



Original Article

# Predictors of radiation-induced changes in arteriovenous malformation patients undergoing radiosurgery: Insights from a Malaysian linear accelerator cohort

Bih Huei Tan<sup>1</sup>, Regunath Kandasamy<sup>2</sup>, Siti Azleen Mohamad<sup>3</sup>, Hari Chandra Thambinayagam<sup>1</sup>

<sup>1</sup>Department of Surgery, Division of Neurosurgery, University Malaya Medical Centre, Petaling Jaya, <sup>2</sup>Department of Neurosurgery, Gleneagles Hospital Kuala Lumpur, <sup>3</sup>Department of Neurosurgery, Hospital Kuala Lumpur, Kuala Lumpur, Malaysia.

E-mail: Bih Huei Tan - bihuei@ummc.edu.my; Regunath Kandasamy - kandasamy.regunath@gmail.com; Siti Azleen Mohamad - siti.azleen@gmail.com;

\*Hari Chandra Thambinayagam - dr.hari.chandran@gmail.com



**\*Corresponding author:**

Hari Chandra Thambinayagam,  
Department of Surgery,  
Division of Neurosurgery,  
University Malaya Medical  
Centre, Petaling Jaya, Malaysia.

dr.hari.chandran@gmail.com

Received: 13 May 2024

Accepted: 07 June 2024

Published: 28 June 2024

DOI

10.25259/SNI\_366\_2024

Quick Response Code:



## ABSTRACT

**Background:** Radiation-induced changes (RICs) post-stereotactic radiosurgery (SRS) critically influence outcomes in arteriovenous malformation (AVM) treatments. This study aimed to identify predictors of RICs, described the types and severity of RICs, and assessed their impact on patient's functional outcomes to enhance risk assessment and treatment planning for AVM patients.

**Methods:** This retrospective study analyzed 87 AVM patients who underwent SRS at Hospital Kuala Lumpur between January 2015 and December 2020. RICs were identified through detailed magnetic resonance imaging evaluations, and predictive factors were determined using multiple logistic regression. Functional outcomes were assessed with the modified Rankin scale (mRS).

**Results:** Among the cohort, 40.2% developed RICs, with radiological RICs in 33.3%, symptomatic RICs in 5.7%, and permanent RICs in 1.1%. Severity categorization revealed 25.3% as Grade I, 13.8% as Grade II, and 1.1% as Grade III. Notably, higher Pollock–Flickinger scores and eloquence location were significant predictors of RIC occurrence. There was a significant improvement in functional outcomes post-SRS, with a marked decrease in non-favorable mRS scores from 8.0% pre-SRS to 1.1% post-SRS ( $P = 0.031$ ).

**Conclusion:** The study identified the eloquence location and Pollock–Flickinger scores as predictors of RICs post-SRS. The significant reduction in non-favorable mRS scores post-SRS underscores the efficacy of SRS in improving patient outcomes. Their results highlighted the importance of personalized treatment planning, focusing on precise strategies to optimize patient outcomes in AVM management, reducing adverse effects while improving functional outcomes.

**Keywords:** Arteriovenous malformation, Linear accelerator, Radiation-induced changes, Stereotactic radiosurgery

## INTRODUCTION

Cerebral arteriovenous malformations (AVMs) are abnormalities of the intracranial vessels, which consist of a number of direct connections between the arterial and venous systems without an intervening capillary bed.<sup>[29]</sup> AVMs are high-flow vascular lesions consisting of a tangle of abnormal blood vessels. It consists of three morphological features which are feeding arteries,

draining veins, and a dysplastic vascular nidus composed of a tangle of abnormal vessels that act as a shunt from the arterial system to the venous system.<sup>[23]</sup> These vascular lesions have an approximate annual rupture rate of 2–4%,<sup>[1]</sup> ranging from <1% for unruptured superficially located AVMs up to 33% in ruptured AVMs with deep locations with deep venous drainage.<sup>[7,42]</sup> Once AVM ruptured, the risk of the patient developing a new neurological deficit has been reported to be up to 50% and fatality ~10%.<sup>[17]</sup> The management of AVMs needs to be based on an understanding of the natural history as well as risks and expectations of surgery, radiosurgery, and embolization, these management pathways can be either single- or multimodality.

Stereotactic radiosurgery (SRS) has been shown to be an excellent treatment modality for patients with small-to-moderated AVM. Complete angiographic obliteration can be achieved in 80–90% of cases with a latency period of 2–3 years, which has been considered effective as surgical resection.<sup>[13,38]</sup> Radiosurgery uses precise localization of high radiation doses to induce a vascular injury response that is ideally limited to the anomalous growth of shunting blood vessels that form the AVM nidus. Thus, SRS favored AVMs with deep brain locations (i.e., brainstem, basal ganglia, or thalamus) or in eloquent brain areas (i.e., sensorimotor, speech, or visual cortex).<sup>[4,5,10]</sup> The most important factors that influenced the AVM obliteration after SRS are the minimum dose to the AVM nidus (marginal dose) and AVM volume.<sup>[15,16]</sup> As SRS becomes a more commonly used modality in the treatment of AVM, complications that arise post-SRS will be crucial to optimizing long-term outcomes.

The earliest and most frequently observed complication after SRS for AVMs is radiation-induced changes (RICs), which typically develop 6–18 months after radiosurgery.<sup>[14]</sup> RICs were defined as newly developed hyperintensity in T2 signal surrounding the treated AVM nidi following radiosurgery.<sup>[25,49]</sup> A grading system was developed to categorize the severity of RICs. Grade I was defined as mild imaging changes with a thickness of increased T2 signal <10 mm surrounding the treated nidi, with no mass effect on surrounding structures. Grade II is defined as moderate imaging changes with increased T2 signal 10 mm or greater, with some mass effect causing effacement of the sulci or compression of the adjacent ventricles. Grade III RICs were severe imaging changes that caused a midline shift of the brain.<sup>[49]</sup> Yen *et al.* evaluated 1426 Gamma Knife surgery procedures performed for AVM patients and noted radiation-induced imaging changes in 33.8% of treated patients. New T2 signal abnormalities following SRS are common and are suggestive of a high rate of cerebral edema or radiation necrosis following treatment.<sup>[49]</sup> In a meta-analysis by Ilyas *et al.* on RICs following SRS for brain AVMs, the rate of radiologic, symptomatic, and permanent changes

was noted to be 35.5%, 9.2%, and 3.8%, respectively. They concluded that approximately 1 in 4 patients who develop radiologic change will become symptomatic.<sup>[21]</sup> Symptoms experienced in patients with RICs include hemiparesis, headache, seizures, sensory dysfunction, ataxia, and cranial nerve palsies.<sup>[21]</sup> RICs have also been associated with late complications post-radiosurgery, such as cyst formation and radiation necrosis. The “12 Gy volume” has been known as the most important factor of symptomatic radiation injury, in which the normal brain area received over 12 Gy adjacent to the lesion was associated with symptomatic post-radiosurgical imaging changes.<sup>[11,12]</sup>

Our study aimed to determine the incidence and predictors of RICs in post-SRS AVM patients. In addition, our secondary objectives were to describe the demographic and clinical characteristics of post-SRS AVM patients, describe the type of RICs developed post-SRS, and determine the effect of RICs on post-SRS AVM patients based on functional outcomes using a modified Rankin scale (mRS). The comprehensive insights gained from this study are intended to improve patient management and outcomes by refining treatment approaches for AVM patients undergoing SRS, thereby enhancing overall treatment efficacy.

## MATERIALS AND METHODS

### Patient selection

This is a retrospective study that obtained approval from the Local Institutional Review Board. We identified patients diagnosed with AVM and treated with SRS alone or in combination with another modality from clinic records. The study included all adult AVM patients treated with SRS at Hospital Kuala Lumpur (HKL) between January 1, 2015, and December 31, 2020. Patients aged over 18 years with AVM confirmed by digital subtraction angiography (DSA) and/or magnetic resonance imaging (MRI)/magnetic resonance-angiogram (MRA)/magnetic resonance-venogram were included in the study. Patients must have received treatment and/or follow-up at the Neurosurgery Department of HKL, with a follow-up period of at least 2 years after SRS and undergone SRS alone or in combination with another treatment modality. Exclusion criteria, including patients lost to follow-up post-SRS and those who were clinically followed but lacked available MRI imaging, including T2 and T2 fluid-attenuated inversion recovery (FLAIR) sequences for analysis, were excluded from the study.

### Variables

We evaluated patient demographics (age, gender, and race), clinical presentation, AVM characteristics (size of nidus, volume of nidus, nidus location, eloquence, venous drainage, arterial feeder, Spetzler-Martin (SM) grading, Spetzler-Ponce

Class, and presence of associated aneurysm), treatment parameters (prior surgery, prior embolization, approach, and treatment dose), along with clinical, angiographic, and MRI follow-up periods.

### Radiosurgical technique

A multidisciplinary meeting was convened to discuss definitive treatment options for patients. This team comprised neurosurgeons, oncologists, and interventional radiologists. Each team member reviewed the patient's records, and a consensus was reached regarding the definitive treatment plan. Linear accelerator radiosurgery was utilized at HKL and the National Cancer Institute (Institute Kanser Negara, IKN) with a frameless-based face mask. Stereotactic cerebral angiography, integrating MRA and DSA, was incorporated into the treatment planning process. Neurosurgeons conducted nidus definition and contouring, while radiation oncologists performed dose planning based on AVM characteristics, proximity to critical structures, and history of prior radiation therapy.

### Follow-up

Following SRS, patients were discharged and subsequently followed up in the clinic to assess clinical symptoms and review MRI imaging. Any newly reported symptoms deemed to be related to radiosurgery by the treating physician were categorized as radiation-induced neurologic signs and symptoms. MRI, including contrast MRI, T2, and T2 FLAIR sequences, as well as MRA, were conducted post-radiosurgery. Once the MRI confirmed total obliteration of the AVM nidus, DSA was performed. Consistent with our hospital protocol, which aligned with existing literature, RICs typically manifest within 6–18 months after radiosurgery, mirroring our MRI follow-up schedule at 6-month intervals until obliteration, followed by annual evaluations after that.<sup>[6,21]</sup> All MRI images were analyzed independently by two radiologists.

### Outcomes

The primary endpoints of this study were as follows: (1) to assess the incidence of RICs, (2) to quantify the type and severity of RICs, and (3) to identify predictors associated with the development of RICs. Secondary endpoints included describing the demographic and clinical characteristics of post-SRS AVM patients and evaluating the impact of RICs on patients' outcomes.

RICs, as defined by Yen *et al.*, were newly developed areas of hyperintensity in the T2 signal surrounding the treated AVM nidi following radiosurgery.<sup>[49]</sup> Post-SRS MRI was conducted at 6, 12, 18, and 24 months in accordance with our hospital's protocol, with a particular T2 signal, which was evaluated to

detect the presence of RICs. A grading system was utilized to categorize the type of RICs into radiologic, symptomatic, and permanent categories. Radiologic RICs were defined as any MRI evidence of perinidal T2-weighted hyperintensities after SRS without new symptoms. Symptomatic RICs were characterized by radiologic evidence coupled with new or worsening neurological symptoms. Permanent RICs were symptomatic RICs without recovery to the patient's pre-SRS neurological status by the end of the study follow-up.<sup>[3,21,26]</sup> In addition, RICs were classified according to severity: Grade I denoted mild imaging changes, Grade II indicated moderate changes with mass effect, and Grade III represented severe changes causing midline brain shift.<sup>[49]</sup>

The secondary endpoint focused on the functional status of patients at 24 months post-SRS. Pre-SRS and post-SRS mRS scores were utilized for their simplicity, widespread acceptance, and established reliability and validity.<sup>[36]</sup> This scale, widely employed in neurology, offered a structured approach to assess the degree of disability or dependence following neurological events. Pollock *et al.* reported on the use of mRS as the primary outcome measure following AVM radiosurgery.<sup>[34]</sup> The mRS scores were dichotomized into favorable (mRS 0–3) and non-favorable (mRS 4–6) outcomes, allowing for a clear distinction between patients experiencing minimal to moderate disability versus those facing severe disability or death. This dichotomization facilitated the evaluation of treatment efficacy and patient prognosis, providing valuable insights into the impact of SRS on functional independence and quality of life.

The radiosurgery-based grading system categorized patient outcomes as excellent, good, fair, unchanged, or poor. Excellent outcomes signified complete nidus obliteration without new deficits, whereas good outcomes indicated minor deficits not significantly impacting daily activities. Fair outcomes reflected major deficits leading to a decline in functioning despite AVM obliteration. Unchanged outcomes indicated persistent arteriovenous shunting without new deficits, whereas poor outcomes encompassed new deficits and incomplete nidus obliteration.<sup>[35]</sup>

### Statistical analysis

Categorical variables were presented as frequencies and percentages, while the normality of continuous variables was assessed using the Shapiro–Wilk test. Skewed distribution variables were described using the median and interquartile range, whereas normally distributed variables were expressed as mean and standard deviation. The association between demographic factors, AVM characteristics, treatment parameters, and outcomes in RIC and non-RIC groups was evaluated using the Chi-square test, with Fisher's Exact test applied when assumptions for the Chi-square test were not met. Medians between RIC and non-RIC groups were

compared using the Mann–Whitney Rank U-test. Multiple logistic regression was employed to identify predictors of RIC, considering variables with *P*-value of at least 0.250 from binary logistic regression for multivariate analysis. The multivariate analysis included factors such as nidus location, depth (deep/superficial), venous drainage pattern (single/multiple), SM grade, Spetzler-Ponce class, radiosurgery-based AVM score (RBAS), approach, AVM obliteration, and AVM duration. Changes in mRS, grade, and RBAS pre- and post-SRS were assessed using the McNemar test. Statistical analyses were conducted using the Statistical Package for the Social Sciences software (version 26), with  $P \leq 0.05$  considered statistically significant. Interrater bias was calculated using Cohen's Kappa value.

## RESULTS

From January 1, 2015, to December 31, 2020, a total of 315 AVM patients were followed up at HKL. Among them, individuals who solely underwent surgery or embolization, as well as those who received both surgery and embolization, were excluded from the analysis, resulting in a cohort of 148 patients who received SRS alone or in combination with other treatment modalities. Following further exclusion of patients who did not meet the inclusion criteria, were lost to follow-up, or had incomplete clinical or radiological data, a total of 87 patients were deemed eligible for the final analysis [Figure 1].

Table 1 shows an analysis of 87 patients undergoing SRS for AVMs, highlighting demographics, AVM characteristics, treatment specifics, and outcomes. The demographic data reveal a cohort predominantly composed of male (55.2%) and Malay (67.8%) patients, with a median age of 26 years,

suggesting a young patient population. AVM analysis revealed a majority with smaller nidus sizes ( $<3 \text{ cm}^3$ , 82.8%) and a significant proportion located in eloquent brain regions (62.1%), underscoring the complexity of the cases treated. Treatment predominantly involved single-session SRS (82.8%), with a median dose of 22.5 Gy, reflecting a standardized therapeutic approach. Outcome assessment post-SRS showed a shift to favorable mRS scores, increasing from 92.0% pre-SRS to 98.9% post-SRS, alongside a 47.1% AVM obliteration rate within a median duration of 18 months. These findings underscored the effectiveness of SRS in improving functional outcomes and achieving AVM obliteration, providing valuable insights into the treatment's impact on a diverse patient population.

Table 2 highlighted the differences between the RIC and non-RIC groups across various parameters, including baseline demographics, AVM characteristics, radiosurgical parameters, and treatment outcomes. Notably, the RIC group contained a significantly higher percentage of males (80%) compared to the non-RIC group (38.5%,  $P < 0.001$ ). In addition, headaches as initial symptoms were more common in the RIC group (17.1%) than in the non-RIC group (1.9%,  $P = 0.010$ ). The data revealed a significant association between RIC occurrence and nidus location in the basal ganglia and thalamus, with higher proportions in the RIC group (14.3% and 31.4%, respectively) than in the non-RIC group (5.8% for both,  $P = 0.002$ ). The result also revealed a significant disparity in treatment approaches; a predominant majority of the non-RIC group underwent single-session radiosurgery, with 96.2% (50 patients) receiving this treatment, whereas only 62.9% (22 patients) in the RIC group, suggesting a lower likelihood of RICs with single-session treatment. Conversely, hypofractionated radiotherapy (HfRT) was more common in

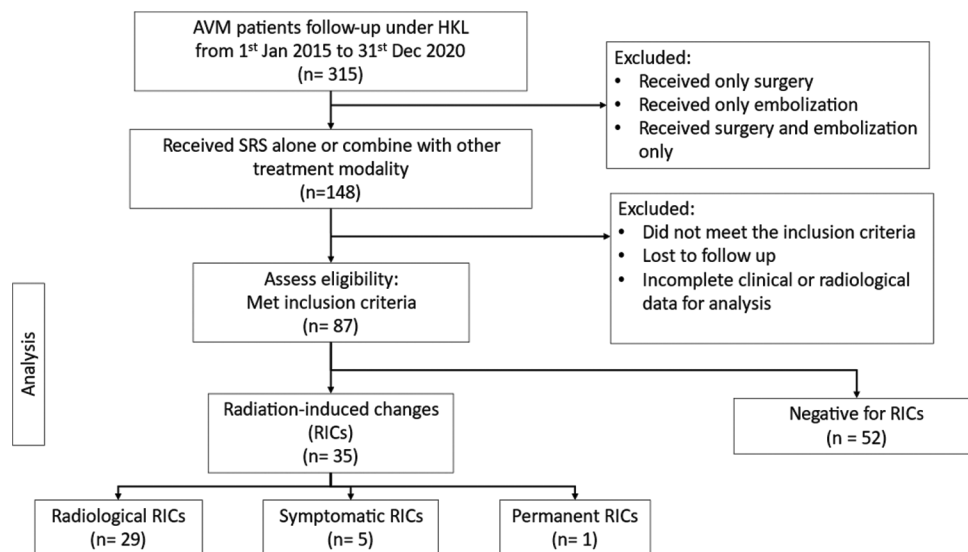


Figure 1: Flow chart of the study design. RIC: Radiation-Induced Changes..



**Table 1:** Patient demographics, AVM characteristics, treatment parameters, and outcomes in the study.

	Total (n=87)
Sex	
Male	48 (55.2)
Female	39 (44.8)
Ethnicity	
Malay	59 (67.8)
Chinese	22 (25.3)
Indian	6 (6.9)
Age (years)	
Median (IQR)	26.0 (17.0)
Presenting symptoms	
Headache	7 (8.0)
Hemorrhage	56 (64.4)
Neurological deficit	7 (8.0)
Seizure	17 (19.5)
AVM characteristics	
Size of nidus (cm <sup>3</sup> )	
<3	72 (82.8)
3–6	15 (17.2)
Nidus vol (cm <sup>3</sup> )	
<5	67 (77.0)
5–10	11 (12.6)
>10	9 (10.3)
Nidus vol (cm <sup>3</sup> )	
Median (IQR)	2.0 (4.4)
Location of nidus	
Basal ganglia	8 (9.2)
Cerebellum	13 (14.9)
Frontal	16 (18.4)
Frontal (corpus)	1 (1.1)
Occipital	6 (6.9)
Parietal	13 (14.9)
Temporal	16 (18.4)
Thalamic	14 (16.1)
Eloquence	
No	33 (37.9)
Yes	54 (62.1)
Venous drainage	
Superficial	41 (47.1)
Deep	32 (36.8)
Both	14 (16.1)
Venous drainage	
Single	51 (58.6)
Multiple	36 (41.4)
Arterial feeder	
Single	46 (54.9)
Multiple	41 (47.1)
Spetzler-Martin grade	
I	17 (19.5)
II	34 (39.1)
III	29 (33.3)
IV	7 (8.0)
Spetzler-Ponce class	
A	49 (56.3)
B	31 (35.6)
C	7 (8.0)

(Contd...)

**Table 1:** (Continued).

	Total (n=87)
VRAS*	
0	4 (4.6)
1	23 (26.4)
2	40 (46.0)
3	10 (11.5)
4	10 (11.5)
Pollock–Flickinger	
<1	48 (55.2)
1.01–1.5	22 (25.3)
1.51–2.0	8 (9.2)
>2.0	9 (10.3)
Asso aneurysm	
No	84 (96.6)
Yes	3 (3.4)
Treatment parameters	
Prior surgery	
No	86 (98.9)
Yes	1 (1.1)
Prior embolization	
No	45 (51.7)
Yes	42 (48.3)
Approach	
Single session	72 (82.8)
HfRT <sup>†</sup>	15 (17.2)
SRS dose	
Min dose	16.0
Max dose	22.5
Median (IQR)	22.5 (4.5)
HfRT dose	
Min dose	35.0
Max dose	55.0
Median (IQR)	55.0 (17.5)
Outcome	
Pre-SRS	
Non-favorable	7 (8.0)
Favorable	80 (92.0)
Pre-SRS grade	
0	40 (46.0)
1	15 (17.2)
2	19 (21.8)
3	6 (6.9)
4	6 (6.9)
5	1 (1.1)
Post-SRS	
Non-favorable	1 (1.1)
Favorable	86 (98.9)
Post-SRS grade	
0	41 (47.1)
1	25 (28.7)
2	14 (16.1)
3	6 (6.9)
4	1 (1.1)

(Contd...)

**Table 1:** (Continued).

	Total (n=87)
RBAS	
Poor	1 (1.1)
Unchanged	45 (51.7)
Fair	1 (1.1)
Good	1 (1.1)
Excellent	39 (44.8)
AVM obliteration	
No	46 (52.9)
Yes	41 (47.1)
AVM obliteration duration (months)	
Median (IQR)	18.0 (7.0)

VRAS\*: Virginia radiosurgery AVM scale, <sup>†</sup>HfRT: Hypofractionated radiotherapy, IQR: Interquartile range, AVM: Arteriovenous malformation, SRS: Stereotactic radiosurgery, RBAS: Radiosurgery-based AVM score

the RIC group, with 37.1% (13 patients) undergoing HfRT, compared to 3.8% (two patients) in the non-RIC group. This highlighted a potential association between HfRT and a higher incidence of RICs. The result also showed a distinct pattern: higher Pollock–Flickinger score correlate with an increased occurrence of RICs among patients. A score >1.5 was linked to a higher frequency of RICs, with 17.1% of patients in both 1.51–2.0 and >2.0 score ranges developing RICs, compared to lower scores where the incidence was markedly less ( $P = 0.028$ ). This correlation underscored the utility of anticipating the risk of adverse outcomes and guiding the stratification of treatment approaches based on the underlying risk profile of the AVM.

Table 3 compares the pre- and post-SRS functional statuses for the entire cohort ( $n = 87$ ) and the subset of patients who developed RICs ( $n = 35$ ). In the total cohort, there was a significant reduction in the proportion of patients with non-favorable mRS scores, decreasing from 8.0% pre-SRS to 1.1% post-SRS ( $P = 0.031$ ). For patients with RICs, the decrease in non-favorable mRS scores from pre-SRS (14.3%) to post-SRS (2.9%) was observed, although it did not achieve statistical significance. The RBAS results indicated that in the total cohort, 44.8% of patients achieved excellent outcomes, whereas 51.7% showed no change. Among the RIC patients, one individual had a poor outcome; 62% remained unchanged, and 28.6% experienced excellent outcomes by the study's conclusion. These results highlight the generally positive effect of SRS on functional outcomes among AVM patients.

Table 4 presents the results of a multiple logistic regression analysis, which was conducted to identify predictors of RICs following SRS. The analysis revealed that the eloquence of the AVM location and the Pollock–Flickinger score were significant predictors of RIC occurrence. Specifically, AVMs

located in eloquent brain regions were associated with a 3.20 times greater likelihood of developing RICs compared to non-eloquent AVMs, as indicated by an adjusted odds ratio (OR) of 3.20 (95% confidence interval [CI]: 1.10–9.33). In addition, Pollock–Flickinger score >2.0 was associated with a 5.55 times higher risk of RICs compared to scores below 1 (adjusted OR = 5.55, 95% CI: 1.13–27.34,  $P = 0.032$ ). Patients with scores between 1.51 and 2.0 had a 9.17 times increased risk of RICs compared to those with scores below 1 (adjusted OR = 9.17, 95% CI: 1.51–55.72,  $P = 0.032$ ). These findings highlighted the significant association between AVM eloquence, high Pollock–Flickinger scores, and the increased risk of RICs post-SRS.

## DISCUSSION

### Incidence and severity of RICs

In this study, 35 patients (40.2%) developed RICs, categorized as radiological (33.3%), symptomatic (5.7%), and permanent (1.1%). When our findings were compared with those from Ilyas *et al.*'s meta-analysis, our rates closely aligned with their reported overall RIC rates of 35.5%, 9.2%, and 3.8% for radiological, symptomatic, and permanent changes, respectively.<sup>[21]</sup> Kano *et al.* reported a symptomatic RIC rate of 7% and a permanent RIC rate of 3% in a similar context.<sup>[24]</sup> Examining RIC severity, our study revealed that 25.3% were classified as Grade I, 13.8% as Grade II, and 1.1% as Grade III in RIC severity. In contrast, Yen *et al.* reported a total RIC rate of 33.8%, with 19.7%, 11.5%, and 2.6% classified as Grade I, Grade II, and Grade III, respectively.<sup>[49]</sup> Similarly, Kim *et al.* found that 43.9% of AVM patients developed RICs, with 48.1%, 46.8%, and 5.1% categorized as Grade I, Grade II, and Grade III.<sup>[26]</sup> While the previous studies have suggested an adverse impact of prior embolization on RIC development, our study did not find a significant association.<sup>[21,26,32]</sup> This discrepancy might stem from the multifactorial and complex nature of the relationship between AVM embolization and RIC development, as indicated by recent studies by Lee *et al.* and Yan *et al.*<sup>[28,47]</sup>

### Risk factors of RICs

Brain eloquence and the Pollock–Flickinger score were identified as predictors, as detailed in Table 4. The previous studies have linked the development of RICs to various factors, including a single draining vein, multiple arterial feeders, large nidus volume, complex AVM angioarchitecture (higher SM grade, Pollock–Flickinger score, and Virginia radiosurgery AVM scale), nidus location, and SRS dose.<sup>[6,21,24,26,45,48,49]</sup> Favorable outcomes have been observed for small-to-moderate-sized AVMs, whereas the efficacy for large-volume AVMs remains uncertain.<sup>[3,13,43]</sup> Large-volume AVMs were frequently associated with low obliteration

**Table 2:** Comparison of baseline demographics data, AVM characteristics, radiosurgical parameters, and treatment outcomes between the RIC group and non-RIC group.

	Non-RIC (n=52)	RIC (n=35)	P-value
Sex			
Male	20 (38.5)	28 (80.0)	<0.001**
Female	32 (61.5)	7 (20.0)	
Ethnicity			
Malay	32 (61.5)	27 (77.1)	0.235
Chinese	15 (28.8)	7 (20.0)	
Indian	5 (9.6)	1 (2.9)	
Age (years)			
Median (IQR)	24.5 (16.0)	27.0 (17.0)	0.252
Presenting symptoms			
Headache	1 (1.9)	6 (17.1)	0.010*
Hemorrhage	39 (75.0)	17 (48.6)	
Neurological deficit	2 (3.8)	5 (14.3)	
Seizure	10 (19.2)	7 (20.0)	
AVM characteristics			
Size of nidus (cm <sup>3</sup> )			
<3	43 (82.7)	29 (82.9)	0.984
3–6	9 (17.3)	6 (17.1)	
Nidus vol (cm <sup>3</sup> )			
<5	42 (80.8)	25 (71.4)	0.527
5–10	6 (11.5)	5 (14.3)	
>10	4 (7.7)	5 (14.3)	
Nidus vol (cm <sup>3</sup> )			
Median (IQR)	1.63 (3.85)	2.16 (5.17)	0.153
Location of nidus			
Basal ganglia	3 (5.8)	5 (14.3)	0.002**
Cerebellum	11 (21.2)	2 (5.7)	
Frontal	10 (19.2)	6 (17.1)	
Corpus	0 (0.0)	1 (2.9)	
Callosum			
Occipital	6 (11.5)	0 (0.0)	
Parietal	7 (13.5)	6 (17.1)	
Temporal	12 (23.1)	4 (11.4)	
Thalamic	3 (5.8)	11 (31.4)	
Eloquent			
No	24 (46.2)	9 (25.7)	0.054
Yes	28 (53.8)	26 (74.3)	
Venous drainage			
Superficial	26 (50.0)	15 (42.9)	0.806
Deep	18 (34.6)	14 (40.0)	
Both	8 (15.4)	6 (17.1)	
Venous drainage			
Single	27 (51.9)	24 (68.6)	0.122
Multiple	25 (48.1)	11 (31.4)	
Arterial feeder			
Single	30 (57.7)	16 (45.7)	0.272
Multiple	22 (42.3)	19 (54.3)	
Spetzler–Martin grade			
I	11 (21.2)	6 (17.1)	0.153
II	24 (46.2)	10 (28.6)	
III	15 (28.8)	14 (40.0)	
IV	2 (3.8)	5 (14.3)	

(Contd...)

**Table 2:** (Continued).

	Non-RIC (n=52)	RIC (n=35)	P-value
Spetzler–Ponce class			
A	33 (63.5)	16 (45.7)	0.131
B	17 (32.7)	14 (40.0)	
C	2 (3.8)	5 (14.3)	
VRAS*			
0	3 (5.8)	1 (2.9)	0.484
1	13 (25.0)	10 (28.6)	
2	27 (51.9)	13 (37.1)	
3	4 (7.7)	6 (17.1)	
4	5 (9.6)	5 (14.3)	
Pollock–Flickinger			
<1	34 (65.4)	14 (40.0)	0.028*
1.01–1.5	13 (25.0)	9 (25.7)	
1.51–2.0	2 (3.8)	6 (17.1)	
>2.0	3 (5.8)	6 (17.1)	
Asso aneurysm			
No	50 (96.2)	34 (97.1)	1.000
Yes	2 (3.8)	1 (2.9)	
Radiosurgical parameters			
Prior surgery			
No	52 (100.0)	34 (97.1)	0.402
Yes	0 (0.0)	1 (2.9)	
Prior embolization			
No	26 (50.0)	19 (54.3)	0.695
Yes	26 (50.0)	16 (45.7)	
Approach			
Single session	50 (96.2)	22 (62.9)	<0.001**
HfRT <sup>†</sup>	2 (3.8)	13 (37.1)	
SRS dose			
Min dose	16.0	18.0	
Max dose	22.5	22.5	
Median (IQR)	22.5 (4.5)	20.4 (4.1)	0.310
HfRT dose			
Min dose	55.0	35.0	
Max dose	55.0	55.0	
Median (IQR)	55.0 (0.0)	55.0 (17.5)	0.476

Data presented as n (%) unless indicated, \*Significant at  $P < 0.05$ ; \*\*Significant at  $P < 0.001$ . VRAS\*, Virginia radiosurgery AVM scale. <sup>†</sup>HfRT: Hypofractionated radiotherapy. IQR: Interquartile range, AVM: Arteriovenous malformation, SRS: Stereotactic radiosurgery, RIC: Radiation-induced change

rates, and a larger area of irradiated normal tissue adjacent to AVMs increased the risk of RICs. A notable finding from our study was the eloquent locations that were associated with a 3.2 times greater risk of developing RICs compared to non-eloquent location AVMs, highlighting the importance of meticulous pre-treatment planning. In addition, eloquent locations were associated with higher hemorrhage rates and were unfavorable predictors for obliteration.<sup>[3,31]</sup> Certain AVM locations were linked to a higher risk of RICs due to their proximity to critical brain regions.<sup>[5,11,24]</sup> This observation aligned with findings by Kobayashi *et al.*, who reported that the increased sensitivity of brain tissue in eloquent

**Table 3:** Pre- and post-SRS mRS score of patients.

	Total (n=87)		P-value
	Pre-SRS	Post-SRS	
mRS			
Non-favorable	7 (8.0)	1 (1.1)	0.031*
Favorable	80 (92.0)	86 (98.9)	
Grade			
0	40 (46.0)	41 (47.1)	N/A
1	15 (17.2)	25 (28.7)	
2	19 (21.8)	14 (16.1)	
3	6 (6.9)	6 (6.9)	
4	6 (6.9)	1 (1.1)	
5	1 (1.1)	0 (0.0)	
*RBAS			
Poor		1 (1.1)	N/A
Unchanged		45 (51.7)	
Fair		1 (1.1)	
Good		1 (1.1)	
Excellent		39 (44.8)	
	Total RICs (n=35)		P-value
	Pre-SRS	Post-SRS	
mRS			
Non-favorable	5 (14.3)	1 (2.9)	0.125
Favorable	30 (85.7)	34 (97.1)	
Grade			
0	10 (28.6)	10 (28.6)	N/A
1	7 (20.0)	9 (25.7)	
2	7 (20.0)	9 (25.7)	
3	6 (17.1)	6 (17.1)	
4	4 (11.4)	1 (2.9)	
5	1 (2.9)	0 (0.0)	
*RBAS			
Poor		1 (2.9)	N/A
Unchanged		22 (62.9)	
Fair		1 (2.9)	
Good		1 (2.9)	
Excellent		10 (28.6)	

\*Significant at P<0.05, N/A: Not applicable. Data presented as n (%). \*RBAS: Radiosurgery-based AVM score, AVM: Arteriovenous malformation, SRS: Stereotactic radiosurgery, mRS: Modified Rankin Scale, RIC: Radiation-induced change

regions to radiation significantly influenced treatment outcomes and higher risk of adverse radiation effects.<sup>[27]</sup> Eloquent brain areas composed of densely packed neuronal structures are highly sensitive to radiation. SRS could cause dose-dependent cortical thinning, disrupting local neural networks and potentially leading to increased incidences of RICs.<sup>[46]</sup> Several studies have described different strategies for treating AVMs in eloquent locations. Kim *et al.* reported that a lower marginal dose (<16 Gy) was prescribed for AVMs situated in eloquent areas.<sup>[26]</sup> Time-dosed SRS was reported to be effective in treating AVMs in highly eloquent areas with a low rate of complications.<sup>[39,40]</sup> This finding is crucial

**Table 4:** Multiple logistic regression analysis to determine the predictors of RICs.

	Adjusted OR	95% CI	P-value
Eloquence			
No	1.00		0.033*
Yes	3.20	1.10–9.33	
Pollock–Flickinger score			
<1	1.00		0.032*
1.01–1.5	1.31	0.44–3.91	
1.51–2.0	9.17	1.51–55.72	
>2.0	5.55	1.13–27.34	

Adjusted OR based on multiple logistic regression with RIC+=1 and RIC-=0. The model is fit (Hosmer and Lemeshow, P=0.538) and explains 20.2% of the variation in RIC (Nagelkerke R2=0.202). No multicollinearity and interaction were found in the final model. Only significant predictors are shown in the final model. \*Significant at P<0.05; OR: Odds ratio. RIC: Radiation-induced change, CI: Confidence interval

for neurosurgeons as it underscores the need for precision in targeting and dose distribution, particularly in eloquent brain regions where maintaining a balance between effective treatment and preservation of function is most delicate.

Another predictor in our study was the Pollock–Flickinger score. Previous studies have shown that a higher Pollock–Flickinger score is associated with an increased risk of RICs.<sup>[24,26]</sup> The Pollock–Flickinger score was also linked to the risk of bleeding; Peciu-Florianu *et al.* reported that for each 0.5-point increase in the Pollock–Flickinger score, the risk of bleeding increased by 1.8.<sup>[33]</sup> In our study, we discovered that the relationship between the Pollock–Flickinger score and the risk of RICs might not be strictly linear. A Pollock–Flickinger score >2.0 was associated with a 5.55 times higher risk of RICs, while patients with a score between 1.51 and 2.0 had a 9.17 times increased risk of RICs. This could be due to the fact that higher Pollock–Flickinger scores are associated with more complex AVMs, which usually require a multimodal treatment approach. A patient with a large volume AVM will undergo embolization to reduce the size of the AVM before SRS. Oermann *et al.* investigated the effect of prior embolization on AVM SRS outcomes and concluded that the AVM’s architectural complexity may significantly confound the impact of prior embolization on AVM obliteration after SRS. In addition, they found that embolization could reduce the risk of RICs.<sup>[32]</sup> Embolization material is proven to attenuate the radiosurgical beam, causing a reduction in the delivered dose of 10–15%.<sup>[2]</sup> Several studies also found that SRS following embolization was associated with a lower obliteration rate than SRS alone.<sup>[22,37,50]</sup> This finding could be due to several reasons: (1) the radiation beam delivered by SRS could be absorbed or scattered by embolic agents, causing a reduced overall dose to the nidus;<sup>[2]</sup> (2) embolization could fragment the nidus into non-contiguous compartments, increasing the difficulty of SRS targeting;<sup>[41]</sup>



and (3) embolization in AVMs could increase the difficulty in defining the nidus by obscuring its boundaries and increase the risk of SRS treatment failure.<sup>[44]</sup> It seems that prior embolization offers some “protective mechanism” against the development of RICs. This correlation not only aids in risk stratification but also in patient counseling, offering a more transparent discussion about potential outcomes. Such insights are vital for enhancing shared decision-making processes and aligning treatment objectives with patient expectations, ultimately fostering a patient-centered approach in neurosurgical care.

### Presenting symptom

Interestingly, a history of hemorrhage was inversely correlated with RIC development, possibly attributed to perinidal gliotic tissue acting as a protective barrier.<sup>[8,20,21,26]</sup> Furthermore, headaches were significantly more prevalent in the RIC group than in the non-RIC group (17.1% vs. 1.9%,  $P = 0.010$ ), consistent with findings by Daou *et al.*<sup>[6]</sup> RICs resulted in temporary symptoms, with an onset ranging from 1 week to 22 months, peaking at 12 months post-treatment. Notably, 34.3% of patients experienced RIC resolution by the study's end, with a mean duration from RIC to resolution of 22.7 months.<sup>[6,8,20,21,26,49]</sup> Our study's exploration into demographic factors and presenting symptoms revealed intriguing associations with RIC development. The inverse relationship between hemorrhage as a presenting symptom and RIC occurrence suggested a potential protective mechanism, a finding that aligned with some prior research but remained a topic of debate. The prevalence of headaches in patients who developed RICs adds another layer of complexity to patient assessment and highlights the need for thorough pre-treatment evaluations. These insights not only add depth to our understanding of RICs but also suggest potential avenues for refining risk assessment and improving patient discussions regarding SRS for AVMs.

### Clinical implications

In Table 4, the outcomes for the total cohort of patients post-SRS showed a significant decrease in non-favorable mRS scores from pre- to post-SRS (8.0–1.1%,  $P = 0.031$ ). This result underscored the overall positive impact of SRS on functional outcomes in AVM patients. However, within the RIC group, there was no statistically significant difference in pre- and post-SRS mRS scores. This suggested that even with the development of RIC, there was no decline in the overall mRS score for patients post-SRS. A retrospective, single-center, and matched cohort study by Nataf *et al.* found that SRS had significantly lower morbidity with no significant difference in mortality or obliteration rates compared to microsurgery.<sup>[30]</sup> Ding *et al.* and Graffeo *et al.* reported similar results in their studies, concluding that SRS

has a favorable risk-to-benefit profile, especially in Grade I–II AVMs, with unfavorable characteristics.<sup>[9,18]</sup> In 2020, the International Society of Stereotactic Radiosurgery (ISRS) developed practice guidelines for SM grade I–II AVMs, recommending SRS as a safe and efficacious treatment and a non-inferior alternative to microsurgery in these cases. ISRS also emphasized SRS as a preferred primary therapy for Grade I–II AVMs with specific characteristics (eloquent location, deep draining vein, incomplete prior resection, and poor surgical candidates). Regarding RICs, ISRS recommends minimizing the 12-Gy volume during treatment planning, as it is associated with the development of RIC.<sup>[19]</sup> The study's outcomes, particularly the changes in mRS score post-SRS, highlighted the therapeutic benefits of SRS in enhancing patient functional outcomes. Despite the development of RICs, the overall mRS scores did not decline significantly post-SRS, indicating that SRS remains a viable treatment option with a favorable risk-to-benefit profile. The guidelines from the ISRS support this finding and reinforce the role of SRS in managing AVM patients effectively.

### Limitations and future directions

While this study offered valuable insights into predictors and outcomes of RICs following SRS for AVMs, it was not without limitations. The retrospective nature and single-center design might have limited the generalizability of the findings, potentially introducing selection biases. In addition, the relatively small sample size and the study's short follow-up period constrained our ability to assess long-term outcomes and the durability of treatment effects comprehensively. Future research should aim to conduct prospective, multi-center studies with larger patient cohorts and extended follow-up durations to validate and expand on our findings. Moreover, there is a need to explore the molecular and genetic mechanisms underlying RIC development to enhance predictive accuracy and develop targeted preventive strategies. Investigating the impact of emerging radiosurgical techniques and refining treatment protocols based on patient-specific factors will also be crucial in advancing the field and improving patient outcomes in AVM management.

### CONCLUSION

This study provided crucial insights into RICs post-SRS for AVMs, demonstrating that 40.2% of patients developed RICs, a statistic that emphasized the need for personalized risk assessments in treatment planning. By identifying key predictors such as the Pollock–Flickinger score and eloquence of AVM location and assessing the impact of various radiosurgical techniques, this study enhanced our understanding of RICs, aligning with and expanding on the existing literature. The findings highlighted the complexity of RIC prediction and the significance of tailored patient

care, offering valuable guidance for clinicians in optimizing treatment strategies and managing post-SRS outcomes. Through this enhanced understanding, the study contributed to improving clinical decision-making, aiming to refine SRS treatments and patient management to reduce RIC risks and improve overall treatment efficacy for AVM patients.

### Acknowledgment

The authors would like to thank individuals who contributed to the study or manuscript preparation but who did not fulfill all the criteria of authorship.

### Ethical approval

The research/study was approved by the Institutional Review Board at the Medical Research and Ethics Committee, number NMRR ID-23-00369-LNJ (IIR), dated May 19, 2023.

### Declaration of patient consent

Patient's consent was not required as there are no patients in this study.

### Financial support and sponsorship

Nil.

### Conflicts of interest

There are no conflicts of interest.

### Use of artificial intelligence (AI)-assisted technology for manuscript preparation

The authors confirm that there was no use of artificial intelligence (AI)-assisted technology for assisting in the writing or editing of the manuscript and no images were manipulated using AI.

## REFERENCES

- Al-Shahi R, Bhattacharya JJ, Currie DG, Papanastassiou V, Ritchie V, Roberts RC, *et al.* Prospective, population-based detection of intracranial vascular malformations in adults: The Scottish Intracranial Vascular Malformation Study (SIVMS). *Stroke* 2003;34:1163-9.
- Andrade-Souza YM, Ramani M, Beachey DJ, Scora D, Tsao MN, terBrugge K, *et al.* Liquid embolization material reduces the delivered radiation dose: A physical experiment. *Acta Neurochir (Wien)* 2008;150:161-4.
- China M, Vastani A, Hill CS, Tancu C, Grover PJ. Gamma Knife radiosurgery for cerebral arteriovenous malformations: A systematic review and meta-analysis. *Neurosurg Rev* 2022;45:1987-2004.
- Cohen-Inbar O, Ding D, Chen CJ, Sheehan JP. Stereotactic radiosurgery for deep intracranial arteriovenous malformations, part 1: Brainstem arteriovenous malformations. *J Clin Neurosci* 2016;24:30-6.
- Cohen-Inbar O, Ding D, Sheehan JP. Stereotactic radiosurgery for deep intracranial arteriovenous malformations, part 2: Basal ganglia and thalamus arteriovenous malformations. *J Clin Neurosci* 2016;24:37-42.
- Daou BJ, Palmateer G, Wilkinson DA, Thompson BG, Maher CO, Chaudhary N, *et al.* Radiation-induced imaging changes and cerebral edema following stereotactic radiosurgery for brain AVMs. *Am J Neuroradiol* 2021;42:82-7.
- Ding D, Starke RM, Sheehan JP. Radiosurgery for the management of cerebral arteriovenous malformations. In: *Handbook of clinical neurology*. Vol. 143. Netherlands: Elsevier B.V.; 2017. p. 69-83.
- Ding D, Yen CP, Starke RM, Xu Z, Sheehan JP. Effect of prior hemorrhage on intracranial arteriovenous malformation radiosurgery outcomes. *Cerebrovasc Dis* 2015;39:53-62.
- Ding D, Yen CP, Xu Z, Starke RM, Sheehan JP. Radiosurgery for low-grade intracranial arteriovenous malformations. *J Neurosurg* 2014;121:457-67.
- Ding D, Yen CP, Xu Z, Starke RM, Sheehan JP. Radiosurgery for primary motor and sensory cortex arteriovenous malformations: Outcomes and the effect of eloquent location. *Neurosurgery* 2013;73:816-24.
- Flickinger JC, Kondziolka D, Pollock BE, Mapz AH, Dade Lunsford L. Complications from arteriovenous malformation radiosurgery: Multivariate analysis and risk modelling. *Int J Radiat Oncol Biol Phys* 1997;38:485-90.
- Flickinger JC, Kondziolka D, Lunsford LD, Kassam A, Phuong LK, Liscak R, *et al.* Clinical investigation central nervous system development of a model to predict permanent symptomatic postradiosurgery injury for arteriovenous malformation patients. *Int J Radiat Oncol Biol Phys* 2000;46:1143-8.
- Flickinger JC, Kondziolka D, Maitz AH, Lunsford LD. An analysis of the dose-response for arteriovenous malformation radiosurgery and other factors affecting obliteration. *Radiother Oncol* 2002;63:347-54.
- Flickinger JC, Lunsford LD, Kondziolka D, Maitz AH, Epstein AH, Simons SR, *et al.* Radiosurgery and brain tolerance: An analysis of neurodiagnostic imaging changes after gamma knife radiosurgery for arteriovenous malformations. *Int J Radiat Oncol Biol Phys* 1992;23:19-26.
- Flickinger JC, Pollock BE, Kondziolka D, Lunsford LD. A dose-response analysis of arteriovenous malformation obliteration after radiosurgery. *Int J Radiat Oncol Biol Phys* 1996;36:873-9.
- Friedman WA, Bova FJ, Mendenhall WM. Linear accelerator radiosurgery for arteriovenous malformations: the relationship of size to outcome. *J Neurosurg* 1995;82:180-9.
- Fukuda K, Majumdar M, Masoud H, Nguyen T, Honarmand A, Shaibani A, *et al.* Multicenter assessment of morbidity associated with cerebral arteriovenous malformation hemorrhages. *J Neurointerv Surg* 2017;9:664-8.
- Graffeo CS, Link MJ, Stafford SL, Garces YI, Foote RL, Pollock BE. More II it than meets the eye: Outcomes after single-fraction stereotactic radiosurgery in a case series of low-grade arteriovenous malformations. *Oper Neurosurg*

- 2020;18:136-44.
19. Graffeo CS, Sahgal A, De Salles A, Fariselli L, Levivier M, Ma L, *et al.* Stereotactic radiosurgery for Spetzler-Martin Grade I and II arteriovenous malformations: International society of stereotactic radiosurgery (ISRS) practice guideline. *Neurosurgery* 2020;87:442-52.
  20. Hayhurst C, Monsalves E, van Prooijen M, Cusimano M, Tsao M, Menard C, *et al.* Pretreatment predictors of adverse radiation effects after radiosurgery for arteriovenous malformation. *Int J Radiat Oncol Biol Phys* 2012;82:803-8.
  21. Ilyas A, Chen CJ, Ding D, Buell TJ, Raper DM, Lee CC, *et al.* Radiation-induced changes after stereotactic radiosurgery for brain arteriovenous malformations: A systematic review and meta-analysis. *Clin Neurosurg* 2018;83:365-76.
  22. Jiang Z, Zhang X, Wan X, Wei M, Liu Y, Ding C, *et al.* Efficacy and safety of combined endovascular embolization and stereotactic radiosurgery for patients with intracranial arteriovenous malformations: A systematic review and meta-analysis. *Biomed Res Int* 2021;2021:6686167.
  23. Kalimo H, Kase M, Haltia M. *Greenfield's neuropathology*. 6<sup>th</sup> ed. New York: Oxford University Press; 1997.
  24. Kano H, Flickinger JC, Tonetti D, Hsu A, Yang H, Flannery TJ, *et al.* Estimating the risks of adverse radiation effects after gamma knife radiosurgery for arteriovenous malformations. *Stroke* 2017;48:84-90.
  25. Katsura M, Sato J, Akahane M, Furuta T, Mori H, Abe O. Recognizing radiation-induced changes in the central nervous system: Where to look and what to look for. *Radiographics* 2021;41:224-48.
  26. Kim MJ, Chang KW, Park SH, Chang WS, Chang JH, Chang JW, *et al.* Predictive factors of radiation-induced changes following single-session gamma knife radiosurgery for arteriovenous malformations. *J Clin Med* 2021;10:2186.
  27. Kobayashi T, Kida Y, Tanaka T, Yoshida K, Mori Y, Ohosuka K, *et al.* Eloquent areas in the gamma knife treatment of arteriovenous malformations of the brain. *Jpn J Neurosurg* 1999;8:385-94.
  28. Lee CC, Chen CJ, Ball B, Schlesinger D, Xu Z, Yen CP, *et al.* Stereotactic radiosurgery for arteriovenous malformations after Onyx embolization: A case-control study. *J Neurosurg* 2015;123:126-35.
  29. Martin NA, Vinters HV. *Neurovascular surgery*. New York: McGraw-Hill; 1995.
  30. Nataf F, Schlienger M, Bayram M, Ghossoub M, George B, Roux FX. Microsurgery or radiosurgery for cerebral arteriovenous malformations? A study of two paired series. *Neurosurgery* 2007;61:39-50.
  31. Nguyen BT, Huynh CT, Nguyen TM, Nguyen VT, Karras CL, Huynh-Le P, *et al.* Gamma knife radiosurgery for brain arteriovenous malformations: A 15-year single-center experience in southern Vietnam. *World Neurosurg* 2022;163:71-9.
  32. Oermann EK, Ding D, Yen CP, Starke RM, Bederson JB, Kondziolka D, *et al.* Effect of prior embolization on cerebral arteriovenous malformation radiosurgery outcomes. *Neurosurgery* 2015;77:406-17.
  33. Peciu-Florianu I, Leroy HA, Drumez E, Dumot C, Aboukaïs R, Touzet G, *et al.* Radiosurgery for unruptured brain arteriovenous malformations in the pre-ARUBA era: Long-term obliteration rate, risk of hemorrhage and functional outcomes. *Sci Rep* 2020;10:21427.
  34. Pollock BE, Brown RD. Use of the Modified Rankin Scale to assess outcome after arteriovenous malformation radiosurgery. *Neurology* 2006;67:1630-4.
  35. Pollock BE, Flickinger JC. A proposed radiosurgery-based grading system for arteriovenous malformations. *J Neurosurg* 2002;96:79-85.
  36. Pożarowski N, Kurkowska-Jastrzębska I, Sarzyńska-Długosz I, Nowak M, Karliński M. Reliability of the modified Rankin Scale in clinical practice of stroke units and rehabilitation wards. *Front Neurol* 2023;14:1064642.
  37. Russell D, Peck T, Ding D, Chen CJ, Taylor DG, Starke RM, *et al.* Stereotactic radiosurgery alone or combined with embolization for brain arteriovenous malformations: A systematic review and meta-analysis. *J Neurosurg* 2018;128:1338-48.
  38. Schlienger M, Atlan D, Lefkopoulos D, Merienne L, Touboul E, Missir O, *et al.* Linac radiosurgery for cerebral arteriovenous malformations: Results in 169 patients. *Int J Radiat Oncol Biol Phys* 2000;46:1135-42.
  39. Sethi A, Chee K, Chatain GP, Wittenberg B, Seinfeld J, Milgrom S, *et al.* Time-dosed stereotactic radiosurgery for the treatment of cerebral arteriovenous malformations: An early institution experience and case series. *Neurosurg Pract* 2023;4:e00056.
  40. Shah SN, Shah SS, Kaki P, Satti SR, Shah SA. Efficacy of dose-escalated hypofractionated radiosurgery for arteriovenous malformations. *Cureus* 2024;16:e52514.
  41. Shtraus N, Schifter D, Corn BW, Maimon S, Alani S, Frolov V, *et al.* Radiosurgical treatment planning of AVM following embolization with Onyx: Possible dosage error in treatment planning can be averted. *J Neurooncol* 2010;98:271-6.
  42. Stapf C, Mast H, Sciacca RR, Berenstein A, Nelson PK, Gobin YP, *et al.* The New York Islands AVM study. *Stroke* 2003;34:e29-33.
  43. Starke RM, Kano H, Ding D, Lee JY, Mathieu D, Whitesell J, *et al.* Stereotactic radiosurgery for cerebral arteriovenous malformations: Evaluation of long-term outcomes in a multicenter cohort. *J Neurosurg* 2017;126:36-44.
  44. Valle RD, Zenteno M, Jaramillo J, Lee A, De Anda S. Definition of the key target volume in radiosurgical management of arteriovenous malformations: A new dynamic concept based on angiographic circulation time. *J Neurosurg* 2008;109:41-50.
  45. van den Berg R, Buis DR, Lagerwaard FJ, Nijeholt GJ, Vandertop WP. Extensive white matter changes after stereotactic radiosurgery for brain arteriovenous malformations. *Neurosurgery* 2008;63:1064-70.
  46. Voshart DC, Wiedemann J, van Luijk P, Barazzuol L. Regional responses in radiation-induced normal tissue damage. *Cancers (Basel)* 2021;13:367.
  47. Yan D, Chen Y, Li Z, Zhang H, Li R, Yuan K, *et al.* Stereotactic radiosurgery with vs. without prior embolization for brain arteriovenous malformations: A propensity score matching analysis. *Front Neurol* 2021;12:752164.
  48. Yang HC, Wu HM, Peng SJ, Lee CC, Chen YW, Kuan AS, *et al.* The irradiated brain volume within 12 Gy is a predictor for radiation-induced changes after stereotactic radiosurgery

- in patients with unruptured cerebral arteriovenous malformations. *Int J Radiat Oncol Biol Phys* 2021;111:785-93.
49. Yen CP, Matsumoto JA, Wintermark M, Schwyzer L, Evans AJ, Jensen ME, *et al.* Radiation-induced imaging changes following Gamma Knife surgery for cerebral arteriovenous malformations. *J Neurosurg* 2013;118:63-73.
50. Zhu D, Li Z, Zhang Y, Fang Y, Li Q, Zhao R, *et al.* Gamma knife surgery with and without embolization for cerebral

arteriovenous malformations: A systematic review and meta-analysis. *J Clin Neurosci* 2018;56:67-73.

**How to cite this article:** Tan B, Kandasamy R, Mohamad S, Thambinayagam H. Predictors of radiation-induced changes in arteriovenous malformation patients undergoing radiosurgery: Insights from a Malaysian linear accelerator cohort. *Surg Neurol Int.* 2024;15:223. doi: 10.25259/SNI\_366\_2024

### Disclaimer

The views and opinions expressed in this article are those of the authors and do not necessarily reflect the official policy or position of the Journal or its management. The information contained in this article should not be considered to be medical advice; patients should consult their own physicians for advice as to their specific medical needs.