

Lupus pneumonitis presenting with high titre of anti-Ro antibody

Mei-Chuan Chen¹, Yueh-Lin Wu², Kai-Ling Lee¹, Kevin S. Lai¹ & Chi-Li Chung^{1,3} 

¹Division of Pulmonary Medicine, Department of Internal Medicine, Taipei Medical University Hospital, Taipei, Taiwan.

²Division of Nephrology Medicine, Department of Internal Medicine, Taipei Medical University Hospital, Taipei, Taiwan.

³School of Respiratory Therapy, Division of Thoracic medicine, Department of Internal Medicine, School of Medicine, College of Medicine, Taipei Medical university, Taipei, Taiwan.

Keywords

anti-Ro antibody, lupus pneumonitis, systemic lupus erythematosus.

Correspondence

Chi-Li Chung, Division of Pulmonary Medicine, Department of Internal Medicine, Taipei Medical University Hospital, No. 252, Wuxing Street, Taipei 11031, Taiwan. E-mail: cchung@tmu.edu.tw

Received: 31 July 2017; Revised: 16 September 2017; Accepted: 26 September 2017;
Associate Editor: Charles Feldman.

Respirology Case Reports, 6 (1), 2018, e00280

doi: 10.1002/rccr.2.280

Abstract

Lupus pneumonitis carries high mortality and is a rare manifestation of systemic lupus erythematosus (SLE). However, it is difficult to diagnose and is often mistaken as pneumonia, alveolar haemorrhage, or organizing pneumonia. Previous studies demonstrated that serum anti-Ro antibodies are elevated more frequently in SLE patients with pneumonitis than in those without. We report a 21-year-old female who was newly diagnosed as having SLE with nephritis and who suddenly developed right lung opacity and rapidly progressed to severe hypoxaemia despite the use of broad-spectrum antibiotics. The serum titre of anti-Ro antibody was greater than 240 U/mL. She underwent lung biopsy and lupus pneumonitis was confirmed by the pathological findings. Subsequently, she showed a favourable response to plasma exchange, steroid pulse therapy, and mycophenolate mofetil (MMF) treatment. For SLE patients with pulmonary infiltrates, high degree of clinical suspicion of lupus pneumonitis is required and measurement of serum anti-Ro antibody may help to make the diagnosis.

Introduction

Lupus pneumonitis carries high mortality and is a rare manifestation in patients with systemic lupus erythematosus (SLE). However, it is difficult to diagnose and often mistaken as pneumonia, alveolar haemorrhage, or organizing pneumonia. Intriguingly, previous studies demonstrated that serum anti-Ro antibodies are elevated more frequently in patients with lupus pneumonitis than in those with other manifestations. We report a 21-year-old female who presented with rapidly progressive lung opacities and was diagnosed as having lupus pneumonitis by pathological examination and high serum anti-Ro antibody. Afterwards, she showed a favourable response to plasma exchange, steroid pulse therapy, and mycophenolate mofetil (MMF) treatment.

Case Report

A 21-year-old female presented with mild fever and right lower chest pain for 1 day. She also complained of dry

cough and breathlessness. She did not smoke and family history was unremarkable. A week before admission, she was diagnosed as having SLE with lupus nephritis class V by renal biopsy, accompanied by the presence of photosensitivity, malar rash, arthralgia, positive antinuclear antibody (ANA) and anti-double stranded DNA (anti-dsDNA), negative anti-Smith and anti-RNP antibodies, and lower levels of C3 and C4 and was currently taking prednisolone 30 mg twice daily (bd) as front treatment. Use of accessory muscle of respiration was observed, and right lower lung crackles, right lower chest tenderness, and bilateral lower limb oedema were present on examination. Laboratory data showed leucocytosis with left shift. Her chest radiograph revealed right lower lobe opacity (Fig. 1A). She was treated empirically with intravenous (i.v.) ceftriaxone and ciprofloxacin with the impression of right-sided pneumonia.

However, after 2 days of antibiotic treatment, she developed aggravated dyspnoea and severe hypoxaemia. The chest radiograph revealed rapid progression of right lower

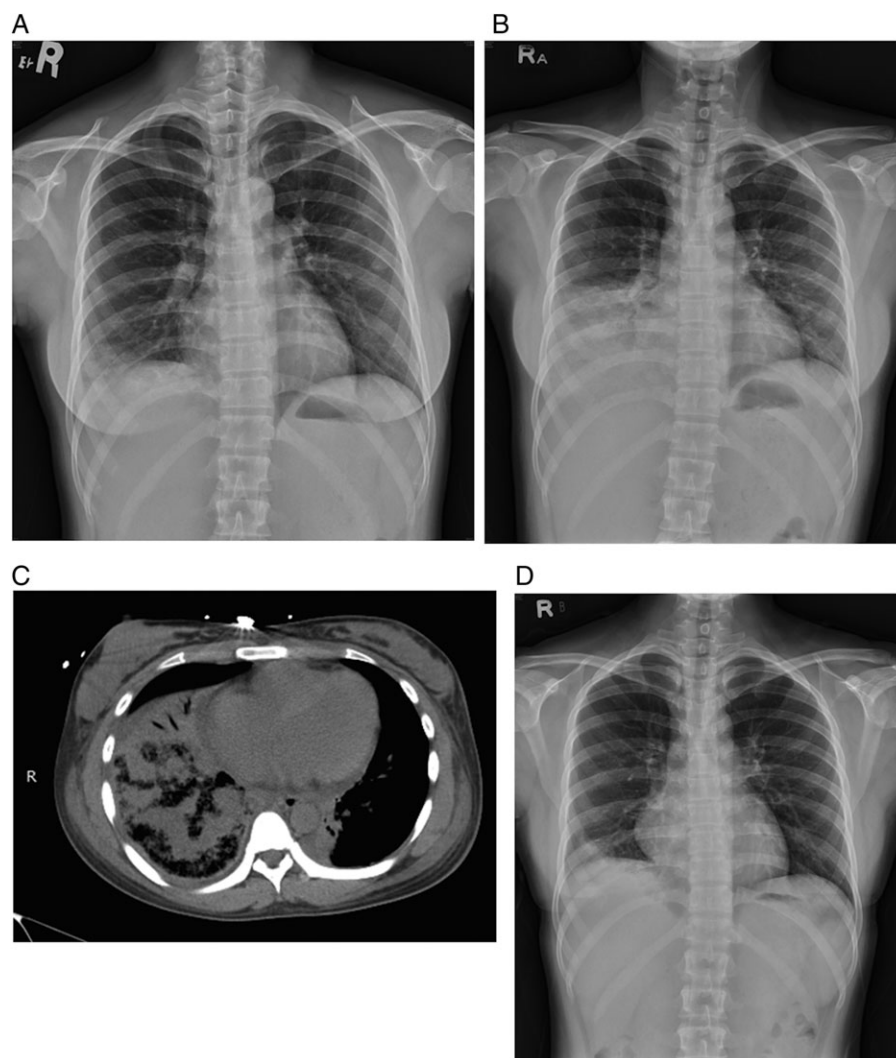


Figure 1. Chest images of the present case. (A) The chest radiograph (CXR) on initial presentation showed right lower lobe consolidation. (B) The CXR 2 days after initial presentation showed rapid progression of right lower lobe consolidation and new infiltrate in left lower lobe. (C) The chest computed tomography (CT) 2 days after initial presentation showed right lower lobe diffuse consolidation and alveolar infiltrate in left lower lobe. (D) The CXR 3 months after treatment showed nearly complete resolution of the lung consolidations.

lobe patchy density (Fig. 1B) and a new infiltrate in left lower lobe. The chest computed tomography (CT) showed right-sided diffuse consolidation and alveolar opacity in left lower lobe (Fig. 1C). Laboratory data revealed anti-ds DNA 23.7 IU/mL (normal <10 IU/mL), C3 64.2 mg/dL (90–180.0 mg/dL), C4 7.0 mg/dL (10.0–40.0 mg/dL), procalcitonin 0.111 ng/mL, C-reactive protein (CRP) 29.02 mg/dL, erythrocyte sedimentation rate (ESR) 111 mm/1 h, and anti-Ro antibody greater than 240 U/mL (upper limit of quantification titres). She underwent CT-guided biopsy of right lower lung and the histopathology revealed chronic inflammation and fibrin deposition in the lung interstitium with reactive pneumocyte and macrophage (CD 68+) infiltrates without visible pathogen on Gram stain and acid-fast stain (Fig. 2).

Subsequently, she exhibited favourable response to plasma exchange, pulse therapy with methylprednisolone 1 g once daily (qd) for 3 days, and MMF 250 mg bd

treatment. The follow-up chest radiograph showed marked improvement and she was discharged uneventfully. Her follow-up chest radiograph after 3 months of treatment (Fig. 1D) showed significant resolution of the lung opacities.

Discussion

SLE presents with a wide spectrum of pulmonary manifestations. It may be caused by lupus lung involvement or may be secondary to other aetiologies. The most common manifestations are pleuritis and pulmonary infections [1]. Other relatively rare presentations are lupus involvement of lung parenchyma, vessels, diaphragm, and airways. Parenchymal involvement includes chronic interstitial lung disease and acute lupus pneumonitis (ALP).

ALP is an uncommon complication of SLE and occurs in 0–14% of the patients [2]. The clinical presentation is

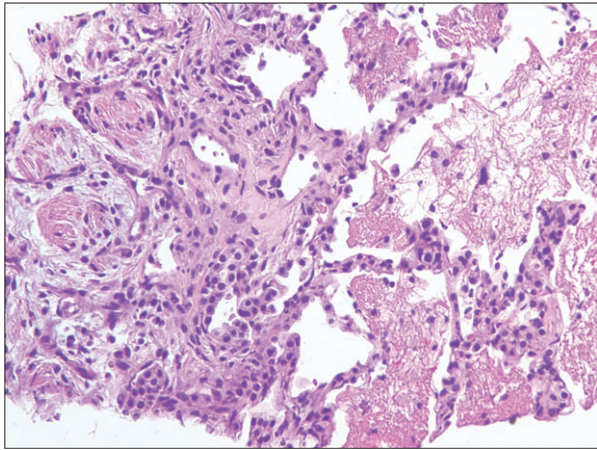


Figure 2. The microscopic findings of the computed tomography (CT)-guided lung biopsy revealed chronic inflammation and fibrin deposition in the lung interstitium with reactive pneumocyte and macrophage infiltrates (haematoxylin–eosin stain, 200X).

acute onset of fever, dyspnoea, cough, pleuritic chest pain, and signs of hypoxaemia. The most characteristic radiographic features are diffuse alveolar filling pattern in bilateral lower lobes coexisting with pleural effusions in around 50% of the cases. However, all the clinical and radiological manifestations are non-specific which makes ALP difficult to diagnose and often mistaken as pneumonia, alveolar haemorrhage, or organizing pneumonia. Although lung biopsy is the main tool for searching pathogens and aetiologies, the pathognomonic pathological finding of ALP has not yet been established. Notably, it has been demonstrated that serum anti-Ro antibodies are elevated more frequently in patients with lupus pneumonitis than in those without [2].

The Ro/SS-A gene exists as a single copy on the short arm of chromosome 19 and the autoantibodies against Ro/SSA autoantigen are frequently present in patients with Sjogren's syndrome and SLE. A previous study first reported an association between anti-Ro antibodies and ALP [3]. Of 63 SLE patients, anti-Ro antibodies were present in 81% of patients with lupus pneumonitis, compared to a frequency of 38% of the entire group [3]. Moreover, another analysis showed that the incidence of anti-Ro antibodies were significantly higher in SLE patients with ALP than in those without (82 vs. 43%, $P < 0.05$) [4]. In compliance with previous studies, this patient presented with a

very high titre of anti-Ro antibody, which highlighted the possibility of ALP. Collectively, this finding supports the view that anti-Ro antibody may play a key role in the lupus pulmonary involvement and may serve as an adjunct diagnostic marker of ALP. Further studies are needed to clarify the correlation between antibody titres and ALP severity and the implication of anti-Ro in the pathogenesis of ALP.

The prognosis of ALP is poor with a mortality rate of 50%. Recommended treatment of ALP is high-dose i.v. methylprednisolone followed by oral corticosteroids and possibly i.v. cyclophosphamide or MMF [5]. Plasmapheresis [6], i.v. immunoglobulins, or rituximab therapy may be considered as an alternative therapy for refractory cases. In conclusion, for SLE patients with pulmonary infiltrates, high degree of clinical suspicion of lupus pneumonitis is required and measurement of anti-Ro antibody may help to make the diagnosis.

Disclosure Statements

Appropriate written informed consent was obtained for publication of this case report and accompanying images.

References

1. Pines A, Kaplinsky N, Olchovsky D, et al. 1985. Pleuropulmonary manifestations of systemic lupus erythematosus: clinical features of its subgroups. Prognostic and therapeutic implications. *Chest* 88:129–135.
2. Cheema GS, and Quismorio FP Jr. 2000. Interstitial lung disease in systemic lupus erythematosus. *Curr. Opin. Pulm. Med.* 6:424–429.
3. Boulware DW, and Hedgpeth MT. 1989. Lupus pneumonitis and anti-SSA (Ro) antibodies. *J. Rheumatol.* 16:479–481.
4. Mochizuki T, Aotsuka S, and Satoh T. 1999. Clinical and laboratory features of lupus patients with complicating pulmonary disease. *Respir. Med.* 93:95–101.
5. Swigris JJ, Olson AL, Fischer A, et al. 2006. Mycophenolate mofetil is safe, well tolerated, and preserves lung function in patients with connective tissue disease-related interstitial lung disease. *Chest* 130:30–36.
6. Isbister JP, Ralston M, Hayes JM, et al. 1981. Fulminant lupus pneumonitis with acute renal failure and RBC aplasia. Successful management with plasmapheresis and immunosuppression. *Arch. Intern. Med.* 141:1081–1083.