
Pathogenesis of bilateral chylothorax after injury of thoracic duct during central venous catheterization

Sir,

I read with interest the article by Saxena *et al.*^[1] and would like to raise the following issues:

1. The authors have described a case of bilateral chylothorax following left-sided central venous catheterization but have not elucidated the pathophysiological mechanism of bilateral chylothorax due to injury to the thoracic duct (which lies on the left side).

It is known that injury to the thoracic duct below T5 results in right-sided chylothorax, between T3 and T5 to bilateral chylothorax and injury above

T3 leads to left-sided chylothorax^[2] (as can be seen from Figure 1). However, in the case described by the authors, bilateral chylothorax resulted from a direct injury to the thoracic duct probably during left internal jugular vein (IJV) cannulation. How can that be explained? Contemporary literature also does not elaborate on to the reason for the same. However, it appears based on reports of injury to lymphatic ducts (albeit in different scenarios such as thoracic duct ligation) that accumulation of chyle bilaterally due to unilateral injury to the thoracic duct may be due to the following reasons:

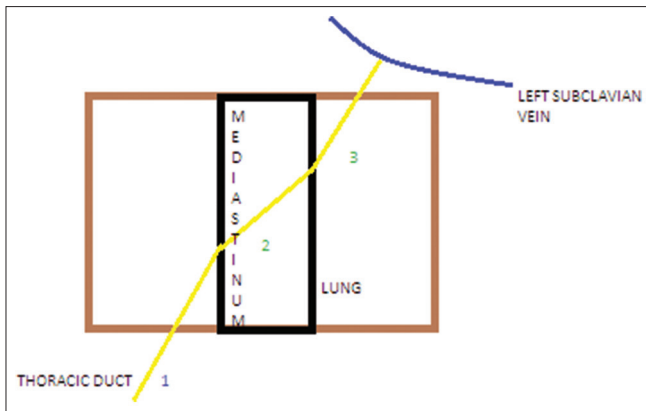


Figure 1: Cartoon depicting the anatomy of the thoracic duct and the divisions on the basis of which unilateral/bilateral chylothorax results

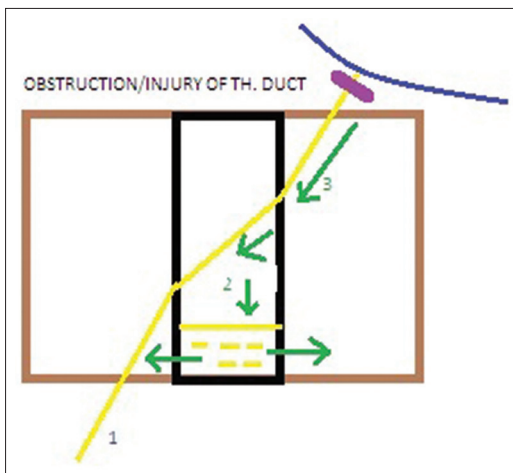


Figure 2: Cartoon of the mechanisms due to which chylothorax occurs after injury to the right lymphatic duct/thoracic duct

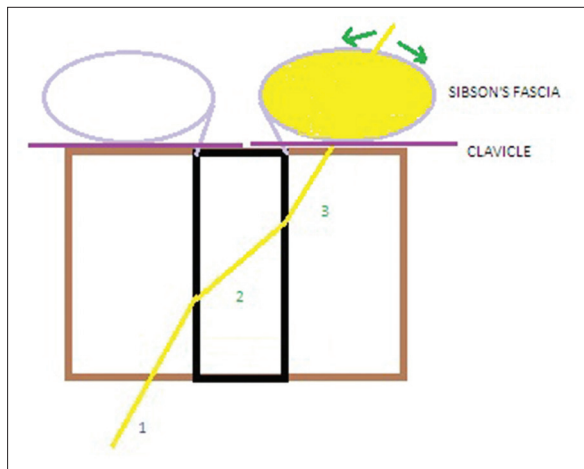


Figure 3: Cartoon showing the mechanism of supraclavicular fossa swelling after injury to the thoracic duct

- a. The leaking chyle sips into the mediastinum probably tracking along the bronchovascular structures^[3]

- b. Following injury to the thoracic duct, there may be occlusion or near-occlusion of the lumen of the thoracic duct (as seen in cases of ligation of the thoracic duct). Now the increasing hydrostatic pressure within the thoracic duct proximal to the occluding site, along with the intrapleural negativity (the pleural space being adjacent to the mediastinum), leads to the transudation of chyle^[3] into the mediastinal space [Figure 2].

Following collection into the mediastinum, the chyle flows into the pleural spaces in the following ways:^[4]

- a. Rupture of the mediastinal pleura due to accumulation of chyle under tension in the mediastinum
 - b. Sipping into the pleural spaces by maceration or backflow through intrapulmonary lymphatics
 - c. Suction of chyle into the pleural spaces by the intrapleural negativity
2. However, systematic literature search by the authors reveal cases where contralateral chylothorax has resulted after injury of the thoracic duct/right lymphatic duct. The explanation of this is less intuitive and cannot be explained by the model proposed above. Is it due to the preferential passage of chyle from the mediastinal space to a particular pleural space owing to pressure differences in the pleural spaces? Animal studies have shown that there may be significant differences in the right and left pleural space pressures.^[5] Can this account for the observations above or is there another explanation behind it?
 3. The authors have described the development of swelling of the supraclavicular fossa following injury to the thoracic duct and have ascribed it to “chyloma” developing “below the pleura” that seems difficult to comprehend. A review of the anatomy of the thoracic duct reveals that this may be due to the collection of chyle above the suprapleural membrane or Sibson’s fascia.

Sibson’s fascia extends from the inner border of the first rib to cover the thoracic inlet. The thoracic duct and the right lymphatic duct traverse the Sibson’s fascia of the left side and the right side, respectively, before emptying into the systemic circulation. Injury to the thoracic duct will lead to collection of chyle limited below by the Sibson’s fascia and hence, will result in a swelling in the supraclavicular fossa [Figure 3]. Development of bilateral supraclavicular fossa swelling has been commonly described, especially in cases of bilateral spontaneous chylothorax probably due to similar reasons.^[6]

Animesh Ray

Department of Pulmonary Critical Care and Sleep Medicine, Fortis
Flt. Lt. Rajan Dhall Hospital, Vasantkunj, New Delhi, India
E-mail: doctoranimeshray@gmail.com

REFERENCES

1. Saxena P, Shankar S, Kumar V, Naithani N. Bilateral chylothorax as a complication of internal jugular vein cannulation. *Lung India* 2015;32:370-4.
2. Bessone LN, Fergusson TB, Burford TH. Chylothorax. *Ann Thorax Surg* 1971;12:527-50.
3. Al-Sebeih K, Sadeghi N, Al-Dahri S. Bilateral chylothorax following neck dissection: A new method of treatment. *Ann Otol Rhinol Laryngol* 2001;110:381-4.
4. Har-El G, Lucente FE. Lymphatic drainage system after left radical neck dissection. *Ann Otol Rhinol Laryngol* 1994;103:46-8.
5. Haneda T, Ikeda S, Tsuiki K, Ishikawa K, Katori R. Regional difference of respiratory changes in pleural pressure between left and right thoraxes in dogs. *Tohoku J Exp Med* 1976;118:311-5.
6. Garcia Restoy E, Bella Cueto F, Espejo Arenas E, Aloy Duch A. Spontaneous bilateral chylothorax: Uniform features of a rare condition. *Eur Respir J* 1988;1:872-3.

Access this article online	
Quick Response Code: 	Website: www.lungindia.com
	DOI: 10.4103/0970-2113.168115