

Esophageal stents in children: Bridge to surgical repair

Bethany J Slater, Ashwin Pimpalwar, David Wesson, Oluyinka Olutoye, Sheena Pimpalwar¹

Division of Pediatric Surgery, Michael E DeBakey Department of Surgery, Baylor College of Medicine and Texas Children's Hospital, ¹Division of Interventional Radiology, Department of Radiology, Texas Children's Hospital, Houston, Texas, USA

Correspondence: Dr. Sheena Pimpalwar, 3765 Drummond Street, Houston, Texas, USA. E-mail: ashwinsheena@hotmail.com

Abstract

Management of complex esophageal problems in children is challenging. We report our experience with the use of esophageal stents in three children with esophageal strictures, leaks, or airway-esophageal fistulae refractory to conventional treatment. The stent played a key role in allowing extubation of a child with a large tracheo-esophageal-pleural fistula and in the resolution of pulmonary infection in a child with esophago-bronchial fistula, both followed by surgery. In the third child, with stricture, stents were complicated with migration, esophageal erosion, and esophago-bronchial fistula. In our experience, esophageal stents were useful mainly as a bridge to definitive surgical repair.

Key words: Broncho-esophageal fistula; esophageal fistula; esophageal leak; esophageal stent; esophageal stricture; tracheo-esophageal fistula

Introduction

Although the use of esophageal stents has been relatively common in adults,^[1,2] for both benign and malignant conditions, their use in children is still evolving.^[3-11] There are a few reports on the use of covered stents in children with caustic strictures or strictures after esophageal atresia repair in which dilatations were unsuccessful.^[3,6,10] In regards to leak or perforation after repair of esophageal atresia or esophageal dilatations, nonoperative management is usually effective. However, there are some cases in which the esophagus fails to close with nonoperative management in which covered stents could be used to manage such perforations.^[5,7] Small size of the pediatric esophagus and the lack of availability of dedicated pediatric esophageal stents [Table 1] makes this process difficult. This report describes the application of esophageal stents in children with esophageal strictures, leaks, or airway-esophageal

fistulae refractory to conventional treatment at a tertiary care children's hospital.

Case Series

Three children aged 7 months, 1 year, and 4 years underwent esophageal stenting at a tertiary care pediatric hospital between December 2012 and November 2016. Institutional review board approval was obtained for this retrospective review.

The stents used in this series were covered nitinol esophageal (Alimaxx-ESTTM) or tracheo-bronchial (AERO[®]) commercially available stents (Merit Medical Systems, Inc., South Jordan, UT, USA). The features of the stent include polyurethane coating to decrease granulation tissue formation, anti-migration struts to decrease migration, and a proximal suture knot to aid removal. All stents

This is an open access journal, and articles are distributed under the terms of the Creative Commons Attribution-NonCommercial-ShareAlike 4.0 License, which allows others to remix, tweak, and build upon the work non-commercially, as long as appropriate credit is given and the new creations are licensed under the identical terms.

For reprints contact: reprints@medknow.com

Cite this article as: Slater BJ, Pimpalwar A, Wesson D, Olutoye O, Pimpalwar S. Esophageal stents in children: Bridge to surgical repair. Indian J Radiol Imaging 2018;28:242-6.

Access this article online	
<p>Quick Response Code:</p> 	<p>Website: www.ijri.org</p> <p>DOI: 10.4103/ijri.IJRI_313_17</p>

Table 1: Characteristics of self-expanding metal esophageal stents available in USA

Esophageal Stent	Material	Diameter (mm)	Length (cm)	Advantages	Disadvantages
Merit Medical Endotek®					
Alimaxx-ES™ Esophageal stent (fully covered)	Laser cut nitinol, polyurethane, silicone	12-22	7-12	No stent foreshortening or elongation, polyurethane coating decreases tissue ingrowth, silicone lining provides smooth inner lumen, anti-migration struts reduce stent migration, purse-string design of the proximal suture knot helps with repositioning and removal	Stent cannot be reconstrained once deployment is initiated.
EndoMAXX™ Esophageal stent (fully covered)	Laser cut nitinol, silicone	19-23	7-15	In addition to advantages of Alimaxx-ES™, flared ends reduce migration, proximal and distal metal suture allow stent repositioning	Stent cannot be reconstrained once deployment is initiated
Boston Scientific					
WallFlex™ Esophageal stent (partially and fully covered)	Braided nitinol, silicone	18,23	10,12,15	Silicone coating decreases tissue ingrowth, flared ends reduce migration, proximal polyester suture helps stent removal, reconstrainable for up to 75% deployment	Stent foreshortening
Ultraflex™ Esophageal NG stent (covered and non-covered)	Knitted nitinol, polyurethane	18,23	7-15	Proximal flare to reduce migration, sutured loop for stent repositioning, available as proximal and distal release systems	
Cook Medical					
Evolution® Esophageal Controlled-Release stent (partially and fully covered)	Woven nitinol, silicone	18,20	8-15	Silicone coating decreases tissue ingrowth, flared ends reduce migration, lasso for stent repositioning, reconstrainable for up to 50% deployment	Stent foreshortening

were placed in the interventional radiology suite under general anesthesia with flexible endoscopy and fluoroscopy guidance using a flexible over-the-wire delivery system. The esophageal diameter was estimated using previous contrast study and endoscopic assessment, and the stent diameter was oversized by approximately 2 mm. The length of the stent was selected to provide at least 2 cm overlap on either side of the leak but without extension into the upper or lower gastrointestinal sphincter. After stent deployment, an esophagogram was performed to document stent position and absence of extravasation. Follow-up chest radiographs were performed as needed during follow-up.

Case 1

A 1-year-old boy developed a large acquired tracheo-esophageal fistula [Figure 1A] after endoscopic removal of a swallowed foreign body. This was surgically repaired but complicated postoperatively with leak from the esophageal anastomosis and tracheo-esophago-pleural fistula. This led to tension pneumothorax for which multiple chest tubes were placed. The patient however continued to have difficulty with ventilation and could not be extubated. A 12 mm × 7 cm Alimaxx-ES™ stent was placed in the esophagus [Figure 1B] to exclude the large fistula. This allowed the patient to be weaned off the ventilator and extubated on postoperative day 8. On postoperative day 15, however, the stent migrated proximally [Figure 1C] and was removed. Thereafter, the patient had successful surgical repair of the partially healed fistula.

Case 2

A 4-year-old boy had congenital esophageal atresia and distal tracheo-esophageal fistula repaired at an outside hospital.

Investigation of recurrent pneumonia led to the finding of an acquired esophago-bronchial fistula [Figure 2A]. An Amplatzer™ Vascular Plug II (St. Jude Medical, St. Paul, MN, USA) was placed within the fistula along with a 16 mm × 7 cm Alimaxx-ES™ esophageal stent [Figure 2B] to completely exclude the fistula. The stent was removed electively at 8 weeks and esophagogram immediately post removal was normal. However, a repeat study two weeks later prior to initiation of oral feeding showed persistent fistula. During this period, the patient had improved symptomatically and all signs of infection had cleared. The patient underwent successful surgical repair with no recurrence of the fistula at the 3-year follow-up.

Case 3

A 7-month-old girl with Trisomy 21, long-gap esophageal atresia, duodenal atresia, and Hirschsprung's disease underwent delayed primary esophageal anastomosis at 4 months of age during which the esophageal ends were tacked together without fashioning an anastomosis because of excessive tension. One month later, the ends of the esophagus were reapproximated over a trans-anastomotic tube. This was complicated by contained leak and anastomotic stricture that did not respond to repeated dilatations [Figure 3A]. A 12 mm × 4 cm AERO® tracheo-bronchial stent was placed across the stricture and leak [Figure 3B]. The AERO® stent was selected because the shortest available Alimaxx-ES™ esophageal stent was 7 cm that would have extended into the stomach. Distal migration of the AERO® stent after one week was managed with telescoping a 14 mm × 4 cm AERO® stent within the previous stent. Over the ensuing 4 weeks, the coaxial stents not only migrated distally but also eroded

into the right lateral esophageal wall creating a large diverticulum [Figure 3C]. This made removal of the stent challenging by obscuring a large part of the upper border of the stent and its suture knot. Over the following 2 weeks, the diverticulum progressed to a esophago-bronchial fistula and there was recurrence of the stricture. The patient was

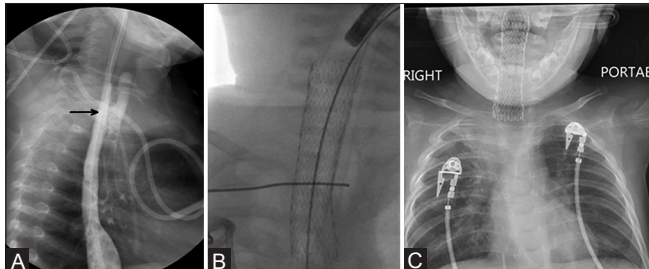


Figure 1 (A-C): Case 1: M/1 year with large acquired tracheo-esophageal fistula (TEF) after foreign body removal. (A) Esophagogram shows large TEF (black arrow) in the upper third of the esophagus. (B) 12 mm × 7 cm Alimaxx-ES™ esophageal stent placed across TEF. (C) Proximal migration of stent on day 15

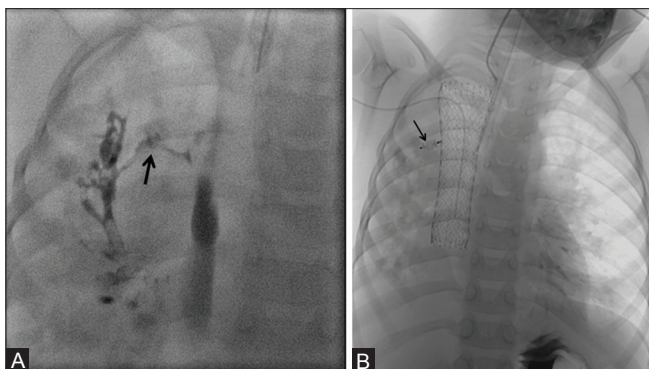


Figure 2 (A and B): Case 2: M/4 year with esophageal atresia and distal TEF post surgical repair. (A) Esophagogram shows acquired esophago-bronchial fistula (black arrow). (B) Placement of 4 mm Amplatzer™ Vascular plug II (black arrow) and 16 mm × 7 cm Alimaxx-ES™ esophageal stent to occlude fistula

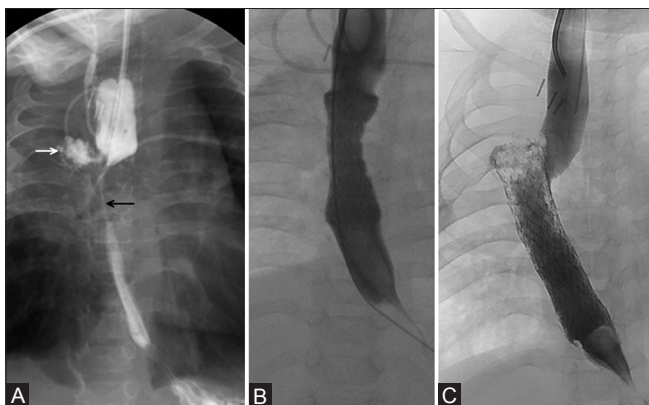


Figure 3 (A-C): Case 3: F/7 month with long gap esophageal atresia post repair (A). Esophagogram shows high grade anastomotic stricture in the mid esophagus (black arrow) associated with a contained leak (white arrow). (B) Placement of a 12 mm × 4 cm AERO® tracheo-bronchial stent across stricture. (C) Distal migration and erosion of stent into right lateral esophageal wall

not a candidate for colon interposition given Hirschsprung's disease and had frozen chest from repeated thoracotomies and soiling, therefore, a proximal esophageal diversion was performed. The patient, however, succumbed to progressive respiratory deterioration and aspiration pneumonia from the persistent esophago-bronchial fistula.

Discussion

Esophageal leaks and strictures in children can occur after a variety of procedures including repair of esophageal atresia, dilatation of stricture, or ingestion of caustic agents. Esophageal anastomotic leaks and iatrogenic esophageal perforations often heal over time with nonoperative management. However, the management of complex esophageal problems that do not heal spontaneously or respond to dilatations is challenging.

The use of esophageal stents in children is evolving and has mostly been described for treatment of strictures refractory to dilatation.^[3,4,6,10,12] The advent of covered retrievable stents led to their utilization particularly for caustic strictures as well as for strictures following esophageal atresia repair with high success rates. Zhang *et al.* described eight patients with corrosive esophageal stenosis who underwent placement of covered retrievable nitinol stents.^[3] All patients were able to eat solid food without dysphagia after stent removal. Rollins *et al.* reported a series of three patients with persistent esophageal leaks in which covered nitinol stents were successfully used,^[5] and patients were able to receive nutrition orally with the stents in place. They concluded that the use of esophageal stents should be considered as an effective option for these cases. In a large pediatric experience of esophageal stenting, Manfredi *et al.* concluded that esophageal stents proved more useful in the management of esophageal perforations than recalcitrant anastomotic strictures.^[8] In the current report, esophageal stents were useful mainly as a bridge to definitive surgical repair. In case 1, the stent played a critical role in controlling massive leak of tidal volume through the tracheo-esophago-pleural fistula. This made it possible to extubate the child but the stent migrated prematurely and required surgical management of the residual fistula. In case 2, the stent temporarily sealed the esophago-bronchial fistula allowing the child to recover from severe pneumonia and systemic illness. The child was then a better candidate for surgical repair. In both these cases, however, the stent could only provide partial or temporary healing of the perforation and surgical repair was subsequently required.

One of the main complications of esophageal stents is stent migration. Migration has been reported in 0–29% of pediatric patients^[12] and 30–60% in the adult literature.^[4] The Alimaxx-ES™ esophageal and AERO® tracheo-bronchial stents have anti-migration struts that are designed to decrease the risk of migration. The struts

are oriented such that they counter distal migration of the esophageal stent and proximal migration of the tracheo-bronchial stent. It has also been reported that stents placed in the upper and lower esophagus are more likely to migrate and more difficult to manage.^[13] Stent migration was a significant problem in case 1 and case 3 in the current series. In case 1, although an esophageal stent with distal anti-migration struts was used, placement in the upper esophagus in proximity to the cricopharyngeal sphincter was most likely responsible for its early proximal migration. In case 3, distal migration occurred despite stent revision. In this patient, a 4-cm long AERO[®] tracheo-bronchial stent was placed initially because the commercially available esophageal stents were too long for this 7-month-old child. The tracheo-bronchial stents have struts oriented to prevent proximal migration, but do not prevent distal migration. In addition, a high-grade anastomotic stricture with a tortuous lumen in this child also contributed to stent migration.

Esophageal perforation secondary to esophageal stents has been reported as one of the delayed complications.^[14-16] Manfredi *et al.* reported esophageal perforation and migration of an esophageal stent into the pleural space within two weeks of placement and recommended close monitoring of all children undergoing esophageal stenting.^[8] In case 3, angulation of the rigid AERO[®] stent into the right lateral wall of the esophagus resulted in erosion of the esophagus and formation of a large diverticulum which subsequently progressed to esophago-bronchial fistula. The AERO[®] stent is made from a laser cut solid nitinol tube which makes its structure rigid, straightens the natural esophageal curves, and causes pressure necrosis of the esophageal wall.

Esophageal stenting in children presents several technical challenges. In infants and smaller sized children, the commercially available esophageal stents may be too long. In these patients, AERO[®] tracheo-bronchial stents available in shorter lengths may be utilized cautiously. The size mismatch and rigidity of the stents also makes the esophagus vulnerable to pressure necrosis, for which close monitoring and timely removal is suggested. There is certainly a need for development of smaller sizes (both length and diameter) of stents as well as more flexible stents which conform to the natural curvatures of the pediatric esophagus.

In conclusion, esophageal stents may serve as a useful tool in the management of children with esophageal leaks and acquired airway-esophageal fistulae refractory to conventional treatment. In this case series, the stent allowed for time to control ventilation and resolve infection, acting as a bridge to definitive surgical repair. The small size and tortuosity of the pediatric esophagus and the limited availability of commercial esophageal stents designed

for the pediatric esophagus are challenges in this field. Development of esophageal stents with improved flexibility, anti-migration features and smaller diameters and lengths could further increase their successful application in children.

Declaration of patient consent

The authors certify that they have obtained all appropriate patient consent forms. In the form the patient has given her consent for her images and other clinical information to be reported in the journal. The patient understands that name and initial will not be published and due efforts will be made to conceal identity, but anonymity cannot be guaranteed.

Financial support and sponsorship

Nil.

Conflicts of interest

There are no conflicts of interest.

References

1. Wilson JL, Louie BE, Farivar AS, Vallières E, Aye RW. Fully Covered Self-Expanding Metal Stents Are Effective For Benign Esophagogastric Disruptions and Strictures. *J Gastrointest Surg* 2013;17:2045-50.
2. van Halsema EE, van Hooft JE. Clinical outcomes of self-expandable stent placement for benign esophageal diseases: A pooled analysis of the literature. *World J Gastrointest Endosc* 2015;7:135-53.
3. Zhang C, Yu JM, Fan GP, Shi CR, Yu SY, Wang HP, *et al.* The use of a retrievable self-expanding stent in treating childhood benign esophageal strictures. *J Pediatr Surg* 2005;40:501-4.
4. Best C, Sudel B, Foker JE, Krosch TCK, Dietz C, Khan KM. Esophageal stenting in children: Indications, application, effectiveness, and complications. *Gastrointest Endosc* 2009;70:1248-53.
5. Rollins MD, Barnhart DC. Treatment of persistent esophageal leaks in children with removable, covered stents. *J Pediatr Surg* 2012;47:1843-7.
6. Broto J, Asensio M, Vernet JMG. Results of a New Technique in the Treatment of Severe Esophag. *J Pediatr Gastroenterol Nutr* 2003;37:203-6.
7. Ahmad A, Wong LM, Song K, Absah I. Esophageal stent placement as a therapeutic option for iatrogenic esophageal perforation in children. *Avicenna J Med* 2016;6:51-3.
8. Manfredi MA, Jennings RW, Anjum MW, Hamilton TE, Smithers CJ, Lightdale JR. Externally removable stents in the treatment of benign recalcitrant strictures and esophageal perforations in pediatric patients with esophageal atresia. *Gastrointest Endosc* 2014;80:246-52.
9. Lange B, Kubiak R, Wessel LM, Kahler G. Use of fully covered self-expandable metal stents for benign esophageal disorders in children. *J Laparoendosc Adv Surg Tech A* 2015;25:335-41.
10. Gebrail R. Successful use of esophageal stent placement to treat a postoperative esophageal stricture in a toddler. *ACG Case Reports J* 2014;2:61-3.
11. Zhang J, Ren L, Huo J, Zhu Z, Liu D. The use of retrievable fully covered self-expanding metal stent in refractory postoperative restenosis of benign esophageal stricture in children. *J Pediatr Surg* 2013;48:2235-40.

12. Kramer RE, Quiros JA. Esophageal stents for severe strictures in young children: Experience, benefits, and risk. *Curr Gastroenterol Rep* 2010;12:203-10.
13. Hindy P, Hong J, Lam-Tsai Y, Gress F. A comprehensive review of esophageal stents. *Clin Adv Hematol Oncol* 2012;10:526-34.
14. Katsanos K, Sabharwal T, Koletsis E, Fotiadis N, Roy-Choudhury S, Dougenis D, *et al.* Direct Erosion and Prolapse of Esophageal Stents into the Tracheobronchial Tree Leading to Life-threatening Airway Compromise. *J Vasc Interv Radiol* 2009;20:1491-5.
15. Wang MQ, Sze DY, Wang ZP, Wang ZQ, Gao YA, Dake MD. Delayed complications after esophageal stent placement for treatment of malignant esophageal obstructions and esophagorespiratory fistulas. *J Vasc Interv Radiol* 2001;12:465-74.
16. Khan S, George N, Tharian B. Extraluminal migration of an esophageal metal stent causing splenic injury. *Endoscopy* 2016;48:E326.