

Available online at [www.sciencedirect.com](http://www.sciencedirect.com)

ScienceDirect

journal homepage: [www.elsevier.com/locate/radcr](http://www.elsevier.com/locate/radcr)

## Case Report

# Perforated adenocarcinoma of the colon within a scrotal hernia imaged by CT: case report and literature review

Malene Roland Vils Pedersen, MSc, PhD<sup>a,b,c,\*</sup>, Claus Dam, MD<sup>a,c</sup>,  
Søren Rafael Rafaelsen, MD, DMSc<sup>a,b,c</sup>

<sup>a</sup> Department of Radiology, Vejle Hospital, Beriderbakken 4, DK 7100, Vejle, Denmark

<sup>b</sup> Institute for regional Health research, University of Southern Denmark, Odense, Denmark

<sup>c</sup> Danish Colorectal Cancer Center South, Vejle Hospital, Vejle, Denmark

## ARTICLE INFO

## Article history:

Received 3 June 2019

Revised 5 August 2019

Accepted 9 August 2019

Available online 6 September 2019

## Keywords:

Colon cancer

Scrotal hernia

CT

## ABSTRACT

Colorectal cancer is one of the most common cancers in the developed countries, and colon cancer is well documented. However, it is very rare for a primary colon cancer to exist in a scrotal hernia, and even rarer for the scrotal hernia to perforate. Here, we describe an unusual case where a 75-year-old patient with a colon tumor that perforated in a scrotal hernia. The teaching point is to highlight the computed tomography scan imaging characteristics of this rare finding in patients with both abdominal and scrotal pain.

© 2019 The Authors. Published by Elsevier Inc. on behalf of University of Washington.

This is an open access article under the CC BY-NC-ND license.

(<http://creativecommons.org/licenses/by-nc-nd/4.0/>)

## Introduction

Colorectal cancer is one of the most common types of cancer in industrialized countries and is associated with significant morbidity and mortality [1]. In the United States, new cases of colon cancer are expected to be diagnosed in 51,690 men and 49,730 women in 2019 [2]. Incidence of colorectal cancer is 40 per 100,000 in some countries in Europe [3]. First line of treatment for patients with assumed curable colon cancer is surgery. Early diagnosis, correct staging, and treatment are of great importance for improving prognosis.

Inguinal hernia is a common problem in adults, and obstructions and torsion are well-known complications in adults. The prevalence for inguinal hernia is 4% for adults age above 45 years [4]. Inguinal hernias are seen as a lump in the groin that often goes away when the patient is lying down. The symptoms are typically mild, and normally patients have no pain. Severe complications for example torsion or strangulations are rare.

The combination of colorectal cancer and inguinal hernia is uncommon. A recent review found less than 40 reported cases, and establish that complications is often seen in these cases, such as perforation or incarceration [5]. Only a few cases

Funding: No funding.

Patient consent for publication: Obtained.

\* Corresponding author.

E-mail addresses: [malene.roland.vils.pedersen@rsyd.dk](mailto:malene.roland.vils.pedersen@rsyd.dk) (M.R.V. Pedersen), [claus.dam@rsyd.dk](mailto:claus.dam@rsyd.dk) (C. Dam), [soeren.rafael.rafaelsen@rsyd.dk](mailto:soeren.rafael.rafaelsen@rsyd.dk) (S.R. Rafaelsen).

<https://doi.org/10.1016/j.radcr.2019.08.009>

1930-0433/© 2019 The Authors. Published by Elsevier Inc. on behalf of University of Washington. This is an open access article under the CC BY-NC-ND license. (<http://creativecommons.org/licenses/by-nc-nd/4.0/>)

of colon cancer and inguinoscrotal hernias have been reported in the literature [5–14].

We present a rare case of inguinoscrotal hernia with colon carcinoma presenting initially as abdominal pain. Included is a literature review with focus on inguinoscrotal hernias.

## Case report

A 75-year-old man was admitted to a local hospital suffering of severe abdominal pain. No previous cancer history.

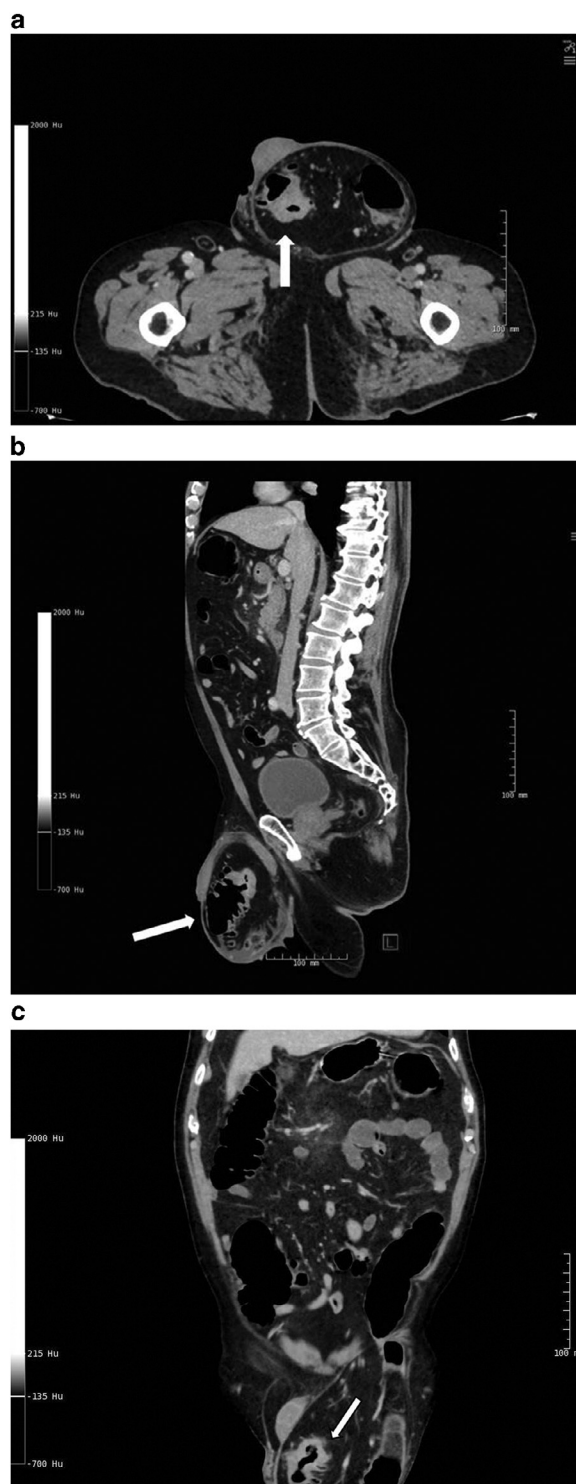
A contrast-enhanced computed tomography (CT) scan of the abdomen and pelvis was performed with both arterial and delayed phases and reported a left scrotal hernia without serious findings. No oral or rectal contrast was used. The pain was reduced due to a nasogastric tube. The patients received antibiotics, as there was a suspicion of inflammation of the pancreas. The patient refused hernia operation and was then discharged from the local hospital.

The patient complaints were getting worse, and a week later he was readmitted to the same local hospital with complains of intensified abdominal pain. A second contrast-enhanced abdominal CT was performed with both arterial and delayed phases, showing ileus and a left scrotal hernia. No oral or rectal contrast was used. The left scrotum contained a perforated sigmoid tumor, fluid, and a small amount of air. The air in the scrotum was caused by the perforation of the sigmoid tumor. The patient was then referred and admitted to the nearest department of oncological surgery at the Lillebaelt Hospital. The 2 hospitals are placed 100 km apart. The patient became septic and was diagnosed with clinical ileus. Acute abdominal surgery was performed the next day where the sigmoid tumor was resected and an orchiectomy was a prerequisite to ensure a radical surgery.

The tumor measured  $2.8 \times 2.8 \times 4.6$  cm and was located in the sigmoid part of the colon. In total 50 cm of the colon including the tumor was removed. The colon appeared dark and edematous with chronic and acute inflammation. No polyps were found in the colon. A total of 27 lymph nodes were surgical removed, one of the lymph node was a metastasis. Histopathology showed a colonic adenocarcinoma of the sigmoid with down growth of 6 mm in muscularis propria and perforation (pT3, N1, and M0).

An orchiectomy of the left testicle was performed. The testicle measured  $40 \times 40 \times 35$  mm. The left testicle showed no malignancy. The hernia showed sign of infection and was after the orchiectomy repaired.

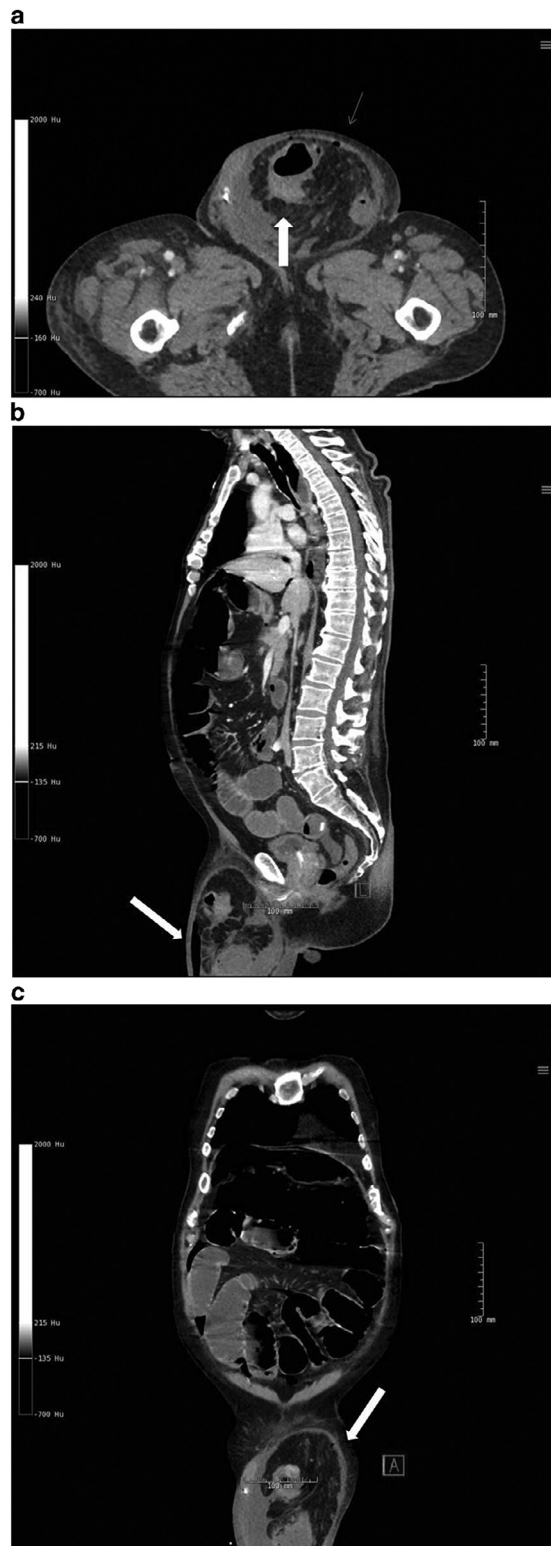The patient's 2 abdominal CT scans from the local hospital were electronically sent using the 2 hospitals Picture Archiving and Communication System. The CT scans were sent to the Lillebaelt cancer hospital simultaneously with the patient's hospitalization. The scans were retrospectively examined by the multidisciplinary team, which included a pathologist, radiologist, oncologist, and a surgeon. The multidisciplinary team reviewed the 2 scans; in order to stage the colon tumor, plan surgery and the following treatment. The multidisciplinary team coordinated the orchiectomy and the colon surgery from the second CT scan. The colonic tumor



**Fig. 1** – First CT scan of the abdomen including an axial (a), sagittal (b), and coronal (c) image. White arrows show the pt3 tumor placed inside the left side of the scrotum

within the scrotal hernia was then retrospectively noticed at the first abdominal CT scan (Figs. 1 and 2).

After a week, the patient was discharged from the hospital. The patient is receiving neoadjuvant chemotherapy treatment. The follow-up revealed no distant metastases and the patient received adjuvant chemotherapy.



**Fig. 2** – Second CT scan of the abdomen including an axial (a), sagittal (b), and coronal (c) image. The a axial image shows the tumor within the scrotum, the small arrows shows bubbles of free air. Notice the sagittal b image where the arrow is pointing toward free air in the scrotum, due to perforation of the sigmoid wall. The white arrow in image c shows the sigmoid tumor in the scrotum

## Discussion

In the literature, there has been reported up to 38 cases on primary colon cancer and hernia [5]. Only a handful of cases on colon cancer within inguinoscrotal hernia have been reported. A literature search of the 1900-2019 Pubmed database, entering “colon cancer” AND “scrotal hernia” as keywords, identified a total of 15 papers. After excluding papers with no true inguinoscrotal hernia, no abstracts available, or non-English language papers, we found a total of 7 case reports with true colon cancer inguinoscrotal hernia present. Hereafter, we used the “snowball” method to search for additional cases of inguinoscrotal hernia and colon cancer, we found 4 extra case reports (Table 1).

In all 11 reported cases, the patients were elderly (mean age 76.3 years, range from 66 to 84 years), and in 9 cases, the inguinoscrotal hernia was left sided. In 3 of the cases, the patient underwent orchiectomy, and in 5 cases, it was not reported in the study.

Inguinal hernia is a common condition, and the prevalence for inguinal hernia is 4% for adults aged above 45 years [4], and males have lifetime risk of developing a groin hernia of 27% [15]. Very few cases have reported of malignant tumors in inguinal and scrotal hernias. If the patients present risk symptoms, for example, weight loss, rectal bleeding, abdominal pain; it is important that the radiologist is aware of the possibility of a colon tumor in an inguinoscrotal hernia.

A perforated colorectal carcinoma is generally reported having poor prognosis, since patients have a higher mortality rate because of complication after operation (eg, sepsis or peritonitis). In this case report, the patient had a contained perforated colon tumor stage pt3 with 1 lymph node metastasis. It is of importance that the patient had a contained perforation, which has a more positive outcome compared to a free tumor perforation. In a retrospective case control study patients with free perforated colon cancer were compared to contained perforations. The patients with free perforated colon cancer had an overall survival of 24% compared to 62% in patients with contained perforation ( $P < .003$ ) [16].

Furthermore, insufficient diagnosis of scrotal hernia may result in serious scrotal outcome such as orchiectomy of the testicles. The spermatic cord can be stretched as a result of a long-lasting hernia. Additionally, if the spermatic cord is stretched it will most likely cause testicular atrophy with a high risk of orchiectomy.

A multidisciplinary team conference is of great importance. In our case, the patients’ colon tumor within an inguinoscrotal hernia was missed at the patients first CT scan, and the patients’ symptoms became worse. The patients’ second abdominal CT scan was discussed on a multidisciplinary team conference, and the perforated colon tumor was diagnosed within the inguinoscrotal hernia. The benefits of multidisciplinary teams are to, for example, discuss imaging, and plan treatment strategies, allowing individual evaluation for the patient. Also, multidisciplinary team conference allows consensus about complex cases within the multidisciplinary teams members [17].

**Table 1 – Overview of included 11 cases with Inguinoscrotal hernia and colon cancer.**

Author	Location	Inguinoscrotal hernia (Left/Right)	Cancer type	Stage	Loss of testicle
Chern, 2018 [5]	Ascending colon	Right	Adenocarcinoma	T4aN2aM0	No
Sharma, 2017 [6]	Cecum	Right	Dukes stage B	T3N0V1M0	NR <sup>1</sup>
Ota, 2015 [7]	Transverse colon	Left	Unknown	NR	No
Daly, 2013 [8]	Sigmoid	Left	Adenocarcinoma	NR	Yes
Marsden, 2014 [12]	cecal	Bilateral	Adenocarcinoma	pT3N2M0	NR
Tan, 2013 [10]	Sigmoid	Left	Adenocarcinoma	T4b,N2,M0	NR
Ko, 2008 [9]	Sigmoid	Left	Adenocarcinoma	NR	NR
Slater, 2008 [11]	Sigmoid	Left	Carcinoma, Dukes stage C1	T3N1MX	Yes, left
Slater, 2008 [11]	Sigmoid	Left	Adenocarcinoma, Dukes stage C2	T4N2MX	Yes left
Kouraklis, 2003 [13]	Sigmoid	Left	Adenocarcinoma	NR	No
Cervinka, 2003 [14]	NR	Left	Adenocarcinoma	T?N0,MX <sup>2</sup>	NR

NR = not reported.

<sup>1</sup> (Excised of the right spermatic cord).

<sup>2</sup> Tumor perforated to the serosal surface.

## Learning points

1. The case presented illustrates a colonic tumor within a scrotal hernia, and it is important to take a close look at scrotal hernias.
2. Always compare new examinations with previous radiology investigations.
3. Consider ultrasonography of the scrotum in findings of CT scrotal hernia.

## Conclusion

Patients presenting with sigmoid adenocarcinomas within scrotal hernias are very rare, and perforation extremely rare, but may have a potential disastrous consequences. The radiologist should be aware of this condition to ensure a preoperative diagnosis.

## Contributors

MRP wrote first draft with support from SRR, and all authors have reviewed and agreed upon the manuscript content.

## REFERENCES

- [1] Ferlay J, Soerjomataram I, Dikshit R, Eser S, Mathers C, Rebelo M, et al. Cancer incidence and mortality worldwide: sources, methods and major patterns in GLOBOCAN 2012. *Int J Cancer* 2015;136:E359–86.
- [2] Siegel R, Miller K, Jemal A. Cancer statistics, 2019. *CA Cancer J Clin* 2019;69:7–34. doi:10.3322/caac.21551.
- [3] Arnold M, Sierra M, Laversanne M, Soerjomataram I, Jemal A, Bray F. Global patterns and trends in colorectal cancer incidence and mortality. *Gut*. 2017;66:683–91.
- [4] Jenkins J, O'Dwyer P. Inguinal hernias. *BMJ* 2008;336:269–72.
- [5] Chern T, Kwang Y, Perera D. A rare case of ascending colon adenocarcinoma incarcerated in an inguinoscrotal hernia: case report and literature review. *Surg Case Reports* 2018;4(48). doi:10.1186/s40792-018-0457-9.
- [6] Sharma S. Inguinoscrotal hernia of a caecal adenocarcinoma. *BMJ Case Rep* 2017 pii:bcr-2017-222547.
- [7] Ota S, Noguchi T, Takao T, Sakamoto T, Kanie Y, Omae K, et al. An incarcerated colon inguinal hernia that perforated into the scrotum and exhibited an air-fluid level. *Case Rep Med* 2015. doi:10.1155/2015/105183.
- [8] Daly D, Filgate R, Muhlmann M. Incarcerated inguinoscrotal hernia containing sigmoid colon cancer. *ANZ J Surg* 2018;88:E550–1.
- [9] Ko K, Yu C, Kao C, Tsai S, Huang G, Chang W. Perforated sigmoid colon cancer within an irreducible inguinal hernia: a case report. *Korean J Radiol* 2010;11:231–3.
- [10] Tan A, Taylor G, Ahmed T. Perforated sigmoid colon carcinoma in an irreducible inguinoscrotal hernia. *Ann R Coll Surg Engl* 2013;95:125–6.
- [11] Slater R, Amatya U, Shorthouse A. Colonic carcinoma presenting as strangulated inguinal hernia: report of two cases and review of the literature. *Tech Coloproctol* 2008;12:255–8.
- [12] Marsden M, Curtis N, McGee S, Bracey E, Branagan G, Sleight S. Intrasaccular caecal adenocarcinoma presenting as enlarging right inguinoscrotal hernia. *Int J Surg Case Rep* 2014;5:643–5.
- [13] Kouraklis G, Kouskos E, Glinavou A, Raftopoulos J, Karatzas G. Perforated carcinoma of the sigmoid colon in an incarcerated inguinal hernia: report of a case. *Surg Today* 2003;33:707–8.
- [14] Cervinka A, Inaba K, Wall W. Surgical images: soft tissue obstructing colon carcinoma in an irreducible scrotal hernia. *Can J Surg* 2003;46:359–60.
- [15] Kingsnorth A, Leblanc K. Hernias: inguinal and incisional. *Lancet* 2003;362:1561–71.
- [16] Zielinski M, Merchea A, Heller S, You Y. Emergency management of perforated colon cancers: how aggressive should we be? *J Gastrointest Surg* 2011;15:2232–8.
- [17] Kontovounisios C, Tan E, Pawa N, Brown G, Tait D, Cunningham D, et al. The selection process can improve the outcome in locally advanced and recurrent colorectal cancer: activity and results of a dedicated multidisciplinary colorectal cancer centre. *Colorectal Dis* 2017;19:331–8.