

Laparoscopic Anterior Resection: New Anastomosis Technique in a Pig Model

Abdulkadir Bedirli, MD, Deniz Yucel, MD, Burcu Ekim, VetMed

ABSTRACT

Background and Objectives: Bowel anastomosis after anterior resection is one of the most difficult tasks to perform during laparoscopic colorectal surgery. This study aims to evaluate a new feasible and safe intracorporeal anastomosis technique after laparoscopic left-sided colon or rectum resection in a pig model.

Methods: The technique was evaluated in 5 pigs. The OrVil device (Covidien, Mansfield, Massachusetts) was inserted into the anus and advanced proximally to the rectum. A 0.5-cm incision was made in the sigmoid colon, and the 2 sutures attached to its delivery tube were cut. After the delivery tube was evacuated through the anus, the tip of the anvil was removed through the perforation. The sigmoid colon was transected just distal to the perforation with an endoscopic linear stapler. The rectosigmoid segment to be resected was removed through the anus with a grasper, and distal transection was performed. A 25-mm circular stapler was inserted and combined with the anvil, and end-to-side intracorporeal anastomosis was then performed.

Results: We performed the technique in 5 pigs. Anastomosis required an average of 12 minutes. We observed that the proximal and distal donuts were completely removed in all pigs. No anastomotic air leakage was observed in any of the animals.

Conclusion: This study shows the efficacy and safety of intracorporeal anastomosis with the OrVil device after laparoscopic anterior resection.

Key Words: Laparoscopic anterior resection, Anastomosis, Pig model, OrVil.

Department of General Surgery, Gazi University Medical Faculty, Ankara, Turkey (Drs. Bedirli, Yucel).

Gazi University Laparoscopic Surgery Education and Research Center, Ankara, Turkey (Dr. Ekim).

Address correspondence to: Abdulkadir Bedirli, MD, Department of General Surgery, Gazi University Medical Faculty, Ankara, Turkey. Telephone: +90 312 2025724, Fax: +90 312 2150494, E-mail: bedirli@gazi.edu.tr

DOI: 10.4293/JSLS.2014.00345

© 2014 by JSLS, Journal of the Society of Laparoendoscopic Surgeons. Published by the Society of Laparoendoscopic Surgeons, Inc.

INTRODUCTION

Laparoscopic colorectal surgery requires a high level of surgical skill. Experience with benign colorectal disorders and technologic advances have led to the frequent use of laparoscopic colorectal methods for the treatment of malignant diseases.¹⁻³ New methods of dissection, resection, specimen removal, and anastomosis are still being developed because laparoscopic colorectal surgery is one of the most advantageous techniques available.

Laparoscopic anterior resection is a common procedure used for the treatment of rectosigmoid colon cancers.⁴ Intracorporeal anastomosis, including the double-stapling technique, is often preferred during resection and anastomosis.⁵ However, this technique requires removal of the colon from the abdomen to facilitate insertion of the circular stapler's anvil into the proximal colon, which leads to mobilization of the splenic flexure. Intracorporeal anvil placement and hand-sewn purse-string suturing are time-consuming and challenging procedures.

We report, for the first time, the use of a circular stapler's anvil (OrVil; Covidien, Mansfield, Massachusetts)—exclusively designed for upper gastrointestinal anastomosis—for anastomosis after segmental rectosigmoid resection in pigs. We aim to introduce a new feasible and safe intracorporeal anastomosis technique after laparoscopic left-sided colon or rectum resection that no longer requires purse-string sutures.

METHODS

This study was performed at the Gazi University Center for Research and Application of Laparoscopic Surgery after we obtained approval from the Gazi University Animal Care and Use Committee. A total of 5 female pigs (*Sus scrofa domesticus*), each weighing between 25 and 35 kg, were included in the study. The pigs were administered anesthesia after 12 hours of fasting. At the time of premedication, we injected 0.02 mg/kg of atropine (Atropin, 0.2%; Vetaş, Istanbul, Turkey) intramuscularly and then administered 2 mg/kg of xylazine hydrochloride (Alfazyne, 2%; EGE VET, Izmir, Turkey) and 10 mg/kg of ketamine hydrochloride (Alfamine, 10%; EGE VET). Venous access was provided through the ear vein, and 2.5%

sodium thiopental (Pental, 0.5 g; İ.E. Ulagay, Istanbul, Turkey) was infused. After intubation, the pigs inhaled isoflurane (Forane Liquid; Abbott Laboratories, Chicago, Illinois) for induction (4%) and maintenance (1.5%–3%). Pulse oximetry, electrocardiography, noninvasive blood pressure, and end-tidal carbon dioxide were monitored during the operation.

Surgical Procedure

The abdominal area was shaved after intubation, and a Veress needle was used to penetrate the abdomen under aseptic conditions just above the umbilicus. Carbon dioxide insufflation was performed with 12 mm Hg of intra-abdominal pressure. A 10-mm trocar was then placed through this site for videoendoscopy. Two trocars (5 mm and 12 mm) were placed in the right lower quadrant, and another 5-mm trocar was placed in the left lower quadrant. The pigs were positioned in the 30° Trendelenburg and right lateral positions (**Figure 1**). A high-definition 30° 10-mm camera (Karl Storz, Tuttlingen, Germany) was used. The bladder was dissected with hook electrocautery, and urine was aspirated to empty the bladder. The bladder was then fixed to the abdominal wall with a tack fixation device (Autosuture ProTack 5 mm; Covidien).

A 10-cm anterior rectosigmoid resection was planned for all of the pigs. A 5-mm LigaSure device (Covidien) was used for mediolateral mesocolon dissection. The colon segment was completely dissected from the surrounding tissues. After anal dilatation, a 25-mm OrVil device was inserted into the anus and advanced proximally to the colon segment to be resected under a laparoscopic view (**Figure 2**). A 0.5-cm incision was made, and a perforation was formed where the anvil was located; the 2 sutures attached to its delivery tube were then cut. The anvil was externally gripped with an atraumatic grasper while the delivery tube was evacuated through the anus. The tip of the anvil that was to be placed in the circular stapler was taken out from this perforation to the abdominal cavity (**Figure 3**). If necessary, the orifice was narrowed with a primary suture composed of No. 2–0 polyglactin 910 (Vicryl; Ethicon, Somerville, New Jersey). The proximal line of the sigmoid colon was transected just distal to the perforation with an articulating endoscopic linear stapler (EndoGIA; Covidien) (**Figure 4**). The rectosigmoid segment to be resected was extracted through the anus with a grasper, and distal transection was performed again with the EndoGIA device (**Figure 5**). A 25-mm EEA circular stapler (Covidien) was inserted and combined with the tip

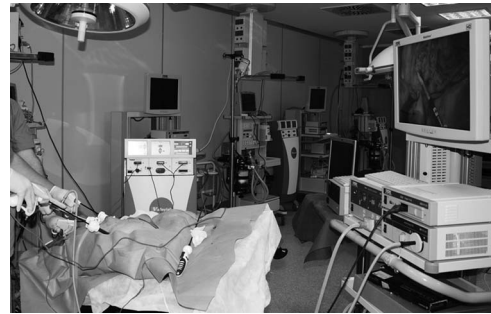

Figure 1. Laparoscopic anterior resection setup in pig model.

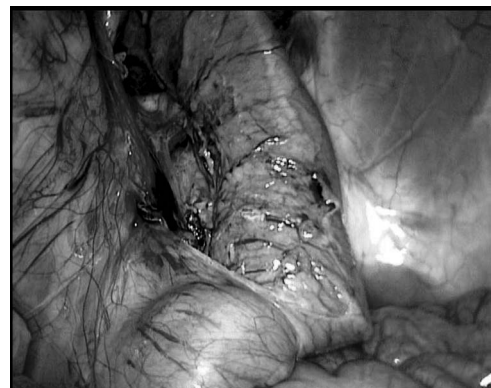


Figure 2. Insertion of anvil through anus.

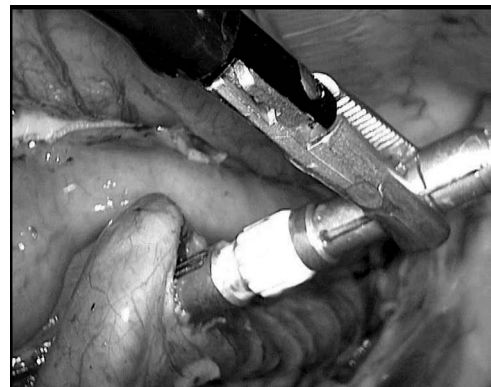


Figure 3. Removal of linking apparatus of anvil through perforation to abdominal cavity.

of the anvil. Finally, end-to-side colorectal anastomosis was performed in an intracorporeal manner (**Figure 6**).

The donuts were evaluated after removal of the circular stapler, and we observed that the proximal and distal donuts were completely removed in all pigs (**Figure 7**). For the anastomotic air leakage test, the pelvis was filled with saline solution, the proximal side of the anastomosis was obstructed with an atraumatic grasper, and air was insufflated through the anus.

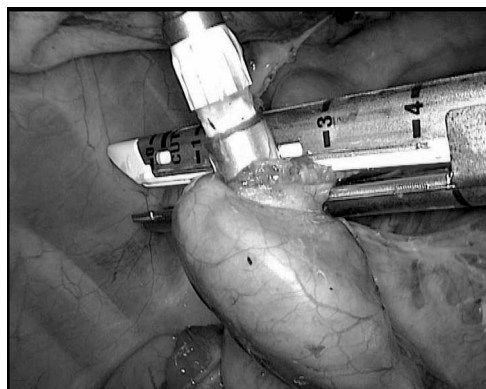


Figure 4. Transection of proximal colon just below perforation site with endoscopic linear stapler.

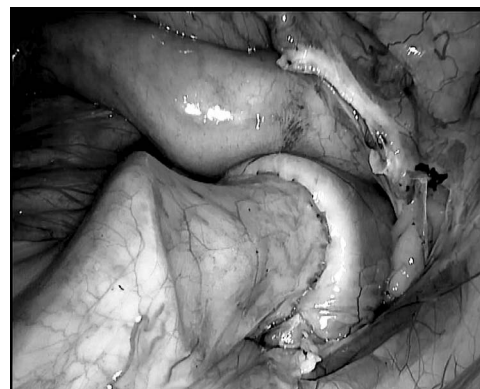


Figure 6. View of staples at edges of anastomosis after firing of circular stapler and removal of anvil.

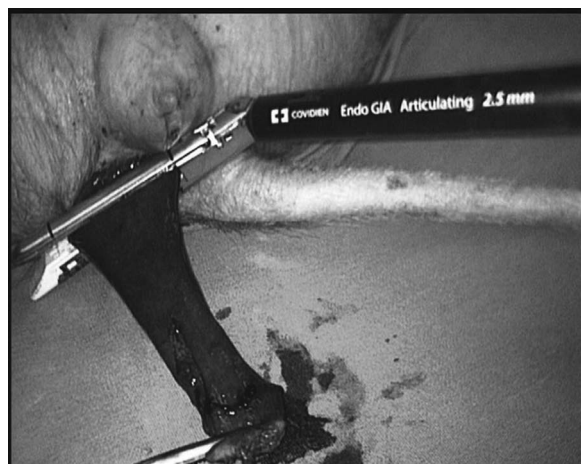

Figure 5. Extraction of colonic segment and distal transection.

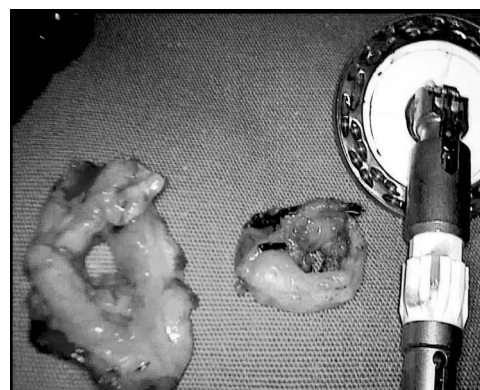

Figure 7. Complete removal of intact donuts after anastomosis.

At the end of the procedure, the animals were killed with an intravenous administration of 2.5% sodium thiopental (Pental, 0.5 g).

RESULTS

A 10-cm anterior rectosigmoid colon resection was performed in all pigs without complication. During the anastomotic air leakage test, no leakage was observed in any of the animals. The mean time from the insertion of the OrVil device into the anus to completion of the intracorporeal anastomosis was 12 minutes (range, 9–14 minutes). The mean operative time in the pigs was 37 minutes (range, 28–44 minutes).

DISCUSSION

Insertion of the OrVil device through the anus, followed by anastomosis with a circular stapler, is presented for the

first time in this report. This technique is safe and effective. This procedure was performed in 5 pigs, and an average of 12 minutes was required for anastomosis. An air leakage test was performed after anastomosis, and no leakage was observed.

Although anastomotic techniques are common in laparoscopic colorectal surgery, the search for feasible and safe techniques continues. The laparoscopic double-stapling technique is the most frequently performed method in left-sided colon and rectum anastomoses.⁵ An anvil is usually inserted into the proximal colon after it has been removed from the abdomen and after purse-string suturing. In another anastomosis method, 2 purse-string sutures are placed either proximally or distally and only 1 stapler is used.^{6,7} Both methods have disadvantages in that an incision must be made to insert the anvil into the extracorporeal colon and there may be excessive splenic colon mobilization in the case of an extracorporeal colon. In our method the anvil is inserted through the anus, a small perforation is created at the anastomosis line on the proximal colon, and the tip of the anvil is removed from

the colon through the perforation. Intraluminal specimen removal is performed so that the procedure can be finished without an additional incision. With our method, we avoid the time-consuming effort needed to make the suprapubic incision and remove the bowel from the abdomen.

Few studies have investigated intracorporeal anvil insertion. Inserting the anvil directly into the abdomen and performing intracorporeal purse-string suturing are difficult procedures that take time. Fleshman et al⁸ located both a circular stapling instrument and the anvil together from the anus and moved both of them upward to the proximal resection line by passing them through transanally. Their technique has 2 major problems. First, the proximal resection line can be longer than the circular stapler. Second, the anvil of the circular stapler is in plain position so this makes it more difficult to carry the anvil forward toward the proximal resection line. In our study only the OrVil device was inserted through the anus and was advanced proximally to the colon segment to be resected. The OrVil device is in tilt position so this makes the technique easier to perform especially in the treatment of neoplastic diseases. Bucher et al⁹ used an alternate method in which they made a transverse incision to the proximal colon and placed the anvil in the abdomen. They then removed the tip of the anvil across the purse-string suture that was placed proximal to the incision. Next, a proximal transection was performed with a linear stapler that covered the transverse incision, and end-to-side anastomosis was performed with a stapler placed below. This procedure has similarities to the method that we performed. However, we believe that an incision as wide as the diameter of the anvil may lead to contamination. Moreover, placing an intracorporeal purse-string suture at the point at which the tip of the anvil is to be removed makes the procedure cumbersome. We did not insert a purse-string suture into any of the animals, and the perforation was narrowed with a primary suture in 2 animals after the anvil was removed. Cutting the 2 sutures attached to the delivery tube is the limitation of our method. If this cutting step could be managed automatically, this method would be more effective.

It is possible that our method may be performed in the treatment of many colon disorders such as colorectal cancer, diverticular disease, prolapse, or inflammatory bowel disease. Complete intracorporeal resection and anastomosis, followed by removal of the specimen in an endobag

through the suprapubic incision, are important regarding oncologic principles. In addition, a suprapubic incision, evacuation of intra-abdominal gas, closure of the incision, and reinsufflation of the abdomen are not needed. We are planning human trials based on this experiment in pigs. The major problem is that the OrVil device exists in sizes of 21 and 25 mm. However, larger-sized circular staplers (>28 mm) are used in human colorectal anastomosis.

In conclusion, our results suggest that intracorporeal anastomosis with the OrVil device is a safe and effective method. If the sutures attached to the delivery tube could be managed automatically, this method would be more effective.

References:

1. Abraham NS, Young JM, Solomon MJ. Meta-analysis of short-term outcomes after laparoscopic resection for colorectal cancer. *Br J Surg*. 2004;91(9):1111–1124.
2. Mehta PP, Griffin J, Ganta S, Rangraj M, Steichen F. Laparoscopic-assisted colon resections: long-term results and survival. *JSLs*. 2005;9(2):184–188.
3. McKay GD, Morgan MJ, Wong SK, et al. Improved short-term outcomes of laparoscopic versus open resection for colon and rectal cancer in an area health service: a multicenter study. *Dis Colon Rectum*. 2012;55(1):42–50.
4. Koopmann MC, Heise CP. Laparoscopic and minimally invasive resection of malignant colorectal disease. *Surg Clin North Am*. 2008;88(5):1047–1072.
5. Yamamoto S, Fujita S, Akasu T, Moriya Y. Safety of laparoscopic intracorporeal rectal transection with double-stapling technique anastomosis. *Surg Laparosc Endosc Percutan Tech*. 2005;15(2):70–74.
6. Ho YH. Techniques for restoring bowel continuity and function after rectal cancer surgery. *World J Gastroenterol*. 2006;12(39):6252–6260.
7. Marecik SJ, Chaudhry V, Pearl R, Park JJ, Prasad LM. Sing-stapled double-pursestring anastomosis after anterior resection of the rectum. *Am J Surg*. 2007;193(3):395–399.
8. Fleshman JW, Brunt LM, Fry RD, et al. Laparoscopic anterior resection of the rectum using a triple stapled intracorporeal anastomosis in the pig. *Surg Laparosc Endosc*. 1993;3(2):119–126.
9. Bucher P, Wutrich P, Pugin F, Gonzales M, Gervaz P, Morel P. Totally intracorporeal laparoscopic colorectal anastomosis using circular stapler. *Surg Endosc*. 2008;22(5):1278–1282.