



NOTE

Pathology

Hodgkin's-like lymphoma in a ferret (*Mustela putorius furo*)

Isao MATSUMOTO¹⁾, Kazuyuki UCHIDA^{1)*}, James Kenn CHAMBERS¹⁾,
Kazumi NIBE²⁾, Yu SATO³⁾, Taku HAMASU³⁾ and Hiroyuki NAKAYAMA¹⁾¹⁾Laboratory of Veterinary Pathology, Graduate School of Agricultural and Life Sciences, The University of Tokyo, 1-1-1 Yayoi, Bunkyo-ku, Tokyo 113-8657, Japan²⁾Japan Animal Referral Medical Center, 2-5-8, Kuji, Takatsu, Kawasaki-shi, Kanagawa 213-0023, Japan³⁾Minato Ohori Animal Hospital, 2-9-29, Ohtemon, Chuo-ku, Fukuoka-shi, Fukuoka 810-0074, Japan

ABSTRACT. A 7-year-old castrated male ferret developed unilateral cervical lymphadenomegaly over a 1-month period. Histological examination revealed proliferation of tumor cells in a diffuse and partially nodular pattern. The tumor cells were predominantly Hodgkin cells and binucleated Reed-Sternberg cells, characterized by abundant, clear, vacuolated cytoplasm, pleomorphic, ovoid nuclei with thick nuclear membranes and distinct nucleoli. Multinucleated cells, resembling lymphocytic and histiocytic (L&H) cells, were also observed. Immunohistochemically, the tumor cells expressed Pax-5, BLA-36 and vimentin. A small population of the tumor cells expressed CD20. This case showed proliferation of Hodgkin/Reed-Sternberg cells in conjunction with L&H cells that were histologically analogous to feline Hodgkin's-like lymphoma. However, Pax-5 and BLA-36 expression along with rare CD20 expression were consistent with classical Hodgkin's lymphoma in humans.

KEY WORDS: ferret, Hodgkin's-like lymphoma, Reed-Sternberg cell

J. Vet. Med. Sci.

79(10): 1660–1663, 2017

doi: 10.1292/jvms.17-0317

Received: 12 June 2017

Accepted: 27 July 2017

Published online in J-STAGE:

11 August 2017

The diagnosis of Hodgkin's lymphoma (HL) is based on the identification of Hodgkin/Reed-Sternberg (H/RS) cells or lymphocytic and histiocytic (L&H) cells [5]. The characteristic inflammatory background and immunophenotyping allow further classification of HL into subgroups [5]. In domestic animals, Hodgkin's-like lymphoma (HLL) has been commonly described in cats [3, 7, 11, 15, 16] and less commonly in other species, including ferrets [2]. In feline studies, HLL did not meet the human HL classification criteria [5, 11]. Recently, feline HLL has been classified as a T-cell-rich B-cell lymphoma [9, 10, 13, 14]. In contrast, histopathological and immunohistochemical similarities were suggested between human HL and ferret HLL [2]. However, due to the limited number of cases in the ferret, the immunohistochemical features and their clinical relevance have not been fully elucidated. In the present case study, we characterized the immunohistochemical profile of HLL in a ferret using a panel of antibodies available for human HL.

A 7-year-old castrated male ferret developed right unilateral lymphadenomegaly in the neck over a one-month period. Due to the enlarged cervical lymph nodes compressing the respiratory tract, the ferret developed dyspnea. Although the lymph nodes reduced in size following prednisolone injections, they rapidly enlarged. The lymph nodes were resected and, the biopsy specimens were submitted for histopathological examination.

Routinely fixed, paraffin-embedded tissue blocks were cut into 4- μ m-thick sections. The sections were deparaffinized, rehydrated through a graded series of alcohols, and stained with hematoxylin and eosin. Immunohistochemical analyses were performed using antibodies to BLA-36, CD3, CD79 α cy and vimentin (Dako Japan, Tokyo, Japan); CD20 and Pax-5 (Thermo Fisher Scientific, Waltham, MA, U.S.A.); and Iba-1 (Wako, Osaka, Japan). Details of immunohistochemistry procedures are summarized in Table 1. Briefly, antigen retrieval was achieved by autoclaving the sections at 121°C for 10 min. Endogenous peroxidase was inactivated by treatment with 3% hydrogen peroxide in methanol at room temperature for 5 min. The sections were then blocked with 8% skimmed milk in Tris-buffered saline (TBS) at 37°C for 30 min and then incubated with the primary antibodies at 4°C overnight. After being washed in TBS three times, the sections were incubated with Dako EnVision + System horseradish peroxidase-labeled polymer secondary antibodies (Dako Japan) at 37°C for 40 min. The sections were washed three times in TBS, before being visualized with 0.05% 3,3'-diaminobenzidine and 0.03% hydrogen peroxidase in Tris-HCl buffer.

Histological examination revealed proliferation of tumor cells in a diffuse and partially nodular pattern, circumscribed by coarse fibrous bands (Fig. 1). The tumor cells were predominantly Hodgkin cells and binucleated Reed-Sternberg cells. The tumor cells were characterized by abundant, clear, vacuolated cytoplasm; pleomorphic, ovoid nuclei with thick nuclear membranes; and

*Correspondence to: Uchida, K.: auchidak@mail.ecc.u-tokyo.ac.jp

©2017 The Japanese Society of Veterinary Science



This is an open-access article distributed under the terms of the Creative Commons Attribution Non-Commercial No Derivatives (by-nc-nd) License. (CC-BY-NC-ND 4.0: <https://creativecommons.org/licenses/by-nc-nd/4.0/>)

Table 1. Antibodies used for immunohistochemistry

Antibody	Clone	Type	Dilution	Manufacturer	Antigen retrieval
CD3		pAb rabbit	RTU	Dako Japan (Tokyo, Japan)	Heat, Sodium citrate buffer (pH6)
CD20		pAb rabbit	1:400	Thermo Fisher Scientific (Waltham, MA, U.S.A.)	None
CD79 α cy	HM57	mAb mouse	1:50	Dako Japan (Tokyo, Japan)	Heat, high pH target retrieval (pH9)
BLA-36	A27-42	mAb mouse	1:25	Dako Japan (Tokyo, Japan)	Heat, Sodium citrate buffer (pH6)
Pax-5		pAb rabbit	RTU	Thermo Fisher Scientific (Waltham, MA, U.S.A.)	Heat, Sodium citrate buffer (pH6)
Vimentin	V9	mAb mouse	RTU	Dako Japan (Tokyo, Japan)	Heat, Sodium citrate buffer (pH6)
Iba-1		pAb rabbit	1:500	Wako (Osaka, Japan)	Heat, Sodium citrate buffer (pH6)

pAb, polyclonal antibody; mAb, monoclonal antibody; RTU, ready to use.

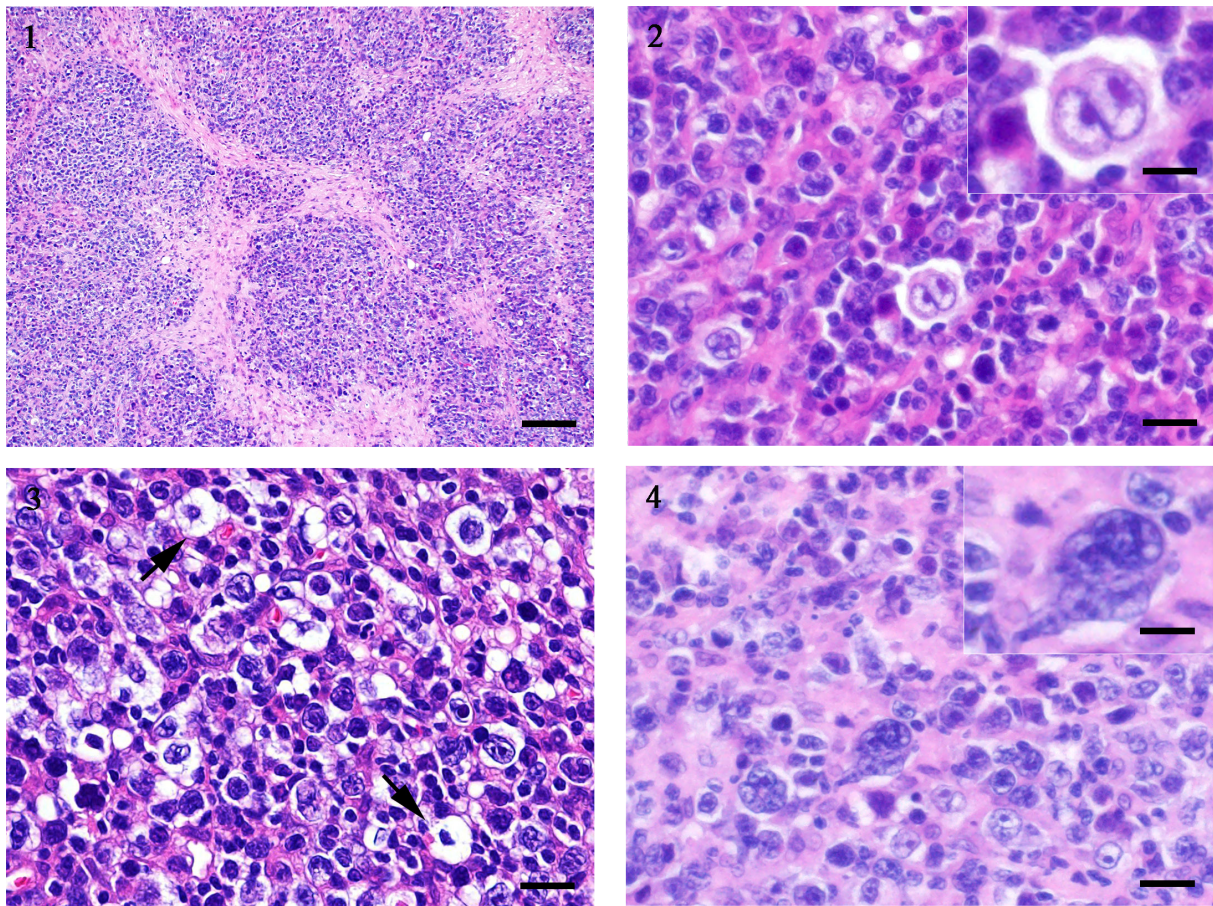


Fig. 1. Low magnification shows tumor cells proliferating in a nodular pattern, circumscribed by coarse fibrous bands. Hematoxylin and eosin. Bar, 100 μ m.

Fig. 2. Characteristic Hodgkin cells and Reed-Sternberg cells are seen in the cervical lymph nodes of a ferret. Hematoxylin and eosin. Bar, 20 μ m. Inset: Reed-Sternberg cells are characterized by pleomorphic bi-nucleated large nuclei with prominent nucleoli. Hematoxylin and eosin. Bar, 10 μ m.

Fig. 3. The cytoplasm of the lacunar cells is retracted towards the nuclear membrane (arrows). Hematoxylin and eosin. Bar, 20 μ m.

Fig. 4. Lymphocytic and histiocytic (L&H) cells frequently identified in the tumor nest. Hematoxylin and eosin. Bar, 20 μ m. Inset: L&H cells are characterized by hyperlobulated nuclei. Hematoxylin and eosin. Bar, 10 μ m.

distinct eosinophilic nucleoli (Fig. 2). H/RS cells with retracted cytoplasm towards the nuclear membrane, as known as lacunar cells, were also frequently found in the tumor nest (Fig. 3). Furthermore, atypical cells with hyperlobulated nuclei, resembling L&H cells, were frequently identified (Fig. 4). On immunohistochemical analyses, the tumor cells showed nuclear expression of Pax-5, with a variation in staining intensity (Fig. 5). The tumor cells also demonstrated diffuse membranous BLA-36 and cytoplasmic expression of vimentin (Figs. 6 and 7). The tumor cells were negative for CD79 α cy, while a minor population of H/RS cells (<5%) expressed CD20 (Fig. 8). Immunohistochemistry for CD3 and Iba-1 revealed marked infiltration of T cells and macrophages in the tumor nest. The results of immunohistochemistry are summarized in Table 2.

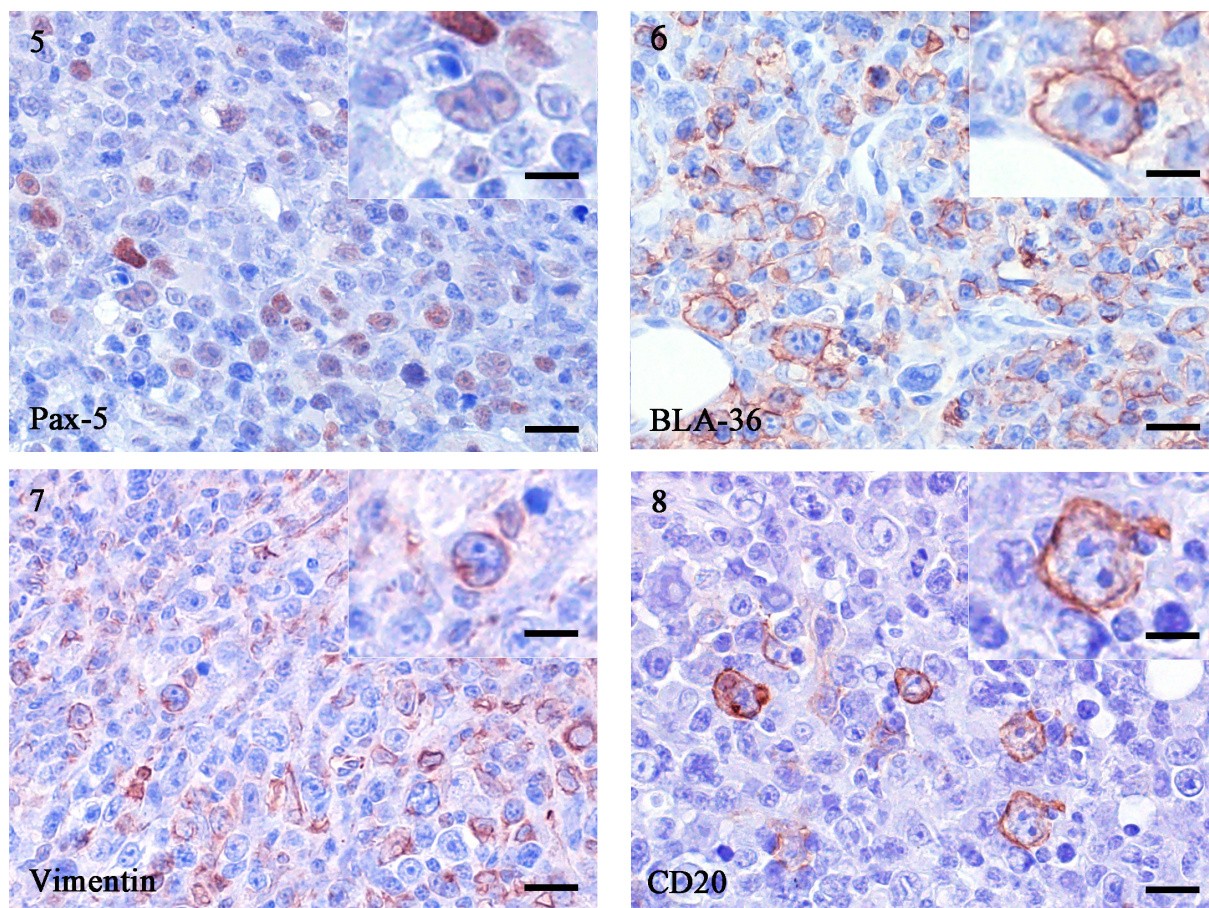


Fig. 5. Nuclear expression of Pax-5 identified in tumor cells. Immunohistochemistry. Hematoxylin counterstain. Bar, 20 μ m. Inset: The nucleus of a Reed-Sternberg cell positive for Pax-5. Immunohistochemistry. Hematoxylin counterstain. Bar, 10 μ m.

Fig. 6. Immunohistochemistry shows expression of BLA-36 in tumor cells. Immunohistochemistry. Hematoxylin counterstain. Bar, 20 μ m. Inset: Membranous expression of BLA-36 in Reed-Sternberg cell. Immunohistochemistry. Hematoxylin counterstain. Bar, 10 μ m.

Fig. 7. Immunohistochemistry shows approximately 50% of the tumor cell population expressing vimentin. Immunohistochemistry. Hematoxylin counterstain. Bar, 20 μ m. Inset: Reed-Sternberg cell shows strong cytoplasmic expression of vimentin. Immunohistochemistry. Hematoxylin counterstain. Bar, 10 μ m.

Fig. 8. Less than five percent of tumor cells expressed CD20. Immunohistochemistry. Hematoxylin counterstain. Bar, 20 μ m. Inset: Reed-Sternberg cell shows membranous expression of CD20. Immunohistochemistry. Hematoxylin counterstain. Bar, 10 μ m.

Following lymphadenectomy, the ferret was treated with different combinations of chemotherapy that included asparaginase, cyclophosphamide, cytarabine, methotrexate and prednisolone. Although the combination of cyclophosphamide and prednisolone was more effective than other combinations, decreased efficacy of cyclophosphamide was evident. Twelve weeks postoperatively, the ferret developed left cervical, superficial cervical and inguinal lymphadenomegaly.

According to the World Health Organization (WHO)/Revised European-American Lymphoma (REAL) classification, human HL can be broadly divided into lymphocyte-prominent HL (LPHL) and classical HL (CHL). CHL is further subdivided into nodular sclerosis CHL (NSCHL), mixed cellularity CHL (MCCHL), lymphocyte-rich CHL (LRCHL) and lymphocyte-depletion CHL (LDCHL) [5]. In human NSCHL, lacunar cells are predominant, while classic H/RS cells are rarely identified [5]. Interestingly, the present ferret case showed the proliferation of lacunar cells in

Table 2. Summary of immunohistochemical examination

Antibody	Tumor cells ^{a)}		Major positive cells ^{b)}
	H/RS cells	L&H cells	
CD3	-	-	T cell
CD20	M+	-	B cell
CD79 α _{cy}	-	-	B cell
BLA-36	M+	M+	B cell
Pax-5	N+	N+	B cell
Vimentin	C+	C+	Fibroblasts
Iba-1	-	-	Macrophages

a) H/RS cells, Hodgkin/Reed-Sternberg cells; L&H cells, lymphocytic and histiocytic cells; C, cytoplasmic; M, membranous; N, nucleus; +, positive; -, negative. b) Cells in the compressed surrounding normal tissues were used for positive control.

conjunction with H/RS cells. In addition, L&H cells, a diagnostic characteristic of LPHL and LRCHL, were frequently identified in the present study. H/RS cells in conjunction with L&H cells may be explained by an intermediate-type morphology of both CHL and LPHL in humans. Eosinophil infiltration, characteristic of NSCHL, was previously described in HLL in a ferret [2]. However, eosinophil infiltration was absent in the current case. The different degree of eosinophil infiltration may correlate with the stage of diseases development or with different etiologies. In the previous feline study, HLL were classified into LPHL-type and CHL-type based on their morphology [11, 15]. However, they were different in the several ways. L&H cells were found in CHL-type, and a small number of lacunar cells were found in LPHL-type in feline HLL [11, 15]. Taken together with those findings, the cellular morphology in the current case suggested the analogous morphology between feline and ferret HLL.

The primary differential diagnosis of HLL is T-cell-rich B-cell lymphoma [12]. In the present study, only a small population of tumor cells expressed CD20, while tumor cells of T-cell-rich B-cell lymphoma show diffuse CD20 expression [11]. L & H cells were positive while H/RS cells were negative for CD79 α in cats [15]. In contrast, the tumor cells uniformly lacked CD79 α expression regardless of the cell types in the current case. Pax-5 is a transcription factor expressed throughout B cell maturation and is detected in most B-cell neoplasms, including CHL and diffuse large B-cell lymphoma [4]. As described in human CHL [4] and feline HLL [16], the tumor cells had nuclear expression of Pax-5 in the current case. Hodgkin cells and human B cell lines, including early B progenitor cells, specifically express BLA-36 [6]. As previously demonstrated in a ferret [2], the tumor cells in our study also expressed BLA-36. In the feline study, BLA-36 expression was observed only in L&H cells but H/RS cells [15]. However, such variations between different cell types were not observed in the current ferret case. A previous human study suggests that vimentin, CD30 and CD15 antibodies are useful in distinguishing CHL from T-cell-rich B-cell lymphoma [8]. Although we were unable to confirm the presence of CD30 and CD15 in the ferret because of the lack of commercially available antibodies, cytoplasmic vimentin expression is consistent with the immunohistochemical profiles of CHL. The presence of vimentin may indicate the altered processes of growth and differentiation in tumor cells [1].

The present study shows morphological similarities between ferret and feline HLL. In contrast, the immunohistochemical profiles of the ferret resembled the profile of human CHL. The expression of Pax-5 and BLA-36, rare CD20 expression may suggest an immunohistochemical profile consistent with B cell lineage. Together with our findings, additional cases will improve the understanding of the clinical nature of HLL in the ferret.

CONFLICT OF INTEREST. None of the authors have any conflicts of interest to declare.

REFERENCES

1. Angel, C. A., Cullen, R. A., Pringle, J. H. and Lauder, I. 1992. Vimentin expression by Reed-Sternberg cells in Hodgkin's disease. *Virchows Arch. A Pathol. Anat. Histopathol.* **421**: 9–11. [Medline] [CrossRef]
2. Blomme, E. A., Foy, S. H., Chappell, K. H. and La Perle, K. M. 1999. Hypereosinophilic syndrome with Hodgkin's-like lymphoma in a ferret. *J. Comp. Pathol.* **120**: 211–217. [Medline] [CrossRef]
3. Day, M. J., Kyaw-Tanner, M., Silkstone, M. A., Lucke, V. M. and Robinson, W. F. 1999. T-cell-rich B-cell lymphoma in the cat. *J. Comp. Pathol.* **120**: 155–167. [Medline] [CrossRef]
4. Desouki, M. M., Post, G. R., Cherry, D. and Lazarchick, J. 2010. PAX-5: a valuable immunohistochemical marker in the differential diagnosis of lymphoid neoplasms. *Clin. Med. Res.* **8**: 84–88. [Medline] [CrossRef]
5. Eberle, F. C., Mani, H. and Jaffe, E. S. 2009. Histopathology of Hodgkin's lymphoma. *Cancer J.* **15**: 129–137. [Medline] [CrossRef]
6. Imam, A., Stathopoulos, E. and Taylor, C. R. 1990. BLA.36: a glycoprotein specifically expressed on the surface of Hodgkin's and B cells. *Anticancer Res.* **10**: 1095–1104. [Medline]
7. Nakayama, H., Nakanaga, K., Ogihara, S., Hayashi, T., Takahashi, R. and Fujiwara, K. 1984. Three cases of feline lymphosarcoma with formation of multinucleated giant cells. *Nihon Juigaku Zasshi* **46**: 225–228. [Medline] [CrossRef]
8. Rüdiger, T., Ott, G., Ott, M. M., Müller-Deubert, S. M. and Müller-Hermelink, H. K. 1998. Differential diagnosis between classic Hodgkin's lymphoma, T-cell-rich B-cell lymphoma, and paraneoplasia by paraffin immunohistochemistry. *Am. J. Surg. Pathol.* **22**: 1184–1191. [Medline] [CrossRef]
9. Sato, H., Fujino, Y., Chino, J., Takahashi, M., Fukushima, K., Goto-Koshino, Y., Uchida, K., Ohno, K. and Tsujimoto, H. 2014. Prognostic analyses on anatomical and morphological classification of feline lymphoma. *J. Vet. Med. Sci.* **76**: 807–811. [Medline] [CrossRef]
10. Valli, V., Bienzle, D. and Meuten, D. 2017. Tumors of the hematology-lymphatic system, lymphoid tumors, types of lymphoma by species. pp. 207–208. *In: Tumors in Domestic Animals*, 5th ed. (Meuten, D. J. ed.), Wiley-Blackwell, Ames.
11. Valli, V., Kiupel, M., Bienzle, D. and Darren Wood, R. 2015. Hematopoietic system. lymph nodes, lymphoid neoplasms, classification of lymphomas. pp. 215–242. *In: Jubb, Kennedy and Palmer's Pathology of Domestic Animals*, 6th ed. (Maxie, M. G. ed.), Elsevier, St. Louis.
12. Valli, V., Jacobs, R., Parodi, A., Vernau, W. and Moore, P. 2002. *Histopathological Classification of Hematopoietic Tumors of Domestic Animals*, 2nd ed., Armed Forces Institute of Pathology, Washington, D.C.
13. Valli, V. E., Jacobs, R. M., Norris, A., Couto, C. G., Morrison, W. B., McCaw, D., Cotter, S., Ogilvie, G. and Moore, A. 2000. The histologic classification of 602 cases of feline lymphoproliferative disease using the National Cancer Institute working formulation. *J. Vet. Diagn. Invest.* **12**: 295–306. [Medline] [CrossRef]
14. Vezzali, E., Parodi, A. L., Marcato, P. S. and Bettini, G. 2010. Histopathologic classification of 171 cases of canine and feline non-Hodgkin lymphoma according to the WHO. *Vet. Comp. Oncol.* **8**: 38–49. [Medline] [CrossRef]
15. Walton, R. M. and Hendrick, M. J. 2001. Feline Hodgkin's-like lymphoma: 20 cases (1992–1999). *Vet. Pathol.* **38**: 504–511. [Medline] [CrossRef]
16. Yoshino, Y., Chambers, J. K., Nakamori, T., Goto-Koshino, Y., Nishigaki, K., Tsujimoto, H., Matsuki, N., Nakayama, H. and Uchida, K. 2017. Primary cerebellar lymphoma with Hodgkin lymphoma-like morphology in a cat. *J. Vet. Diagn. Invest.* 1040638717704239. [Medline]