

Minimally invasive partial cystectomy with bilateral vesico-ureteric junction resection and reimplantation for a large paraganglioma involving urinary bladder trigone

Abinaya Ravichandran-Chandra¹, Vinodh-Kumar-Adithyaa Arthanareeswaran¹, Hoang-Minh Do¹, Anja Dietel¹, Toni Franz¹, Iason Kyriazis², Evangelos Liatsikos³, Joerg Ressler⁴, Lars-Christian Horn⁵, Jens-Uwe Stolzenburg¹

¹Department of Urology, Leipzig University Hospital, Leipzig, Germany

²University of Patras Medical School, Patras, Greece

³University Hospital of Patras, Patras, Greece

⁴Department of Urology, St. Elisabeth-Krankenhaus, Leipzig, Germany

⁵Department of Pathology, University Hospital Leipzig, Leipzig, Germany

Citation: Ravichandran-Chandra A, Arthanareeswaran VKA, Do H-M, et al. Minimally invasive partial cystectomy with bilateral vesico-ureteric junction resection and reimplantation for a large paraganglioma involving urinary bladder trigone. Cent European J Urol. 2017; 70: 378-381.

Article history

Submitted: April 23, 2017

Accepted: Sept. 17, 2017

Published online: Sept. 19, 2017

Corresponding author

Abinaya

Ravichandran-Chandra
Leipzig University Hospital
Department of Urology
Liebigstraße 20
04103 Leipzig, Germany
sayhaitoabi@gmail.com

Paragangliomas are neuroendocrine tumours of extra adrenal origin. Although it occurs rarely in the genitourinary system, urinary bladder is the most common site. Its diagnosis warrants complete surgical excision with lymphadenectomy in case of metastatic disease. The functional status of this tumour makes intraoperative handling challenging. Surgical resection necessitates minimal manipulation of tumour thereby mitigating intraoperative physiological jeopardy. We report the possibility of minimally invasive partial cystectomy with bilateral vesico-ureteric junction resection and re-implantation for non-malignant paraganglioma involving the bladder trigone. Intraoperative frozen section is deemed necessary to achieve tumour free margin status.

Key Words: intra-operative frozen section <> paraganglioma <> partial cystectomy <> robot assisted <> ureteric re-implantation

CASE PRESENTATION

A 14-year-old female patient presented with history of haematuria and headache with tachycardia and mild hypertension on examination. MRI identified a 5x5x3 cm mass in the posterior bladder wall (Figure 1). Cystoscopic biopsy from the bladder trigone was performed with an initial suspicion of bladder cancer with no special precautions. Surprisingly, histopathological examination revealed paraganglioma. Urine metabolites, namely normetanephrine, noradrenaline and vanillylmandelic acid were elevated.

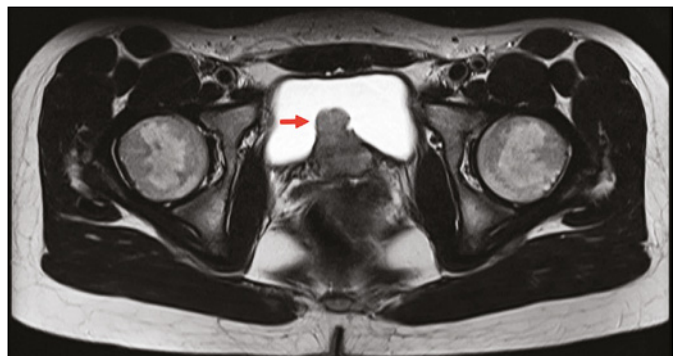


Figure 1. Contrast enhanced magnetic resonance imaging showing paraganglioma on the posterior bladder wall (arrow).

Somatostatin-Receptor PET/MRI showed enhancement of the tumour region in the bladder, confirming its functional status. Although the patient tolerated the biopsy without any complications, surgical resection was performed following pharmacological optimization with alpha blocker initially followed by beta blocker three days prior to surgery.

Operative technique

Patient was positioned in steep Trendelenburg position and ports were placed using standard technique for robot assisted pelvic surgery. Urinary bladder was first completely mobilized ventrally and dorsally between the bladder and vagina to enable complete resection of the tumour. A sagittal incision was made on the dorsal wall of bladder extending up to the trigone; revealing the tumour below. Visual cues from three-dimensional magnified vision of the endoscope were used to mark macroscopic tumour margins with cautery (Figure 2). The tumour was subsequently resected without disturbing the anatomical vesico-ureteric junctions. Reconstruction was initially planned using a rotational bladder flap. Surprisingly, IOFS revealed presence of tumour in the margins and further resection including the bladder outlet and both vesico-ureteric junctions were necessary. The re-resected tumour margins were free from tumour on IOFS. The reconstruction strategy required modification, which now included anatomical and functional restoration of the bladder outlet and bilateral vesico-ureteric junctions. The bladder outlet was reconstructed using 4-0 Stratafix (Ethicon Inc., New Jersey, USA) (Figure 3). Next, the tumour free margins of the bladder were closed primarily using 3-0 V-Loc (Covidien Ltd., Dublin, Ireland) sutures. Both ureters were then re-implanted using the classical technique described by Politano-Leadbetter with two separate incisions on the lateral surface of bladder (Figure 4). The total operative time was 220 min with 150 ml blood loss. The intraoperative and postoperative periods were uneventful. The urinary catheter was removed on the 10th postoperative day following cystogram (Figure 5). Although extensive resection of the trigone including the bladder outlet and ureteric orifices were performed, the patient was able to empty the bladder normally without any residual urine. Final histopathological analysis confirmed a non-malignant type of paraganglioma with cells positive for synaptophysin, chromogranin, CD56 and S100 on immunohistochemistry (Figure 6) with tumour free margins. The patient was symptom free on six-month follow-up. Further long-term follow up is planned with annual CT and 123/131I-metiodobenzylguanidine (I-MIBG SPECT) scan.

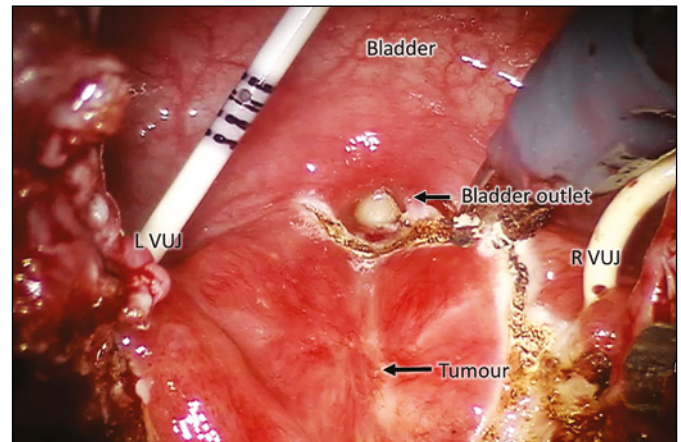


Figure 2. Paraganglioma visualised on the posterior bladder wall involving the trigone. Margins for resection are marked using cautery. LVUJ – left vesico-ureteric junction, RVUJ – right vesico-ureteric junction.

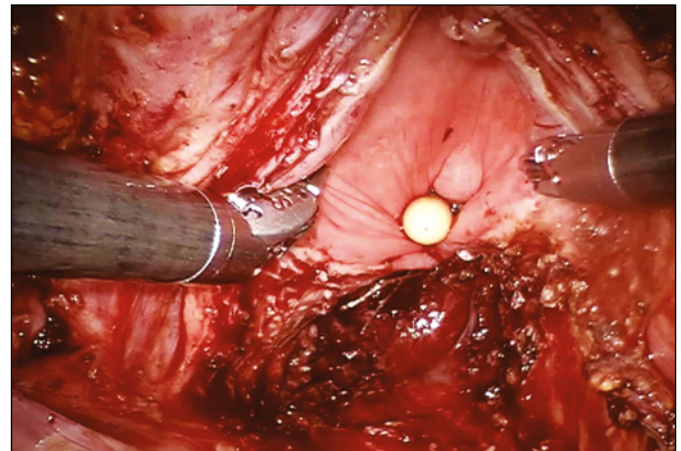


Figure 3. Bladder outlet reconstructed following re-resection and negative surgical margins on frozen section.

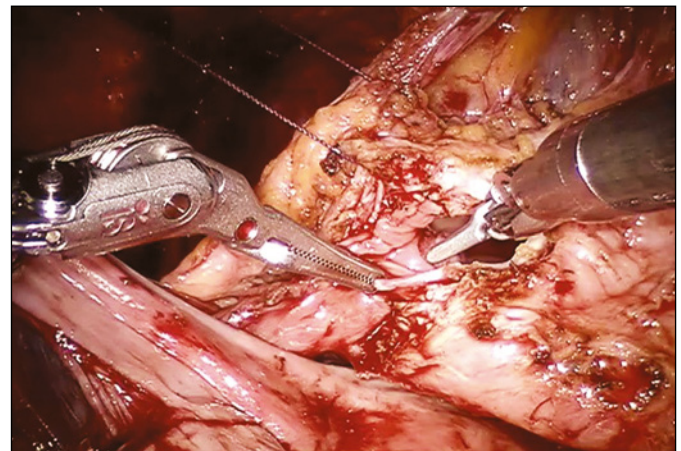


Figure 4. Ureteric re-implantation performed according to classical technique described by Politano-Leadbetter by creating a submucosal tunnel (arrow). LFT – left fallopian tube.

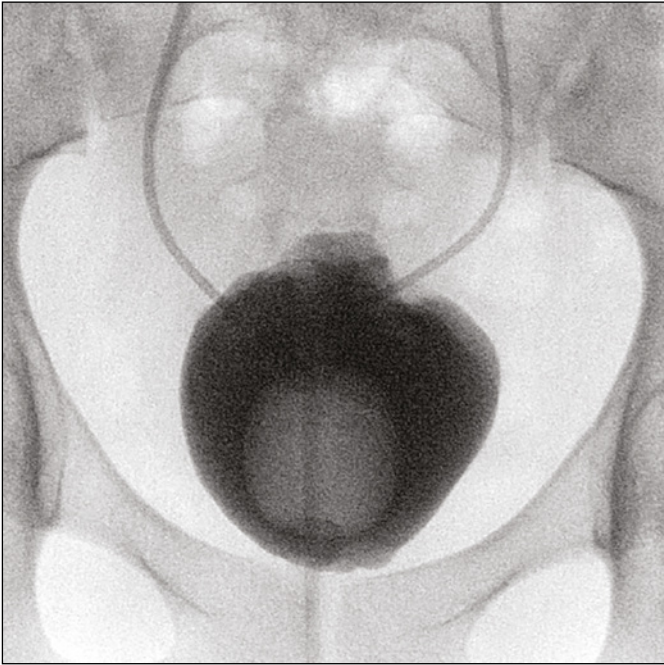


Figure 5. Postoperative cystogram showing normal contour of bladder and absence of contrast extravasation.

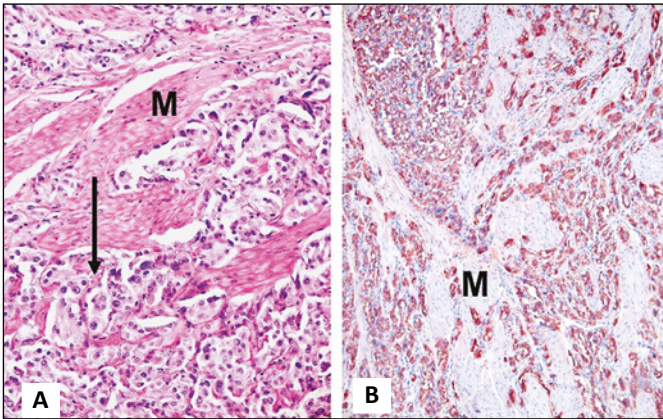


Figure 6. Final histopathologic examination. A) Paraganglioma cells (arrow) dissecting the bladder muscle (M). B) Immunohistochemistry staining of paraganglioma cells positive for chromogranin A growing between smooth muscle cells (M) of the bladder wall.

DISCUSSION

Paragangliomas are a rare type of neuroendocrine tumours arising from chromaffin cells that are derived from the embryonic neural crest, which forms a part of sympathetic nervous system [1]. Paraganglioma of urinary bladder accounts for less than 0.5% of all bladder tumours, [2] with trigone being the most common site of occurrence [1]. The bladder is the most common site of genitourinary para-

gangliomas accounting for 79.2% of cases, followed by urethra (12.7%) and ureters (3.2%) [2]. Around 10% of bladder paragangliomas are reported to be malignant with metastatic potential [3]. Most bladder paragangliomas are functionally active and only 17% are non-functional [4]. Patients classically have symptomatic manifestations of sympathetic over-activity like headache, sweating, hot flushes, palpitation which warrants medical and surgical attention. The classical presentation of bladder paraganglioma consists of a triad of hypertension, painless haematuria and 'micturition attacks' (headache, palpitation, syncope, during or after voiding). Among these, painless gross haematuria is the most common presenting symptom, reported in 55% to 58% of cases [3]. Clinical assessment relies on diagnostic imaging and functional evaluation of catecholamine metabolites in blood and urine. Although the tumour can be delineated by ultrasound or contrast enhanced computer tomography (CT) or MRI, functional imaging techniques that distinctly target the catecholamine pathway can precisely describe the anatomical and functional status of the tumour including metastases. Gallium-68 somatostatin receptor positron emission tomography (PET)/ magnetic resonance imaging (MRI) has been reported to have 98% accuracy rate when compared to 123I-MIBG-SPECT which has a sensitivity of 80–95% in identifying neuroendocrine tumours [3]. Treatment requires complete surgical excision of the tumour.

Lymphadenectomy is only indicated in case of metastatic disease [3]. Prognostication of bladder paraganglioma cannot be assessed with histopathological features alone. Indicators of malignant potential encompass necrosis, angiolymphatic invasion, high mitotic index, absence of hyaline bodies, p53 alteration, and DNA ploidy analysis [4]. Nevertheless, occurrence of metastasis indicates malignancy. Adequate preoperative blockade of adrenoceptors with alpha and beta blockers should be achieved to circumvent hypertensive crisis during intraoperative tumour handling. Lifelong follow-up is recommended with annual CT and 123I-MIBG SPECT scan to detect recurrences; although recurrence does not specify malignancy. We report a case of large paraganglioma involving the urinary bladder trigone managed by robot assisted partial cystectomy with bilateral vesico-ureteric junction resection and re-implantation using Politano-Leadbetter technique.

Being a rare entity with diverse clinical presentation, paragangliomas are challenging to diagnose and treat. Management necessitates total excision of tumour [4] by partial cystectomy with lymph

node dissection in case of a metastatic disease [5]. The robot-assisted resection of a paraganglioma involving unilateral vesico-ureteric junction was first reported by Nayar et al. in 2010 [6]. Similar management for other sites in the bladder were subsequently reported [3, 7–10]. Pelvic lymph node dissection for a metastatic paraganglioma was performed by Luchey et al. [8]. This is the first case to report robot-assisted partial cystectomy with bilateral vesico-ureteric junction resection and re-implantation for a large non-malignant bladder paraganglioma. We also demonstrate that tumour resection based on visual appearance alone is inadequate and utilization of IOFS is invaluable in identifying tumour free margins.

CONCLUSIONS

In conclusion, paraganglioma involving the bladder trigone can be effectively managed using adequate surgical resection with bilateral re-implantation of ureters. IOFS is an absolute necessity to identify tumour free margins. The manoeuvrability and flexibility of the robotic instruments may help the surgeon to perform these complex steps efficiently and precisely; thereby aiming to deliver an unmitigated outcome to the patient. Long-term follow-up is warranted in all patients with bladder paraganglioma.

CONFLICTS OF INTEREST

The authors declare no conflicts of interest.

References

- McNicol AM. Adrenal medulla and paraganglia. *Endocrine pathology: differential diagnosis and molecular advance*. Springer 2010; p. 281.
- Hanji AM, Rohan VS, Patel JJ, Tankshali RA. Pheochromocytoma of the urinary bladder: a rare cause of severe hypertension. *Saudi J Kidney Dis Transpl*. 2012; 23: 813-816.
- Beysens M, Lapauw B, Gykiere PJ, Dekeyzer S, Lumen N, Decaestecker K. Minimally invasive approach of bladder paraganglioma: case report and review of literature. *Austin J Clin Case Rep*. 2014; 1: 1034.
- Al-Zahrani AA. Recurrent urinary bladder paraganglioma. *Adv Urol*. 2010; 912125.
- Pahwa HS, Kumar A, Srivastava R, Misra S, Goel MM. Urinary bladder paraganglioma—a case series with proposed treating algorithm based on our experience and review of literature. *Indian J Surg Oncol*. 2013; 4: 294-297.
- Nayyar R, Singh P, Gupta NP. Robotic management of pheochromocytoma of the vesico-ureteric junction. *JSL*. 2010; 14: 309-312.
- Kang SG, Kang SH, Choi H, Ko YH, Park HS, Cheon J. Robot-assisted partial cystectomy of a bladder pheochromocytoma. *Urol Int*. 2011; 87: 241-244.
- Luchey A, Zaslau S, Talug C. Robotic assisted partial cystectomy with pelvic lymph node dissection for metastatic paraganglioma of the urinary bladder. *Can J Urol*. 2012; 19: 6389-6391.
- Weintraub MD, Siddiqui MM, Ricketts CJ, et al. Robot-assisted partial cystectomy for treatment of bladder paraganglioma. *Videourology*. 2013; 27.
- Bishnoi K, Bora GS, Mavuduru RS, Devana SK, Singh SK, Mandal AK. Bladder paraganglioma: safe and feasible management with robot assisted surgery. *J Robot Surg*. 2016; 10: 275-278. ■