

Case Report

Pathological changes in chronic eosinophilic peritonitis in peritoneal dialysis patient

Yukio Yuzawa¹, Yasuhiko Ito^{1,2}, Masashi Mizuno^{1,2}, Akiho Sawai¹ and Seiichi Matsuo¹

¹Department of Nephrology and ²Department of Renal Replacement Therapy, Nagoya University Graduate School of Medicine, Nagoya, Japan

Correspondence and offprint requests to: Yasuhiko Ito; E-mail: yasuito@med.nagoya-u.ac.jp

Abstract

We report the pathological findings of the peritoneum in a patient with chronic eosinophilic peritonitis. Peripheral blood eosinophilia was confirmed before insertion of Tenckhoff catheter. Eosinophilic peritonitis continued from the second day after initiation of peritoneal dialysis for 18 months. Pathological findings showed numerous eosinophils in peritoneal blood vessels. Mast cells were also detected in the peritoneum, while neoangiogenesis was not prominent. The highly permeable state of the peritoneal membrane may be due to inflammatory mediators, such as tryptase. Mast cells may be involved in high peritoneal permeability in such patients.

Keywords: eosinophilia; mast cell; peritoneal permeability

Introduction

Eosinophilic peritonitis is defined as >10% eosinophils in effluent at presentation, and its causes are often obscure. However, cases have been reported with allergic reactions, exposure to drugs such as vancomycin, fungal and viral infections, soon after catheter replacement, and icodextrin treatment [1]. Eosinophilic peritonitis has been thought to heal spontaneously without disturbance of peritoneal function. Therefore, the pathological findings of an affected peritoneum have not been studied in detail to date. However, a case of encapsulated peritoneal sclerosis (EPS) after recurrent episodes of eosinophilic peritonitis has been reported [2]. Here, we report a patient with eosinophilic peritonitis that continued for 18 months, and evaluate the pathological findings of the peritoneum.

Case report

A 71-year-old Japanese man developed advanced chronic renal failure due to nephrosclerosis and underwent surgery to insert and embed a Tenckhoff peritoneal dialysis (PD) catheter on 27 December 2007. His medications were

candesartan cilexetil, diltiazem hydrochloride, furosemide, spironolactone, bayaspirin, alfacalcidol and calcium carbonate. At the beginning of December 2007, he experienced a pruritic maculopapular rash affecting his arms and anterior chest with eosinophilia (eosinophils 16.6%, 1700/mm³). After administration of the antihistamine agent for 2 weeks, his symptoms subsided. He had no other history of allergic disease, including bronchial asthma or food sensitivity, other than this episode.

On 31 January 2008, CAPD treatment was initiated immediately after confirming that serum blood urea nitrogen was 26.8 mmol/L (75 mg/dL), and creatinine was 954.7 µmol/L (10.8 mg/dL). Two days after commencing CAPD, a cloudy effluent was noted. He had no clinical symptoms, and physical examination was unremarkable. Investigation revealed an elevated number of leucocytes in the peritoneal fluid (310/µL) with 29% eosinophils, 11% neutrophils, and 60% lymphocytes and monocytes. Repeated culture of dialysis fluid failed to reveal any organisms. Blood culture and PCR for *Mycobacterium tuberculosis*, *Mycobacterium avium* and *Mycobacterium intracellulare* were negative. We diagnosed eosinophilic peritonitis, and intraperitoneal administration of antibiotics was discontinued.

Mild eosinophilic peritonitis with peripheral blood eosinophilia continued for 18 months. During this period, white cell count in peritoneal effluent was 200–1060/µL, and eosinophils were 20–30%. In addition, C-reactive protein was 0.04–2.01 mg/dL (0.36 ± 0.47, mean ± SD). Repeated examination of the stool revealed no parasite ova. Anti-nuclear antibody, anti-proteinase 3 and anti-myeloperoxidase antibodies, and monoclonal protein were negative. Immunoglobulin E (IgE) levels did not increase during the course, and IgE radioimmunosorbent tests for food, animals and house dust were all negative.

Peritoneal equilibration test with Dianeal-N PD-4 (Baxter, Tokyo, Japan) was performed twice at 6 and 12 months after initiation of PD. The ratio of creatinine concentration in dialysate and plasma (D/P Cr) values was 0.82 and 0.81, which indicates high peritoneal transporter status. Candesartan, diltiazem, furosemide and spironolac-

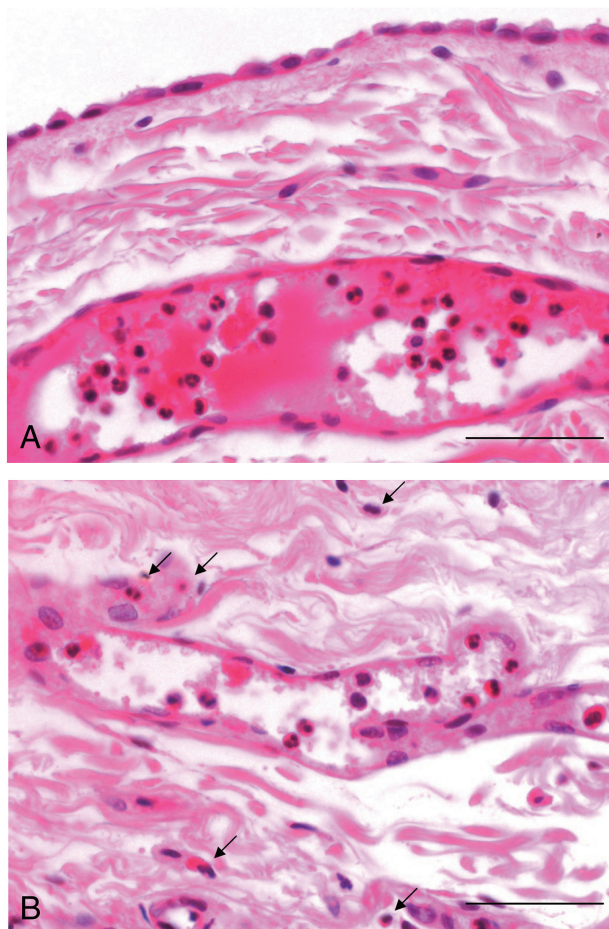


Fig. 1. Pathological findings of peritoneum. (A) H&E stain. Numerous eosinophils in dilated blood vessels of the peritoneum are seen. Mesothelial cells are preserved. Scale bars = 50 μ m. (B) H&E stain. Clusters of eosinophils are observed in blood vessels. Arrows indicate the possible features of eosinophil extravasation from venules into the peritoneal interstitium. Scale bars = 100 μ m.

tone were switched to losartan potassium, cilnidipine, eplerenone and torasemide, and antihistamine medication was restarted. However, the extent of cloudiness in peritoneal effluent did not change. He refused to take corticosteroids.

After PD treatment for 18 months, early gastric cancer was found, and laparoscopic partial gastrectomy was performed. We then evaluated the parietal peritoneum biopsied during gastrectomy. CAPD was resumed; however, eosinophilic peritonitis continued, and D/P Cr levels (0.82) did not change 5 months after operation.

Pathologically, mesothelial cells were seen as a monolayer covering the surface of the peritoneum. Numerous eosinophils were observed in the blood vessels, and some were present in the interstitium (Figure 1). On immunohistochemistry, we detected increased chymase- and tryptase-positive mast cell infiltration, as compared with previously reported control tissue [3]. However, macrophage infiltration and CD-31- and pathologic anatomie Leiden-endothelium (PAL-E)-positive blood vessels were not elevated in comparison with previous control data [4] (Figure 2) (Supplementary Data). No evidence of parasites, granulomas or vasculitis was identified.

Discussion

Eosinophilic peritonitis usually occurs within the first 3 months of initiating dialysis, although it has been reported to occur much later [1]. The natural course of eosinophilic peritonitis appears to be self limiting, although the process may continue for as long as 5 months [1]. Therefore, there is no sufficient information on pathological findings, and there have been no case reports of chronic eosinophilic peritonitis. Peritoneal eosinophilia is reported to be associated with peripheral blood eosinophilia in 57% of patients [1]. In this case, peripheral blood eosinophilia was detected when skin eruption had appeared prior to insertion of the Tenckhoff catheter. We also found a strong infiltration of eosinophils in the peritoneal blood vessels. These findings suggest that the present case of eosinophilic peritonitis is associated with non-PD-related allergic reactions, and that this eosinophilic reaction is not only localized in the peritoneal membrane. Interestingly, gastric cancer was reported to be associated with eosinophilia and to be related to the prognosis [5,6]. However, the relationship between eosinophilic peritonitis and gastric cancer was not clear in this case.

The histological findings in the peritoneum differed when compared to those in recurrent episodes of eosinophilic peritonitis in EPS after PD treatment for <4 years [2]. Our case did not show detachment of mesothelial cells and fibrin exudation (Figure 1A); however, these were seen in the former case. The prominent features in our case were clustering of eosinophils extravasating from blood vessels (Figure 1B). Numerous mast cells were seen in the peritoneum, while the number of blood vessels and macrophages did not increase (Figure 2).

The classical pathway of mast cell activation in allergic reactions is through IgE–Fcε cross-linking, and this is involved in host defence against allergic diseases. Mast cells are also thought to participate in the inflammatory response and fibrosis due to their ability to secrete various inflammatory mediators [7,8]. High peritoneal permeability, as assessed by D/P Cr in this case, was confirmed in the absence of neoangiogenesis. Thus, inflammatory mediators may be involved in developing high peritoneal solute transport by increasing vascular permeability; for example, tryptase may accelerate vascular permeability as a result of direct or indirect generation of bradykinin [8]. Corticosteroid therapy is not usually recommended [1], but has recently been reported to be effective for severe cases of eosinophilic peritonitis, and may be useful for blocking these mechanisms, thereby controlling peritoneal permeability [9,10].

Supplementary data

Supplementary data is available online at <http://ndt.oxfordjournals.org>.

Acknowledgements. The authors are grateful for the technical assistance of Mr Norihiko Suzuki, Ms Naoko Asano and Ms Yuriko Sawa (Department of Nephrology, Nagoya University, Nagoya, Japan).

Conflict of interest statement. None declared.

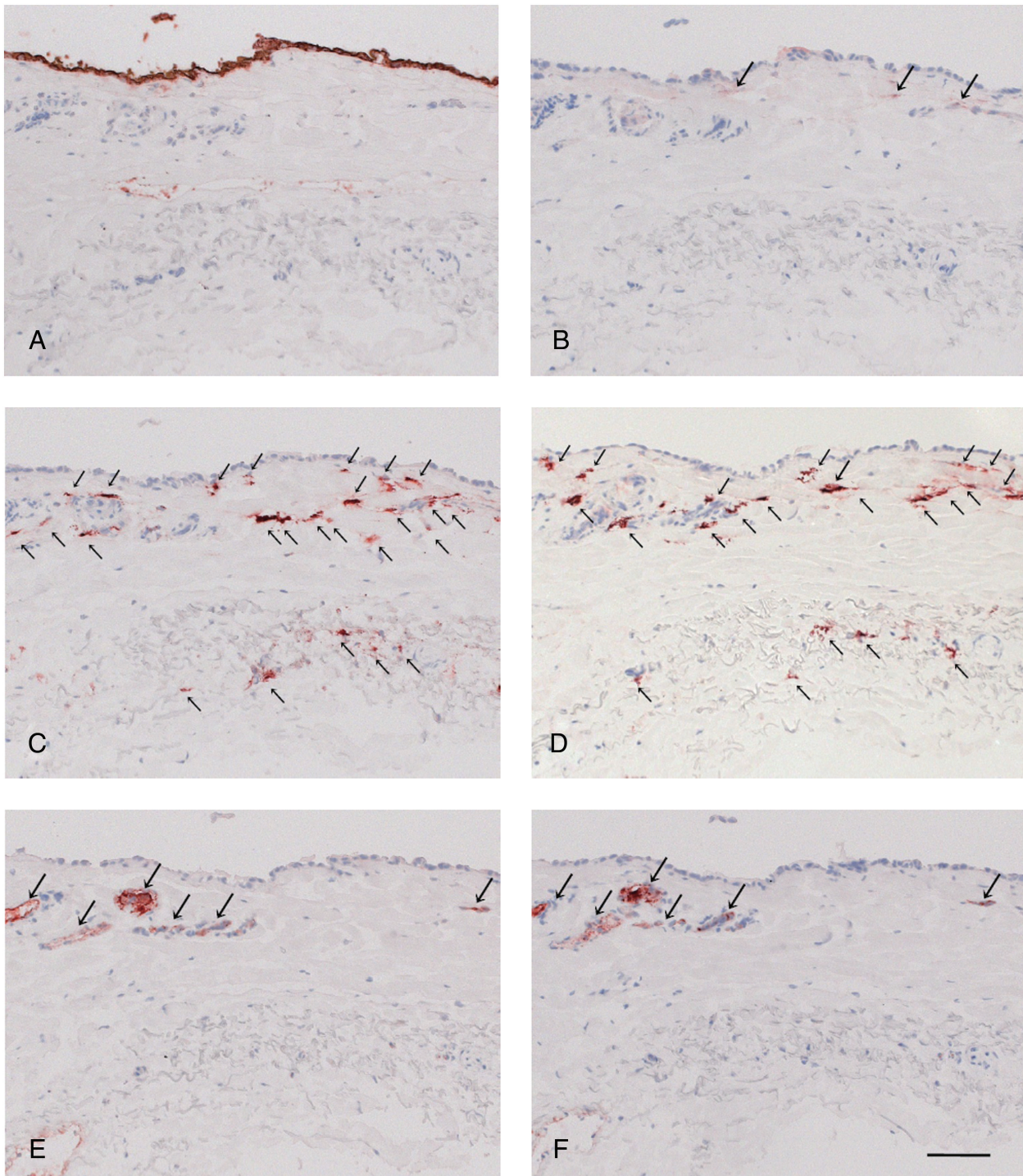


Fig. 2. Immunohistochemistry of peritoneum. Immunohistochemistry was performed on serial sections of frozen tissues for mesothelial cells (A), CD68-positive macrophages (arrows, B), chymase-positive mast cells (arrows, C), tryptase-positive macrophages (arrows, D), CD31-positive vessels (arrows, E) and PAL-E positive vessels (arrows, F). Scale bars = 100 μ m.

References

1. Chan MK, Chow L, Lam SS *et al.* Peritoneal eosinophilia in patients on continuous ambulatory peritoneal dialysis: a prospective study. *Am J Kidney Dis* 1988; 11: 180–183
2. Nakamura Y, Okada H, Yasui A *et al.* Sclerosing encapsulating peritonitis associated with recurrent eosinophilic peritonitis. *Nephrol Dial Transplant* 1999; 14: 768–770
3. Jiménez-Heffernan JA, Bajo MA, Perna C *et al.* Mast cell quantification in normal peritoneum and during peritoneal dialysis treatment. *Arch Pathol Lab Med* 2006; 130: 1188–1192
4. Williams JD, Craig KJ, Topley N *et al.* Morphologic changes in the peritoneal membrane of patients with renal disease. *J Am Soc Nephrol* 2002; 13: 470–479
5. Teoh SC, Siow WY, Tan HT. Severe eosinophilia in disseminated gastric carcinoma. *Singapore Med J* 2000; 41: 232–234

6. Iwasaki K, Torisu M, Fujimura T. Malignant tumor and eosinophils. I. Prognostic significance in gastric cancer. *Cancer* 1986; 58: 1321–1327
7. Holdsworth SR, Summers SA. Role of mast cells in progressive renal diseases. *J Am Soc Nephrol* 2008; 19: 2254–2261
8. Nigrovic PA, Lee DM. Mast cells in inflammatory arthritis. *Arthritis Res Ther* 2005; 7: 1–11
9. Asghar R, Woodrow G, Turney JH. A case of eosinophilic peritonitis treated with oral corticosteroids. *Perit Dial Int* 2000; 20: 579–580
10. Thakur SS, Unikowsky B, Prichard S. Eosinophilic peritonitis in CAPD: treatment with prednisone and diphenhydramine. *Perit Dial Int* 1997; 17: 402–403

Received for publication: 7.8.09; Accepted in revised form: 12.4.10