




Case Report

Sensorineural Hearing Impairment Recovery after Transmastoidal Surgery for a Petrous Apex Cholesterol Granuloma: A Case Report

Stan van Keulen^{1*}, Walter J. Szeweryn^{2*} , Thijs T.G. Jansen² , Stijn Bekkers² ,
Henricus P.M. Kunst²

¹Department of Oral and Maxillofacial Surgery, Radboud University Medical Center, Nijmegen, The Netherlands

²Dutch Academic Alliance Skull Base Pathology, Radboud University Medical Center, Maastricht University Medical Center+, Nijmegen/Maastricht, The Netherlands

ORCID IDs of the authors: W.J.S. 0000-0002-7388-9651; T.T.G.J. 0000-0002-4842-6954; S.B. 0000-0002-8330-9243.

Cite this article as: van Keulen S, Szeweryn WJ, Jansen TTG, Bekkers S, Kunst HPM. Sensorineural hearing impairment recovery after transmastoidal surgery for a petrous apex cholesterol granuloma: A case report. *J Int Adv Otol.* 2022;18(5):447-450.

Cholesterol granulomas are the most common primary lesions of the petrous apex. Although their benign character, impingement of critical neurovascular structures can cause significant symptomatology such as hearing impairment. We present unique results after treatment of a cholesterol granuloma located in the petrous apex causing sensorineural hearing impairment. A transmastoidal approach was performed using an intraoperative computed tomography-guided navigation system. The video, which is included for reference, illustrates clear drainage of the cyst and drain positioning. The hearing improved completely in the lower frequencies at 500 and 1000 Hz and with a 19 dB improvement in overall bone conduction in the affected ear.

KEYWORDS: Cholesterol granuloma, petrous bone, hearing loss, neurotology

INTRODUCTION

Cholesterol granulomas of the petrous apex are rare cystic lesions with an estimated incidence of approximately 0.6 per 1 million people in the general population.¹ The etiology remains uncertain, although it is thought that cholesterol granulomas are a result of an inflammatory response caused by cholesterol crystal formation from degenerated blood.² Extension of the lesion can cause significant neurological symptoms correlating to the compression of cranial nerves VI, VII, and VIII. Surgical decompression within the window of opportunity has shown improvement in multiple cases.³

As cholesterol granulomas lack epithelial lining, total surgical excision is not crucial and one can suffice with marsupialization. If permanent aeration of the cavity is guaranteed by the use of stents, recurrence rates of Petrous Apex Cholesterol Granuloma (PACG) can be reduced with reported recurrence rates dropping from 10.7% to 4.3%.^{4,5} Various surgical entry routes are feasible depending on location and their relation to critical neurovascular structures.

We present unique treatment results of a cholesterol granuloma situated in the petrous apex causing sensorineural hearing impairment of the left ear. This is, to the best of our knowledge, the first reported case of sensorineural hearing recovery after transmastoidal drainage of a PACG.

CASE PRESENTATION

A 53-year-old male presented with progressive complaints of headache, vertigo, continuous tinnitus, and unilateral hearing loss, all with detriment to the left side. Past medical history was significant for hypertension and an earlier diagnosed subclinical subarachnoid cyst located in the left temporal region. Physical examination showed the Weber test lateralizing to the left with a positive Rinne test bilaterally. The electronystagmography demonstrated symmetrical vestibular stimulation. The results of audiology

*Equally contributed as first two authors.

Corresponding author: Walter J. Szeweryn, e-mail: walter.szeweryn@radboudumc.nl

Received: April 20, 2021 • **Accepted:** December 13, 2021 • **Available Online Date:** August 10, 2022

Available online at www.advancedotology.org



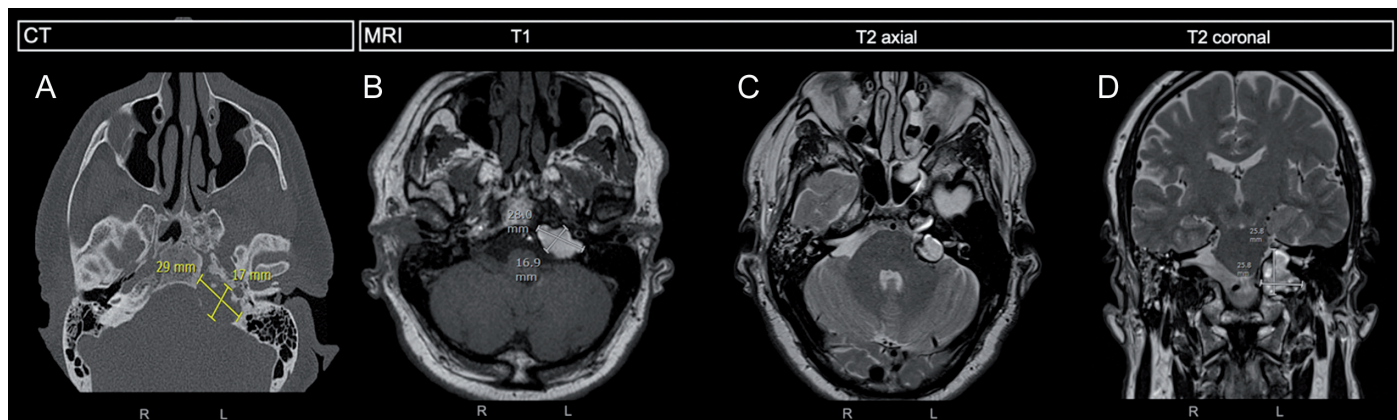


Figure 1. a-d. Preoperative radiologic findings. (A) The axial CT reconstruction, used for navigation, of a low-density expansive mass in the left petrous apex with corresponding radiographic measurements. (B) T1 axial MRI reconstruction with corresponding radiographic measurements. (C-D) T2 axial and coronal MRI reconstruction. (B-C-D) The dorsal margin of the well-circumscribed mass reached the internal acoustic meatus with a clear displacement of the vestibulocochlear nerve. The anterolateral margin remained within the petrous apex, whereas the medial margin expanded toward the lateral side of the internal carotid artery. CT, computed tomography; MRI, magnetic resonance imaging.

testing at the presentation were asymmetrical sensorineural hearing loss with 0-5 dB at 500 and 1000 Hz and an overall bone conductive (BC) hearing loss of 15 dB. Magnetic resonance imaging (MRI) showed a homogenous hyper-intensive mass on T₁-weighted MRI and a heterogenous mixture of hypo- and hyperintensive mass on T₂-weighted MRI. Its radiographic character was a suspect for a cholesterol granuloma in the left petrous apex.

A *wait and scan* management strategy (consisting of yearly MRI and audiogram) revealed significant growth of the lesion, with yearly growth in the craniocaudal direction of 19 to 23 mm and to 29 mm preoperatively (Figure 1). Eventually, the patient developed spasms in the left corner of the mouth suggesting NVII involvement. At this point, sensorineural hearing loss progressed to 20 dB at 500 and 1000 Hz with an overall BC hearing loss of 32 dB.

Subsequently, a transmastoidal, infralabyrinthine approach was used for drainage of the PACG using a computed tomography (CT)-guided navigation system (see supplemental video). After mastoidectomy, identification of the posterior semicircular canal (PSC) was accomplished. The PSC was used as the most superior dissection border during CT-navigation. The jugular bulb was exposed following the sigmoid sinus. We then proceeded in the medial direction, cranial to the jugular bulb and cochlear aqueduct, caudal to the otic capsule and the cochlear aqueduct, and posterior to the mastoid segment of

the facial nerve. The lateral wall of the PACG was reached and opened with subsequent evacuation of a high volume of dense yellow liquid (Figure 2). The cyst was marsupialized and its drainage pathway was opened further. Before leaving a ventricle drain for aeration, the outermost medial wall of the PACG was identified using CT-guided navigation. By doing this, complete cyst drainage is ensured and the extent of drain placement in the remaining cavity can be assessed. Consequently, fibrine glue (Tissucol) was wrapped around the drain and a gelatin hemostatic sponge (Gelfoam) was left in the epi-tympanic recess before closing. No postoperative complications were encountered.

The patient reported complete resolution of the spasm in the left corner of the mouth and improvement of vertigo and hearing in the left ear. Postoperative audiograms revealed recovery from 20 dB preoperatively to 5 dB postoperatively at 500 and 1000 Hz. Overall BC improved from 32 to 17 dB (Figure 3). Five months postoperatively an MRI revealed a substantial reduction of the lesion with correct positioning of the drain. The patient was last seen 6 months after surgery and is now subjected to yearly follow-up with audiogram and MRI.

DISCUSSION

Tumor growth and symptom progression of a cholesterol granuloma in the left petrous apex of a 54-year-old male led us to the treatment of the lesion by a transmastoidal, infralabyrinthine approach. Using CT-guided navigation, the outermost medial border of the PACG was

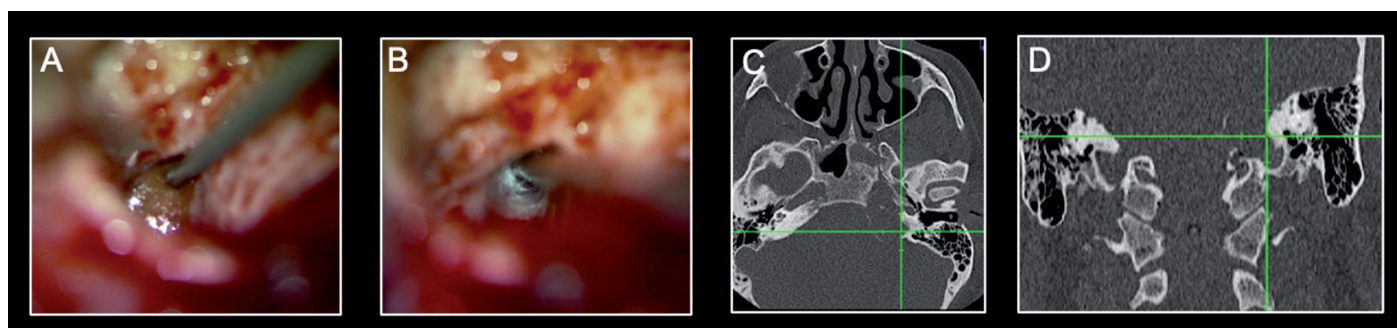


Figure 2. a-d. Intraoperative findings with corresponding CT-navigation (A and C) at the point of entry at the lateral wall of the PACG after mastoidectomy with subsequent drainage. (B and D) Identifying most medial wall of the PACG. CT, computed tomography.

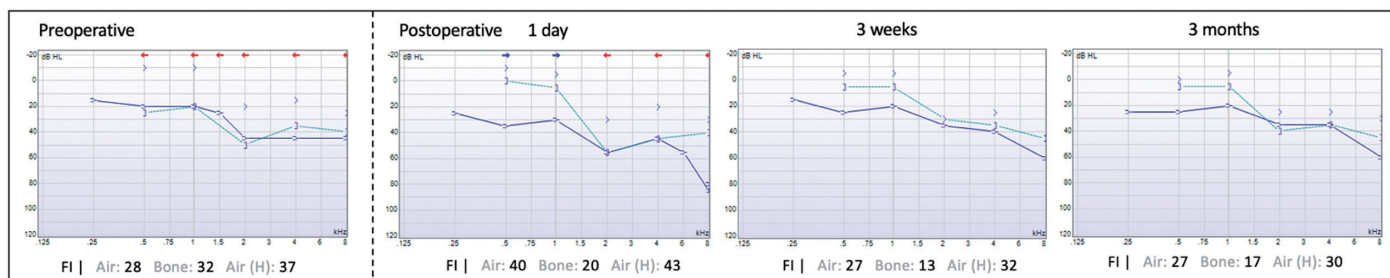


Figure 3. Pre- and postoperative audiograms of the left ear. The audiogram illustrates a clear recovery to normal hearing at 500 Hz and 1 kHz and an overall improvement in bone conduction.

identified, guaranteeing complete surgical drainage of the lesion. During postoperative follow-up, our case demonstrated complete recovery of hearing loss in the lower frequencies (500 and 1000 Hz) and an overall improvement in BC hearing.

Symptomatology of a PACG usually entails hearing loss, tinnitus, vertigo, headaches, and diplopia as a result of direct pressure on cranial nerves.³ Lower cranial nerve defects are less common. In our case, compression of NVII and NVIII was the most likely cause of vertigo, unilateral sensorineural hearing loss, and facial spasms. Drainage of the lesion caused decompression of these critical structures and eventually improvement of symptoms.

As the majority of these lesions remain stable or show little growth over time, and treatment remains anatomically challenging, monitoring patients without impingement of adjacent neurovascular structures is justified. This *wait and scan* strategy comprises frequent MRI, audiograms, and follow-up evaluation of possible symptom progression.⁶

However, when symptoms and/or growth are observed, surgical marsupialization remains the treatment of choice.³ The goal of surgery is to drain the cyst and leave the cavity aerated to prevent reaccumulation of fluid. The variety of surgical approaches remains subject to ongoing debate. Currently, lateral routes such as transmastoidal (infralabyrinthine, translabyrinthine) and middle fossa approaches together with endonasal approaches are used to gain entrance to the petrous apex. More recently, endoscopic endonasal approaches have rapidly gained popularity, mainly in lesions directly adjacent to the sphenoid sinus.⁷⁻⁹ From all transtemporal routes, the translabyrinthine approach provides the most direct access to the petrous apex with early identification of the facial nerve. Due to the obliteration of the labyrinth, this approach is solely reserved for the non-hearing patient. Alternatively, a transmastoidal infralabyrinthine or a infracochlear approach is a solution for the hearing patient. In the latter, dissecting is between the jugular bulb and carotid artery just below the level of the cochlea.

In our particular patient, we have chosen the transmastoidal, infralabyrinthine approach, with special attention to avoiding damage to the cochlear aqueduct. This approach offers safe access to the petrous apex in terms of neurovascular structures together with an uncomplicated aeration possibility through the mastoid cavity.¹⁰ Other advantages are the conservation of normal external and middle-ear functioning.⁴ This access route, however, does require proper aeration of the temporal bone, allowing the surgeon to reach the granuloma without damaging the vestibulum or cochlear

aqueduct when accessing it. Consequently, vertigo, further hearing impairment, and damage to the facial nerve and chorda tympani should be discussed preoperatively, besides general surgical risks such as a disappointing result, infection, and bleeding. Satisfying results from surgical treatment can be established through sufficient drainage and permanent aeration of the cavity. Long-term follow-up is warranted as recurrence is estimated at approximately 15% (in 34 patients),⁴ mostly caused by obliteration of the drainage canal by fibrotic tissue.¹¹

CONCLUSION

Our findings illustrate the unique case of unilateral sensorineural hearing impairment recovery after marsupialization of a petrous apex cholesterol granuloma using transmastoidal, infralabyrinthine approach. Complete drainage of the lesion was ensured by identifying the most medial wall using CT-guided navigation and leaving a drain in situ.

Informed Consent: Written informed consent was obtained from the patient who participated in this study.

Peer-review: Externally peer-reviewed.

Author Contributions: Concept – S.B., S.v.K., W.J.S., T.T.G.J., H.P.M.K.; Design – S.v.K., S.B., W.J.S.; Supervision – H.P.M.K.; Materials – S.v.K., S.B., W.J.S.; Data Collection and/or Processing – S.v.K., S.B., W.J.S.; Analysis and/or Interpretation – S.v.K., S.B., W.J.S.; Literature Review – S.v.K., S.B., W.J.S.; Writing Manuscript – S.B., S.v.K., W.J.S., T.T.G.J., H.P.M.K.; Critical Review – S.B., S.v.K., W.J.S., T.T.G.J., H.P.M.K.

Declaration of Interests: The authors declare that they have no conflict of interest.

Funding: The authors declared that this study has received no financial support.

Video: <https://youtu.be/-h2uBOf08tg>.

REFERENCES

- Mosnier I, Cyna-Gorse F, Grayeli AB, et al. Management of cholesterol granulomas of the petrous apex based on clinical and radiologic evaluation. *Otol Neurotol*. 2002;23(4):522-528. [\[CrossRef\]](#)
- Oyama K, Ikezono T, Tahara S, Shindo S, Kitamura T, Teramoto A. Petrous apex cholesterol granuloma treated via the endoscopic transsphenoidal approach. *Acta Neurochir (Wien)*. 2007;149(3):299-302. [\[CrossRef\]](#)
- Isaacson B. Cholesterol granuloma and other petrous apex lesions. *Otolaryngol Clin North Am*. 2015;48(2):361-373. [\[CrossRef\]](#)
- Brackmann DE, Toh EH. Surgical management of petrous apex cholesterol granulomas. *Otol Neurotol*. 2002;23(4):529-533. [\[CrossRef\]](#)

5. Eytan DF, Kshetry VR, Sindwani R, Woodard TD, Recinos PF. Surgical outcomes after endoscopic management of cholesterol granulomas of the petrous apex: a systematic review. *Neurosurg Focus*. 2014;37(4):E14. [\[CrossRef\]](#)
6. Raghavan D, Lee TC, Curtin HD. Cholesterol granuloma of the petrous apex: a 5-year review of radiology reports with follow-up of progression and treatment. *J Neurol Surg B Skull Base*. 2015;76(4):266-271. [\[CrossRef\]](#)
7. Kohanski MA, Palmer JN, Adappa ND. Indications and endonasal treatment of petrous apex cholesterol granulomas. *Curr Opin Otolaryngol Head Neck Surg*. 2019;27(1):54-58. [\[CrossRef\]](#)
8. Royer MC, Pensak ML. Cholesterol granulomas. *Curr Opin Otolaryngol Head Neck Surg*. 2007;15(5):319-322. [\[CrossRef\]](#)
9. Zanation AM, Snyderman CH, Carrau RL, Gardner PA, Prevedello DM, Kassam AB. Endoscopic endonasal surgery for petrous apex lesions. *Laryngoscope*. 2009;119(1):19-25. [\[CrossRef\]](#)
10. Wilson DF, Hodgson RS. Transmastoid infralabyrinthine approach to petrous temporal bone. *Skull Base Surg*. 1991;1(3):188-190. [\[CrossRef\]](#)
11. Thedinger BA, Nadol JB, Jr, Montgomery WW, Thedinger BS, Greenberg JJ. Radiographic diagnosis, surgical treatment, and long-term follow-up of cholesterol granulomas of the petrous apex. *Laryngoscope*. 1989;99(9):896-907. [\[CrossRef\]](#)