



## ■ HIP

# Surgical treatment of femoroacetabular impingement following slipped capital femoral epiphysis

## A SYSTEMATIC REVIEW

**K. O. Oduwole,  
D. de SA,  
J. Kay,  
F. Findakli,  
A. Duong,  
N. Simunovic,  
Y-M. Yen,  
O. R. Ayeni**

McMaster University,  
Hamilton, Ontario,  
Canada

■ K. O. Oduwole, MCh, FRCSC, Fellow, Division of Orthopaedic Surgery,  
■ D. de SA, MD, FRCSC, Resident, Division of Orthopaedic Surgery,  
■ J. Kay, MD, Resident, Division of Orthopaedic Surgery,  
■ O. R. Ayeni, MD, MSc, FRCSC, Associate Professor, Division of Orthopaedic Surgery, Department of Surgery,  
■ F. Findakli, MBBS, Research Assistant, Centre for Evidence Based Orthopaedics,  
■ A. Duong, MSc, Clinical Research Coordinator, Centre for Evidence Based Orthopaedics,  
■ N. Simunovic, MSc, Research Coordinator, Centre for Evidence Based Orthopaedics, Department of Clinical Epidemiology and Biostatistics, McMaster University, Hamilton, Ontario, Canada.  
■ Y-M. Yen, MD, PhD, Assistant Professor, Division of Orthopaedic Surgery, Harvard Medical School, Boston, Massachusetts, USA.

Correspondence should be sent to O. R. Ayeni;  
email: femiyeni@gmail.com

doi: 10.1302/2046-3758.68.BJR-2017-0018.R1

*Bone Joint Res* 2017;6:472–480.  
Received: 20 January 2017;  
Accepted: 4 April 2017

### Objectives

The purpose of this study was to evaluate the existing literature from 2005 to 2016 reporting on the efficacy of surgical management of patients with femoroacetabular impingement (FAI) secondary to slipped capital femoral epiphysis (SCFE).

### Methods

The electronic databases MEDLINE, EMBASE, and PubMed were searched and screened in duplicate. Data such as patient demographics, surgical technique, surgical outcomes and complications were retrieved from eligible studies.

### Results

Fifteen eligible level IV studies were included in this review comprising 261 patients (266 hips). Treatment groups included arthroscopic osteochondroplasty, surgical hip dislocation, and traditional open osteotomy. The mean alpha angle corrections were 32.14° (standard deviation (SD) 7.02°), 41.45° (SD 10.5°) and 6.0° (SD 5.21°), for arthroscopy, surgical hip dislocation, and open osteotomy groups, respectively ( $p < 0.05$ ). Each group demonstrated satisfactory clinical outcomes across their respective scoring systems. Major complication rates were 1.6%, 10.7%, and 6.7%, for arthroscopy, surgical dislocation and osteotomy treatments, respectively.

### Conclusion

In the context of SCFE-related FAI, surgical hip dislocation demonstrated improved correction of the alpha angle, albeit at higher complication and revision rates than both arthroscopic and open osteotomy treatments. Further investigation, including high-quality trials with standardised radiological and clinical outcome measures for young patients, is warranted to clarify treatment approaches and safety.

**Cite this article:** *Bone Joint Res* 2017;6:472–480.

**Keywords:** Slipped capital femoral epiphysis, Slipped upper femoral epiphysis, Post slipped capital femoral epiphysis, Femoroacetabular impingement, Labrum

### Article focus

■ The purpose of this study was to evaluate the existing literature for the efficacy of surgical management of patients with femoroacetabular impingement (FAI) secondary to slipped capital femoral epiphysis (SCFE) over a ten-year period (2005 to 2016).

### Key messages

■ In the context of SCFE-related FAI, surgical hip dislocation demonstrated improved correction of the alpha angle

albeit at higher complication and revision rates than both arthroscopic and open osteotomy treatments.

■ Further investigation, including high-quality trials with standardised radiological and clinical outcome measures for young patients is warranted to clarify treatment approaches and safety based on femoral head-neck offset.

### Strengths and limitations

■ One of the first systematic reviews of the English literature to evaluate different

surgical treatments for SCFE-related FAI, and is strengthened by a strong rigorous methodology, and thorough data abstraction/analysis.

- Has inherent methodological limitations such as selection, spectrum and inherent language bias.
- Whether statistical differences correlate with minimal clinical important differences remains to be known.

## Introduction

SCFE, a common childhood hip disorder, involves a reduction in the head-neck offset caused by distortion of the proximal femur that accompanies posterior-inferior epiphyseal displacement.<sup>1</sup> To date, surgical treatment with *in situ* pinning remains the benchmark management option.<sup>2,3</sup> However, the residual deformity (i.e. femoral retrotorsion) may lead to a unique metaphyseal “cam” impingement which, though distinctly different from the “cam” of typical FAI, may manifest as changes in passive and active hip range of movement.<sup>4-7</sup> Studies have documented that patients treated with *in situ* pinning following SCFE can develop symptomatic FAI during adolescence.<sup>8-10</sup> FAI may lead to intra-articular pathology at the chondrolabral junction, labrum and femoral head with the potential to develop secondary osteoarthritic changes.<sup>11-13</sup> Thus, several authors have proposed early surgical intervention in order to avert these long-term comorbidities.<sup>14-17</sup>

Currently, the pragmatic approaches to surgical treatment of post-SCFE-related FAI are based on the severity of displacement according to the Southwick classification (slip angle).<sup>18</sup> As such, arthroscopic osteochondroplasty is recommended for mild deformities (slip angle < 30°). Open techniques, be it surgical dislocation of the hip (SDH) with femoral head osteochondroplasty or flexion intertrochanteric osteotomy, are typically reserved for moderate deformities (slip angle 30° to 60°) and severe deformities (slip angle > 60°), respectively.<sup>19,20</sup> However, some studies have shown poor correlation with slip angle severity and risk of developing FAI,<sup>1,5,6,9</sup> with a direct relationship between intra-articular damage and severity of deformity after SCFE remaining unproven.

The purpose of this systematic review was to analyse the available literature on the arthroscopic and open surgical treatment options of FAI secondary to SCFE and to evaluate clinical and radiographic outcomes, complications, and revision rates.

## Materials and Methods

The Preferred Reporting Items for Systematic Reviews and Meta-Analyses (PRISMA) guidelines were used in designing this study.

**Search Strategy.** Two reviewers (OKO, AD) searched three online databases (MEDLINE, EMBASE and PubMed) for literature related to the surgical management of FAI secondary to SCFE deformity. The database search was conducted on 08 August 2016, and retrieved articles

from the date of database inception to 08 August 8, 2016. The following key terms were used in the search: “slipped capital femoral epiphysis”, “slipped upper femoral epiphysis”, “post SCFE”, “femoroacetabular impingement” and “labrum”. A table detailing the search strategy is presented in Supplementary Table i.

**Study screening.** The research question and individual study eligibility criteria were established before the search took place. The inclusion criteria were: all levels of evidence, studies focused on FAI following SCFE treatment in any age or gender, studies published in English, studies on humans and studies reporting, at minimum, one clinical or radiographic outcome. Exclusion criteria were: any non-surgical treatment studies, technique articles without outcomes, cadaver studies, review articles, editorial comments or letters to the editor and instructional course lectures. Studies older than ten years were also excluded.

Two reviewers (FF, JK) independently screened the titles, abstracts, and full texts of the retrieved studies in duplicate, and any discrepancies at the title and abstract stage were resolved by automatic inclusion to ensure thoroughness. Any discrepancies at the full-text stage were resolved by consensus between the two reviewers. If a consensus could not be reached, a third, more senior, reviewer (KOO) resolved the discrepancy. The references of included studies were screened to capture any articles that may have eluded the initial search strategy.

**Quality assessment of included studies.** A quality assessment of all the included studies was completed using the methodological index for non-randomised studies (MINORS) criteria.<sup>21</sup> MINORS represents a validated scoring tool for non-randomised studies (e.g. case reports, case series, cohort studies). Each of the 12 items in the MINORS criteria is given a score of zero, one, or two, giving a maximum score of 16 for non-comparative studies and a maximum score of 24 for comparative studies.

**Data abstraction.** Two reviewers (FF, JK) independently abstracted pertinent study data from the final pool of eligible articles and recorded these data in a Microsoft Excel spreadsheet (Version 2007; Microsoft, Redmond, Washington). Study demographics were abstracted and included author, year of publication, sample size, study design, level of evidence and patient characteristics (gender, age). In addition to demographic information, surgical technique, surgical outcomes and complications were documented. Patients in the primary studies were divided into three main groups according to type of surgical management: those treated with hip arthroscopy and osteochondroplasty, those treated with surgical hip dislocation and osteochondroplasty, +/-intertrochanteric osteotomy, and those treated with open osteotomy (e.g. Southwick, valgus/varus-producing subtrochanteric osteotomies).

Clinical outcomes were abstracted and included hip outcome scores, complication rates and revision surgery rates. For the radiological outcomes, the pre-operative

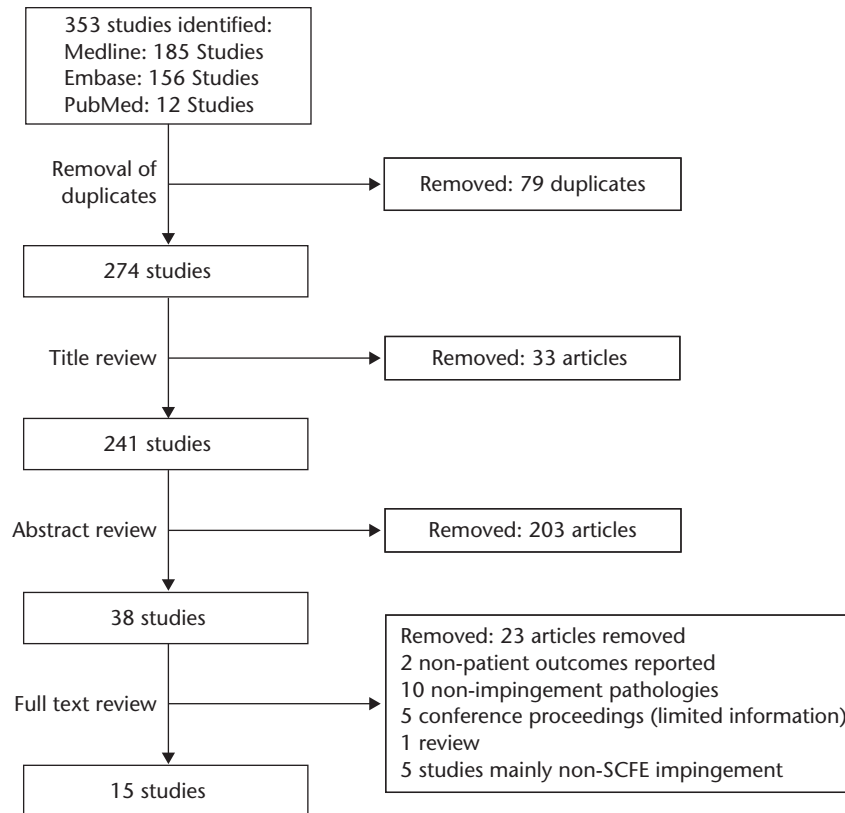


Fig. 1

The Preferred Reporting Items for Systematic Reviews and Meta-Analyses flow diagram demonstrating the systematic review of the literature for surgical treatment of femoroacetabular impingement following slipped capital femoral epiphysis (SCFE).

and post-operative alpha angle measurement on frog-leg lateral plain radiograph or MRI was administered and fully reported by most studies. Hence, it was used to compare the degree of surgical correction between study groups. Other radiographic parameters were inconsistently used among the studies, making them difficult to use as a comparable tool.

**Statistical analysis.** A weighted kappa ( $k$ ) was calculated for each stage of article screening to evaluate inter-reviewer agreement.<sup>21</sup> The agreement was categorised before the search took place as follows: a  $k$  score  $> 0.61$  indicated substantial agreement, 0.21 to 0.60 moderate agreement, and those  $< 0.20$  indicated slight agreement.<sup>22</sup> Descriptive statistics, such as means, ranges and measures of variance (e.g. standard deviation (SD), 95% confidence intervals (CI)) were reported when available. Student  $t$ -tests were used to test for differences in post-operative outcomes between groups. The agreement between the two reviewers for assessment of study quality was calculated using an intraclass correlation coefficient, which evaluates the consistency of multiple observers measuring the same groups of data. Because of heterogeneity among studies, both in terms of patient populations and outcome measures, no meta-analysis was performed.

## Results

**Interviewer agreement in study identification.** There was substantial agreement between reviewers at title ( $k = 0.68$ ; 95% CI 0.66 to 0.69), abstract ( $k = 0.863$ ; 95% CI 0.795 to 0.930), and full-text screening stages ( $k = 0.84$ ; 95% CI 0.81 to 0.87).

**Study characteristics.** Our initial literature search yielded 353 studies of which 38 were reviewed in more detail; 15 were deemed eligible at this point<sup>14-16,23-34</sup> with 23 being excluded<sup>35-57</sup> for this review (Fig. 1). These studies included a total of 261 patients with 266 hips. The treatment groups were as follows: arthroscopy, 85 patients (88 hips); surgical hip dislocation, 131 patients (133 hips); and osteotomy, 45 patients (45 hips). Of the patients treated across the studies, 57.5% were male. The mean ages of patients were 14.1 years (SD 2.96), 15.6 years (SD 2.19), and 13.5 years (SD 0.70) for arthroscopy treatment, surgical hip dislocation and osteotomy, respectively. The mean follow-up for arthroscopy treatment was 20.0 months (SD 7.59), for surgical hip dislocation was 39.45 months (SD 17.9), and for osteotomy was 51.5 months (SD 12.0) (Table I).

**Study quality.** All the included studies were level IV case series or retrospective reviews. There was high agreement among quality assessment scores of included studies using MINORS criteria, with intraclass correlation

**Table I.** Demographic characteristics of individual studies and the groups

Study	Study design	Level of evidence	Type of surgical intervention (cases)	Patients (n)	Hips (n)	M/F	Mean age (yrs), n (range)	Mean follow-up (mths), n (range)	MINOR Score*
<b>Arthroscopy</b>									
Chen et al <sup>23</sup>	Retrospective case series	IV	Hip arthroscopy and osteochondroplasty	31	34	19/18	13.1 (10 to 19)	22 (12 to 56)	11
Tscholl et al <sup>24</sup>	Prospective study	II	Hip arthroscopy and osteochondroplasty	14	14	8/6	12.6 (NR)	17 (11 to 41)	10
Basheer et al <sup>25</sup>	Prospective study	II	Hip arthroscopy and osteochondroplasty	18	18	9/9	19 (13 to 42)	24	10
Wylie et al <sup>26</sup>	Case series	IV	Hip arthroscopy and osteochondroplasty	9	9	6/3	17.5 (13.5 to 26.9)	28.6 (12.6 to 55.6)	9
Lee et al <sup>16</sup>	Case series	IV	Hip arthroscopy and osteochondroplasty	5	5	3/2	10.8 (10 to 14)	6 (3 to 9)	7
Akkari et al <sup>27</sup>	Prospective observational	IV	Hip arthroscopy and osteochondroplasty	5	5	3/2	13.2 (11.11 to 14.8)	26 (12 to 39)	13
Leunig et al <sup>14</sup>	Case series	IV	Hip arthroscopy and osteochondroplasty	3	3	3/0	12.7 (11 to 15)	16.7 (6 to 23)	8
<b>Surgical hip dislocation</b>									
Ziebarth et al <sup>28</sup>	Case series	IV	Surgical hip dislocation, osteochondroplasty	40	40	17/23	12.8 (9 to 18)	55 (12 to 101)	11
Spencer et al <sup>29</sup>	Retrospective case series	IV	Surgical hip dislocation + osteochondroplasty (6); osteoplasty + intertrochanteric osteotomy (6)	12	12	5/7	18.5 (12 to 38)	14 (12 to 25)	10
Abdelazeem et al <sup>30</sup>	Prospective case series	IV	Surgical hip dislocation + osteochondroplasty (25); osteoplasty + osteotomy (6)	31	32	26/5	14 (11 to 17)	24.1 (7 to 14)	12
Rebello et al <sup>31</sup>	Retrospective case series	IV	Surgical hip dislocation + osteoplasty (7); femoral neck osteotomy (4); osteoplasty + intertrochanteric osteotomy (8); ORIF (5); Intertrochanteric osteotomy (5)	29	29	9/20	15.7 (8 to 23)	41.6 (12 to 73)	8
Anderson et al <sup>32</sup>	Retrospective case series	IV	Surgical hip dislocation subcapital osteotomy	11	12	7/4	15 (12 to 19)	61 (6 to 104)	11
Bali et al <sup>33</sup>	Case series	IV	Surgical hip dislocation subcapital osteotomy	8	8	6/2	17.8 (13 to 29)	41 (20 to 84)	10
<b>Osteotomy</b>									
Tjousmakari et al <sup>34</sup>	Therapeutic case series	IV	Transverse subtrochanteric osteotomy	13	13	5/8	14 (11 to 17)	43 (32 to 92)	11
Saisu et al <sup>15</sup>	Therapeutic	IV	Open intertrochanteric flexion osteotomy	32	32	24/8	13 (12 to 17)	60 (24 to 108)	12

\*maximum MINOR score was 16  
MINOR, Methodological index for non-randomised studies; NR not reported

coefficient 0.97 (95% CI 0.96 to 0.98). The included studies had a mean MINORS score of 10.05 (8 to 13), which indicates a fair quality of evidence (Table I), although all studies are considered inherently low-quality evidence as they were retrospective, and did not have a control group for comparison.

**Patient outcomes.** Different radiological measurements such as alpha angle, slip angle, femoral head neck-offset ratio, and centre-edge angle were used in the eligible studies. Alpha angle measurement on the frog-leg lateral plain radiograph was sufficiently administered both pre-operatively and post-operatively in ten of the 15 studies. It was measured on frog-leg lateral radiograph in all of the studies except one that measured it on MRI using radial reformatted MR images.<sup>24</sup> This was used to compare the degree of surgical correction between study groups. The mean alpha angle corrections were 32.14° (SD 7.02°), 41.45° (SD 10.5°) and 6.0° (SD 5.21°) for arthroscopy, surgical hip dislocation and osteotomy, respectively ( $p < 0.05$ ) (Table II).

The clinical outcomes reported in the included studies are presented in Table III. Due to the heterogeneity of these outcome measures, direct comparisons among the three procedures were limited. However, the three types of surgical treatment demonstrated statistically significant improvements in their respective scoring systems ( $p$  values ranging from  $< 0.0001$  to 0.05) except in patients with peri-operative<sup>15,29</sup> or post-operative findings of articular cartilage defect, avascular necrosis or chondrolysis (Table IV).<sup>30,32</sup>

Modified Harris Hip Scores (mHHS) were most commonly reported in arthroscopy ( $n = 3$  studies; 32 hips) and surgical dislocation studies ( $n = 2$  studies; 44 hips). Mean pre-operative mHHS were 45.67 in arthroscopy and 60.95 in surgical hip dislocation treatment. Post-operatively, these scores improved to 84.37 in arthroscopy and 86.65 in surgical dislocation (range of instrument, 0 to 100). Notably, hip arthroscopy was associated with a greater, but statically insignificant, improvement in mHHS of 38.7 *versus* 25.7 in surgical

**Table II.** Mean (and range where available) correction of alpha angles in eligible studies

Type of treatment	Study	Pre-operative alpha angle	Post-operative alpha angle	Mean degree of correction
<b>Arthroscopy</b>	Chen et al <sup>23</sup>	88.22° (70° to 118°)	54.92° (33° to 67°)	32.14°
	Tscholl, et al <sup>24</sup>	57.0° (51° to 74°)	37.0° (32° to 47°)	
	Basheer et al <sup>25</sup>	91.61° (58° to 140°)	51.73°	
	Wylie et al <sup>26</sup>	75.0° (60° to 97°)	46.0° (33° to 58°)	
	Lee et al <sup>16</sup>	76.8° (70° to 85°)	43.4° (40° to 52°)	
	Akkari et al <sup>27</sup>	86.0°	48.7°	
<b>Surgical hip dislocation</b>	Abdelazeem et al <sup>30</sup>	99.97° (87° to 109°)	47.0° (25° to 60°)	41.45°
	Anderson et al <sup>32</sup>	85.0° (79.1° to 90.1°)	56.0° (range, 41.9° to 49.8°)	
	Bali et al <sup>33</sup>	64.4° (50° to 78°)	32.0° (range, 25° to 39°)	
<b>Osteotomy</b>	Saisu et al <sup>15</sup>	82.0° (52° to 119°)	76.0° (43° to 107°)	6.0°

**Table III.** Mean (and range where available) follow-up and Modified Harris Hip scores (mHHS), Western Ontario and McMaster Universities Osteoarthritis Index (WOMAC) and range of movement (ROM) in eligible studies

Type of treatment	Study	Mean follow-up (mths)	Score	Mean improvement
<b>Arthroscopy</b>	Basheer et al <sup>25</sup>	29 (23 to 56)	<b>mHHS pre-operative score</b> 56.2 (27.5 to 100.1)	<b>Post-operative score</b> 75.1 (33.8 to 96.8)
	Wylie et al <sup>26</sup>	28.6 (12.6 to 55.6)	63.6 (33 to 95.7)	91.4 (61.6 to 100)
	Akkari et al <sup>27</sup>	26	17.2	86.6
	Mean		45.67	84.37
<b>Surgical hip dislocation</b>	Abdelazeem et al <sup>30</sup>	24.1 (12 to 40)	67.9 (61 to 74)	96.3 (65 to 100)
	Anderson et al <sup>32</sup>	61 (6 to 104)	54.0 (47.9 to 60.7)	77.0 (64.1 to 89.6)
<b>Arthroscopy</b> <b>Surgical hip dislocation</b>	Spencer et al <sup>29</sup>	No data	<b>WOMAC pre-operative</b> 35.7	<b>Post-operative</b> 17.7
	Abdelazeem et al <sup>30</sup>	24.1 (12 to 40)	64.03 (54 to 72)	97.0 (74 to 100)
	Rebello et al <sup>31</sup>	41.6 (12 to 73)	29.5	16.9
	Mean		43.08	43.87
<b>Arthroscopy</b>	Leunig, et al <sup>14</sup>	29 (6 to 23)	<b>ROM pre-operative IR</b> -6° (-20° to 0°)	<b>Post-operative IR</b> 10 (10° to 10°)
	Basheer et al <sup>25</sup>	24 (interquartile range 24 to 35)	0°	9° (0° to 20°)
	Chen et al <sup>23</sup>	22 (12 to 56)	-22° (-45° to 10°)	10 (-20° to 20°)
	Lee et al <sup>16</sup>	6 (3 to 12)	-16° (-30° to 5°)	11° (0° to 20°)
	Mean		-11°	10
<b>Surgical hip dislocation</b>	Anderson et al <sup>32</sup>	61 (6 to 104)	-35° (-47.7° to -22.3°)	13° (7.2° to 17.8°)
	Spencer et al <sup>29</sup>	14°	-16°	12°
	Abdelazeem et al <sup>30</sup>	24.1° (12° to 40°)	0	40° (10° to 50°)
<b>Osteotomy</b>	Mean		-17°	22°
	Tjoumakari et al <sup>34</sup>	43°	-10°	18°

IR, internal rotation in 90° of hip flexion

dislocation ( $p = 0.56$ ). No study in the osteotomy group reported outcomes using this instrument.

In addition, the Western Ontario and McMaster Universities Osteoarthritis Index (WOMAC) score was reported in three studies that allowed for the comparative assessment of post-operative improvement only in surgical dislocation. This outcome score showed a marginal improvement of 0.79 post-operatively ( $n = 3$  studies; 73 hips).

Pre- and post-operative internal rotation (IR) in 90° of hip flexion was compared among eligible studies in arthroscopy ( $n = 4$  studies; 60 hips), surgical dislocation ( $n = 3$  studies; 56 hips) and osteotomy ( $n = 1$  study;

13 hips) treatments. While there were improvements in these measurements across all of the study groups (arthroscopy IR, 21°; surgical hip dislocation IR, 39°; osteotomy IR, 28°), surgical dislocation treatment showed a statistically insignificant ( $p = 0.18$ ) improvement over arthroscopic and osteotomy treatments. Two studies reported a persistently positive impingement test (flexion, adduction, internal rotation) in about 25% of their patients post-operatively following arthroscopy treatment<sup>15</sup> and osteotomy treatment.<sup>32</sup>

**Complications and revision rates.** Complications and revision surgeries were reported in four arthroscopic treatment studies (62 patients),<sup>23,26,27</sup> in six surgical

**Table IV.** Reported complications from eligible studies

Treatment	Complication rates minor/type, n (%)	Complication rates major/type, n (%)	Revision rates, n (%)	Type of surgery
<b>Arthroscopy</b>				
Chen et al (n = 34) <sup>23</sup>	2 (5.9) iatrogenic labral, acetabular injury	0	3 (8.8)	Revision osteoplasty, 2 x osteotomy for OERD
Wylie et al (n = 9) <sup>26</sup>	4 (44) neuropraxia (peroneal LFC), HO, capsular instability	0	1 (11)	Capsular repair
Tscholl et al (n = 14) <sup>24</sup>	1 (7.1) arthrofibrosis	0	1 (7.1)	Adhesiolysis
Akkari et al (n = 5) <sup>27</sup>	0	1 (20) AVN	1 (20)	0 observation
<b>Surgical Dislocation</b>				
Ziebarth et al (n = 40) <sup>28</sup>	6 (15) HO, 2 x residual FAI	3 (7.5) failure of fixation	5 (12.5)	2 x revision osteoplasty; 3 x revision for screw breakage
Spencer et al (n = 12) <sup>29</sup>	1 (8.3) peroneal neuropraxia	0	0	NA
Abdelazeem et al (n = 31) <sup>30</sup>	0	1 (3.2) AVN, 1 (3.2) deep infection	2 (6.5)	1 x arthroscopic debridement, hardware removal
Rebello et al (n = 29) <sup>31</sup>	2 (6.9) peroneal neuropraxia	2 (6.9) AVN, 1 (3.5) segmental necrosis	2 (6.9)	2 x arthrodesis
Anderson et al (n = 11) <sup>32</sup>	0	4 (36); 2 x AVN; 1 x deep infection; 1 x failure of fixation	4 (36)	2 x THA; 1 x I&D; 1 x revision fixation
Bali et al (n = 8) <sup>33</sup>	0	2 (25) nonunion	2 (25)	Valgus osteotomy
<b>Osteotomy</b>				
Tjounakari et al (n = 13) <sup>34</sup>	5 (38.5); 1 x peroneal neuropraxia, 4 x pin tract infection	1 (7.7) undisplaced; femoral fracture	0	Non-operative
Saisu et al (n = 32) <sup>15</sup>	0	2 (6.3) chondrolysis	1 (3)	Femoral lengthening

OERD, obligatory external rotation deformity; LFC, lateral femoral cutaneous nerve; HO, heterotrophic ossification; FAI, femoroacetabular impingement; THA, total hip arthroplasty; AVN, avascular necrosis; I&D, incision and drainage; NA, not applicable

dislocation studies (131 patients)<sup>28,29,31-33</sup> and in two osteotomy treatment studies (45 patients)<sup>15,34</sup> (Table IV). The minor (and major) complication rates were 11.3% (1.6%), 6.9% (10.7%), and 11.1% (6.7%) for arthroscopy, surgical dislocation, and osteotomy treatments, respectively. Revision rates were 8.1%, 11.5% and 2.2% for arthroscopy, surgical dislocation, and osteotomy, respectively (Table IV).

## Discussion

**Key findings.** The key findings of this review were that all approaches to treat post-SCFE deformity resulted in a significant correction in alpha angle, internal rotation and in patient-reported outcomes, however, surgical dislocation had higher rates of complications and revisions.

The surgical approach to patients with symptomatic FAI secondary to SCFE deformity remains controversial, with some advocating immediate osteoplasty at the time of SCFE pinning.<sup>14,16</sup> Treatment decisions, though typically based on the severity of the slip angle, may not be as reliable as those based on alpha angle measurements.<sup>9,58</sup> Two studies in this review demonstrated that clinical signs of FAI correlated with alpha angle more than with slip angle in SCFE-related impingement.<sup>15,23</sup> Although originally measured on MRI, a previous study showed little benefit over plain radiographs in improving inter-observer agreement in cam-type FAI morphology.<sup>59</sup> Nevertheless, it remains an important measure of cam-type FAI as adequate correction has been correlated with positive outcome following FAI surgery.<sup>60</sup>

Clinical outcome scores showed improvements in all treatment types, with statistically insignificant higher

scores in mHHS in arthroscopy compared with other procedures (Table III). Previous systematic reviews of both procedures in the treatment of FAI revealed superior results for arthroscopic treatment on the 12-Item Short-Form Survey (SF-12) physical component in comparison with surgical dislocation treatment.<sup>61</sup> This systematic review showed a greater improvement in hip internal rotation in surgical dislocation treatment. IR is usually decreased from FAI and may serve as a clinical measurement of impingement severity. As such, determining how much of the reduced IR is due to the retrotorsion of the femur rather than residual post-operative deformity is essential to validate the clinical significance of this physical exam feature.<sup>10,62</sup>

Revision osteoplasty rates due to osseous under-resection are comparable in surgical dislocation (1.5%) and arthroscopic (1.6%) treatments. A cadaveric study by Sussmann et al<sup>63</sup> showed the efficacy of arthroscopic decompressions of the head-neck junction for isolated cam-type impingement, with an accuracy and precision similar to those of an open surgical technique. Thus, depending on the severity of the deformity, some cam-type impingement may be better treated by surgical dislocation.

Surgical hip dislocation was described by Ganz et al<sup>64</sup> to provide a reproducibly safe 360° view of the femoral head and neck, and has long been the standard surgical modality for treating FAI.<sup>64-67</sup> Ganz et al<sup>64</sup> reported successful results of this open technique without any occurrence of avascular necrosis of the femoral head.<sup>64,66</sup> A similar result has not been reproduced in papers included in this systematic review.<sup>30-32</sup> A higher avascular necrosis

(AVN) rate (4.6%) was noted with the use of open techniques (Table IV), possibly due to the smaller number of feeder vessels from the circumflex artery, when compared with arthroscopic and osteotomy treatments. Surgical outcomes in these patients were with poor long-term function.


Future efforts should focus on performing high-quality trials with standardised radiological and clinical outcome measures for young patients to clarify treatment approaches, clinical and radiographic indicators, and optimise patient safety. In addition, given that not all patients with SCFE develop FAI, it would be of clinical relevance to identify the percentage of patients with SCFE that can remodel their proximal femurs, as well as identify factors that make patients more likely to develop the metaphyseal cam deformity.

**Strengths and limitations.** To the best of our knowledge, this is one of the first systematic reviews of the English literature to evaluate different surgical treatments for SCFE-related FAI, and is strengthened by a strong and rigorous methodology and thorough data abstraction/analysis. There are, however, limitations in this review. First, all studies were retrospective, level IV case series. This study design has inherent methodological limitations, such as selection and spectrum bias, that prevent us from answering such questions of importance as, 'how long after the initial SCFE treatment did the second surgery for FAI occur?'. Furthermore, the lack of comparative studies limits the ability to draw definitive conclusions on the efficacy of one procedure in comparison with another based on the available data. This is an English language-only study, which carries an inherent language bias. Second, there were more patients in the surgical dislocation group than there were in the other groups, thus limiting the ability to make direct comparisons. Further, the alpha angle may correct impingement, but not overall deformity, based on Southwick slip angle.<sup>18</sup> Clinical outcome scores were heterogeneous, making direct comparison of functional improvement difficult. Lastly, the hip outcome tools used may not always be applicable to the young hip patients, and whether statistical differences correlate with minimal clinical important differences remains to be seen.

In conclusion, based on the current systematic review, FAI following SCFE might be amenable to open and arthroscopic surgical management with good short-term outcomes. However, we are unable to determine conclusively the superiority of one treatment technique over another. It may be that isolated metaphyseal defects can be managed via an open or arthroscopic approach, with open techniques reserved for cases where arthroscopy cannot provide adequate resection and/or in those patients requiring corrective osteotomy. Further investigation, including high-quality trials with standardised radiological and clinical outcome measures for young

patients, is warranted to clarify treatment approaches, clinical and radiographic indicators, and to optimise patient safety.

### Supplementary material

 A table showing search strategy, and lists of eligible and ineligible studies at review, as well as the Preferred Reporting Items for Systematic Reviews and Meta-Analyses checklist, are available alongside the online version of this article at [www.bjr.boneandjoint.org.uk](http://www.bjr.boneandjoint.org.uk)

### References

1. **Millis MB, Novais EN.** In situ fixation for slipped capital femoral epiphysis. *J Bone Joint Surg [Am]* 2011;93-A(Suppl 2):46-51.
2. **Boyer DW, Mickelson MR, Ponseti IV.** Slipped capital femoral epiphysis. Long-term follow-up study of one hundred and twenty-one patients. *J Bone Joint Surg [Am]* 1981;63-A:85-95.
3. **Carney BT, Weinstein SL, Noble J.** Long-term follow-up of slipped capital femoral epiphysis. *J Bone Joint Surg [Am]* 1991;73-A:667-674.
4. **Goodman DA, Feighan JE, Smith AD, et al.** Subclinical slipped capital femoral epiphysis. Relationship to osteoarthritis of the hip. *J Bone Joint Surg [Am]* 1997;79-A:1489-1497.
5. **Rab GT.** The geometry of slipped capital femoral epiphysis: implications for movement, impingement, and corrective osteotomy. *J Pediatr Orthop* 1999;19:419-424.
6. **Leunig M, Casillas MM, Hamlet M, et al.** Slipped capital femoral epiphysis: early mechanical damage to the acetabular cartilage by a prominent femoral metaphysis. *Acta Orthop Scand* 2000;71:370-375.
7. **Monazzam S, Bomar JD, Pennock AT.** Idiopathic cam morphology is not caused by subclinical slipped capital femoral epiphysis: an MRI and CT study. *Orthop J Sport Med* 2013;1.
8. **Fraitl CR, Käfer W, Nelitz M, Reichel H.** Radiological evidence of femoroacetabular impingement in mild slipped capital femoral epiphysis: a mean follow-up of 14.4 years after pinning in situ. *J Bone Joint Surg [Br]* 2007;89-B:1592-1596.
9. **Dodds MK, McCormack D, Mulhall KJ.** Femoroacetabular impingement after slipped capital femoral epiphysis: does slip severity predict clinical symptoms? *J Pediatr Orthop* 2009;29:535-539.
10. **Mamisch TC, Kim YJ, Richolt JA, Millis MB, Kordelle J.** Femoral morphology due to impingement influences the range of motion in slipped capital femoral epiphysis. *Clin Orthop Relat Res* 2009;467:692-698.
11. **Ganz R, Parvizi J, Beck M, et al.** Femoroacetabular impingement: a cause for osteoarthritis of the hip. *Clin Orthop Relat Res* 2003;417:112-120.
12. **Beck M, Kalhor M, Leunig M, Ganz R.** Hip morphology influences the pattern of damage to the acetabular cartilage: femoroacetabular impingement as a cause of early osteoarthritis of the hip. *J Bone Joint Surg [Br]* 2005;87-B:1012-1018.
13. **Peters CL, Erickson JA.** Treatment of femoro-acetabular impingement with surgical dislocation and débridement in young adults. *J Bone Joint Surg [Am]* 2006;88-A:1735-1741.
14. **Leunig M, Horowitz K, Manner H, Ganz R.** In situ pinning with arthroscopic osteoplasty for mild SCFE: A preliminary technical report. *Clin Orthop Relat Res* 2010;468:3160-3167.
15. **Saisu T, Kamegaya M, Segawa Y, Kakizaki J, Takahashi K.** Postoperative improvement of femoroacetabular impingement after intertrochanteric flexion osteotomy for SCFE. *Clin Orthop Relat Res* 2013;471:2183-2191.
16. **Lee CB, Matheny T, Yen YM.** Case reports: acetabular damage after mild slipped capital femoral epiphysis hip. *Clin Orthop Relat Res* 2013;471:2163-2172.
17. **Ziebarth K, Leunig M, Slongo T, Kim YJ, Ganz R.** Slipped capital femoral epiphysis: relevant pathophysiological findings with open surgery. *Clin Orthop Relat Res* 2013;471:2156-2162.
18. **Southwick WO.** Osteotomy through the lesser trochanter for slipped capital femoral epiphysis. *J Bone Joint Surg [Am]* 1967;49-A:807-835.
19. **Azegami S, Kosuge D, Ramachandran M.** Surgical treatment of femoroacetabular impingement in patients with slipped capital femoral epiphysis: a review of current surgical techniques. *Bone Joint J* 2013;95-B:445-451.

20. **Kuzyk PRT, Kim Y-J, Millis MB.** Surgical management of healed slipped capital femoral epiphysis. *J Am Acad Orthop Surg* 2011;19:667-677.
21. **Slim K, Nini E, Forestier D, et al.** Methodological index for non-randomized studies (Minors): development and validation of a new instrument. *ANZ J Surg* 2003;73:712-716.
22. **McGinn T, Wyer PC, Newman TB, et al; Evidence-Based Medicine Teaching Tips Working Group.** Tips for learners of evidence-based medicine: 3. Measures of observer variability (kappa statistic). *CMAJ* 2004;171:1369-1373.
23. **Chen A, Youderian A, Watkins S, Gourineni P.** Arthroscopic femoral neck osteoplasty in slipped capital femoral epiphysis. *Arthroscopy* 2014;30:1229-1234.
24. **Tscholl PM, Zingg PO, Dora C, et al.** Arthroscopic osteochondroplasty in patients with mild slipped capital femoral epiphysis after in situ fixation. *J Child Orthop* 2016;10:25-30.
25. **Basheer SZ, Cooper AP, Maheshwari R, Balakumar B, Madan S.** Arthroscopic treatment of femoroacetabular impingement following slipped capital femoral epiphysis. *Bone Joint J* 2016;98-B:21-27.
26. **Wylie JD, Beckmann JT, Maak TG, Aoki SK.** Arthroscopic treatment of mild to moderate deformity after slipped capital femoral epiphysis: intra-operative findings and functional outcomes. *Arthroscopy* 2015;31:247-253.
27. **Akkari M, Santili C, Braga SR, Polesello GC.** Trapezoidal bony correction of the femoral neck in the treatment of severe acute-on-chronic slipped capital femoral epiphysis. *Arthroscopy* 2010;26:1489-1495.
28. **Ziebarth K, Zilkens C, Spencer S, et al.** Capital realignment for moderate and severe SCFE using a modified Dunn procedure. *Clin Orthop Relat Res* 2009;467:704-716.
29. **Spencer S, Millis MB, Kim Y-J.** Early results of treatment of hip impingement syndrome in slipped capital femoral epiphysis and pistol grip deformity of the femoral head-neck junction using the surgical dislocation technique. *J Pediatr Orthop* 2006;26:281-285.
30. **Abdelazeem AH, Beder FK, Abdel Karim MM, Abdelazeem H, Abdel-Ghani H.** The anatomical reduction of a moderate or severe stable slipped capital femoral epiphysis by modified Dunn subcapital osteotomy using the Ganz approach: functional and radiological outcomes. *Bone Joint J* 2016;98-B:1283-1288.
31. **Rebello G, Spencer S, Millis MB, Kim YJ.** Surgical dislocation in the management of pediatric and adolescent hip deformity. *Clin Orthop Relat Res* 2009;467:724-731.
32. **Anderson LA, Galilland JM, Pelt CE, Peters CL.** Subcapital correction osteotomy for malunited slipped capital femoral epiphysis. *J Pediatr Orthop* 2013;33:345-352.
33. **Bali K, Railton P, Kiefer GN, Powell JN.** Subcapital osteotomy of the femoral neck for patients with healed slipped capital femoral epiphysis. *Bone Joint J* 2014;96-B:1441-1448.
34. **Tjoumakaris FP, Wallach DM, Davidson RS.** Subtrochanteric osteotomy effectively treats femoroacetabular impingement after slipped capital femoral epiphysis. *Clin Orthop Relat Res* 2007;464:230-237.
35. **Novais EN, Heyworth BE, Stamoulis C, et al.** Open surgical treatment of femoroacetabular impingement in adolescent athletes: preliminary report on improvement of physical activity level. *J Pediatr Orthop* 2014;34:287-294.
36. **Albers CE, Steppacher S, Tannast M, Siebenrock K.** Relative neck lengthening in complex proximal femoral deformities: Technique, complications, and 5-year results. *Swiss Med Wkly* 2014;144:20S.
37. **Sink EL, Zaltz I, Heare T, Dayton M.** Acetabular cartilage and labral damage observed during surgical hip dislocation for stable slipped capital femoral epiphysis. *J Pediatr Orthop* 2010;30:26-30.
38. **Larson AN, McIntosh AL, Trousdale RT, Lewallen DG.** Avascular necrosis most common indication for hip arthroplasty in patients with slipped capital femoral epiphysis. *J Pediatr Orthop* 2010;30:767-773.
39. **McClincy MP, Bosch PP.** Combined surgical dislocation and proximal femoral osteotomy for correction of SCFE-induced femoroacetabular impingement. *Oper Tech Orthop* 2015;23:140-145.
40. **Sucato DJ, De La Rocha A.** High-grade SCFE: the role of surgical hip dislocation and reduction. *J Pediatr Orthop* 2014;34(Suppl 1):S18-S24.
41. **Frey E, Zingg P, Ramseier L, Dora C.** In situ fixation and arthroscopic osteochondroplasty for mild slipped capital femoral epiphysis: can the alpha-angle be normalized? *Swiss Med Wkly* 2013:26S.
42. **Massè A, Aprato A, Grappiolo G, et al.** Surgical hip dislocation for anatomic reorientation of slipped capital femoral epiphysis: preliminary results. *Hip Int* 2012;22:137-144.
43. **Nishiyama K, Sakamaki T, Ishii Y.** Follow-up study of the subcapital wedge osteotomy for severe chronic slipped capital femoral epiphysis. *J Pediatr Orthop* 1989;9:412-416.
44. **Novais EN, Hill MK, Carry PM, Heare TC, Sink EL.** Modified Dunn procedure is superior to in situ pinning for short-term clinical and radiographic improvement in severe stable SCFE. *Clin Orthop Relat Res* 2015;473:2108-2117.
45. **Abu Amara S, Cunin V, Ilharreborde B, French Society of Pediatric Orthopaedics (SOPOP).** Severe slipped capital femoral epiphysis: A French multicenter study of 186 cases performed by the SoFOP. *Orthop Traumatol Surg Res* 2015;101(Suppl):S275-S279.
46. **Muhamad AR, Jonathan R, Abd Hamid MA, Ithnin MN, Osman Z.** Modified Dunn technique through open surgical hip dislocation in treating severe slipped upper femoral epiphysis in two extreme ages of presentation. *Malays Orthop J* 2012:97.
47. **Keith T, Balakumar J.** Radiological assessment of capital realignment surgery following slipped capital femoral epiphyses (SCFE). *Arch Dis Child* 2012;97(Suppl 2):A135.
48. **Chomiak J, Dungal P, Ostadal M, Burian M.** Results of treatment of severe grade of SCFE [abstract]. 10<sup>th</sup> Congress of the European Hip Society. *HIP Int* 2012;4:425-426.
49. **Browne PS, Wainwright D.** Severe irreducible slipping of upper femoral epiphysis: a review of 14 cases treated by subtrochanteric osteotomy. *Injury* 1975;6:213-219.
50. **Adolfson SE, Sucato DJ.** Surgical technique: open reduction and internal fixation for unstable slipped capital femoral epiphysis. *Oper Tech Orthop* 2009;19:6.
51. **Murgier J, Reina N, Cavaignac E, et al.** The frequency of sequelae of slipped upper femoral epiphysis in cam-type femoroacetabular impingement. *Bone Joint J* 2014;96-B:724-729.
52. **Slongo T, Kakaty D, Krause F, Ziebarth K.** Treatment of slipped capital femoral epiphysis with a modified Dunn procedure. *J Bone Joint Surg [Am]* 2010;92-A:2898-2908.
53. **Kocher MS, Kim YJ, Millis MB, et al.** Hip arthroscopy in children and adolescents. *J Pediatr Orthop* 2005;25:680-686.
54. **Ilizaliturri VM Jr, Nossa-Barrera JM, Acosta-Rodriguez E, Camacho-Galindo J.** Arthroscopic treatment of femoroacetabular impingement secondary to paediatric hip disorders. *J Bone Joint Surg [Br]* 2007;89-B:1025-1030.
55. **Albers CE, Steppacher S, Tannast M, Siebenrock K.** Relative neck lengthening in complex proximal femoral deformities: technique, complications and 5-year results. Poster presented at: *Annual Meeting Proceedings of the American Academy of Orthopedic Surgeons*. 2014; New Orleans.
56. **Tibor LM, Ganz R, Leunig M.** Anteroinferior acetabular rim damage due to femoroacetabular impingement. *Clin Orthop Relat Res* 2013;471:3781-3787.
57. **Rudd J, Suri M, Choate W, Heinrich S, Christoforetti J.** Outcomes of arthroscopically treated femoroacetabular impingement in children and adolescents with slipped capital femoral epiphysis and Legg-Calve-Perthes disease. *Arthroscopy* 2013;29:e209-e210.
58. **Nötzli HP, Wyss TF, Stoecklin CH, et al.** The contour of the femoral head-neck junction as a predictor for the risk of anterior impingement. *J Bone Joint Surg [Br]* 2002;84-B:556-560.
59. **Cadet ER, Babatunde OM, Gorroochurn P, et al.** Inter- and intra-observer agreement of femoroacetabular impingement (FAI) parameters comparing plain radiographs and advanced, 3D computed tomographic (CT)-generated hip models in a surgical patient cohort. *Knee Surg Sports Traumatol Arthrosc* 2016;24:2324-2331.
60. **de Sa D, Urquhart N, Philippon M, et al.** Alpha angle correction in femoroacetabular impingement. *Knee Surg Sports Traumatol Arthrosc* 2014;22:812-821.
61. **Nwachukwu BU, Rebollo B, McCormick F, et al.** Arthroscopic versus open treatment of femoroacetabular impingement: a systematic review of medium- to long-term outcomes. *Am J Sports Med* 2016;44:1062-1068.
62. **Wyss TF, Clark JM, Weishaupt D, Nötzli HP.** Correlation between internal rotation and bony anatomy in the hip. *Clin Orthop Relat Res* 2007;460:152-158.
63. **Sussmann PS, Ranawat AS, Lipman J, et al.** Arthroscopic versus open osteoplasty of the head-neck junction: a cadaveric investigation. *Arthroscopy* 2007;23:1257-1264.
64. **Ganz R, Gill TJ, Gautier E, et al.** Surgical dislocation of the adult hip. *J Bone Joint Surg [Br]* 2001;83-B:1119-1124.
65. **Lavigne M, Parvizi J, Beck M, et al.** Anterior femoroacetabular impingement: part I. Techniques of joint preserving surgery. *Clin Orthop Relat Res* 2004;418:61-66.
66. **Beck M, Leunig M, Parvizi J, et al.** Anterior femoroacetabular impingement: part II. Midterm results of surgical treatment. *Clin Orthop Relat Res* 2004;418:67-73.
67. **Ferguson SJ, Bryant JT, Ganz R, Ito K.** An in vitro investigation of the acetabular labral seal in hip joint mechanics. *J Biomech* 2003;36:171-178.



**Funding Statement**

- None declared.
- All authors meet the authorship requirements as stated in the Uniform Requirements for Manuscripts Submitted to Biomedical Journals.

**Author Contributions**

- K. O. Oduwole: Lead author, Contributed to all elements of the study, Study design, Responsible for executing the search for abstracts, Data analysis and presentation, Primary manuscript writer, Responsible for all encompassing and all subsequent revisions throughout the editing process.
- D. de SA: Content expert, Contributed to study design, Data analysis and presentation, Assisted with writing of the manuscript and encompassing subsequent revisions throughout the editing process.
- J. Kay: Primary literature reviewer, Responsible for executing the search for abstracts, Data abstraction, analysis and presentation, Contributed to the writing of the manuscript, Responsible for all encompassing subsequent revisions throughout the editing process.
- F. Findakli: Assisted with literature reviewer, Responsible for executing the search for abstracts, Data abstraction.

- A. Duong: Content expert, Contributed to study design, Data analysis, Manuscript preparation and revision.
- N. Simunovic: Content expert, Contributed to study design, Data analysis, Manuscript preparation and revision.
- Y-M. Yen: Content expert, Contributed to study design, Data analysis, Manuscript preparation and revision.
- O. R. Ayeni: Study supervisor and content expert, Contributed to all elements of the study, Study design, Development of the literature search strategy and grading process, Assisted with data analysis and presentation, Manuscript preparation and revision.

**Conflicts of Interest Statement**

- None declared.

© 2017 Ayeni et al. This is an open-access article distributed under the terms of the Creative Commons Attributions licence (CC-BY-NC), which permits unrestricted use, distribution, and reproduction in any medium, but not for commercial gain, provided the original author and source are credited.