

Original

Bilateral Asynchronous Adrenocortical Adenoma in a Girl with Beckwith-Wiedemann Syndrome

Michiyo Mizota¹, Izumi Tamada¹, Kazuko Hizukuri¹, Kiyoko Otsubo¹, Siu Arima¹,
Yoshifumi Kawano¹, Seigo Ono¹, Yoshihiro Hayashida², Tatsuru Kaji²,
Hideo Takamatsu² and Hironobu Sasano³

¹*Department of Pediatrics, Kagoshima University, Kagoshima,*

²*Department of Pediatric Surgery, Kagoshima University, Kagoshima,*

³*Departments of Pathology, Tohoku University School of Medicine, Sendai, Japan*

Abstract. We report a case of asynchronous occurrence of bilateral adrenocortical adenoma in a 13-yr-old girl with Beckwith-Wiedemann syndrome. A right virilizing adrenal adenoma was surgically removed at age 6, following clinical manifestation of virilization such as acne, voice change, clitoris hypertrophy and overgrowth. Histopathological examination of the resected specimen revealed an adrenocortical adenoma predominantly composed of eosinophilic tumor cells expressing all the steroidogenic enzymes. High serum levels of DHEA-S (6,380 ng/ml) and testosterone (547 ng/dl) were noted prior to the operation. Postoperative course was unremarkable. Menstruation started at age 11, with a regular interval. At the age of 13 yr old, a high serum level of DHEA-S (8,250 ng/ml) was detected. In contrast to the episode of virilization at age 6, however, the serum testosterone level was not so high (122 ng/dl), and no clinical symptoms of virilization were apparent. Abdominal ultrasonography demonstrated the presence of a left adrenocortical adenoma. Pathological examination of the resected specimen revealed a circumscribed and well encapsulated tumor with essentially the same histological features as the tumor previously removed, except that the tumor cells showed a more prominent morphological similarity to the fetal adrenal cortex and did not express 3β HSD. The absence of virilization at the second episode was due to the relatively low serum level of testosterone compared with that of DHEA-S.

Key words: adrenal tumor, virilizing, Beckwith-Wiedemann syndrome

Introduction

Beckwith-Wiedemann syndrome (BWS) is generally considered an "overgrowth syndrome".

Received: July 7, 2004

Accepted: August 20, 2004

Correspondence: Dr. Michiyo Mizota, Department of Pediatrics, Kagoshima University, 8-35-1 Sakuragaoka, Kagoshima City, 890-8520, Japan

E-mail: seven@m.kufm.kagoshima-u.ac.jp

Children with BWS are considered to have increased risk of developing solid tumors such as Wilms' tumor, hepatoblastoma, adrenocortical tumor and others (1). We recently experienced a case of a girl with BWS who had asynchronous occurrence of bilateral adrenocortical adenoma; Here we report our clinical and histopathological findings including immunolocalization of steroidogenic enzymes.

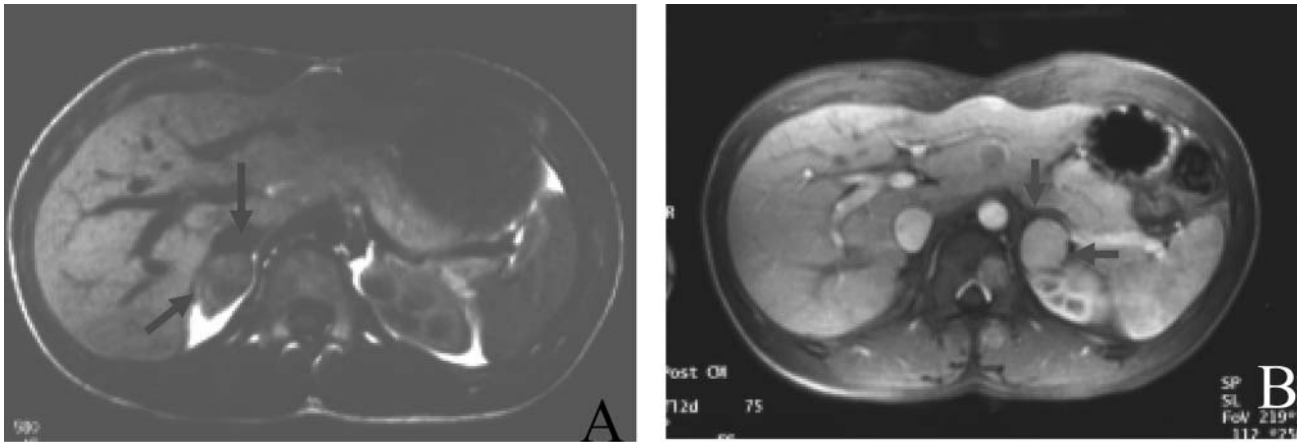


Fig. 1 A: CT scan of abdomen in 1996 showing the right adrenal tumor. B: MRI of abdomen in 2002 showing the left adrenal tumor.

Table 1 Clinical course

		before 1st operation	after	before 2nd operation	after
		1995.12	1996.2	2002.10	2002.11
age		6		13	
blood examination					
ACTH	(pg/ml)	49.2	54	32.3	242
cortisol	(μ g/)	13.8	10.3	9.6	14.4*
DHEA-S	(ng/ml)	6380	107	8250	351
testosterone	(ng/dl)	547	<5	122	41
E ₂	(pg/ml)	89.1	<10	77	274
urine examination					
17KS	(mg/day)	26.8	2	26.1	7.2
17OHCS	(mg/day)	5.1	2.2	6	1.2

*Cortisol supplement therapy was started after the 2nd operation.

Case Report

The patient was a 13-yr-old girl. She was born at 36 wk and her birth weight was 3,224 g. At birth, she was diagnosed with BWS because of intact omphalocele and macroglossia. Omphalocele repair was performed at day 1 of life; macroglossia repair was performed at the age of 1 yr. In 1996, she was referred to us because of symptoms of virilization such as acne, voice change, overgrowth, pubic hair and clitoris hypertrophy at the age of 6 yr. High serum levels of

dehydroepiandrosterone sulfate (DHEA-S) (6,380 ng/ml) (age-matched normal range: 49–831) and testosterone (547 ng/dl) were detected. The 24-h urinary 17-ketosteroids (17KS) secretion was also high (26.8 mg/day). Ultrasonography and CT scan of the abdomen revealed the presence of a right adrenal tumor (Fig. 1A). The right adrenal gland was totally resected. The tumor measured 2 × 2.5 × 2 cm. Postoperative course was unremarkable. Menstruation started at age 11, with a regular interval. In 2002, at the age of 13 yr old, a high serum level of DHEA-S (8,250 ng/ml) (age-

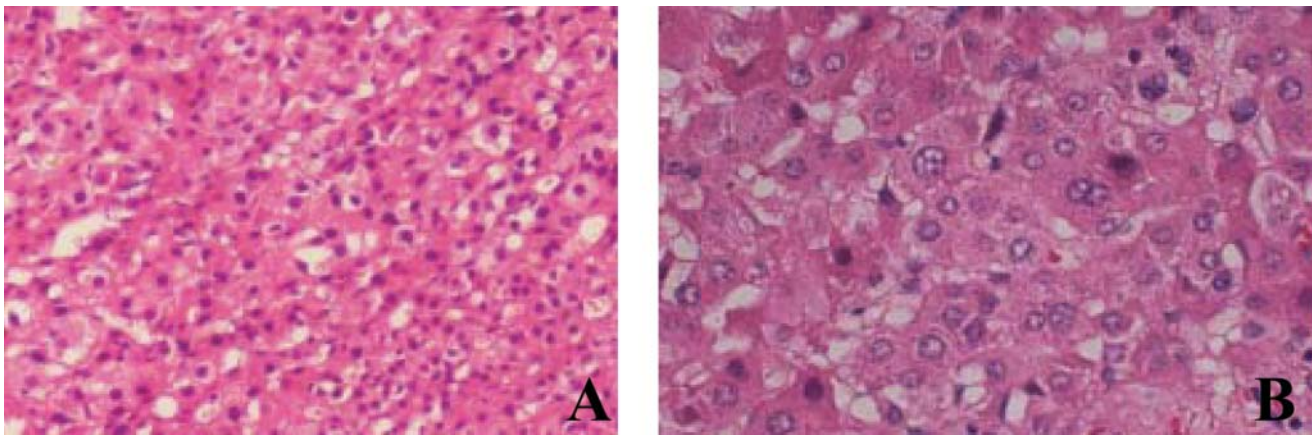


Fig. 2 Histopathological findings. A: The tumor cells resected in 1996 revealed eosinophilic cytoplasm and trabeculae formation. Some tumor cells formed a pseudoglandular architecture. B: The tumor cells resected in 2002 also revealed eosinophilic cytoplasm, but a greater amount of pseudoglandular formation was noted compared to the tumor resected in 1996.

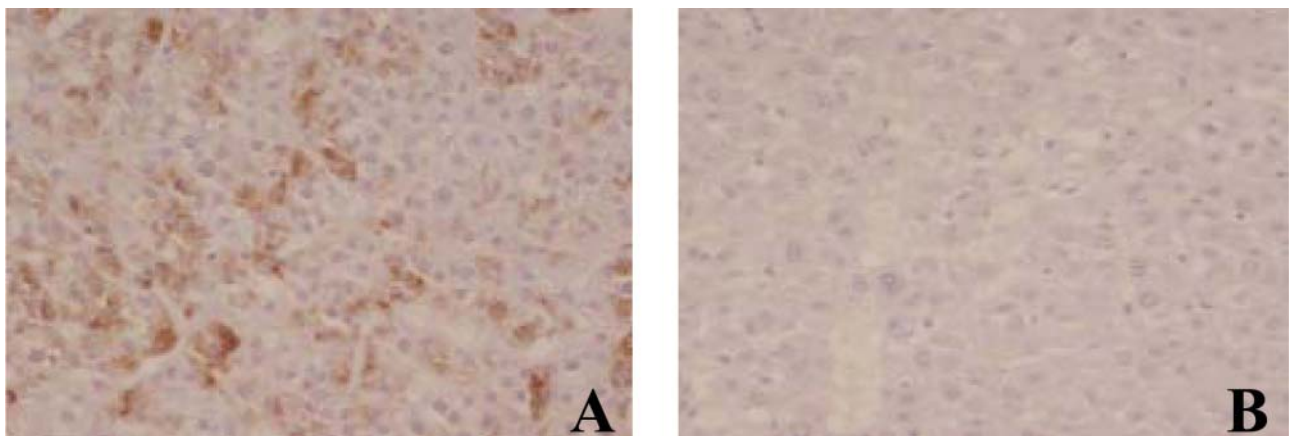


Fig. 3 Immunohistochemistry of the steroidogenic enzymes for 3β HSD. A: Immunoreactivities for 3β HSD were detected in 1996. B: No immunoreactivities for 3β HSD were detected in 2002.

matched normal range: 322–2,490) was noted. Serum testosterone level was, however, not elevated (122 ng/dl) (age-matched normal range: 5–63.2) in contrast to the first episode described above. The 24-h urinary 17KS secretion was high (26.1 mg/day) (Table 1). Abdominal ultrasonography and MRI demonstrated the presence of a left adrenal tumor (Fig. 1B). The resected tumor was circumscribed and well encapsulated, measuring $3 \times 2.5 \times 2$ cm.

Following surgery, the serum level of ACTH continued to be elevated, and adrenocortical hormone supplement therapy was started.

Histopathological Findings

Histopathological examination revealed eosinophilic cytoplasm and trabeculae formation in the great majority of the tumor cells resected in 1996 (Fig. 2A). Some tumor cells formed a

pseudoglandular architecture, which is considered characteristic of the adrenal cortex in patients with BWS.

Histopathological examination of the tumor resected in 2002 revealed that this tumor was also comprised of tumor cells with eosinophilic cytoplasm, but a greater amount of pseudoglandular formation was noted, and adrenocortical tissues morphologically resembling fetal adrenal cortex were also noted (Fig. 2B).

Immunohistochemistry of the steroidogenic enzymes for P450scc (cholesterol side chain-cleavage enzyme), 3 β HSD (3 β hydroxysteroid dehydrogenase), P450c21 (21-hydroxylase), P450c11 (11 β hydroxylase), P450c17 (17 α hydroxylase), and DHEA-ST (dehydroepiandrosterone sulfotransferase) was performed.

Immunoreactivities with P450scc and P450c17 were seen in almost all tumor cells in 1996; reactivities with P450c21, 3 β HSD, P450c11, and DHEA-ST, though seen, were not as prevalent (Fig. 3A).

Immunoreactivities with P450scc and P450c17 were detected in almost all tumor cells in 2002, but no immunoreactivities for 3 β HSD were detected (Fig. 3B).

In cells from both years, a low percentage of Ki67, and the criteria of Weiss for adrenocortical malignancy were consistent with the features of adrenocortical adenoma (2).

Discussion

Adrenocortical tumors comprise less than 0.5% of tumors in children. More than 95% of adrenocortical tumors in children are associated with active secretion of adrenocortical hormones (3). Among adrenocortical tumor cases associated with BWS, Halmi *et al.* (4) reported a case of adrenal tumor in a 4 yr-old girl associated with conversion of virilization to feminization at the time of relapse. In addition, Beauloye *et al.* (5) reported a girl with bilateral adrenocortical adenoma who had incomplete features of BWS. In

our case no virilization was detected at the second episode. This was considered to be due to the relatively low serum level of testosterone in the second episode. The reason for these different endocrinological features in 2002 was considered to be the absence of 3 β HSD expression in the tumor cells.

Patients with BWS have an increased concurrent risk of developing certain specific childhood tumors. The risk of tumor occurrence is 7.5%. Hyperplastic growth of organs, delayed maturation, and cellular anaplasia or maturation predisposed tissues all contribute to malignant transformation in patients with BWS (6). At the second operation, we resected the adrenal tumor separately from the normal tissue and existing adrenal tissue. We must carefully follow up on the patient to prevent recurrence of the adrenal tumor.

References

1. Sbragia-Neto L, Melo-Filho AA, Guerra-Junior G, Valente de Lemos Marini SH, Baptista MT, Sabino de Matos PS, *et al.* Beckwith-Wiedemann Syndrome and Virilizing Cortical Adrenal Tumor in a Child. *J Pediatr Surg* 2000; 35: 1269–71.
2. Nakazumi H, Sasano H, Iino K, Ohashi Y, Orikasa S. Expression of Cell Cycle Inhibitor p27 and Ki-67 in Human Adrenocortical Neoplasms. *Mod Pathol* 1998; 11 (12): 1165–70.
3. Wolthers OD, Cameron FJ, Scheimberg I, Honour JW, Hindmarsh PC, Savage MO, *et al.* Androgen secreting adrenocortical tumours. *Arch Dis Child* 1999; 80: 46–50.
4. Halmi KA, Lascari AD. Conversion of virilization to feminization in a young girl with adrenal cortical carcinoma. *Cancer* 1971; 931–5.
5. Beauloye V, Zain F, Malvaux P, Rahier J, Gosseye S, Honour JW, *et al.* Bilateral asynchronous adrenal adenoma in a girl with an incomplete form of Beckwith-Wiedemann syndrome. *Eur J Pediatr* 2001; 160: 142–3.
6. Engstrom W, Lindham S, Schofield P. Wiedemann-Beckwith syndrome. *Eur J Pediatr* 1988; 147: 450–7.