

Case Report

Periodontal Manifestation in a Patient with Kindler Syndrome

Aysegul Sari ¹ and Salih Celik ²

¹Faculty of Dentistry, Department of Periodontology, Hatay Mustafa Kemal University, Hatay, Turkey

²Department of Oral and Maxillofacial Surgery, TDC Dental Clinic, Antalya, Turkey

Correspondence should be addressed to Aysegul Sari; aysegulsari@mku.edu.tr

Received 24 November 2020; Revised 4 February 2021; Accepted 23 February 2021; Published 9 March 2021

Academic Editor: Sukumaran Anil

Copyright © 2021 Aysegul Sari and Salih Celik. This is an open access article distributed under the Creative Commons Attribution License, which permits unrestricted use, distribution, and reproduction in any medium, provided the original work is properly cited.

Kindler syndrome is a rare subtype of inherited epidermolysis bullosa. A 42-year-old female patient was admitted to our clinic with a complaint of tooth mobility. Multiple hypo- and hyperpigmented macules dissipated all over her body, prominent poikilodermatous changes, xerosis of the skin, and atrophy were seen in the clinical extraoral examination. Intraoral examination showed atrophy of the buccal mucosa, limited oral opening, epidermal tissue easily separated from the connective tissue, painful ulcers of the hard palate, severe periodontitis, and keratosis of the lips. All of the teeth showed mobility. After dermatologist consultation, the diagnosis of the patient was clinically identified as “Kindler syndrome.” All of her teeth were extracted due to her progressive periodontal disease and late admission to our clinic. Periodontal treatment might be effective in treating and controlling oral symptoms related to the syndrome and in improving the patient’s quality of life.

1. Introduction

Kindler syndrome (KS) is defined as a rare autosomal recessive genodermatosis disease. Progressive poikiloderma, the presence of trauma-induced blisters, diffuse cutaneous atrophy, abnormal pigmentation, varying degrees of photosensitivity, and skin fragility are prominent clinical characteristics of the syndrome. Theresa Kindler described the syndrome for the first time in a 14-year-old girl with acral blistering since childhood who subsequently developed photosensitivity and poikiloderma in 1954 [1].

The genetic origin of the syndrome was first defined in 2003, with the identification of loss-of-function mutations in the gene *KIND1* held on chromosome 20p12.3 [2]. More than 25 mutations have been revealed in this gene. Gene *KIDIN 1* encodes kindlin-1 protein, which is one of the components of focal contacts in keratinocytes expressed particularly in the basal keratinocytes located in the epidermis. Abnormal skin fragility with defects in the actinextracellular matrix linkage is caused by loss of this protein [3, 4].

Histopathological examination of the cutaneous biopsy in KS reported a presence of pigmentary incontinence,

degeneration of focal vacuole in the basal layer accompanied by subepidermal cleft, dilatation of blood vessels in the upper dermis, and epidermal atrophy [5, 6].

Other clinical symptoms of KS include nail dystrophy; acral hyperkeratosis [7]; webbing and contractures of toes and fingers [6]; alopecia [8]; actinic changes [9]; mucosal involvement including esophageal [6], oral commissure [10], vaginal [6], and urethral [8] stenosis; ectropion of the eyelids [10]; pigmentation of the lips [8]; and onychodystrophy [6].

The present case reported periodontal management of a 42-year-old female patient KS.

2. Case Report

A 42-year-old female patient presented to Hatay Mustafa Kemal University, Faculty of Dentistry, Periodontology Department, with complaints of tooth mobility in February 2016. Multiple hypo- and hyperpigmented macules dissipated all over her body, prominent poikilodermatous changes, xerosis of the skin, alopecia, and atrophy were seen in the clinical extraoral examination. There was a distinct

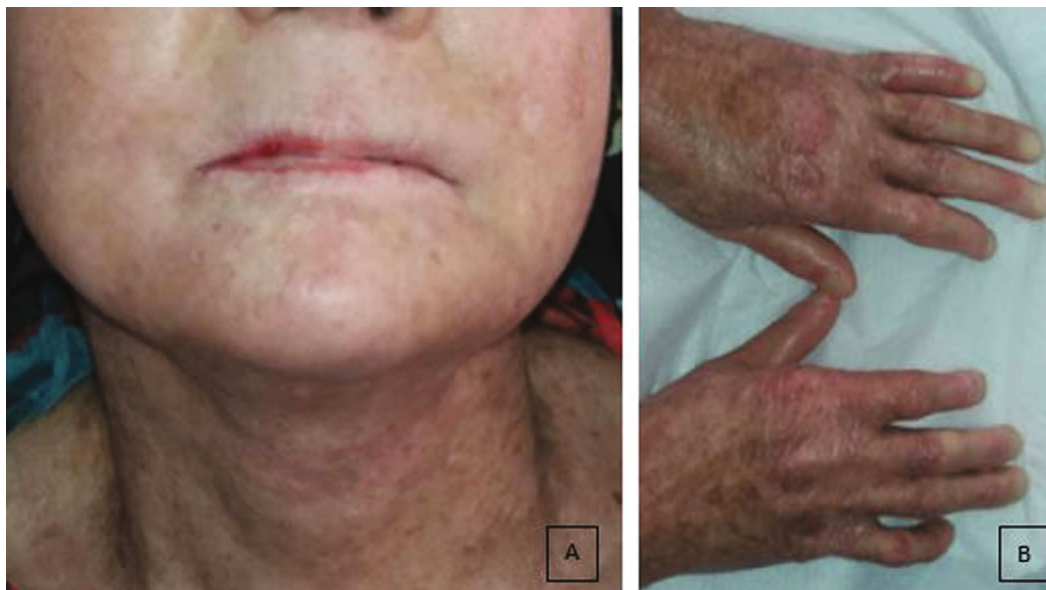

FIGURE 1: (a) The image showing multiple hypo- and hyperpigmented macules, prominent poikilodermatous changes, xerosis, alopecia, and atrophy of the skin. (b) The image showing cigarette paper-like wrinkling on the dorsum of the feet and hands. Atrophy and adhesions were detected in the fingers.

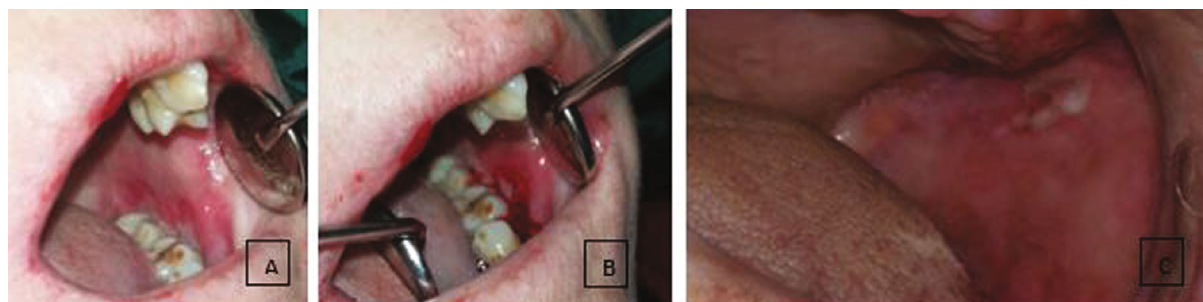


FIGURE 2: (a) The image showing atrophy of the lip, painful ulcers of the buccal mucosa, and keratosis of the lips. (b) It was clinically detected that the oral epidermal tissue easily separated from the connective tissue. (c) Leukoplakia-like lesions were observed in the buccal mucosa.

cigarette paper-like wrinkling on the dorsum of the feet and hands. Atrophy and adhesions were present in the fingers (Figure 1). Her mental and motor statuses were normal.

Intraoral examination showed atrophy of the buccal mucosa, limited oral opening, epidermal tissue easily separated from the connective tissue, painful ulcers of the hard palate, severe periodontitis, and keratosis of the lips. Also, leukoplakia-like lesions were observed in the buccal mucosa (Figure 2). Clinical attachment loss was severe in the periodontal tissue. There were few teeth in the mouth. All of the teeth showed mobility. The gingiva was thin and fragile. Bleeding, swelling, atrophy, and floppy were observed in the gingival tissue (Figure 3).

The patient stated that she had a syndrome in her anamnesis; however, she would not give to us sufficient information about her disorder. Hospital records of the patient could not be reached. The patient was referred to the dermatology department for a definitive diagnosis. The patient's disorder was diagnosed as "Kindler syndrome" by the dermatologist. All of her teeth were extracted due to her progressive

periodontal disease and late admission to our clinic. Furthermore, floppy gingival tissue was removed with gingivectomy for tissue modeling (Figure 4). She was prescribed 0.2% chlorhexidine gluconate for mouth rinsing (2x1, during 14 days), in addition to tetracaine chlorhydrate (0.5 mg) and hexamidine isethionate (1 mg) solution for relieving the oral symptoms.

Conservative treatment was preferred since the results of surgical and dental implant treatments to the patient were not predictable. The patient was referred to the prosthodontics department for the prosthetic process and maintained under clinical follow-up.

3. Discussion

Kindler syndrome is a rare heritable skin disorder with a complex phenotype and poorly understood pathogenesis [11, 12]. The current case reported the oral findings of a 42-year-old female patient with KS who applied to our clinic when her periodontal prognosis had advanced.

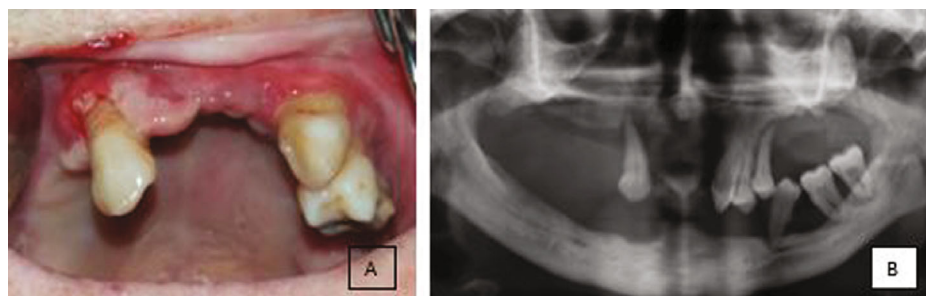


FIGURE 3: (a) The image showing that the clinical attachment loss was severe in the periodontal tissue. Bleeding, swelling, atrophy, and floppy were observed in the gingival tissue. (b) The panoramic radiography image of the patient.

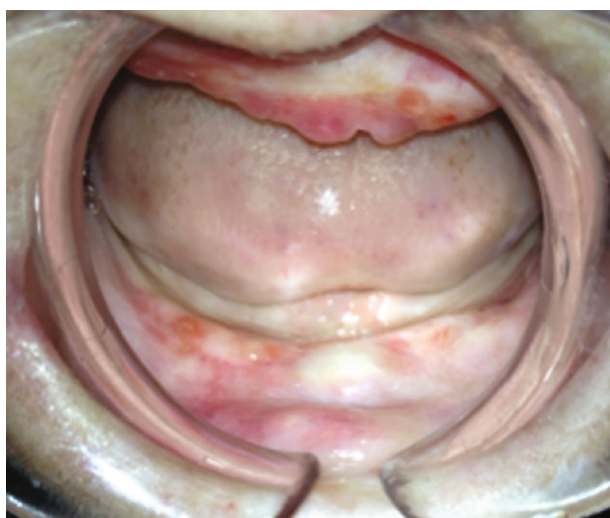

FIGURE 4: The image showing six-week postoperative healing after medicine treatment and gingivectomy.

KS has various clinical symptoms such as acral skin blisters, progressive poikiloderma [1], alopecia, nail dystrophy, acral hyperkeratosis [7], contractures and webbing of toes and fingers [6], photosensitivity [1], and actinic changes [9]. In addition, oral symptoms are very common in this disorder. It was reported that oral manifestations often include severe periodontitis which begins with permanent teeth eruption and progresses rapidly, poor dentition with premature loss of teeth, erosive areas in the labial and buccal mucosa and gingiva, spontaneous bleeding, desquamative gingivitis, angular cheilitis, leukokeratosis of the lips, caries, halitosis, and xerostomia [13]. Clinical and oral manifestations of the present case were similar to those reported in previous studies.

Oral ulcerations and rapidly progressing periodontitis are conditions that should be considered in terms of periodontal health in patients with KS. Kindlin-1 mutations can cause these symptoms [14]. Kindler syndrome is a genetic disorder that occurs as a result of mutations in the fermitin family homolog 1 gene that encodes the kindlin-1 protein which plays a role in cell adhesion, spreading, and migration [15]. It has been reported that kindlin-1 has a basic role in actin-dependent keratinocyte cell adhesion, which is necessary for epidermal and periodontal health. Lack of this protein

in keratinocytes results in reduction of cell spreading, proliferation, and migration rate [16]. Larjava et al. indicated that rapid progression of periodontal disease can be caused by deficiency of integrin activation in the junctional epithelium which can be caused by kindlin-1 mutations [17].

There are few studies evaluating periodontal condition in patients with KS. Wiebe et al. [18] reported that in a case report, by periodontal therapy and long-term follow-up, many teeth were maintained for >10 years despite the rapid prognosis of periodontal disease in patients with KS. Siegel et al. suggested that periodontitis progression was rapid in patients with KD compared to healthy controls [19]. Also, Wiab et al. indicated that kindler subjects exhibited largely similar patterns of periodontal destruction on both sides of the mouth [20]. In accordance with previous data, periodontal disease prognosis was very advanced in the present case. The patient's admission for treatment was in the late period, which limited the periodontal treatment. Since all the teeth had serious mobility and almost all periodontal attachments were lost, all of the teeth were extracted. It can be considered that periodontal disease process could have been accelerated because the patient had never received periodontal treatment before.

4. Conclusion

Management of patients with Kindler syndrome requires a multidisciplinary approach. Periodontal treatment might be effective in treating and controlling oral symptoms related to the syndrome and in improving the patient's quality of life.

Conflicts of Interest

The authors declared that they have no conflict of interest.

Authors' Contributions

The authors contributed to the conception and design of the case report. Treatment and follow-up of the case were performed by Aysegul Sari and Salih Celik. The draft of the manuscript was written by Aysegul SARI. All the authors commented on the previous versions of the manuscript. All the authors read and approved the final manuscript.

Acknowledgments

The author would like to thank Ebru Celik, Assist. Prof., from Hatay Mustafa Kemal University, Medical Faculty, Dermatology Department, for medical diagnosis.

References

- [1] E. de la Rosa-Garcia and A. Mosqueda-Taylor, "Leiomyomatous hamartoma of the anterior tongue: report of a case and review of the literature," *International Journal of Paediatric Dentistry*, vol. 9, no. 2, pp. 129–132, 1999.
- [2] M. Nava-Villalba, F. Ocampo-Acosta, A. Seamanduras-Pacheco, and B. C. Aldape-Barrios, "Leiomyomatous hamartoma: report of two cases and review of the literature," *Oral Surgery, Oral Medicine, Oral Pathology, Oral Radiology, and Endodontics*, vol. 105, no. 4, pp. e39–e45, 2008.
- [3] H. S. McGuff, A. C. Jones, J. Heim-Hall, and T. A. Keller, "Case of the month. Leiomyomatous hamartoma," *Texas Dental Journal*, vol. 126, pp. 544–545, 2009.
- [4] K. H. Ng, C. H. Siar, and H. Abdul Latif, "Leiomyoma of the incisive papilla region: a case report," *Annals of Dentistry*, vol. 51, no. 1, pp. 29–31, 1992.
- [5] L. Mendes, L. Nogueira, V. Vilasboas, C. Talhari, S. Talhari, and M. Santos, "Kindler syndrome: report of two cases," *Anais Brasileiros de Dermatologia*, vol. 87, no. 5, pp. 779–781, 2012.
- [6] H. Shimizu, M. Sato, M. Ban et al., "Immunohistochemical, ultrastructural, and molecular features of Kindler syndrome distinguish it from dystrophic epidermolysis bullosa," *Archives of Dermatology*, vol. 133, no. 9, pp. 1111–1117, 1997.
- [7] S. Hacham-Zadeh, A. A. Garfunkel, J. M. Opitz, and J. F. Reynolds, "Kindler syndrome in two related Kurdish families," *American Journal of Medical Genetics*, vol. 20, no. 1, pp. 43–48, 1985.
- [8] A. Y. Kapasi, U. Khopkar, S. Raj, and S. L. Wadhwa, "Weary-Kindler syndrome with multiple seborrheic keratoses," *International Journal of Dermatology*, vol. 32, no. 6, pp. 444–445, 1993.
- [9] R. M. Haber and W. M. Hanna, "Kindler syndrome. Clinical and ultrastructural findings," *Archives of Dermatology*, vol. 132, no. 12, pp. 1487–1490, 1996.
- [10] D. N. Ricketts, C. L. Morgan, J. M. McGregor, and P. R. Morgan, "Kindler syndrome: a rare cause of desquamative lesions of the gingiva," *Oral Surgery, Oral Medicine, Oral Pathology, Oral Radiology, and Endodontics*, vol. 84, no. 5, pp. 488–491, 1997.
- [11] M. Lotem, M. Raben, R. Zeltser et al., "Kindler syndrome complicated by squamous cell carcinoma of the hard palate: successful treatment with high-dose radiation therapy and granulocyte-macrophage colony-stimulating factor," *The British Journal of Dermatology*, vol. 144, no. 6, pp. 1284–1286, 2001.
- [12] F. Jobard, B. Bouadjar, F. Caux et al., "Identification of mutations in a new gene encoding a FERM family protein with a pleckstrin homology domain in Kindler syndrome," *Human Molecular Genetics*, vol. 12, no. 8, pp. 925–935, 2003.
- [13] N. M. Barbosa, F. Visioli, M. D. Martins, M. A. Martins, and M. C. Munerato, "Oral manifestations in Kindler syndrome: case report and discussion of literature findings," *Special Care in Dentistry*, vol. 36, no. 4, pp. 223–230, 2016.
- [14] J. M. Albandar, C. Susin, and F. J. Hughes, "Manifestations of systemic diseases and conditions that affect the periodontal attachment apparatus: case definitions and diagnostic considerations," *Journal of Clinical Periodontology*, vol. 89, Supplement 20, pp. S183–S203, 2018.
- [15] E. Rognoni, R. Ruppert, and R. Fassler, "The kindlin family: functions, signaling properties and implications for human disease," *Journal of Cell Science*, vol. 129, no. 1, pp. 17–27, 2016.
- [16] G. Petricca, M. Leppilampi, G. Jiang et al., "Localization and potential function of kindlin-1 in periodontal tissues," *European Journal of Oral Sciences*, vol. 117, no. 5, pp. 518–527, 2009.
- [17] H. Larjava, L. Koivisto, J. Heino, and L. Hakkinen, "Integrins in periodontal disease," *Experimental Cell Research*, vol. 325, no. 2, pp. 104–110, 2014.
- [18] C. B. Wiebe, G. Petricca, L. Hakkinen, G. Jiang, C. Wu, and H. S. Larjava, "Kindler syndrome and periodontal disease: review of the literature and a 12-year follow-up case," *Journal of Periodontology*, vol. 79, no. 5, pp. 961–966, 2008.
- [19] D. H. Siegel, G. H. Ashton, H. G. Penagos et al., "Loss of Kindlin-1, a Human Homolog of the *Caenorhabditis elegans* Actin-Extracellular-Matrix Linker Protein UNC-112, Causes Kindler Syndrome," *American Journal of Human Genetics*, vol. 73, no. 1, pp. 174–187, 2003.
- [20] C. B. Wiebe, H. Penagos, N. Luong et al., "Clinical and microbiologic study of periodontitis associated with Kindler syndrome," *Journal of Periodontology*, vol. 74, no. 1, pp. 25–31, 2003.