

Consecutive failing proximal landing zones

Côme Bosse, MD, Thomas Le Houérou, MD, Raphael Soler, MD, Dominique Fabre, MD, PhD, and Stéphan Haulon, MD, PhD, *Paris Saclay, France*

ABSTRACT

We report the case of a 77-year-old man who presented with successive aortic aneurysms during a 12-year period. He was first treated in 2006 for an abdominal aortic aneurysm with a bifurcated endograft, then in 2016 for a tender type IV thoracoabdominal aortic aneurysm with a proximal aortic cuff with in situ laser fenestrations. He presented in 2018 with a 9-cm distal thoracic aorta aneurysm managed by an off-the-shelf t-Branch endograft (Cook Medical, Bloomington, Ind). The perioperative course was uneventful, and 6-month follow-up computed tomography scan has shown freedom from endoleaks and branch patency. This case illustrates that apparently “healthy” aortic necks can degenerate after endovascular aneurysm repair. (*J Vasc Surg Cases and Innovative Techniques* 2019;5:544-8.)

Keywords: Aneurysm; Abdominal aorta; Branched stent graft; Endograft; Thoracic endovascular aortic repair; Reintervention

Proximal aortic neck dilation after endovascular aneurysm repair (EVAR) and open aortic surgical repair has been widely reported.¹⁻⁶ Subsequent interventions can be challenging, especially in emergency presentations, such as tender, ruptured, or very large aneurysms.⁷⁻⁹ Open conversion can be considered in fit patients, but off-label use of available endovascular grafts may be the only realistic treatment option.

CASE REPORT

We report the case of a 77-year-old man with a history of recurrent degeneration of apparently adequate aortic sealing zones after initially successful infrarenal EVAR. Consent to publish was obtained from the patient. His past medical history included granulomatosis with polyangiitis, hypertension, atrial fibrillation, and a nonspecific polyarthritis. The patient was never genetically tested.

The patient was first treated for a 58-mm-diameter abdominal aortic aneurysm (AAA) in 2006 (at the age of 65 years) with a standard bifurcated 34-mm Talent endograft (Medtronic Vascular, Santa Rosa, Calif). At that time, the infrarenal aortic neck was 20 mm long and 28 mm in diameter. Annual computed tomography (CT) follow-up from 2006 to 2014 showed an excluded aneurysm with stable aortic and neck diameters. In 2016, a proximal type IA endoleak secondary to

aneurysmal degeneration of the visceral aorta (Fig 1) was found. The maximum diameter of the aneurysm had increased to 89 mm, and it was clinically tender. This was treated urgently using a proximal aortic cuff (Endurant II 36-49; Medtronic), positioned with one proximal sealing stent above the celiac trunk to provide aortic sealing and AAA exclusion. In situ laser fenestrations of the proximal cuff were created to allow the placement of covered, balloon-expandable bridging stents to both renal arteries, the superior mesenteric artery, and the celiac trunk (Advanta V12; Maquet Getinge Group, Rastatt, Germany). It provided a 25-mm-long seal in a 31-mm-diameter visceral aorta. This solution was preferred to a custom-made fenestrated endograft because of the aneurysm diameter, aortic tenderness, and risk of rupture inherent in the manufacturing delay for the custom-made device at that time. The postoperative 1-month and 1-year CT scans showed no endoleak and patent visceral vessels (Fig 2).

He did not show up to his follow-up visits. Two years later, in 2018, he presented with a symptomatic 90-mm aneurysm of the distal thoracic aorta (DTA), above the previous repair, and an occlusion of the left renal artery bridging stent (Fig 3).

This new thoracic aortic aneurysm was excluded using an off-the-shelf t-Branch endograft (Cook Medical, Bloomington, Ind). We employed our standard treatment strategies including cerebrospinal fluid drainage. In addition, we elected to precatheterize the three patent target vessels through a femoral approach to position “buddy wires” and also to preflare the aortic portions of the existing bridging stents using 12- × 20-mm balloons. The t-Branch device was deployed from the contralateral groin, and the right renal artery, the superior mesenteric artery, and the celiac stents and vessels were catheterized through right axillary artery cutdown. The branches were connected to their respective target vessels with Covera Plus (Bard, Murray Hill, NJ) and BeGraft+ bridging stents (Bentley Innomed GmbH, Hechingen, Germany). The left renal artery branch was extended and then occluded by a combination of a BeGraft stent and an Amplatzer Vascular Plug II (St. Jude Medical, St. Paul, Minn). A proximal thoracic extension (Zenith Alpha Thoracic 38-117; Cook Medical) and a standard aortobi-iliac

From the Aortic Center, Marie Lannelongue Hospital, Le Plessis-Robinson, Paris-Sud University.

Author conflict of interest: S.H. is a consultant for Cook Medical, GE Healthcare, and Bentley.

Correspondence: Stéphan Haulon, MD, PhD, Aortic Center, Hôpital Marie Lannelongue, INSERM UMR_S 999-Université Paris Sud, 133 avenue de la Résistance, 92350 Le Plessis-Robinson, France (e-mail: s.haulon@hml.fr).

The editors and reviewers of this article have no relevant financial relationships to disclose per the Journal policy that requires reviewers to decline review of any manuscript for which they may have a conflict of interest.

2468-4287

© 2019 The Author(s). Published by Elsevier Inc. on behalf of Society for Vascular Surgery. This is an open access article under the CC BY-NC-ND license (<http://creativecommons.org/licenses/by-nc-nd/4.0/>).

<https://doi.org/10.1016/j.jvscit.2019.06.009>

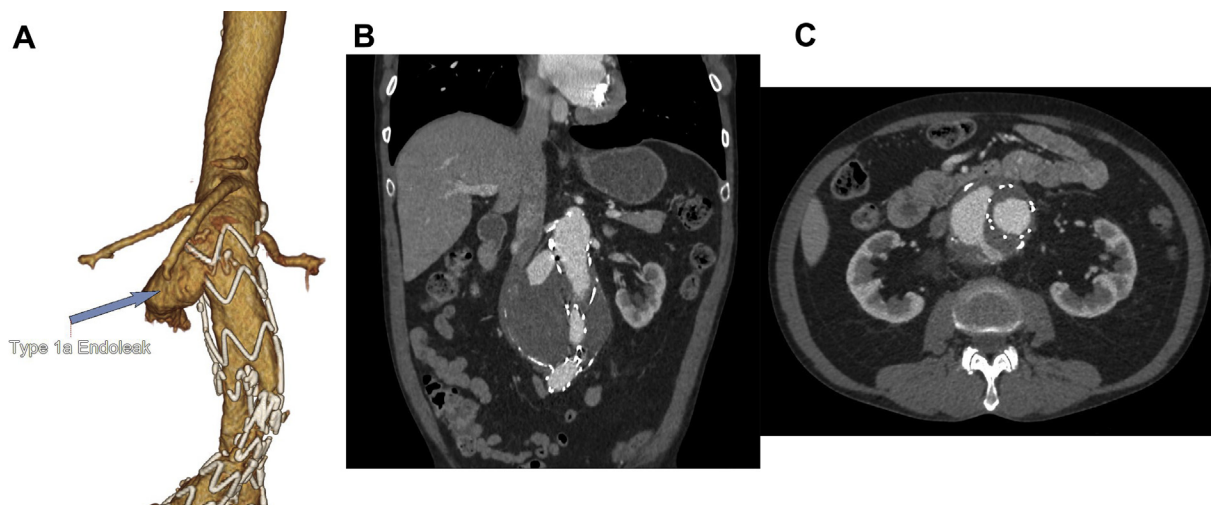


Fig 1. Computed tomography (CT) scan from 2016 showing a type IA endoleak with three-dimensional volume rendered reconstruction (A) and coronal (B) and axial (C) views.

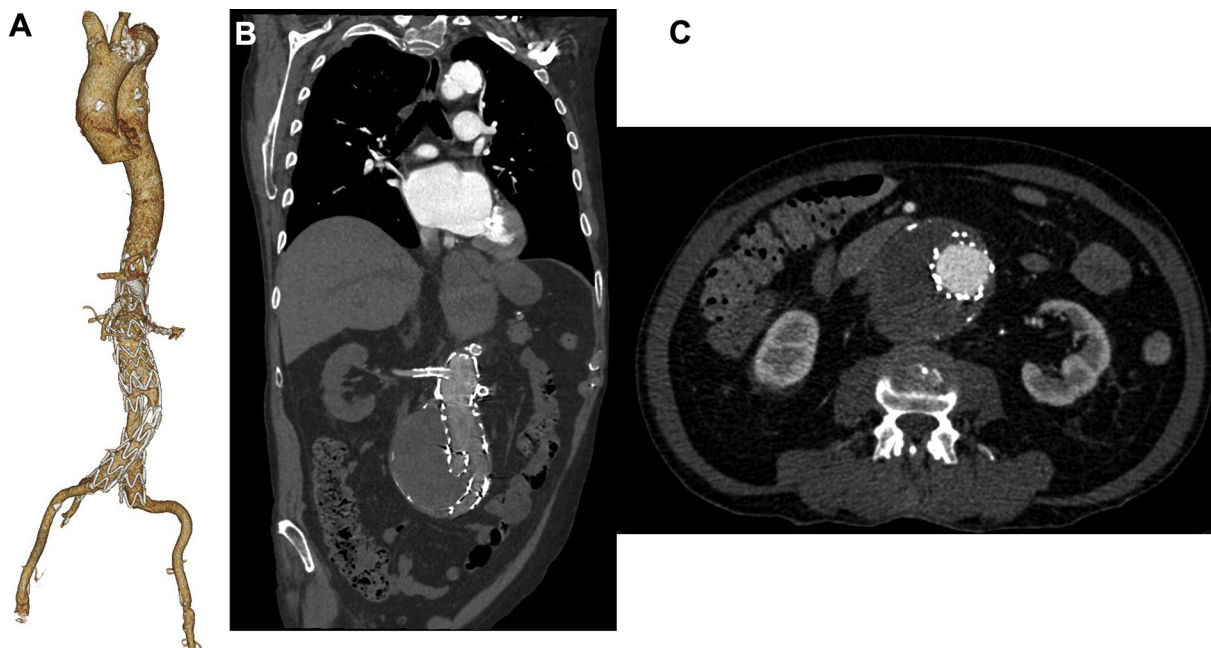


Fig 2. Computed tomography (CT) scan at 1-year follow-up after proximal extension and in situ laser fenestration with total exclusion of the aneurysm with three-dimensional volume rendered reconstruction (A) and coronal (B) and axial (C) views.

bifurcated Zenith endograft (Cook Medical) were deployed proximal and distal to the t-Branch, respectively. The skin to skin procedure duration was 3 hours 54 minutes, the cumulative air kerma was 399 mGy, the fluoroscopy time was 72 minutes, and 75 mL of contrast medium was injected. During the postoperative course, the patient suffered hematuria (probably from traumatic urinary catheterization and aggressive anticoagulation) requiring cystoscopy and bladder irrigation, which delayed discharge to postoperative day 17. Postoperative CT scans at 1 month and 6 months confirmed sac exclusion and patency of the three remaining branches (Fig 4). The proximal sealing

zone is currently 35 mm long. The aortic diameter at that level is 33 mm. Before and after the third procedure, no graft or aortic infection was suspected on CT scan, and no fever or C-reactive protein or white blood cell elevation was observed.

DISCUSSION

This case report illustrates the importance of always anticipating the next step in performing EVAR (planning for manageable failure). Aortas that contain aneurysms in one segment are not truly “healthy,” and further aneurysmal degeneration affecting both sealing zones and

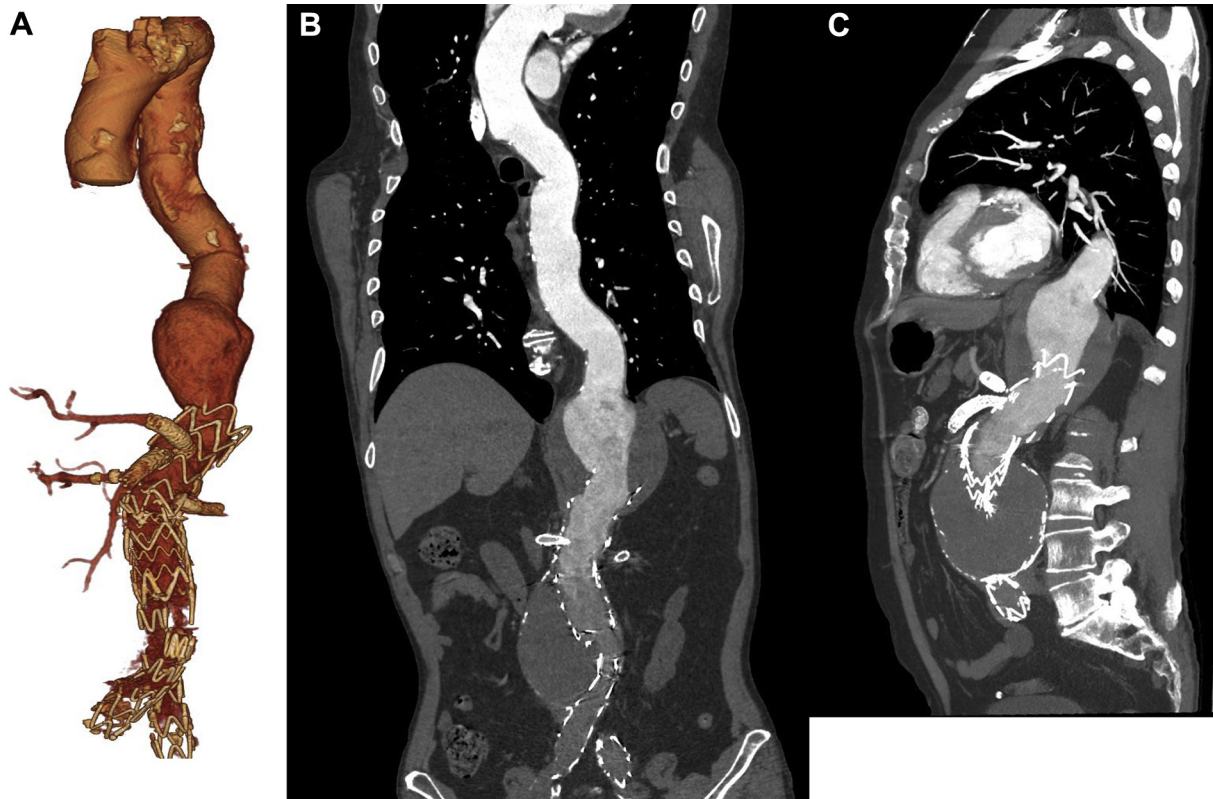


Fig 3. Three-dimensional volume-rendered reconstruction (A) and coronal (B) and sagittal (C) orientations of the preoperative computed tomography (CT) scan in 2018 showing an aneurysmal evolution of the distal thoracic aorta (DTA).

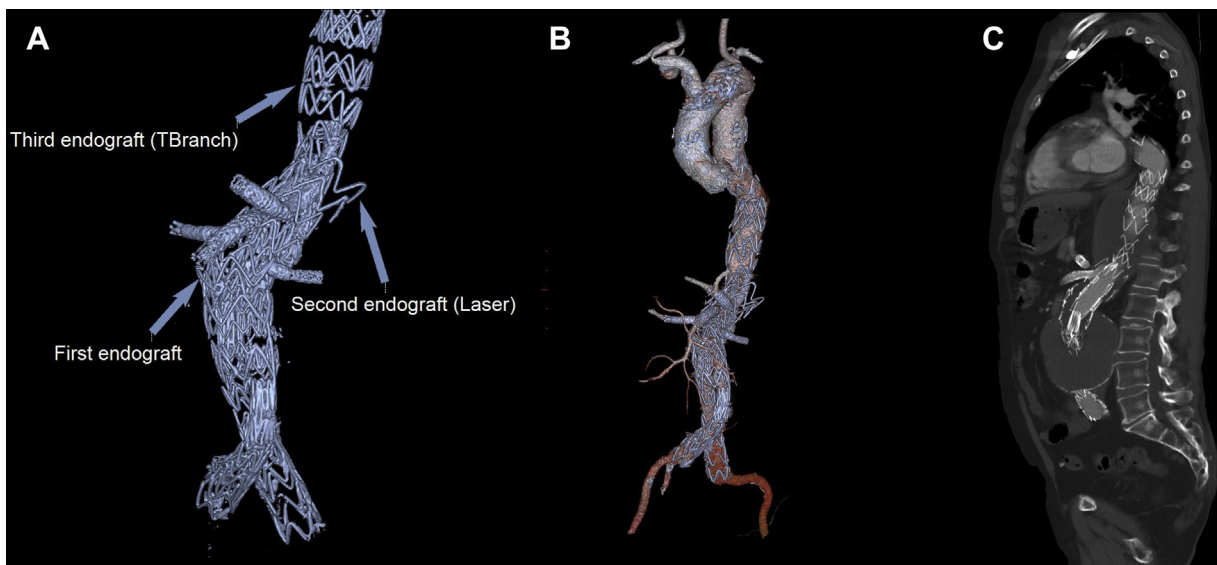


Fig 4. Computed tomography (CT) scan at 6-month follow-up after thoracoabdominal multibranch endograft implantation inside the previous endograft: total exclusion of the aneurysm with three-dimensional volume rendered reconstructions (A and B) and sagittal view (C). This shows a total of three endografts deployed one inside the other.

previously uninvolved segments over time is not rare. It is therefore important to plan sealing zones compatible with future EVAR extensions, most particularly in young

first-time presenters with long predicted remaining life spans. After 8 years of uneventful follow-up, our patient experienced rapid aneurysm growth and was exposed

to rupture, underlining the importance of lifelong imaging follow-up after EVAR. Extended follow-up is difficult to achieve, however.^{10,11} Arterial aneurysms are a rare complication of granulomatosis with polyangiitis.¹² Our patient had regular follow-up of his disease that was controlled with prednisolone treatment. The unexpected development of his thoracic aneurysm could be linked to this underlying pathologic process.

Oberhuber et al¹ reported a mean neck enlargement of 2 mm after a mean follow-up of 34 months following both endovascular and open surgical treatment of AAA. Monahan et al³ documented a mean 5.3-mm dilation at 48-month follow-up after EVAR in their cohort in which neck enlargement was observed in all patients during follow-up. Rodway et al² described a greater rate of neck enlargement after endovascular repair than after open surgical repair. Furthermore, whereas neck enlargement is reported to be most rapid between 24 and 36 months after EVAR, it does not stop after 5 years of follow-up.⁴ Finally, the literature suggests that neck enlargement is independent of sac regression and reinterventions⁵ but may be related to endograft oversizing.⁶

Failing EVAR with proximal type I endoleaks is not infrequent when the neck diameter is ≥ 28 mm, as shown in this case report.¹³ The endoleaks are most likely to be resealed by proximal fenestrated or branched cuffs.⁷ These reinterventions are more challenging than similar operations in previously untreated aortas⁸ but are nonetheless possible and generally successful in experienced hands. An alternative therapeutic option is reversion to open surgical repair with explantation of the endograft, but this is a considerable undertaking and physiologic challenge. It is the first-line option in fit patients but is associated with appreciable procedure-related risks.⁹ In circumstances of urgency (symptomatic or very large aneurysms), treatment options include chimney EVAR,¹⁴ in situ laser fenestrations,¹⁵ physician-modified endografts,¹⁶ and use of off-the-shelf endografts such as the t-Branch endograft.¹⁷

In this case report, the failing EVAR was treated with an in situ laser fenestrated EVAR (FEVAR). The failing FEVAR was subsequently relined using a multi-branched endograft. Had the previous FEVAR been performed with two or more sealing stents above the celiac fenestration, the later DTA aneurysm would have been easily excluded by simply relining the FEVAR with a standard thoracic endovascular aortic repair proximal extension. Precatheterization of the target vessels and flaring of the bridging stents secured access by preventing irretrievable crushing of the original bridging stents and facilitated implantation of the new bridging stents. We have found the routine use of steerable sheaths in such complex procedures a very helpful adjunct.

CONCLUSIONS

Thoracoabdominal multibranch endografts can be inserted through failed FEVAR devices when proximal seal fails. Better planning of the original FEVAR cuff with two or more proximal sealing stents above the highest fenestration would have greatly simplified the management of the DTA.

REFERENCES

1. Oberhuber A, Buecken M, Hoffmann M, Orend KH, Mühling BM. Comparison of aortic neck dilatation after open and endovascular repair of abdominal aortic aneurysm. *J Vasc Surg* 2012;55:929-34.
2. Rodway AD, Powell JT, Brown LC, Greenhalgh RM. Do abdominal aortic aneurysm necks increase in size faster after endovascular than open repair? *Eur J Vasc Endovasc Surg* 2008;35:685-93.
3. Monahan TS, Chuter TA, Reilly LM, Rapp JH, Hiramoto JS. Long-term follow-up of neck expansion after endovascular aortic aneurysm repair. *J Vasc Surg* 2010;52:303-7.
4. Tsilimparis N, Dayama A, Ricotta JJ. Remodeling of aortic aneurysm and aortic neck on follow-up after endovascular repair with suprarenal fixation. *J Vasc Surg* 2015;61:28-34.
5. Kaladji A, Cardon A, Laviolle B, Heautot JF, Pinel G, Lucas A. Evolution of the upper and lower landing site after endovascular aortic aneurysm repair. *J Vasc Surg* 2012;55:24-32.
6. Kret MR, Tran K, Lee JT. Change in aortic neck diameter after endovascular aortic aneurysm repair. *Ann Vasc Surg* 2017;43:115-20.
7. Martin Z, Greenberg RK, Mastracci TM, Eagleton MJ, O'Callaghan A, Bena J. Late rescue of proximal endograft failure using fenestrated and branched devices. *J Vasc Surg* 2014;59:1479-87.
8. Katsargyris A, Yazar O, Oikonomou K, Bekkema F, Tielliu I, Verhoeven EL. Fenestrated stent-grafts for salvage of prior endovascular abdominal aortic aneurysm repair. *Eur J Vasc Endovasc Surg* 2013;46:49-56.
9. Kouvelos G, Koutsoumpelis A, Lazaris A, Matsagkas M. Late open conversion after endovascular abdominal aortic aneurysm repair. *J Vasc Surg* 2015;61:1350-6.
10. Grima MJ, Karthikesalingam A, Holt PJ, Kerr D, Chetter I, Harrison S, et al. Multicentre Post-EVAR Surveillance Evaluation Study (EVAR-SCREEN). *Eur J Vasc Endovasc Surg* 2019;57:521-6.
11. Wu CY, Chen H, Gallagher KA, Eliason JL, Rectenwald JE, Coleman DM. Predictors of compliance with surveillance after endovascular aneurysm repair and comparative survival outcomes. *J Vasc Surg* 2015;62:27-35.
12. Niimi N, Miyashita T, Tanji K, Hirai T, Watanabe K, Ikeda K, et al. Aortic aneurysm as a complication of granulomatosis with polyangiitis successfully treated with prednisolone and cyclophosphamide: a case report and review of the literature. *Case Rep Rheumatol* 2018;2018:9682801.
13. Gargiulo M, Gallitto E, Watzet H, Verzini F, Bianchini Massoni C, Loschi D, et al. Outcomes of endovascular aneurysm repair performed in abdominal aortic aneurysms with large infrarenal necks. *J Vasc Surg* 2017;66:1065-72.
14. Montelione N, Pecoraro F, Puipe G, Chaykovska L, Rancic Z, Pfammatter T, et al. A 12-year experience with chimney and periscope grafts for treatment of type I endoleaks. *J Endovasc Ther* 2015;22:568-74.
15. Le Houérou T, Fabre D, Alonso CG, Brenot P, Bourkaib R, Angel C, et al. In situ antegrade laser fenestrations during

- endovascular aortic repair. *Eur J Vasc Endovasc Surg* 2018;56:356-62.
16. Cochennec F, Kobeiter H, Gohel M, Leopardi M, Raux M, Majewski M, et al. Early results of physician modified fenestrated stent grafts for the treatment of thoraco-abdominal aortic aneurysms. *Eur J Vasc Endovasc Surg* 2015;50:583-92.
 17. Kanafer A, Khashram M, Ruiz CM, Mann D, Laing A. Use of the off-the-shelf t-Branch device to treat an acute type Ia endoleak in a symptomatic juxtarenal abdominal aortic aneurysm. *J Endovasc Ther* 2016;23:212-5.

Submitted Apr 9, 2019; accepted Jun 30, 2019.