



Case Report

Recurrent solitary bone plasmacytoma: A case report

Rajendra Sakhrekar¹, Ketan Khurjekar¹, Shailesh Hadgaonkar¹, Pramod Bhilare¹, Parag Sancheti¹, Ashok Shyam¹

¹Department of Spine Surgery, Sancheti Institute of Orthopedics and Rehabilitation, Pune, Maharashtra, India.

E-mail: *Rajendra Sakhrekar - raj.sakhrekar1@gmail.com; Ketan Khurjekar - kkhurjekar@gmail.com; Shailesh Hadgaonkar - drshadgaonkar@gmail.com; Pramod Bhilare - pramod.bhilare@gmail.com; Parag Sancheti - parag@sanchetihospital.org; Ashok Shyam - drashokshyam@gmail.com



*Corresponding author:

Rajendra Sakhrekar,
Department of Spine
Surgery, Sancheti Institute of
Orthopedics and Rehabilitation,
Pune, Maharashtra, India.

raj.sakhrekar1@gmail.com

Received : 02 May 2021

Accepted : 25 June 2021

Published : 19 July 2021

DOI

10.25259/SNI_442_2021

Quick Response Code:



ABSTRACT

Background: Plasmacytoma is an hematological malignancy that originates in bone. It may involve a single skeletal location. Notably, these lesions can progress to involve multiple segments in 50% of cases, at which point they are classified as having multiple myeloma (MM).

Case Description: One year ago, this patient had undergone a D6 laminectomy and biopsy for plasmacytoma. Now at age 73, she newly presented with the onset of a progressive paraparesis of 4 weeks' duration. On examination, she had 3/5 strength in both lower extremities accompanied by diffuse hyperreflexia, and bilateral Babinski signs. She underwent a D5-D7 decompression, D6 corpectomy with anterior mesh cage reconstruction, and a D3-D9 posterior fusion.

Conclusion: Patients originally treated for plasmacytoma present 50% of the time with the new onset of neurological symptoms and signs due to the subsequent evolution of MM. As these lesions may be refractory to radiation and/or chemotherapy, surgery is often warranted.

Keywords: Instability, Neurodeficit, Recurrence, Solitary bone plasmacytoma, Surgical management

INTRODUCTION

Plasmacytoma is an hematological malignancy that primarily originates in bone. It can occur as a single skeletal location, a factor which differentiates it from multiple myeloma (MM) (i.e., plasmacytoma progresses to involve multiple spinal segments in 50% of cases at which point it is relabeled resulting MM).^[1-3] Here, we present a 73-year-old female who 1 year previously was treated for a D6 plasmacytoma. As she now acutely presented with a paraparesis, urgent circumferential surgical decompression/fusion was warranted.

CASE REPORT

A 73-year-old female had been treated for a D6 spinal plasmacytoma 1 year previously (i.e., utilizing a D6 laminectomy and biopsy). She now newly presented with the acute onset of a paraparesis (3/5 motor deficit in the lower extremities) of 4 weeks' duration.

Diagnostic studies

X-ray and MRI studies both showed a new, pathologic, unstable fracture of D6 involving all three columns; this resulted in significant collapse of the D6 vertebral body with focal kyphosis

This is an open-access article distributed under the terms of the Creative Commons Attribution-Non Commercial-Share Alike 4.0 License, which allows others to remix, tweak, and build upon the work non-commercially, as long as the author is credited and the new creations are licensed under the identical terms.

©2021 Published by Scientific Scholar on behalf of Surgical Neurology International

[Figures 1 and 2]. Further, the MRI and PET scans showed a heterogeneous mass involving the D6 vertebra accompanied by both intraspinal and right paravertebral tumors that now significantly compressed the spinal cord [Figures 3-5].

Surgery

Indications for urgent surgery included intractable pain and a progressive paraparesis of 4 weeks duration. It included a single-stage procedure; a D5-D7 decompression, D6 corpectomy with anterior mesh cage reconstruction, and a D3-D9 posterior fusion [Figure 6].

This stabilized the spinal column, while providing for sufficient resection and decompression of tumor. It was followed by adjuvant radiation therapy.

Pathology

The biopsy confirmed the diagnosis of plasmacytoma, showing sheets and clusters of plasma cells including immature forms with focal nuclear pleomorphism [Figure 7].

Postoperative course

Postoperatively, her pain dramatically decreased; she was mobilized the day after surgery. She continued to improve up to 2 years following the surgery (i.e., VAS improved to 1/10 and ODI score to 4).

DISCUSSION

Incidence and location of SBP

SBP most commonly affects the axial skeleton (25–60%) and has a predilection for the thoracic spine. Further, SBP has a high risk of progression to MM.^[4,6] If there is spinal

involvement, pain and instability of the vertebra could be seen, but fractures are rare.

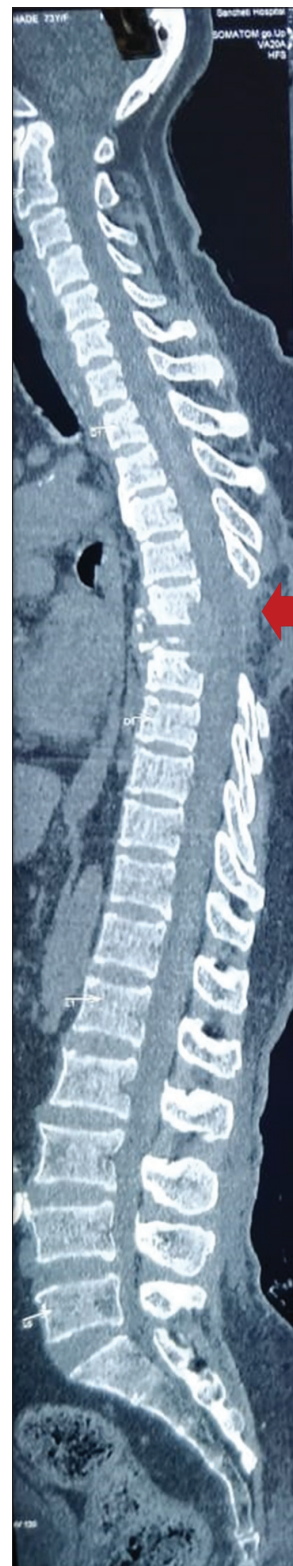

Figure 2: CT scan spine sagittal view: showing D5 to D7 laminectomy defects with D6 collapse.

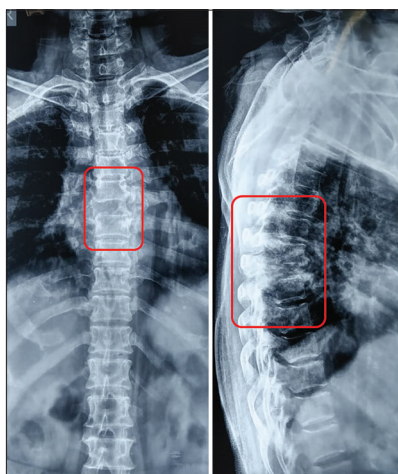


Figure 1: X-ray dorsal spine anteroposterior and lateral view: showing D5 to D7 laminectomy defects with collapsed D6 with focal kyphosis.

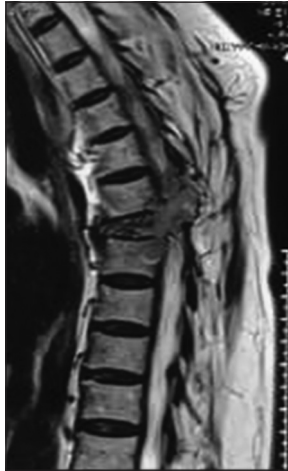

Figure 3: MRI dorsal spine sagittal view: the heterogeneous tumor mass spread around the vertebra with collapse of the D6 vertebra.

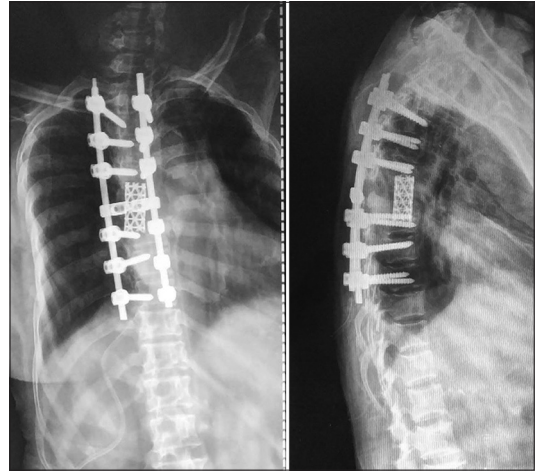


Figure 6: X-ray postsurgery dorsal spine anteroposterior and lateral view: D5-D7 decompression with D6 corpectomy and anterior mesh cage reconstruction with D3-D9 posterior stabilization.

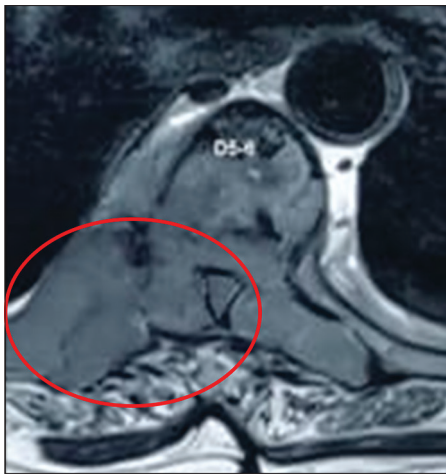


Figure 4: MRI dorsal spine axial view: the widespread tumor mass causing significant engulfing of spinal cord.

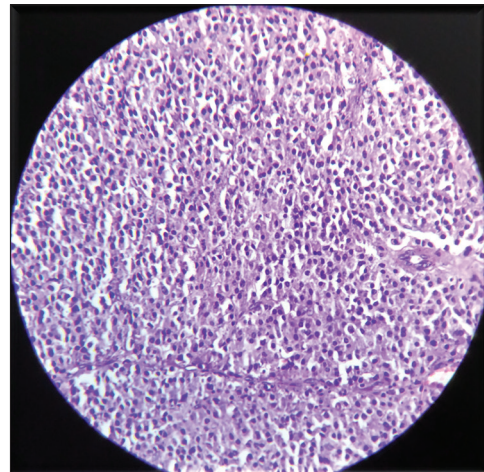


Figure 7: Biopsy section: sheets and clusters of plasma cells consisting of immature forms having focal nuclear pleomorphism.

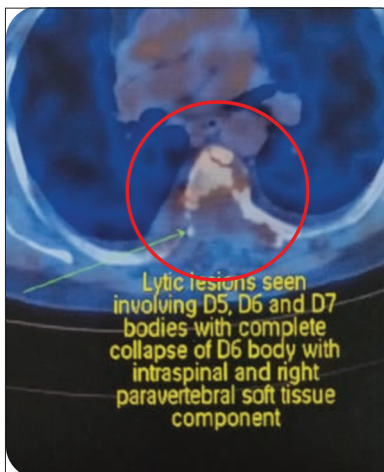


Figure 5: PET scan axial view: lytic lesion seen involving D5, D6, and D7 vertebral body with intraspinal and right paravertebral soft-tissue component.

CT and MR studies of SBP

CT or MRI can detect the lesions and describe the tumor extent at its earlier stage. MRI has an important role in the description of the residual tumor, local relapse and tumor progression to MM after treatment.

Biopsy and treatment modalities

Biopsy and histopathology play an important role in the diagnosis and management of this disease. Notably, radiotherapy is considered the treatment of choice for SPB.^[5,7] Although surgery is not the first choice to treat SPB, it remains a viable option for patients with intractable pain and/or new neurological deficits attributed to cord compression, progressive vertebral involvement, and instability,^[8] When Tsutsumi *et al.* described seven previously reported cases of

solitary spinal extradural plasmacytoma, four of five patients undergoing decompression and tumor resection showed neurological improvement. They concluded that surgical management was effective for symptom relief for SBP.^[10] Given to the increasing probability of long-term survival in these patients, it is recommended that reconstruction of the involved spinal segments be performed.^[9-11]

CONCLUSION

Surgical management of plasmacytomas is advised in cases involving significant pathological fractures, cord compression, and/or instability contributing to severe neurological deficits.

Declaration of patient consent

The authors certify that they have obtained all appropriate patient consent.

Financial support and sponsorship

Nil.

Conflicts of interest

There are no conflicts of interest.

REFERENCES

1. Baba H, Maezawa Y, Furusawa N, Wada M, Kokubo Y, Imura S, *et al.* Solitary plasmacytomas of the spine associated with neurological complications. *Spinal Cord* 1998;36:4170-5.
2. Dimopoulos M, Kiamouris C, Moulopoulos LA. Solitary bone plasmacytoma and extramedullary plasmacytoma. *Curr*

3. Treatment Options *Oncol* 2002;3:255-9.
3. Dimopoulos M, Terpos E, Comenzo RL, Tosi P, Beksac M, Sezer O, *et al.* International myeloma working group consensus statement and guidelines regarding the current role of imaging techniques in the diagnosis and monitoring of multiple Myeloma. *Leukemia* 2009;23:1545-56.
4. Dores GM, Landgren O, McGlynn KA, Curtis RE, Linet MS, Devesa SS. Plasmacytoma of bone, extramedullary plasmacytoma, and multiple myeloma: Incidence and survival in the United States, 1992-2004. *Br J Haematol* 2009;144:86-94.
5. He MX, Zhu MH, Zhang YM, Fu QG, Wu LL. Solitary plasmacytoma of spine: A clinical, radiologic and pathologic study of 13 cases. 2009;38:307-11.
6. Holland J, Trenkner DA, Wasserman TH, Fineberg B. Plasmacytoma: Treatment results and conversion to myeloma. *Cancer* 1992;69:1513-7.
7. Jyothirmayi R, Gangadharan VP, Nair MK. Radiotherapy in the treatment of solitary plasmacytoma. *Br J Radiol* 1997;70:511-6.
8. Ozsahin M, Tsang RW, Poortmans P, Belkacemi Y, Bolla M, Dinçbas FO, *et al.* Outcomes and patterns of failure in solitary plasmacytoma: A multicentre rare cancer network study of 258 patients. *Int J Radiat Oncol Biol Phys* 2006;64:210-7.
9. Takahashi T, Kosu K, Tominaga T, Takahashi A, Yoshimoto T. Solitary plasmacytoma in the thoracic spine. Two case reports. *Neurosurg Rev* 1998;21:121-5.
10. Tsutsumi S, Yasumoto Y, Ito M. Solitary spinal extradural plasmacytoma: A case report and literature review. *Clin Neuroradiol* 2013;23:5-9.
11. Wiltshaw E. The natural history of extramedullary plasmacytoma and its relation to solitary myeloma of bone and myelomatosis. *Medicine* 1976;55:217-38.

How to cite this article: Sakhrekar R, Khurjekar K, Hadgaonkar S, Bhilare P, Sancheti P, Shyam A. Recurrent solitary bone plasmacytoma: A case report. *Surg Neurol Int* 2021;12:356.