

## High-Flow Bypass with Radial Artery Graft for Cavernous Carotid Aneurysm

### Abstract

Cavernous carotid aneurysms can be managed by different surgical as well as endovascular methods. The aim of treatment is to exclude the aneurysm from circulation and maintain normal cerebral blood flow. We are reporting a case of incidentally detected CCA managed by high flow bypass with radial artery graft. We discuss the surgical technique and nuances of high flow bypass surgery.

**Keywords:** Cavernous carotid aneurysm, high-flow bypass, radial artery graft

### Introduction

Cavernous carotid aneurysms (CCAs) account for 2%–9% of all intracranial aneurysms.<sup>[1]</sup> Most often, they remain asymptomatic and are detected incidentally. They may attain large size and present with mass effect causing cranial neuropathies. A transitional variant with intradural component may rupture, causing SAH and rarely intracavernous rupture leads to direct carotid-cavernous fistula.<sup>[2-4]</sup> There are lots of controversies regarding management of CCAs. Management options include surgical and endovascular methods with aim of exclusion of aneurysm from circulation and maintenance of normal cerebral perfusion. This can be achieved by parent artery occlusion by surgical or endovascular method with or without bypass procedures, coiling (balloon or stent assisted), flow diverters and liquid embolic agents.<sup>[5]</sup>

We present a case of CCA managed by high-flow bypass with radial artery (RA) interposition graft followed by carotid ligation.

### Case Report

A 66-year-old female patient was incidentally diagnosed with right CCA and left side internal carotid artery (ICA) paraclinoid aneurysm. She underwent surgery for the paraclinoid aneurysm was 1 year back. Option of conservative treatment with follow-up was explained

to the patient; however, she was very apprehensive and decided to go for surgery. Four-vessel digital subtraction angiography (DSA) was performed to study the aneurysm anatomy in further details as well as to see the cross flow. Aneurysm sac size was 8.9 mm × 8.4 mm with 2.0 mm neck diameter and there was no evidence of cross flow [Figure 1].

### Surgical procedure

#### Position and incision

The patient was positioned supine with head turned to 30° to the left side. Superficial temporal artery (STA) was palpated and a frontotemporal curvilinear incision reaching till midline was marked accordingly. Neck incision started above the level of angle of mandible along the anterior border of sternocleidomastoid muscle and curved anteriorly along the superior border of thyroid cartilage. A curvilinear incision along the medial border of brachioradialis muscle of right forearm was marked for RA graft. Proximal end was approximately 2 centimeters below elbow crease and distal end was just proximal to wrist crease [Figure 2].

#### Neck exposure

Platysma was incised to expose the sternocleidomastoid and dissection toward the anterior border of sternocleidomastoid was done to identify parotid gland. Greater auricular nerve was preserved and external

**Ambuj Kumar,  
Raghavendra  
Kumar Sharma<sup>1</sup>,  
Riki Tanaka<sup>2</sup>,  
Yashuhiro Yamada<sup>2</sup>,  
Katsumi Takizawa<sup>3</sup>,  
Yoko Kato<sup>2</sup>**

Department of Neurosurgery,  
NSCB Medical College,  
Jabalpur, Madhya Pradesh,  
<sup>1</sup>Department of Neurosurgery,  
AIIMS, Raipur, Chhattisgarh,  
India, <sup>2</sup>Department of  
Neurosurgery, Bantane Hospital,  
Fujita Health University,  
Nagoya, <sup>3</sup>Department of  
Neurosurgery, Japanese Red  
Cross Asahikawa Hospital,  
Asahikawa, Hokkaido, Japan

#### Address for correspondence:

Dr. Raghavendra Kumar  
Sharma,  
Department of Neurosurgery,  
AIIMS, Raipur, Chhattisgarh  
India.  
E-mail: sdr.raghavendra@gmail.  
com

#### Access this article online

Website: www.asianjns.org

DOI: 10.4103/ajns.AJNS\_82\_20

#### Quick Response Code:



**How to cite this article:** Kumar A, Sharma RK, Tanaka R, Yamada Y, Takizawa K, Kato Y. High-flow bypass with radial artery graft for cavernous carotid aneurysm. Asian J Neurosurg 2020;15:678-82.

Submitted: 08-Mar-2020 Revised: 01-Apr-2020  
Accepted: 29-Apr-2020 Published: 28-Aug-2020

This is an open access journal, and articles are distributed under the terms of the Creative Commons Attribution-NonCommercial-ShareAlike 4.0 License, which allows others to remix, tweak, and build upon the work non-commercially, as long as appropriate credit is given and the new creations are licensed under the identical terms.

For reprints contact: WKHLRPMedknow\_reprints@wolterskluwer.com

jugular vein was sacrificed. Posterior belly of digastric muscle was dissected from carotid sheath. Common facial vein was encountered which was dissected carefully to preserve hypoglossal nerve. Common facial vein was ligated and cut. Descending loop of ansa cervicalis and hypoglossal nerve was mobilized anterosuperiorly to completely expose carotids. Carotid sheath was incised and carotid bifurcation, ICA, external carotid artery (ECA) and superior thyroid artery was exposed [Figure 3a].

**Craniotomy and superficial temporal artery harvesting**

Parietal and frontal branches of STA were dissected from the flap [Figure 3b]. Frontotemporal craniotomy was done. Extratemporal bone toward the temporal pole was removed to make way for RA graft.

**Radial artery graft**

Preoperatively collateral circulation with ulnar artery was confirmed with Allen’s test as well as imaging. Incision was made as described above. Fascial sheath between brachioradialis and flexor carpi radialis muscle was incised and RA was exposed [Figure 4]. It was dissected free from surrounding soft tissue and accompanying concomitant veins. The artery was lifted using vascular tape and small muscular branches were coagulated and cut. Once the

artery was completely free, it was left *in situ*. Length of the graft was 18 cm.

**Tunneling**

Submandibular route was used for RA graft. Index finger was inserted between posterior belly of digastric and hypoglossal nerve. Blunt dissection was done with finger and styloid process was palpated. At this point finger was moved forward toward the anterior temporal region. A Kelly forceps was inserted from cranial end beneath the zygoma and temporalis muscle and its tip was felt by the finger inserted from neck. Then, the Kelly forceps was advanced into the passage made by finger to come out of cervical incision. A 24 Fr chest tube threaded with 1.0 silk suture was guided through the tunnel with help of Kelly forceps. On the cranial side, RA graft is tied to the 1.0 silk suture and suture is pulled from cervical side to position the RA graft inside the chest tube [Figure 4].

**Anastomosis**

**Superficial temporal artery-M3 anastomosis**

Purpose of this bypass was to prevent ischemic complications at the time of RA-M2 anastomosis

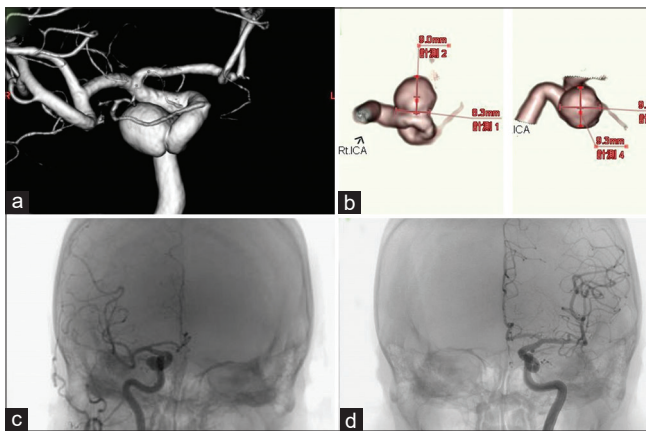


Figure 1: Three-dimensional digital subtraction angiography anteroposterior view (a) showing right side cavernous carotid aneurysm, measuring 9.3 mm × 9.7 mm with 8.3 mm neck diameter (b). Right and left internal carotid artery injection revealed poor cross flow through anterior communicating artery (c and d)

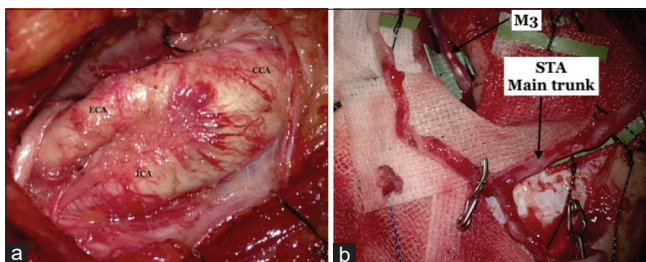


Figure 3: (a) Carotid bifurcation, internal carotid artery, and external carotid artery. (b) Superficial temporal artery with frontal and parietal branch harvested from scalp

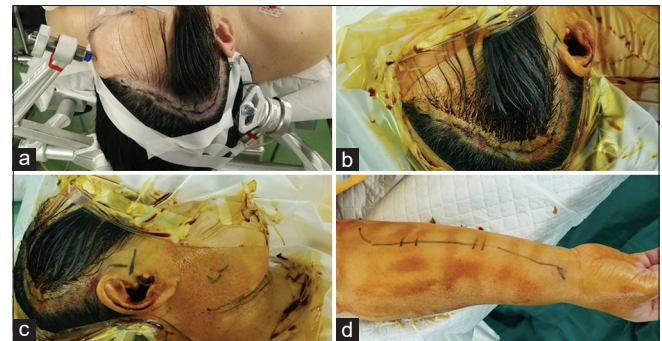


Figure 2: Head position and scalp incision (a and b), neck incision (c) and incision for radial artery graft (d)

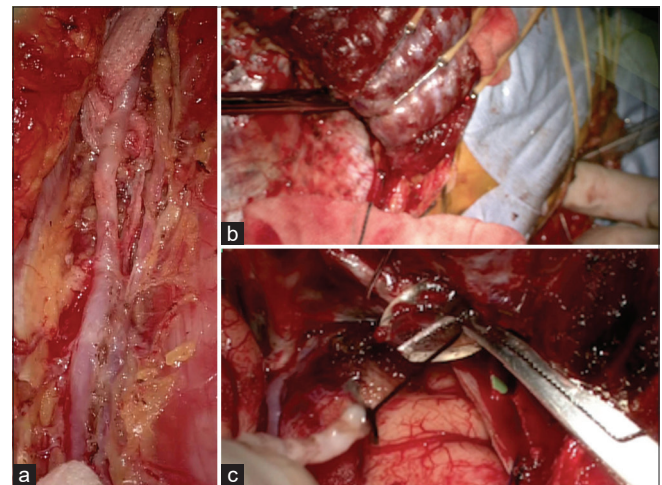


Figure 4: (a) Harvesting radial artery graft. (b) Technique of making tunnel for radial artery graft with help of finger dissection and Kelly forceps. (c) Radial artery graft is tied with silk suture and passed into the tunnel through the chest tube



that requires longer temporary proximal blockade (double insurance bypass). This also helps in monitoring the brain surface middle cerebral artery (MCA) pressure to assess the patency of RA graft.

Connective tissue around STA stump was thoroughly removed. Stump was incised at an angle of 60 degrees and one end was further incised for the same length as the diameter of distal end.

Margin was stained with violet dye. Arteriotomy site on M3 was marked and it was trapped with temporary clips. Arteriotomy was done and end to side anastomosis was performed with nylon 9-0 suture in interrupted fashion. Temporary occlusion time was 19 min.

#### Radial artery-M2 anastomosis

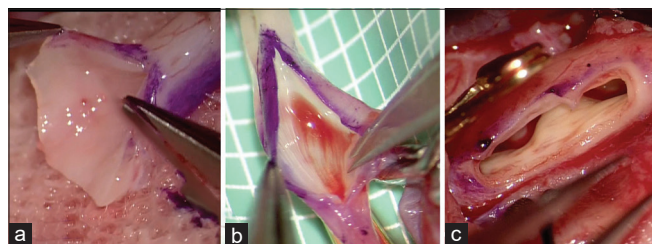
RA graft was flushed with heparinized saline and chest tube was removed from cranial end. Stump of RA graft was prepared and arteriotomy site on M2 was temporarily trapped [Figure 5]. Nylon 9-0 sutures were used for anastomosis. Temporary occlusion time was 25 min. Before removing the temporary clips from MCA, a temporary clip was placed over RA graft close to anastomosis site.

#### External carotid artery-radial artery anastomosis

RA graft stump was widely cut to make a large aperture. Arteriotomy was done in ECA after temporary trapping of ECA. Opening was enlarged with help of vascular punch [Figure 5]. End to side anastomosis was performed with prolene 7-0 suture.

#### Monitoring of brain surface pressure

This was done to ensure the patency of graft as well as to assess intraoperatively whether STA-MCA anastomosis is sufficient to maintain adequate brain perfusion or high-flow bypass is required. A cannula was inserted into the branch of STA and it was connected to pressure transducer. STA trunk was clamped and the transducer indicates the brain surface pressure of MCA. ICA was clamped and there was significant fall in pressure. After releasing STA clamp, MCA pressure increased, but still it was around 60% of baseline. Hence, the decision for high-flow ECA-MCA bypass was made. After performing ECA-MCA bypass with RA interposition graft, STA and



**Figure 5:** Preparation for anastomosis (a) preparation of radial artery graft stump for anastomosis (b) arteriotomy at M2 for radial artery-M2 anastomosis (c) arteriotomy at External carotid artery which has been enlarged using vascular punch

RA graft was unclamped and MCA stump pressure was measured. MCA pressure increased to baseline level indicating sound graft patency as well as adequate brain perfusion [Figure 6].

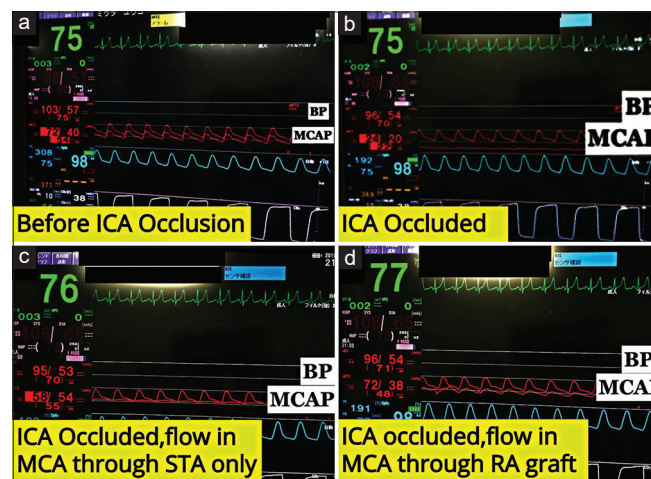
Dual imaging video angiography and intraoperative Doppler probe were also used to confirm graft patency [Figure 7]. Cervical ICA was double ligated and cut.

Postoperatively, the patient was extubated and there was no neurological deficit. Three-dimensional computerized tomography angiography revealed good flow through the graft into MCA and no antegrade flow in aneurysm [Figure 8].

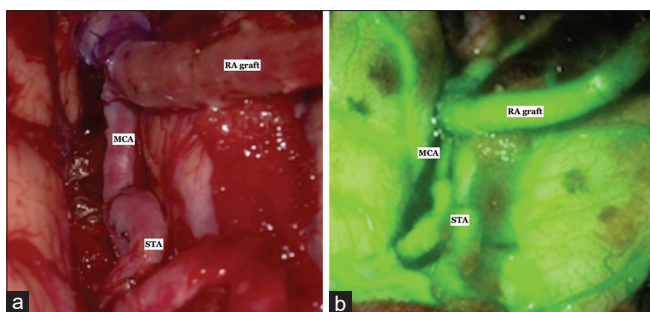
## Discussion

CCAs have relatively benign natural history. As per the International Study of Unruptured Aneurysm Trial, 5 years rupture rate for <13 mm, 13–24 mm and >25 mm size CCAs is 0%, 3.0% and 6.4%, respectively.<sup>[6]</sup> If rupture, they lead to direct caroticocavernous fistula (CCF) or rarely cause SAH in cases with intradural component. Fatal epistaxis due to sphenoid bone erosion is a rare complication. Spontaneous thrombosis of giant CCA had also been reported.<sup>[7]</sup> Stiebel-Kalish *et al.* published the follow-up results of treated and untreated patients of CCAs. Among 111 untreated patients, 2% had stroke, 1% had SAH, 1% had direct CCF, and 6% developed compressive optic neuropathy leading to overall 10% adverse events rate.<sup>[8,9]</sup>

CCAs can be managed by open surgical methods such as clipping, trapping with or without bypass or endovascular methods. Endovascular coiling with or without stent carry a high rate of recanalization and re-treatment.<sup>[10,11]</sup> Recently, pipeline devices had shown promising results, however,



**Figure 6:** BP and middle cerebral artery pressure measured through transducer connected to branch of superficial temporal artery before internal carotid artery occlusion (a), after internal carotid artery occlusion (b), internal carotid artery occluded but superficial temporal artery unclamped to fill middle cerebral artery (c) and internal carotid artery occluded and middle cerebral artery filled through radial artery graft (d)



**Figure 7: (a) Final view after radial artery-M2 and superficial temporal artery-M3. (b) Dual imaging video angiography revealing robust flow through both radial artery-M2 and superficial temporal artery-M3 anastomosis**

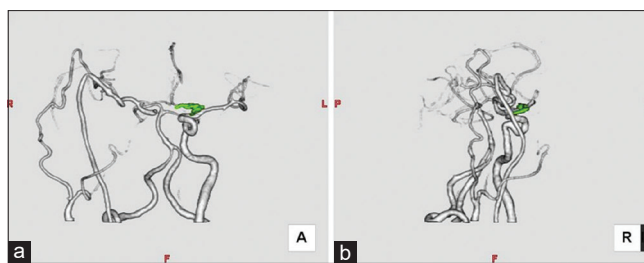
several studies have reported significant hemorrhagic and thrombotic complications.<sup>[12-14]</sup> Direct surgical methods such as clipping and trapping are technically challenging and carry a high risk of complications. Indirect methods such as high-flow bypass with ICA ligation can achieve aneurysm obliteration with acceptable morbidity and mortality rates.<sup>[15,16]</sup>

Murai *et al.* published results of 8 cases of giant CCAs managed by ECA-RA-MCA bypass with cervical ICA occlusion. Complete aneurysmal thrombosis was achieved in 100% cases and 87.5% patients showed symptomatic improvement. Postoperatively, one patient (12.5%) had a small ipsilateral frontal infarct, one patient (12.5%) developed transient trochlear nerve palsy, and one patient (12.5%) had one episode of seizure probably due to hyperperfusion syndrome.<sup>[17]</sup>

Shimizu *et al.* performed high-flow bypass with ICA occlusion in six patients with CCAs with acceptable clinical and hemodynamical results.<sup>[18]</sup>

In this reported case, CCA was incidentally detected. In view of poor cross flow on DSA, we decided to go for revascularization with carotid occlusion. Option of endovascular treatment was also explained to patient and relatives; however, they opted for surgical management.

There is no clear cut guideline to decide whether revascularization should be done or not after ICA is sacrificed. One policy is to evaluate cerebrovascular reserve preoperatively by Balloon occlusion test (BOT), single-photon emission computed tomography or positron emission tomography and to decide the need for revascularization. Risk of ischemic complications is 32%–60%, if carotid occlusion is performed without preoperative evaluation of cerebrovascular reserve.<sup>[19,20]</sup> Risk of infarction is 22%, if revascularization is not done on the basis of preoperative BOT showing adequate cerebrovascular reserve. With additional revascularization in patients showing adequate cerebrovascular reserve, risk of infarction comes down to 14%.<sup>[21,22]</sup> Other problem with parent artery occlusion without revascularization is delayed



**Figure 8: Postoperative angiography anteroposterior (a) and lateral (b) view showing good flow through radial artery graft and nonvisualization of aneurysm**

*de novo* aneurysm formation or enlargement of existing aneurysms due to increased hemodynamic stress.<sup>[23]</sup> This is why we decided to go for revascularization without performing preoperative BOT. BOT also helps in deciding between low-flow and high-flow bypass. High-flow and low-flow STA-MCA bypass are performed for patients with poor and moderate cerebrovascular reserve, respectively.<sup>[24]</sup> We intraoperatively decided to go for high-flow bypass by measuring MCA pressure after STA-M3 anastomosis and ICA temporary occlusion using pressure transducer connected to a branch of STA.

Although high-flow bypass appears to be a very extensive technique, it is minimally invasive to the brain except for the temporary occlusion part. To reduce the temporary occlusion-related ischemic complications, we performed STA-M3 anastomosis in our case before going for RA-M2 anastomosis. Occlusion time for STA-M3 anastomosis is less as compared to RA-M2 anastomosis leading to less chances of ischemic complications. Second, occlusion at a more proximal segment (M2) carries more risk as compared to distal occlusion (M3).<sup>[15,25,26]</sup> Hence, by performing STA-M3 anastomosis, during RA-M2 anastomosis, MCA territory is supplied by STA and risk for ischemic complications is minimized.

## Conclusion

High-flow bypass with RA interposition graft followed by cervical ICA ligation is an effective management option for CCAs. Performing STA-MCA bypass as insurance bypass and intraoperative measurement of MCA stump pressure adds to the safety of the procedure. Complications related to surgical technique are minimal, when performed by expert surgeon at high volume centers.

## Declaration of patient consent

The authors certify that they have obtained all appropriate patient consent forms. In the form the patient(s) has/have given his/her/their consent for his/her/their images and other clinical information to be reported in the journal. The patients understand that their names and initials will not be published and due efforts will be made to conceal their identity, but anonymity cannot be guaranteed.

## Financial support and sponsorship

Nil.

## Conflicts of interest

There are no conflicts of interest.

## References

- Ambekar S, Madhugiri V, Sharma M, Cuellar H, Nanda A. Evolution of management strategies for cavernous carotid aneurysms: A review. *World Neurosurg* 2014;82:1077-85.
- Welch BG, Batjer HH. Cavernous carotid aneurysms: You can but should you? *World Neurosurg* 2014;82:996-7.
- Hardy WG, Thomas LM, Webster JE, Gurdjian ES. Carotid ligation for intracranial aneurysm: A follow-up study of 54 patients. *J Neurosurg* 1958;15:281-9.
- Wanke I, Doerfler A, Stolke D, Forsting M. Carotid cavernous fistula due to a ruptured intracavernous aneurysm of the internal carotid artery: Treatment with selective endovascular occlusion of the aneurysm. *J Neurol Neurosurg Psychiatry* 2001;71:784-7.
- Ratre S, Yadav YR, Parihar VS, Kher Y. Microendoscopic removal of deep-seated brain tumors using tubular retraction system. *J Neurol Surg A Cent Eur Neurosurg* 2016;77:312-20.
- Wiebers DO. Unruptured intracranial aneurysms: Natural history, clinical outcome, and risks of surgical and endovascular treatment. *Lancet* 2003;362:103-10.
- Kasliwal MK, Suri A, Sai Kiran NA, Sharma BS. Spontaneous thrombosis of giant cavernous internal carotid artery aneurysm in a neonate. Case report and review of the literature. *Pediatr Neurosurg* 2008;44:329-32.
- Stiebel-Kalish H, Kalish Y, Bar-On RH, Setton A, Niimi Y, Berenstein A, *et al.* Presentation, natural history, and management of carotid cavernous aneurysms. *Neurosurgery* 2005;57:850-7.
- Kumar A, Kutty RK, Yamada Y, Tanaka R, Ravisankar V, Musara A, *et al.* A retrospective analysis of treatment outcomes of 40 incidental cavernous carotid aneurysms. *World Neurosurg* 2019;130:e1034-40.
- Molyneux AJ, Kerr RS, Yu LM, Clarke M, Sneade M, Yarnold JA, *et al.* International subarachnoid aneurysm trial (ISAT) of neurosurgical clipping versus endovascular coiling in 2143 patients with ruptured intracranial aneurysms: A randomised comparison of effects on survival, dependency, seizures, rebleeding, subgroups, and aneurysm occlusion. *Lancet* 2005;366:809-17.
- Raymond J, Guilbert F, Weill A, Georganos SA, Juravsky L, Lambert A, *et al.* Long-term angiographic recurrences after selective endovascular treatment of aneurysms with detachable coils. *Stroke* 2003;34:1398-403.
- Becske T, Kallmes DF, Saatci I, McDougall CG, Szikora I, Lanzino G, *et al.* Pipeline for uncoilable or failed aneurysms: Results from a multicenter clinical trial. *Radiology* 2013;267:858-68.
- Kulcsár Z, Houdart E, Bonafé A, Parker G, Millar J, Goddard AJ, *et al.* Intra-aneurysmal thrombosis as a possible cause of delayed aneurysm rupture after flow-diversion treatment. *AJNR Am J Neuroradiol* 2011;32:20-5.
- Turowski B, Macht S, Kulcsár Z, Hänggi D, Stummer W. Early fatal hemorrhage after endovascular cerebral aneurysm treatment with a flow diverter (SILK-Stent): Do we need to rethink our concepts? *Neuroradiology* 2011;53:37-41.
- Ishishita Y, Tanikawa R, Noda K, Kubota H, Izumi N, Katsuno M, *et al.* Universal extracranial-intracranial graft bypass for large or giant internal carotid aneurysms: Techniques and results in 38 consecutive patients. *World Neurosurg* 2014;82:130-9.
- Patel HC, Teo M, Higgins N, Kirkpatrick PJ. High flow extra-cranial to intra-cranial bypass for complex internal carotid aneurysms. *Br J Neurosurg* 2010;24:173-8.
- Murai Y, Mizunari T, Umeoka K, Tateyama K, Kobayashi S, Teramoto A. Radial artery grafts for symptomatic cavernous carotid aneurysms in elderly patients. *Neurol India* 2011;59:537.
- Shimizu H, Matsumoto Y, Tominaga T. Parent artery occlusion with bypass surgery for the treatment of internal carotid artery aneurysms: Clinical and hemodynamic results. *Clin Neurol Neurosurg* 2010;112:32-9.
- Linskey ME, Sekhar LN, Hirsch WL Jr., Yonas H, Horton JA. Aneurysms of the intracavernous carotid artery: Natural history and indications for treatment. *Neurosurgery* 1990;26:933-7.
- Linskey ME, Jungreis CA, Yonas H, Hirsch WL Jr., Sekhar LN, Horton JA, *et al.* Stroke risk after abrupt internal carotid artery sacrifice: Accuracy of preoperative assessment with balloon test occlusion and stable xenon-enhanced CT. *AJNR Am J Neuroradiol* 1994;15:829-43.
- Lye RH, Jha AN. Unruptured aneurysms of the intracavernous internal carotid artery: Outcome following carotid ligation or conservative treatment. *Br J Neurosurg* 1989;3:181-8.
- Mount LA. Results of treatment of intracranial aneurysms using the selverstone clamp. *J Neurosurg* 1959;16:611-8.
- Dare AO, Chaloupka JC, Putman CM, Fayad PB, Awad IA. Failure of the hypotensive provocative test during temporary balloon test occlusion of the internal carotid artery to predict delayed hemodynamic ischemia after therapeutic carotid occlusion. *Surg Neurol* 1998;50:147-55.
- Kai Y, Hamada J, Morioka M, Yano S, Mizuno T, Kuroda J, *et al.* Treatment strategy for giant aneurysms in the cavernous portion of the internal carotid artery. *Surg Neurol* 2007;67:148-55.
- Ishikawa T, Kamiyama H, Kobayashi N, Tanikawa R, Takizawa K, Kazumata K. Experience from "double-insurance bypass." Surgical results and additional techniques to achieve complex aneurysm surgery in a safer manner. *Surg Neurol* 2005;63:485-90.
- Hongo K, Horiuchi T, Nitta J, Tanaka Y, Tada T, Kobayashi S. Double-insurance bypass for internal carotid artery aneurysm surgery. *Neurosurgery* 2003;52:597-602.