



Contents lists available at ScienceDirect

## International Journal of Surgery Case Reports

journal homepage: [www.casereports.com](http://www.casereports.com)

# Piezosurgery: A new and safe technique for distraction osteogenesis in Pierre Robin sequence review of the literature and case report



Manlio Galié\*, Valentina Candotto, Giovanni Elia, Luigi C. Clauser

Unit of Cranio Maxillo Facial Surgery, Center for Orbital Pathology & Surgery, Reference Center for Treatment of Rare Diseases, EACMFS International Teaching Centers Network, St. Anna Hospital and University, Via Aldo Moro n. 8 Cona (FE), Ferrara 44124, Italy

## ARTICLE INFO

## Article history:

Received 24 July 2014

Received in revised form

27 November 2014

Accepted 28 November 2014

Available online 5 December 2014

## Keywords:

Ultrasound scalpel

Infant and pediatric surgery

Mandibular reconstruction

Pierre Robin sequence

Mandibular distraction

Piezosurgery

Airway management

Bone healing

## ABSTRACT

**INTRODUCTION:** Pierre Robin sequence (PRS) is characterized by microgenia and retrognathia. Cleft palate and glossoptosis are frequently associated with airway obstruction and difficulty in swallowing. Distraction osteogenesis with micro-distractors has recently been considered as a surgical option during the neonatal age.

**CASE PRESENTATION:** A 6-week-old female with PRS underwent mandibular lengthening in neonatal age. Mandibular osteotomies were performed with the piezoelectric scalpel.

**DISCUSSION:** Piezosurgery represents an innovative technique as it offers the maxillofacial surgeon the opportunity to make precise bone cuts without damaging the soft tissue, minimizing the invasiveness of the surgical procedure, and the opportunity of working in a field which is almost totally blood free.

**CONCLUSION:** The use of a piezoelectric device to perform this kind of surgery provides clinical and surgical results which would be difficult with traditional instruments, not only for the patient's benefit but also for the surgeon's. Preservation of the original bony structure, especially of the cancellous bone, will benefit the bone healing process due to its high estrogenic potential.

© 2014 The Authors. Published by Elsevier Ltd. on behalf of Surgical Associates Ltd. This is an open access article under the CC BY-NC-ND license (<http://creativecommons.org/licenses/by-nc-nd/3.0/>).

## 1. Introduction

Pierre Robin sequence (PRS) is characterized by microgenia with retrognathia cleft palate glossoptosis and frequently is associated with airway obstruction and difficulty in swallowing. The respiratory obstruction may be severe and require immediate treatment at birth. Numerous surgical and nonsurgical techniques have been proposed for the treatment of severe respiratory obstruction and feeding difficulties [1].

In the algorithm of processing of the sequence, distraction osteogenesis with micro-distractors has recently been considered as a surgical option which is very important during the neonatal age. The benefits associated with piezoelectric bone surgery can result in significant improvement of new bone formation during distraction osteogenesis in neonatal and pediatric patients [2].

Actually, bone regeneration processes during osteodistraction require minimally invasive surgery with preservation of soft tissues and vascularization. The preservation of osteocytes and periosteal tissue that constitute a biologic couch for bone regeneration is also essential. Piezoelectric osteotomy permits a micrometric selective cut and clear surgical site with the cavitation effect created by irrigation/cooling solution and oscillating tip.

Positive clinical effects of piezoelectric bone surgery are considered accurate cutting and the absence of bone necrosis, while from the biological point of view a clean cut surface with living osteocytes enhances the early release of morphogenetic proteins which have been reported to greatly stimulate bone regeneration.

Histomorphological analyses demonstrated that more inflammatory cells were present in sites where a piezoelectric scalpel had been used. Also, neo-osteogenesis was consistently more active in those bone samples. Moreover, bone around areas treated with the piezoelectric bone surgery technique showed an earlier increase in BMP-and TGF- $\beta$ 2 proteins as well as a reduction in proinflammatory cytokines [3].

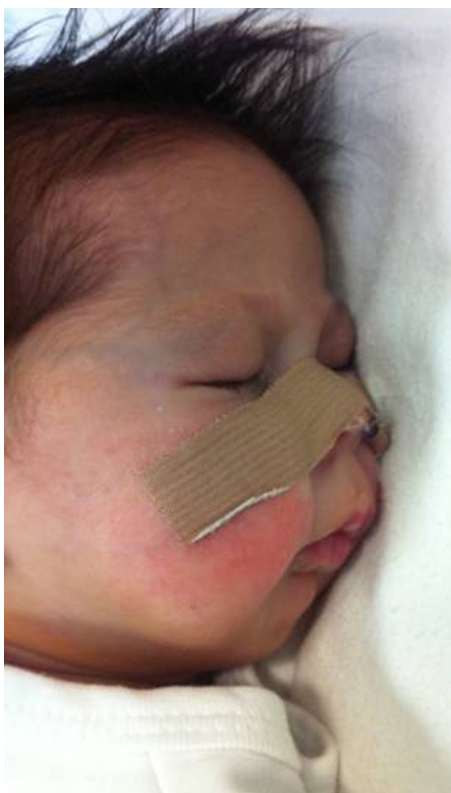The treatment of airway obstruction in the newborn with PRS is complex; sometimes it may constitute a real surgical emergency [4]. The evolution of devices for osteodistraction and the use of hybrid techniques have allowed surgical treatment in the first few months of life [5].

The complications associated with the use of these devices are, however, well documented and should be taken into account [6]. The authors describe the treatment of a neonate suffering from PRS with severe respiratory obstruction.

## 2. Case presentation

A 6-week-old female infant with PRS underwent mandibular lengthening in neonatal age. The little patient was admitted to our

\* Corresponding author. Tel.: +39 532236365.  
E-mail address: [glm@unife.it](mailto:glm@unife.it) (M. Galié).

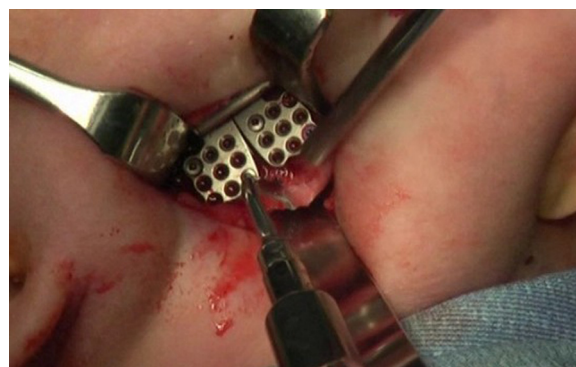

**Fig. 1.** A 6-week-old female with Pierre Robin sequence.

unit with severe airway obstruction and tracheostomy (Fig. 1). Pre-operative flexible video laryngoscopy showed limited movement of the dorsum of the tongue to the posterior pharyngeal wall and collapse of the epiglottis.

Evaluation by a multidisciplinary team included performing fibroscopic assessment. 3D CT confirmed severe mandibular retrognathia and hypoplasia.

The baby was treated by applying distraction KLS-Martin micro devices (Zurich) placed through an external Risdon-type incision. After two days latency, the activation rates were 1.5 mm per day based on a three-per-day rhythm. The activation period was 15 days with a 60 day consolidation period. The osteotomies were performed externally using a Piezosurgery device manufactured



**Fig. 3.** (A) Pre-op 3D CT showing severe mandibular hypoplasia with retrognathia at 6 weeks old. (B) Post-op 3D CT showing normal mandibular development two years after the distraction procedure.

by Mectron Medical Technology (Carasco, Italy) which allows great cutting accuracy and the possibility of use in very restricted areas (Fig. 2).

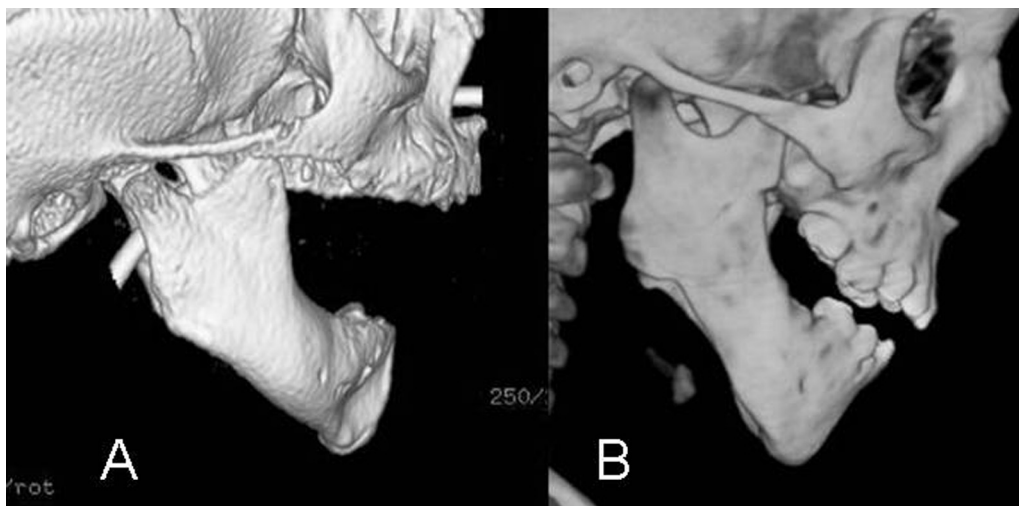
After the early distraction protocol at the age of 3 months, the maxillo-mandibular relationship was within 2 mm of the incisors edge to edge.

Comparison of pre-distraction and post-distraction lateral CT scans confirmed a significant improvement in the airway space. Direct visualization with flexible endoscope demonstrated the airway changes (Fig. 3). The infant was successfully decannulated seven days after the active phase of the distraction (20 mm). Improvement in feeding was seen following mandibular distraction and removal of the nasogastric tube (Fig. 4). The last control was performed at the age of 28 months (Fig. 5). The baby had a regular follow-up.

### 3. Discussion

Piezoelectric surgery is based on the use of ultrasound for the cutting of bone. It represents an innovative technique as it offers the maxillofacial surgeon the opportunity to make precise bone cuts without damaging any soft tissue, minimizing the invasiveness of the surgical procedure, and the opportunity of working in a field which is almost totally blood free [7].

In 2001 the Italian odontostomatologist Tomaso Vercellotti introduced an angled piezoelectric short saw, which presented benefits for osteotomies during oral surgery with no side effects on



**Fig. 2.** Intraoperative right osteotomy performed with piezosurgery and placement of the distractor device (same on the left).



Fig. 4. The baby at 28 months with normal appearance and function.

adjacent soft tissue. The Piezoelectric ultrasound osteotomy device is ideal for complex surgical sites where soft and delicate structures are very close to the osteotomy lines; this is due to its selective cut, which works only on mineralized structures [2]. Osteotomy of the ramus of the mandible is probably the most crucial step of the surgical procedure in early mandibular distraction [8].

A surgical way was introduced out to avoid nerve damage, obtaining favorable results [9]. It is not difficult to guess that for many surgeons, who have only recently begun to approach this pathology with distraction osteogenesis, a safer procedure to perform osteotomies of the ramus would be needed. This is true also in consideration of the anatomic variability of the nerve course [10]. Piezoelectric surgery could be a much safer procedure which selectively works only on hard, mineralized tissues, sparing soft tissues such as the mandibular nerve. Furthermore, many other structures can be affected when performing osteotomies on the mandibular

ramus with standard burs or chisels, such as the muscles, periosteum, and vessels [11].

Sørensen et al. [12] showed in five cases of skull base surgery that with a piezoelectric device there was no osteonecrosis, less damage to the surrounding soft tissue, and better vision of the operative site.

Assael et al. [13] stated that damage to the mandibular nerve during surgery may result in neuroma-like changes with fascicles, epineural tissues, and axons mixed into the surrounding scar tissue. Eriksson et al. [14] reported that such an interruption of the structures of a nerve would result in proliferation of axons, a plausible pathophysiological cause of paresthesia, dysesthesia, allodynia, and phantom pain, and it might develop into severe disabling pain. In a study by Metzger et al. [15] it was shown that the epineurium became roughened without the deeper structures being affected after piezosurgery for transposition of the mandibular nerve and claimed the degree of injury was lower than when using conventional rotary burs.

It should be stressed that ultrasonic osteotomy and conventional osteotomy demand quite different manual controls of the operator. Whereas exerting more pressure on a rotary bur accelerates incision, placing excessive pressure on an ultrasonic tip can prevent its proper vibration, and experience with ultrasound suggests that this will result in overheating [16]. At each moment, a pressure must be used that is right for the bone being cut. Although the use of appropriate pressure minimizes the risk of overheating, regular interruptions to prevent overheating are nevertheless advisable, especially during long or deep cuts [17]. The use of piezosurgery requires only a short learning curve, but is important to gain adequate dexterity [18]. Piezosurgery definitely enhances handling of delicate structures in the oral and maxillofacial region. Concerning osteotomies of thin and fragile bones like those of babies, application of ultrasound is assessed to be superior to other mechanical instruments because of easy handling, efficient bone ablation and minimal accidental harm to adjacent soft tissue structures [19]. As bone healing is not disturbed by piezosurgery, and even seems to be improved, this method will have a major influence on new minimally invasive bone surgery techniques with special regard to biomechanics [20].

Preservation of the original bony structure, especially of the cancellous bone, will benefit the bone healing process due to its high osteogenic potential. This circumstance might have clinical consequences in particularly concerning the velocity of distraction therapy in cranio maxillofacial surgery. Compared with tracheotomy, patients treated with distraction had a shorter hospital stay with reduction of short and long term costs [21]. Cumulative

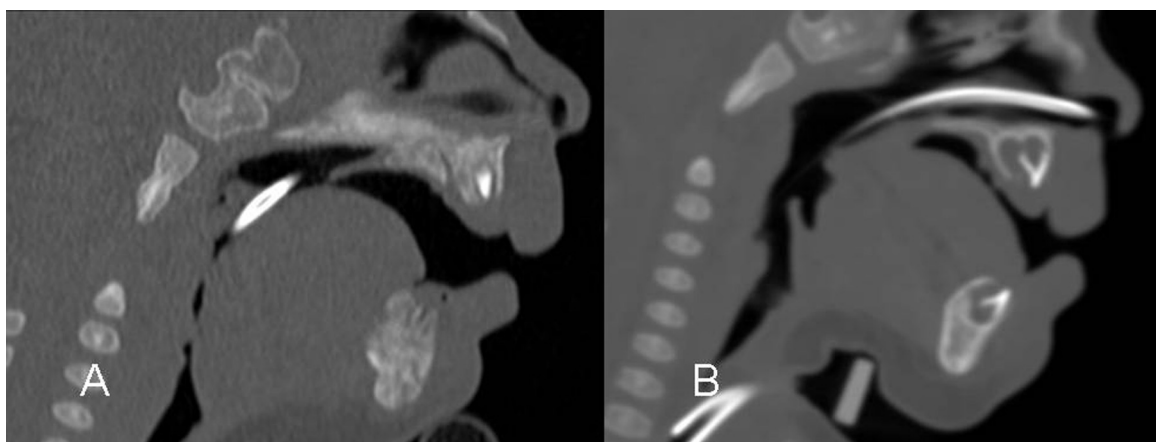


Fig. 5. (A) Airway obstruction with collapsed tongue and epiglottis before distraction; (B) mandibular advancement – tongue and epiglottis are in an advanced form with creation of a new pharyngeal space airway after distraction.

cost for home care and absence from work have a significant impact on the total costs [22].

#### 4. Conclusion

In summary, mandibular distraction osteogenesis in neonates with PRS is an effective treatment option to safely relieve upper airway obstruction associated with micrognathia.

For selected newborns mandibular osteogenesis distraction will allow avoidance of a tracheostomy and improved oral feeding. A careful evaluation of the patient's airway and feeding must be performed and evaluated by a multidisciplinary team approach.

Planning and selection of an appropriate distraction vector is of paramount importance in early distraction osteogenesis to avoid severe complications. The use of a piezoelectric device to perform this kind of surgery provides clinical and surgical results which would not be possible with traditional instruments, not only for the patient's benefit but also for the surgeon's.

#### Conflict of interest statement

None.

#### Funding

None.

#### Ethical approval

Retrospective paper case report based on clinical records.

#### Authors contribution

Manlio Galiè MD, DMD: study concept, design, surgeon.  
Valentina Candotto MD: data analysis, writing the paper.  
Riccardo Tieghi MD: surgeon.  
Giovanni Elia MD: data collection.  
Luigi C. Clauser MD, DMD, PhD: surgeon.

#### Consent

"Written informed consent was obtained from the patient for publication of this case report and accompanying images. A copy of the written consent is available for review by the Editor-in-Chief of this journal on request."

#### Key learning points

- Ultrasound scalpel
- Infant and pediatric surgery
- Mandibular reconstruction
- Pierre Robin sequence
- Mandibular distraction

- Piezosurgery
- Airway management
- Bone healing

#### References

- [1] A.K. Gosain, Discussion: the surgical correction of Pierre Robin sequence: mandibular distraction osteogenesis versus tongue-lip adhesion, *Plast. Reconstr. Surg.* 133 (June (6)) (2014) 1440–1442.
- [2] T. Vercellotti, S. De Paoli, M. Nevins, The piezoelectric bony window osteotomy and sinus membrane elevation: introduction of a new technique for simplification of the sinus augmentation procedure, *Int. J. Periodontics Restorative Dent.* 21 (2001) 561–567.
- [3] G. Preti, G. Martinasso, B. Peirone, R. Navone, C. Manzella, G. Muzio, C. Russo, R.A. Canuto, G. Schierano, Cytokines and growth factors involved in the osseointegration of oral titanium implants positioned using piezoelectric bone surgery versus a drill technique: a pilot study in minipigs, *J. Periodontol.* 78 (April (4)) (2007) 716–722.
- [4] R.B. Schaefer, J.A. Stadler, A.K. Gosain, To distract or not to distract: an algorithm for airway management in isolated Pierre Robin sequence, *Plast. Reconstr. Surg.* 113 (2004) 1113–1125.
- [5] M. Galiè, L. Clauser, Early mandibular distraction osteogenesis in neonates and pediatric age, *Int. J. Oral Maxillofac. Surg.* 42 (October (10)) (2013) 1212–1213.
- [6] M. Heiland, M. Blessmann, P. Pohlenz, L. Li, et al., Intraoral osteotomies using piezosurgery for distraction in an infant with Pierre-Robin sequence, *Clin. Oral Invest.* 11 (2007) 303–306.
- [7] C. Huang, R. Ross, Surgical advancement of the retrognathic mandible in growing children, *Am. J. Orthod.* 82 (1982) 89–103.
- [8] A. Itró, G. Lupo, A. Carotenuto, M. Filipi, E. Cocozza, A. Marra, Benefits of piezoelectric surgery in oral and maxillofacial surgery. Review of literature, *Minerva Stomatol.* 61 (May (5)) (2012) 213–224.
- [9] M. Robiony, F. Polini, Piezosurgery: a safe method to perform osteotomies in young children affected by hemifacial microsomia, *J. Craniofac. Surg.* 21 (November (6)) (2010) 1813–1815.
- [10] B.H. Grayson, S. McCormick, P.E. Santiago, et al., Vector of device placement and trajectory of mandibular distraction, *J. Craniofac. Surg.* 8 (1997) 47.
- [11] E.Y. Kan, A. Doyle, T.B. De Chalmers, Morphological variability of inferior alveolar nerve in low-grade craniofacial microsomia, *J. Craniofac. Surg.* 13 (2002) 53.
- [12] M.G. Sørensen, K. Henriksen, S. Schaller, M.A. Karsdal, Biochemical markers in preclinical models of osteoporosis, *Biomarkers* 12 (May–June (3)) (2007) 266–286, Review.
- [13] L.A. Assael, The nerve under the microscope, *J. Oral Maxillofac. Surg.* 60 (2002) 483–484.
- [14] L. Eriksson, S. Hillerup, J. Reibel, S. Persson, A. Brun, Traumatic changes of the inferior alveolar nerve and gasserian ganglion after removal of a mandibular third molar: report of a case, *J. Oral Maxillofac. Surg.* 64 (2006) 1821–1825.
- [15] M.C. Metzger, K.H. Bormann, R. Schoen, N.C. Gellrich, R. Schmelzeisen, Inferior alveolar nerve transposition—an in vitro comparison between piezosurgery and conventional bur use, *J. Oral Implantol.* 32 (2006) 19–25.
- [16] J.C. Budd, D. Gekelman, J.M. White, Temperature rise of the post and on the root surface during ultrasonic post removal, *Int. Endod. J.* 38 (2005) 705–711.
- [17] M. Robiony, F. Polini, F. Costa, T. Vercellotti, M. Politi, Piezoelectric bone cutting in multipiece maxillary osteotomies, *J. Oral Maxillofac. Surg.* 62 (2004) 759–761.
- [18] A. Rachmiel, R. Manor, M. Peled, et al., Intraoral distraction osteogenesis of the mandible in hemifacial microsomia, *J. Oral Maxillofac. Surg.* 59 (2001) 728.
- [19] L.C. Clauser, M. Galiè, R. Tieghi, G. Elia, Piezosurgery in Maxillo Facial Osteotomies Workshop in New Horizons in Orthognathic Surgery NH14 Ferrara, February 28th–March 1st 2014.
- [20] S. Stübinger, J.W. Goethe, Bone healing after piezosurgery® and its influence on clinical applications, *J. Oral Maxillofac. Surg.* 65 (September (9) (Suppl. 1)) (2007), 39. e7–39. e8.
- [21] A. Zeitouni, J. Manoukian, Tracheostomy in the first year of life, *J. Otolaryngol.* 22 (1993) 431.
- [22] E.C. Paes, J.J. Fouché, M.S. Muradin, L. Speleman, M. Kon, C.C. Breugem, Tracheostomy versus mandibular distraction osteogenesis in infants with Robin sequence: a comparative cost analysis, *Br. J. Oral Maxillofac. Surg.* 52 (March (3)) (2014) 223–229.

#### Open Access

This article is published Open Access at [sciedirect.com](http://sciedirect.com). It is distributed under the [IJSCR Supplemental terms and conditions](#), which permits unrestricted non commercial use, distribution, and reproduction in any medium, provided the original authors and source are credited.