

A rare complication of balloon pulmonary angioplasty: Aortopulmonary window and its treatment 🎧

id Birgül Varan, id Kahraman Yakut, id Kürşad Tokel, id Süleyman Özkan*, id Sait Aşlamacı*
 Departments of Pediatric Cardiology, and *Cardiovascular Surgery, Faculty of Medicine, Başkent University; Ankara-Turkey

Introduction

Surgical repair, balloon dilatation, and stenting are good treatment options for stenosis in the branches of the pulmonary artery (1, 2). Balloon angioplasty may cause complications such as aneurysm formation, vessel dissection or rupture, iatrogenic aortopulmonary window (APW) formation, and temporary unilateral lung edema (2-5). Iatrogenic APW has been rarely reported after pulmonary angioplasty (2, 3). Acute formation of APW causes increased volume load on the left heart and leads to congestive heart failure. Here we report a rare case of iatrogenic APW with congestive heart failure that did not respond to medical treatment.

Case Report

The case was diagnosed with transposition of great arteries on postnatal first day, and arterial switch operation was performed using the LeCompte maneuver at age 14 days. The stenosis in the left pulmonary artery gradually progressed and reached serious levels at age 5 years. At this age, balloon angioplasty was performed using gradually increasing balloon sizes of 8, 10, and 12 mm (balloon/stenosis ratio: 3.2) (Fig. 1). A pulmonary angiogram obtained after the procedure showed that the pulmonary artery was not visualized well and that the contrast media was washed with blood coming from elsewhere. An association between the aorta and pulmonary artery was suspected, and a contrast agent was injected into the aorta. Angiography revealed that the contrast agent passed from the aorta into the pulmonary bed at the level of the ascending aorta (Video 1). No extravasation out of vessels or into the lungs was observed. Oxymetric studies revealed the presence of a left-to-right shunt at the pulmonary artery level, and the flow ratio was calculated as 1.9. We started follow-up of our case in the intensive care unit and initiated medical treatment. Despite medical treatment, heart failure persisted, and the patient was not hemodynamically stable. The iatrogenic APW was surgically repaired on day 5 after the balloon pulmonary angioplasty.

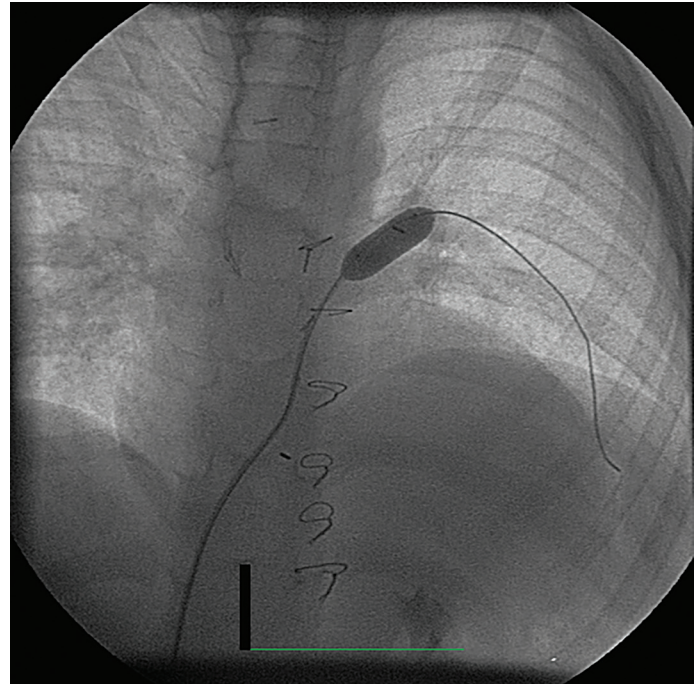


Figure 1. Balloon angioplasty performed on the left pulmonary artery stenosis is observed

Discussion

The formation of iatrogenic APW after pulmonary angioplasty in patients who have undergone ASO can be regarded as a potential complication (2, 4). Dilatation with balloon angioplasty, stenting, and surgical intervention are the treatment options for supravalvular pulmonary stenosis after ASO. During pulmonary angioplasty procedures, complications such as aneurysms, vessel dissection or rupture, thrombosis and iatrogenic APW formation may develop. In cases with iatrogenic APW after pulmonary angioplasty, lung edema due to reperfusion, myocardial ischemia together with coronary steal syndrome, left ventricle volume overload due to an acute left-to-right shunt, and congestive heart failure may develop. In such cases, heart failure and hemodynamic disorders may develop rapidly within hours, or they may manifest as pulmonary edema, tachypnea, and heart failure that develop over months. Vida et al. (1) have reported that the patient was stabilized with diuretic treatment because the patient developed pulmonary edema after pulmonary artery CP-stent and balloon angioplasty. Four months after the procedure, iatrogenic APW was detected when the patient had progressive respiratory distress and right pleural effusion. Detecting iatrogenic APW during balloon angioplasty was important for early hemodynamic stabilization of our patient. It is recommended to treat cases that respond to medical treatment, those who are not in heart failure, and are hemodynamically stable under elective conditions (1, 4, 6). As in our case, cases that do not respond to medical treatment or that develop heart

failure or pulmonary edema are to be treated with surgical or interventional procedures before being discharged from hospital. It has been reported that covered stents can be safely used in the treatment of iatrogenic APW (1-3, 7, 8). Surgical interventions are frequently performed to treat both iatrogenic and native APW, and the potential results of surgery are well known (5). We started to follow-up our patient in the intensive care unit and initiated medical treatment. During follow-up, the patient developed congestive heart failure. The patient did not respond to intense medical treatment and underwent surgery to repair the iatrogenic APW on day 5 after balloon angioplasty. We also thought that surgery could be safer due to the large iatrogenic APW. The communication between the aorta and pulmonary artery was repaired primarily. The stenosis in the left pulmonary artery was repaired and widened using a patch. Our patient rapidly recovered from heart failure after surgery.

Conclusion

The patients in whom the LeCompte maneuver is used during arterial switch operations are at risk of development of stenosis in the pulmonary artery and its branches. After performing balloon angioplasty on stenosis of the branches of the pulmonary artery, the rare but important complication of iatrogenic APW must be considered. Even if the surgeon is experienced in handling complications, the surgical team and operation room should be prepared for emergency interventions.

References

1. Vida VL, Biffanti R, Stellin G, Milanesi O. Iatrogenic aortopulmonary fistula occurring after pulmonary artery balloon angioplasty: a word of caution. *Pediatr Cardiol* 2013; 34: 1267-8.
2. Marini D, Ferraro G, Agnoletti G. Iatrogenic "aortopulmonary window": percutaneous rescue closure as a bridge to surgical repair. *Cardiol Young* 2016; 26: 609-11.
3. Tzifa A, Papagiannis J, Qureshi S. Iatrogenic aortopulmonary window after balloon dilation of the pulmonary artery stenosis following arterial switch operation. *J Invasive Cardiol* 2013; 25: E188-90.
4. Takayama H, Sekiguchi A, Chikada M, Noma M, Ishida R. Aortopulmonary window due to balloon angioplasty after arterial switch operation. *Ann Thorac Surg* 2002; 73: 659-61.
5. Alsoufi B, Schlosser B, McCracken C, Kogon B, Kanter K, Border W, et al. Current Outcomes of Surgical Management of Aortopulmonary Window and Associated Cardiac Lesions. *Ann Thorac Surg* 2016; 102: 608-14.
6. Ailawadi G, Lim DS, Peeler BB, Matsumoto AH, Dake MD. Traumatic ascending aortopulmonary window following pulmonary artery stent dilatation: therapy with aortic endovascular stent graft. *Pediatr Cardiol* 2007; 28: 305-8.
7. Stamato T, Benson LN, Smallhorn JF, Freedom RM. Transcatheter closure of an aortopulmonary window with a modified double umbrella occluder system. *Cathet Cardiovasc Diagn* 1995; 35: 165-7.
8. Marini D, Calcagni G, Ou P, Bonnet D, Agnoletti G. Percutaneous

treatment of aorto-pulmonary window in a one year old child. *Int J Cardiol* 2008; 129: e91-3.

Video 1. The angiography revealed that the contrast agent passed from the aorta into the pulmonary bed at the level of the ascending aorta.

Address for Correspondence: Dr. Kahraman Yakut,

Başkent Üniversitesi Tıp Fakültesi,

Çocuk Kardiyoloji Bilim Dalı,

Ankara-Türkiye

Phone: +90 312 203 68 68/1382

E-mail: kahramanyakut@gmail.com

©Copyright 2018 by Turkish Society of Cardiology - Available online at www.anatoljcardiol.com

DOI:10.14744/AnatolJCardiol.2018.24704

