



ELSEVIER

Contents lists available at ScienceDirect

# Toxicology Reports

journal homepage: [www.elsevier.com/locate/toxrep](http://www.elsevier.com/locate/toxrep)

## Safety assessment of the methanol extract of the stem bark of *Amphimas pterocarpoides* Harms: Acute and subchronic oral toxicity studies in Wistar rats



Job Tchoumtchoua<sup>a,b</sup>, Oumarou Riepou Mouchili<sup>a</sup>, Sylvin Benjamin Ateba<sup>a</sup>, Stéphane Zingue<sup>a,c</sup>, Maria Halabalaki<sup>b</sup>, Jean Claude Mbanya<sup>d</sup>, Alexios-Leandros Skaltsounis<sup>b</sup>, Dieudonné Njamèn<sup>a,\*</sup>

<sup>a</sup> Laboratory of Animal Physiology, Department of Animal Biology and Physiology, Faculty of Science, University of Yaounde I, P.O. Box 812, Yaounde, Cameroon

<sup>b</sup> Division of Pharmacognosy and Natural Products Chemistry, Faculty of Pharmacy, University of Athens, Panepistimioupoli Zografou, 15771, Athens, Greece

<sup>c</sup> Laboratory of Physiology, Department of Life and Earth Sciences, Higher Teachers' Training College, University of Maroua, P.O. Box 55 Maroua, Cameroon

<sup>d</sup> Department of Internal Medicine and Specialties, Faculty of Medicine and Biomedical Sciences, University of Yaounde I, PO Box 8046, Yaounde, Cameroon

### ARTICLE INFO

#### Article history:

Received 26 August 2014

Received in revised form

26 September 2014

Accepted 3 October 2014

Available online 16 October 2014

### ABSTRACT

*Amphimas pterocarpoides* Harms (Leguminosae) is widely used traditionally in Central and West Africa for the treatment of various ailments. However, no data regarding its safety have been published until now. Thus, the present study aimed to investigate the potential toxicity of the methanol extract of the stem bark of *Amphimas pterocarpoides* (AP) in Wistar rats following the OECD guidelines. In acute oral toxicity, female rats received a single dose of 2000 mg/kg of AP and were observed for 14 days. In subchronic toxicity, doses of 150, 300, 600 mg/kg/day of AP were given *per os* to rats (males and females) for 28 days. No death and abnormal behaviors were observed in acute toxicity and the LD<sub>50</sub> was estimated higher than 5000 mg/kg. In the subchronic study, AP induced no significant variation in body weight and relative weight of organs, whereas a delayed decrease of white blood cell count and granulocytes was observed. Inconsistent increase of the total cholesterol/high density lipoprotein was observed at 600 mg/kg in males. Such variation (not dose dependent) and without biological relevance indicate a wide margin of safety for the traditional use of AP.

© 2014 Published by Elsevier Ireland Ltd. This is an open access article under the CC BY-NC-ND license (<http://creativecommons.org/licenses/by-nc-nd/3.0/>).

### 1. Introduction

Medicinal plants remain the most used form of treatment in most African villages. According to the World Health Organization, about 80% of the world

population, especially in developing countries, rely on traditional medicine for their primary health care [1]. Besides the deficiency and the elevated cost of modern medicine [2], the easy accessibility of herbal medicines and the belief that they are safe and harmless since they are natural and have been used for thousands of years account for this gained popularity of traditional medicine and encourage the public toward self-medication [3,4]. Though several plants possess interesting pharmacological activities, the

\* Corresponding author. Tel.: +237 79 42 47 10.  
E-mail address: [dnjamen@gmail.com](mailto:dnjamen@gmail.com) (D. Njamèn).

valorization of these medicinal plants is very often limited due to the lack of written records about their safety or toxicity [5]. Therefore, the acute and subchronic toxicological studies of *Amphimas pterocarpoides* were carried out.

*Amphimas pterocarpoides* Harms (Leguminosae) is a sub-Saharan tree known by regional names such as bokanga, edjip, edzui, lati or yaya, and is distributed in Central and West Africa. Various preparations of root and stem bark of this plant are used in traditional medicine to treat dysentery, anemia, hematuria, dysmenorrhoea, impotence, and to prevent spontaneous abortion [6,7]. In previous studies, hydro-alcoholic and aqueous extracts of the bark of *Amphimas pterocarpoides* displayed antioxidant and antianemia activities *in vitro* and *in vivo*, respectively [8,9]. Moreover, four isoflavonoids namely amphisoiflavone, isoformononetin, 8-methoxyisoformononetin, and 6-methoxyisoformononetin with antioxidant and antimicrobial activities were isolated from the dichloromethane–methanol (50:50 v/v) extract of the root bark of *Amphimas pterocarpoides* [10]. In our previous report, we isolated 11 potential estrogenic isoflavonoids from a methanol extract of the stem bark of this plant [11]. Our ongoing investigation showed osteoprotective properties of this extract at the dose of 150 mg/kg BW in adult ovariectomized Wistar rats. Despite the wide application of this plant in the folkloric medical practice and its methodical published activities, no reports on toxicity and safety profile are yet available. Therefore, this study has been designed aiming to evaluate the acute and subchronic oral toxicity of the methanol extract of the stem bark of *Amphimas pterocarpoides* in Wistar rats.

## 2. Material and methods

### 2.1. Plant material and extraction

The stem bark of *Amphimas pterocarpoides* were collected at Mount Eloumdem, in the suburbs of Yaounde, Center Region of Cameroon, on August 10th 2013 (8:00–9:00 am). The plant was identified and authenticated by Mr. Victor Nana, a botanist at the Cameroon National Herbarium where a voucher specimen is deposited under the reference number 52563/HNC. After the drying and pulverization process, 3 kg of the powder was extracted with 10 L of methanol of analytical grade (Merk, Darmstadt, Germany) for a total duration of 1 week. The filtration and renewal of methanol occurred every 2 days. The collected solution was concentrated under reduced pressure at 40 °C and lyophilized to produce 60 g of extract (2% yield) called AP. The extract was kept at 2–8 °C and dissolved in distilled water prior to administration. The administered volume was 2 mL per 100 g BW.

As reported in our previous study, 20 isoflavonoids and 1 flavonoid were identified in the methanol extract of the stem bark of *Amphimas pterocarpoides* using a UHPLC-LTQ Orbitrap system, and 11 representative isoflavonoids were further isolated and structurally identified using 1 and 2D NMR techniques [11].

### 2.2. Animals

Young Wistar rats, aged 8–10 weeks (acute toxicity) and 5–6 weeks (subchronic study) obtained from the animal house of the Laboratory of Animal Physiology of the University of Yaounde I, Cameroon, were used. They were maintained in standard conditions of temperature (at around 25 °C), with approximately 12 h light/dark natural illumination cycle and a relative humidity of 45–55%. They had free access to standard rat chow and tap water *ad libitum*. The guidelines of the Institutional Ethic Committee of the Cameroon Ministry of Scientific Research and Technological Innovation, which has adopted the guidelines established by the European Union on Animal Care (CEE Council 86/609) were followed for all procedures.

### 2.3. Acute toxicity

The acute oral toxicity test was performed using the acute toxicity class method (ATC) in accordance with the Organization for Economic Cooperation and Development (OECD) guideline 423 adopted on December 17th, 2001 [12]. Based on a survey of tests done using the conventional LD<sub>50</sub> that pointed out that female rats are generally more sensitive [13,14] and according to the OECD recommendation, female rats were used for this experiment. Six healthy rats were allocated in two groups of 3 animals each. The first group (Control) received distilled water by gavage whereas the second group received a single dose of 2000 mg/kg BW of AP. Prior to administration, animals were weighted, marked, and fasted overnight without suppression of water. After dosing, food was withheld for a further 3–4 h while animals were observed individually during the first 30 min and then 2, 4, 6 h after treatment. Thereafter, observations were made once daily (5–10 min) for a total period of 14 days and the animals were weighed every 4 days. The experiment was repeated with the same dose and same number of animals according to the OECD flow charts [12]. The observation focused on mortality, changes in general behavior, skin, eyes, fur, and somatomotor activity. Attention was directed to observations of tremors, convulsions, salivation, diarrhea, lethargy, sleep, and coma. At the end of the 14th day, animals were sacrificed by decapitation under light anaesthesia (10 mg/kg BW diazepam and 50 mg/kg BW ketamine i.p.) and liver, lungs, kidneys, heart, stomach, spleen, and adrenals were removed, weighed and immediately observed for gross pathological changes (gross necropsy).

### 2.4. Subchronic toxicity

The repeated dose 28-day oral toxicity was carried out according to OECD guideline 407, adopted on October 3rd, 2008 [15]. Sixty Wistar rats were distributed in 6 groups of 10 animals each (5 females and 5 males). Animals were segregated according to their gender to avoid any chance of mating. After a 7-day adaptation, the animals were treated as follows: The first group received distilled water (Control); groups 2–4 received the AP extract at the doses of 150, 300, and 600 mg/kg BW,

respectively; Groups 5–6 served as satellite in the control (Control SAT) and the top dose (600 SAT) groups, respectively. Animals were treated daily (12:00–13:00) by gavage for 28 days and observed once daily. The satellite groups were followed-up for 14 days after the end of the treatment for observation of reversibility, or persistence, or delayed occurrence of toxic effects. The observation focused on mortality, changes in general behavior, skin, eyes, fur, and somatomotor activity. Attention was directed to observations of tremors, convulsions, salivation, diarrhea, lethargy, sleep, and coma. Animals were weighed every 4 days during treatment and posttreatment periods. Twenty-four hours after the last administration (for groups 1–4) and after the posttreatment follow-up (satellite groups), animals were sacrificed by decapitation under light anaesthesia (10 mg/kg BW diazepam and 50 mg/kg BW ketamine i.p.) after a 10–12 h overnight fast. Blood samples were collected for hematological and biochemical parameters analyses. The portion used for hematological analyses was collected in EDTA-coated tubes and the remainder in dry tubes. The heart, liver, kidneys, stomach, spleen, adrenals, and lungs were dissected, weighed, and immediately observed for gross pathological changes (gross necropsy). Thereafter, liver, kidneys, and lungs were fixed for 4 days in 10% formaldehyde for histological analysis.

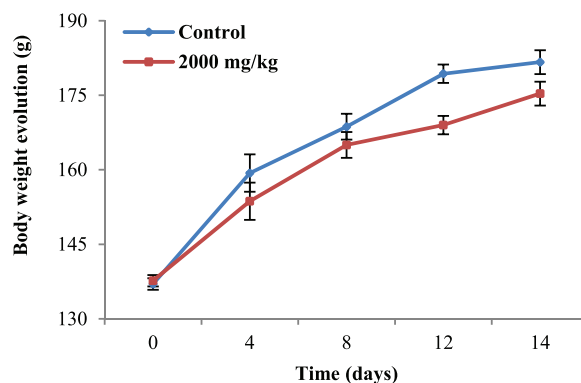
### 2.5. Measurement of hematological and biochemical parameters

Blood samples in dry tubes were centrifuged at 3500 g (15 min at 4°C) and the supernatant (serum) was collected and introduced into new tubes. Triglycerides (TG), total cholesterol (TC), high density lipoprotein (HDL-C), alanine transaminase (ALT), and aspartate transaminase (AST) were measured using reagent kits from Fortress Diagnostics Limited (Muckamore, United Kingdom) whereas the total bilirubin (TB) concentration was determined using reagent kits from Cypress Diagnostics (Langdorp, Belgium). Total proteins (TP) were measured using the Biuret reagent.

For hematological analysis, white blood cell (WBC) count, lymphocytes, monocytes, granulocytes, red blood cell (RBC) count, hematocrit, hemoglobin, mean corpuscular volume (MCV), mean corpuscular hemoglobin (MCH), mean corpuscular hemoglobin concentration (MCHC), and platelets count were evaluated using a HumaCount<sup>30</sup>TS Automated Hematology Analyzer from Human Diagnostics Worldwide (Wiesbaden, Germany).

### 2.6. Histopathological examination of the liver and the kidney

Liver, lung, and kidneys were dehydrated by a series of ethanol solution and embedded in paraffin blocks before cutting into 5 µm sections. These sections were stained with hematoxylin and eosin (HE) and examined under an Axioskop 40 microscope connected to a computer where the image was transferred using MRGrab1.0 and Axio Vision 3.1 softwares (Zeiss, Hallbermoos, Germany).



**Fig. 1.** Body weight evolution of rats treated orally with the methanol extract of the stem bark of *Amphimas pterocarpoides* at the single dose of 2000 mg/kg BW. Each point represents the mean  $\pm$  SEM ( $n=6$ ). No significant difference.

### 2.7. Statistical analysis

Data are expressed as mean  $\pm$  standard error of the mean (SEM). Comparison and analysis were performed using the two way nonparametric Mann–Whitney *U* test using GraphPat InStat 3.05 statistical software. The results were considered to be significant at values  $p < 0.05$ .

## 3. Results

### 3.1. Acute toxicity

The single oral dose of AP at 2000 mg/kg BW, even after the repetition of the experiment did not cause mortality, changes in general behavior or any clinical signs of toxicity. In addition, between group significant differences were not observed with respect to body weight profile (Fig. 1), relative weight (Table 1), and gross pathological examinations of the selected organs. According to the OECD flow chart recommendations, the LD<sub>50</sub> was estimated greater than 5000 mg/kg.

### 3.2. Subchronic toxicity

#### 3.2.1. Observations

Throughout the experiment, no mortality or treatment-related signs of toxicity were recorded.

**Table 1**  
Relative weight of organs (mg/kg BW) in the control and AP-treated (2000 mg/kg BW) groups.

Organs	Control	2000 mg/kg
Heart	3595 $\pm$ 79.0	3564 $\pm$ 107
Liver	34130 $\pm$ 126	31056 $\pm$ 976
Stomach	8473 $\pm$ 769	8068 $\pm$ 233
Lungs	6343 $\pm$ 40.0	6351 $\pm$ 739
Spleen	2790 $\pm$ 262	2949 $\pm$ 314
Adrenals	483 $\pm$ 32.0	395 $\pm$ 43.0
Kidneys	6862 $\pm$ 74.0	6849 $\pm$ 495

Data are represented as mean  $\pm$  SEM ( $n=6$ ). No significant difference.

**Table 2**Relative organ weights after a 28-day treatment with the methanol extract of stem bark of *Amphimas pterocarpoides* in male Wistar rats.

Organs	Control	<i>A. pterocarpoides</i> (mg/kg BW)			Satellite groups	
		150	300	600	Control SAT	600 SAT
Liver	37820 ± 1870	36542 ± 1932	37418 ± 2057	37340 ± 1870	40944 ± 5610	34287 ± 383
Stomach	9497 ± 624	9526 ± 387	10320 ± 634	9815 ± 1004	8728 ± 1116	7920 ± 277
Kidneys	6495 ± 249	6185 ± 225	6895 ± 251	7873 ± 817	6636 ± 881	5993 ± 148
Lungs	7160 ± 842	8053 ± 712	6579 ± 487	7770 ± 969	6975 ± 1115	5096 ± 182
Spleen	4628 ± 718	5375 ± 849	5003 ± 635	6175 ± 1360	2789 ± 393	2897 ± 256
Heart	3511 ± 105	3588 ± 217	4034 ± 231	3772 ± 343	3472 ± 469	3245 ± 62
Adrenals	264 ± 23	217 ± 15	235 ± 29	254 ± 52	382 ± 73	346 ± 25

Data are represented as mean ± SEM (n = 5). Control SAT: satellite control treated with vehicle; 600 SAT: satellite of top dose treated with the extract at 600 mg/kg BW. No significant difference.

### 3.2.2. Body and organ weights

Compared to the control groups, no significant differences were observed in the body weight evolution (Fig. 2) or relative organ weights (Tables 2 and 3) at all the tested doses after the 28-day treatment and the 14-day posttreatment observation.

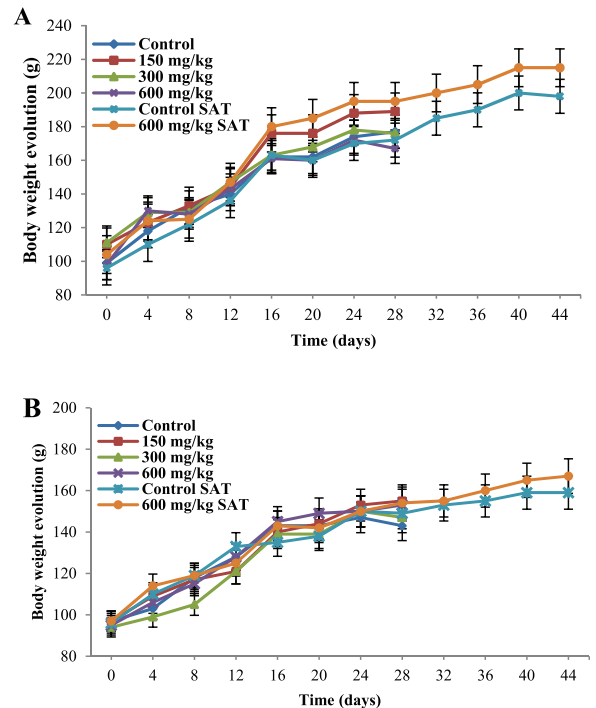
### 3.2.3. Hematological parameters

Table 4 shows that the 28-day oral administration of AP (once daily) induced a significant increase ( $p < 0.01$ ) of platelets in males at the dose of 600 mg/kg. In addition, a significant and delayed decrease ( $p < 0.01$ ) of white blood cell count (WBC), monocytes, granulocytes, and platelets as well as a significant increase ( $p < 0.01$ ) of lymphocytes were noted in males after the 14-day posttreatment follow-up.

In females, significant increases ( $p < 0.05$ ) of RBC (at 150 and 600 mg/kg), along with hematocrit and hemoglobin (at 600 mg/kg) were observed. Moreover, significant increases ( $p < 0.01$ ) of platelets were noted at the doses of 300 and 600 mg/kg after the 28-day treatment, whereas significant and delayed decreases of WBC ( $p < 0.05$ ), granulocytes, and platelets ( $p < 0.01$ ) were observed after a 14-day posttreatment (Table 5).

### 3.2.4. Biochemical parameters

Table 6 shows a significant decrease ( $p < 0.01$ ) of HDL-C levels at all tested doses and a significant increase ( $p < 0.01$ ) of total bilirubin (TB) at 600 mg/kg in males. No significant variations were observed in TG and TC levels. On the other hand, significant increases ( $p < 0.05$ ) of the TC/HDL-C ratio was observed at 150 mg/kg. Compared



**Fig. 2.** Body weight evolution of male (A) and female (B) rats during a 28-day treatment with the methanol extract of the stem bark of *Amphimas pterocarpoides* at 150, 300, and 600 mg/kg BW (n = 5). Each point represents the mean ± SEM. Control SAT: satellite control treated with vehicle; 600 mg/kg SAT: satellite of top dose treated with 600 mg/kg of extract. No significant difference.

**Table 3**Relative organ weights after a 28-day treatment with the methanol extract of stem bark of *Amphimas pterocarpoides* in female Wistar rats.

Organs	Control	<i>A. pterocarpoides</i> (mg/kg BW)			Satellite groups	
		150	300	600	Control SAT	600 SAT
Liver	32243 ± 1577	34944 ± 1105	36330 ± 2318	32457 ± 726	31156 ± 1188	34523 ± 1177
Stomach	9417 ± 520	8335 ± 217	9141 ± 226	9001 ± 327	8172 ± 324	9915 ± 215
Kidneys	6651 ± 141	6676 ± 186	6374 ± 312	6663 ± 93	6231 ± 93	6213 ± 120
Lungs	8665 ± 983	8438 ± 575	7635 ± 616	8374 ± 1166	7262 ± 309	7489 ± 682
Spleen	5121 ± 680	3427 ± 624	3799 ± 631	3100 ± 396	3076 ± 103	4059 ± 173
Heart	3845 ± 158	4180 ± 149	3816 ± 201	3812 ± 201	3916 ± 191	3725 ± 179
Adrenals	386 ± 19	543 ± 83	438 ± 100	383 ± 33	406 ± 37	545 ± 21

Data are represented as mean ± SEM (n = 5). Control SAT: satellite control treated with vehicle; 600 SAT: satellite of top dose treated with the extract at 600 mg/kg BW. No significant difference.

**Table 4**  
Hematological parameters after a 28-day treatment with the methanol extract of stem bark of *Amphimas pterocarpoides* in male Wistar rats.

Parameters	Historical ranges	Control	<i>A. pterocarpoides</i> (mg/kg BW)			Satellite groups	
			150	300	600	Control SAT	600 SAT
WBC ( $\times 10^3 \mu\text{L}^{-1}$ )	5–16	15.58 $\pm$ 2.65	14.84 $\pm$ 2.18	15.96 $\pm$ 2.23	17.32 $\pm$ 4.78	13.38 $\pm$ 1.92	3.55 $\pm$ 0.35**
Lymphocytes (%)	65–85	68.58 $\pm$ 2.27	68.04 $\pm$ 2.85	64.30 $\pm$ 2.23	70.18 $\pm$ 1.42	76.78 $\pm$ 1.19	89.33 $\pm$ 1.26**
Monocytes (%)	0–20	19.66 $\pm$ 1.12	18.60 $\pm$ 1.18	20.96 $\pm$ 1.36	16.28 $\pm$ 1.27	14.10 $\pm$ 1.70	8.40 $\pm$ 0.45**
Granulocytes (%)	0–27	11.78 $\pm$ 1.33	13.38 $\pm$ 1.55	14.74 $\pm$ 1.46	13.54 $\pm$ 1.53	11.60 $\pm$ 0.76	2.48 $\pm$ 0.53**
RBC ( $\times 10^3 \mu\text{L}^{-1}$ )	5–10	7.30 $\pm$ 0.31	6.71 $\pm$ 0.88	7.53 $\pm$ 0.30	7.65 $\pm$ 1.21	7.00 $\pm$ 0.48	5.47 $\pm$ 0.48
Hematocrit (%)	32–53	38.94 $\pm$ 1.26	35.66 $\pm$ 3.55	38.92 $\pm$ 1.33	39.82 $\pm$ 6.08	36.70 $\pm$ 4.46	27.03 $\pm$ 2.34
MCV (fL)	52–59	53.40 $\pm$ 0.81	54.80 $\pm$ 2.85	51.60 $\pm$ 0.81	52.20 $\pm$ 1.32	57.25 $\pm$ 3.95	49.80 $\pm$ 0.48
Platelets ( $\times 10^3 \mu\text{L}^{-1}$ )	200–1100	317.60 $\pm$ 23.26	266.80 $\pm$ 17.50	328.40 $\pm$ 15.07	419.60 $\pm$ 22.75**	271.00 $\pm$ 24.46	72.67 $\pm$ 4.06**
MCH (pg)	17–27	18.88 $\pm$ 0.27	21.12 $\pm$ 2.86	18.18 $\pm$ 0.40	17.74 $\pm$ 0.61	24.02 $\pm$ 2.23	19.13 $\pm$ 0.18
Hemoglobin (g/dL)	12–18	13.76 $\pm$ 0.48	13.16 $\pm$ 0.61	13.68 $\pm$ 0.48	13.68 $\pm$ 2.46	12.62 $\pm$ 1.49	10.40 $\pm$ 0.83
MCHC (g/dL)	32–45	35.34 $\pm$ 0.34	38.02 $\pm$ 0.97	35.18 $\pm$ 0.97	34.00 $\pm$ 0.77	41.34 $\pm$ 0.84	38.53 $\pm$ 0.26

WBC: white blood cells; RBC: red blood cells; MCV: mean corpuscular volume; MCH: mean corpuscular hemoglobin; MCHM: mean corpuscular hemoglobin concentration. Control SAT: satellite control treated with vehicle; 600 SAT: satellite of top dose treated with AP at 600 mg/kg BW.

Data are represented as mean  $\pm$  SEM ( $n=5$ ).

\*\* $p < 0.01$  significantly different as compared to control groups.

**Table 5**  
Hematological parameters after a 28-day treatment with the methanol extract of stem bark of *Amphimas pterocarpoides* in female Wistar rats.

Parameters	Historical ranges	Control	<i>A. pterocarpoides</i> (mg/kg BW)			Satellite groups	
			150	300	600	Control SAT	600 SAT
WBC ( $\times 10^3 \mu\text{L}^{-1}$ )	5–16	11.90 $\pm$ 0.42	11.40 $\pm$ 0.49	12.94 $\pm$ 1.78	9.18 $\pm$ 2.35	14.92 $\pm$ 2.71	6.84 $\pm$ 0.82*
Lymphocytes (%)	65–85	75.88 $\pm$ 1.25	70.55 $\pm$ 2.53	72.68 $\pm$ 1.39	73.70 $\pm$ 1.82	79.06 $\pm$ 2.88	82.18 $\pm$ 2.57
Monocytes (%)	0–20	14.23 $\pm$ 0.70	14.98 $\pm$ 1.04	15.52 $\pm$ 0.88	16.46 $\pm$ 1.05	12.92 $\pm$ 0.59	11.80 $\pm$ 1.06
Granulocytes (%)	0–27	11.03 $\pm$ 0.66	16.58 $\pm$ 2.54	11.50 $\pm$ 0.84	9.88 $\pm$ 1.03	12.18 $\pm$ 1.45	6.28 $\pm$ 0.77**
RBC ( $\times 10^3 \mu\text{L}^{-1}$ )	5–10	6.86 $\pm$ 0.33	8.18 $\pm$ 0.37*	7.47 $\pm$ 0.30	8.20 $\pm$ 0.21**	5.51 $\pm$ 0.68	5.74 $\pm$ 0.37
Hematocrit (%)	32–53	37.22 $\pm$ 2.76	38.46 $\pm$ 3.97	40.50 $\pm$ 1.34	45.60 $\pm$ 1.30*	25.76 $\pm$ 3.98	28.16 $\pm$ 1.72
MCV (fL)	52–59	58.00 $\pm$ 1.97	56.80 $\pm$ 4.72	54.40 $\pm$ 108	55.60 $\pm$ 1.20	54.60 $\pm$ 3.88	49.20 $\pm$ 0.20
Platelets ( $\times 10^3 \mu\text{L}^{-1}$ )	200–1100	343.67 $\pm$ 9.39	390.33 $\pm$ 41.00	440.75 $\pm$ 41.02**	488.00 $\pm$ 26.82**	216.00 $\pm$ 82.47	105.00 $\pm$ 3.83**
MCH (pg)	17–27	18.16 $\pm$ 0.26	17.03 $\pm$ 0.43	18.86 $\pm$ 0.49	18.12 $\pm$ 0.28	26.50 $\pm$ 3.26	19.56 $\pm$ 0.25
Hemoglobin (g/dL)	12–18	12.90 $\pm$ 0.45	13.73 $\pm$ 0.80	14.04 $\pm$ 0.48	14.92 $\pm$ 0.32**	7.33 $\pm$ 1.51	11.26 $\pm$ 0.82
MCHC (g/dL)	32–45	32.50 $\pm$ 0.17	33.57 $\pm$ 0.93	34.66 $\pm$ 0.51	32.74 $\pm$ 0.78	45.60 $\pm$ 2.57	39.76 $\pm$ 0.54

WBC: white blood cells; RBC: red blood cells; MCV: mean corpuscular volume; MCH: mean corpuscular hemoglobin; MCHM: mean corpuscular hemoglobin concentration. Control SAT: satellite control treated with vehicle; 600 SAT: satellite of top dose treated with AP at 600 mg/kg BW.

Data are represented as mean  $\pm$  SEM ( $n=5$ ).

\* $p < 0.05$  and \*\* $p < 0.01$  significantly different from control groups.

to the satellite control, the extract at the dose of 600 mg/kg induced a delayed and significant decrease ( $p < 0.01$ ) of total proteins (TP) after a 14-day posttreatment.

In females, all biochemical parameters evaluated were not significantly different (Table 7).

### 3.2.5. Histopathological assessment of the liver, kidney, and lung

Compared to the control groups, histopathological features of the liver and the kidney of male and female Wistar rats showed normal structures after a subchronic (28 days) administration of AP at the doses of 150, 300, and

**Table 6**  
Biochemical parameters after a 28-day treatment with the methanol extract of stem bark of *Amphimas pterocarpoides* in male Wistar rats.

Parameters	Control	<i>A. pterocarpoides</i> (mg/kg BW)			Satellite groups	
		150	300	600	Control SAT	600 SAT
TG (mg/dL)	95.92 $\pm$ 21.39	124.25 $\pm$ 9.14	79.64 $\pm$ 18.85	69.73 $\pm$ 11.98	105.06 $\pm$ 15.80	103.47 $\pm$ 3.91
TC (mg/dL)	76.36 $\pm$ 4.63	73.40 $\pm$ 5.06	74.38 $\pm$ 5.37	79.05 $\pm$ 9.19	77.13 $\pm$ 4.76	83.72 $\pm$ 13.04
HDL-C (mg/dL)	31.86 $\pm$ 2.39	24.78 $\pm$ 0.70**	22.36 $\pm$ 2.03**	21.48 $\pm$ 2.27**	13.92 $\pm$ 0.98	15.21 $\pm$ 1.77
ALT (U/L)	96.56 $\pm$ 6.64	93.23 $\pm$ 2.97	107.24 $\pm$ 4.58	116.96 $\pm$ 4.58	111.20 $\pm$ 4.58	99.16 $\pm$ 4.91
AST (U/L)	105.79 $\pm$ 6.39	106.54 $\pm$ 3.30	108.86 $\pm$ 1.26	115.91 $\pm$ 3.83	111.00 $\pm$ 2.92	108.67 $\pm$ 1.92
TB (mg/dL)	0.2 $\pm$ 0.02	0.19 $\pm$ 0.03	0.22 $\pm$ 0.03	0.45 $\pm$ 0.11**	0.24 $\pm$ 0.02	0.24 $\pm$ 0.02
TP (g/dL)	1.39 $\pm$ 0.04	1.31 $\pm$ 0.02	1.35 $\pm$ 0.05	1.46 $\pm$ 0.07	1.43 $\pm$ 0.10	1.17 $\pm$ 0.02**
TC/HDL-C	2.43 $\pm$ 0.18	2.97 $\pm$ 0.24	3.44 $\pm$ 0.37	3.70 $\pm$ 0.24*	5.64 $\pm$ 0.47	5.45 $\pm$ 0.72

TG: triglycerides; TC: total cholesterol; HDL-C: high density lipoprotein cholesterol; ALT: alanine transaminase; AST: aspartate transaminase; TB: total bilirubin; TP: total protein. Control SAT: satellite control treated with vehicle; 600 SAT: satellite of top dose treated with AP at 600 mg/kg BW.

Data are represented as mean  $\pm$  SEM ( $n=5$ ).

\* $p < 0.05$  and \*\* $p < 0.01$  significantly different compared to control groups.

**Table 7**Biochemical parameters after a 28-day treatment with the methanol extract of stem bark of *Amphimas pterocarpoides* in female Wistar rats.

Parameters	Control	<i>A. pterocarpoides</i> (mg/kg BW)			Satellite groups	
		150	300	600	Control SAT	600 SAT
TG (mg/dL)	68.65 ± 6.69	93.48 ± 4.96	92.96 ± 9.82	84.66 ± 8.72	66.64 ± 3.05	64.54 ± 8.00
TC (mg/dL)	60.87 ± 3.84	61.09 ± 8.91	60.20 ± 7.49	54.01 ± 3.55	63.92 ± 10.71	67.61 ± 12.63
HDL-C (mg/dL)	22.04 ± 1.19	18.80 ± 0.83	22.43 ± 1.37	22.33 ± 0.61	10.33 ± 0.87	10.71 ± 1.69
ALT (U/L)	105.4 ± 1.29	100.13 ± 3.70	104.73 ± 3.13	101.80 ± 2.58	115.72 ± 1.86	106.87 ± 4.04
AST (U/L)	121.2 ± 3.72	129.64 ± 5.71	114.34 ± 4.88	112.99 ± 2.98	108.46 ± 4.36	112.60 ± 3.93
TB (mg/dL)	0.3 ± 0.02	0.3 ± 0.02	0.3 ± 0.02	0.34 ± 0.02	0.26 ± 0.02	0.29 ± 0.03
TP (g/dL)	1.47 ± 0.05	1.52 ± 0.08	1.44 ± 0.05	1.48 ± 0.04	1.29 ± 0.07	1.07 ± 0.07
TC/HDL-C	2.78 ± 0.17	3.24 ± 0.45	2.71 ± 0.34	2.42 ± 0.13	6.71 ± 1.64	7.88 ± 3.01

TG: triglycerides; TC: total cholesterol; HDL-C: high density lipoprotein cholesterol; ALT: alanine transaminase; AST: aspartate transaminase; TB: total bilirubin; TP: total protein. Control SAT: satellite control treated with vehicle; 600 SAT: satellite of top dose treated with AP at 600 mg/kg BW.

Data are represented as mean ± SEM (n = 5).

\* $p < 0.05$  and \*\* $p < 0.01$  significantly different from control groups.

600 mg/kg. In males, a slight overdilatation of air spaces was observed at the dose of 300 mg/kg (Fig. 3).

#### 4. Discussion

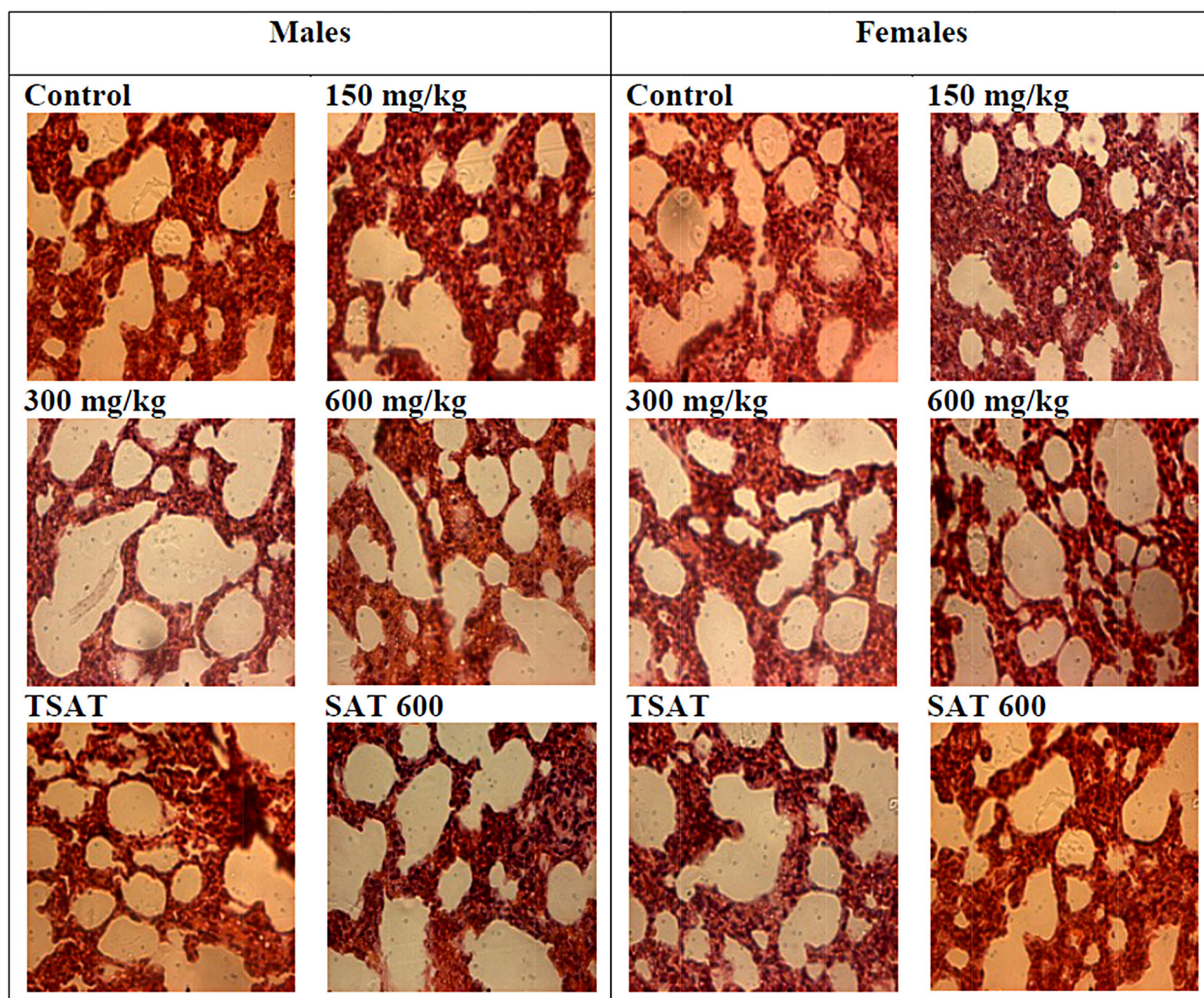
*Amphimas pterocarpoides* is a plant widely used in African traditional medicine for the treatment of various ailments. The present work evaluates the acute and sub-chronic oral toxicity of the methanol extract of stem bark of this plant (AP) in order to determine its safety profile. In the acute toxicity study, neither mortality nor any signs of toxicity were observed in animals after the oral administration of AP at the dose of 2000 mg/kg BW and after a posttreatment period of 14 days. The results remained the same even after the repetition of the experiment and thus, the LD<sub>50</sub> has been estimated greater than 5000 mg/kg. Such substances, according to Kennedy et al. are considered as practically nontoxic and resulted in classifying of AP in hazard category 5 or unclassified in accordance with the Globally Harmonized Classification System for Chemical Substances and Mixtures [12,16,17].

In the 28-day treatment, no significant differences in the relative weight of organs were noted compared to the control groups. Relative organ weight is an indicator of toxic effects of drugs [18], and any significant increase of relative weight of the organs might be due to the hypertrophy and/or hyperplasia. In line with this, our results suggest that at the tested doses, AP did not induce the hypertrophy or hyperplasia in the selected organs. Similarly, the change in body weight may be an important signal of toxicity [19]. No statistically significant difference in body weight of animals was observed suggesting that at the tested doses AP has no effect on animals' growth.

The hematopoietic system is one of the most sensitive targets of xenobiotics [20]. Therefore, it constitutes an important marker of the physiopathological status [21] and provides informations on the vital state of the bone marrow activity and on the intra-vascular effects of xenobiotics [22]. Compared to the control group, significant increases in RBC count (at 150 and 600 mg/kg), hematocrit and hemoglobin (at 600 mg/kg) were noted in females. Although these slight variations were statistically significant, they remained within the normal physiological

ranges [23] and therefore, cannot be considered as toxic effects. These variations are not observed in males, suggesting a higher sensitivity of females to the treatment. Platelets play an important role in hemostasis through the building of a platelet plug. Our results showed a significant increase albeit in the normal physiological limits, of platelet count at 300 mg/kg in females and 600 mg/kg in both sexes. However, satellites groups of both sexes treated with the top dose of extract (600 SAT) showed a significant decrease of platelet count compared to the Control SAT group. These results suggest that AP at the highest tested dose induced a delayed effect either by decreasing platelets production or by reducing the circulating levels of platelets (thrombocytopenia). Likewise, there was a delayed decrease of white blood cells count in both sexes at the dose of 600 mg/kg probably due to the action of AP on hematopoietic cells and/or on circulating white blood cells. On the other hand, delayed decreases in monocytes (in males) and granulocytes (both sexes) as well as a delayed increase in lymphocytes (in males) were observed suggesting that AP acts in opposite way on leucocyte subpopulations and has gender-related effects.

As far as biochemical parameters are concerned, the subchronic administration of AP induced no significant variation of ALT and AST. ALT, specific to hepatocytes and AST, found in liver, cardiac muscle, and kidney [24,25] are well-known as markers of cell damage, especially hepatocyte necrosis [26,27]. Therefore, the non variation of these two parameters indicated the absence of hepatocyte necrosis. Total bilirubin, product of hemoglobin degradation is a marker of hepatobiliary injury [28,29]. In our study, sub-chronic treatment with AP at the dose of 600 mg/kg induced a significant increase of total bilirubin in males. Usually, the increase in serum bilirubin is related to an increase of hemolysis [30], liver injury or cholestasis [31]. Given the lack of any signs of necrosis following the histopathological examinations of the liver, no significant variation of ALT activity and RBC, the increase in total bilirubin observed in males not indicated any sign of toxicity since all values were within physiological ranges. Significant decrease of HDL-C levels were observed in males at all the tested doses while no statistically significant difference was noted in females, suggesting a gender-related effect in which males



**Fig. 3.** Microphotographs of hematoxylin/eosin (400 $\times$ ) stained sections of lungs in subchronic oral treatment with the methanol extract of stem bark of *Amphimas pterocarpoides* at 150, 300, and 600 mg/kg. TSAT: satellite control treated with the vehicle, SAT 600: Satellite of top dose treated with the extract at 600 mg/kg.

were more sensitive. It has long been known that a low HDL-C is a predictor of increased cardiovascular risk. However, over the last decade, it appeared that these lipids' parameters taken individually are not always reliable indicators of the cardiovascular disease [32]. Therefore, the TC/HDL-C ratio is thought to be more predictive for the cardiovascular risks and its increase is correlated positively with the increase of cardiovascular risks. Increase of the TC/HDL-C ratio was only observed at the doses of 600 mg/kg in males. According to our results, the increase of TC/HDL-C appears to be mainly due to decrease of HDL-C observed.

Histopathological examinations of the liver and the kidney of both sexes showed normal integrity of these tissues at all tested doses after a subchronic treatment of AP. However, a slight increase of the volume of pulmonary alveoli was noted in males at the dose of 300 mg/kg. Since there were no signs of lungs injury at the highest dose (600 mg/kg), this slight overdistention of alveoli air spaces

was observed at 300 mg/kg appear to be an artifact or a biological variation with a lack of biological significance.

## 5. Conclusions

In conclusion, the single oral dose of 2000 mg/kg of the methanol extract of the stem bark of *Amphimas pterocarpoides* induced no mortality, no behavior changes, and any treatment-related signs of toxicity. However, in subchronic treatment, AP induced a delayed decrease of white blood cell and platelet count at 600 mg/kg. Therefore, the present investigation demonstrated that the methanol extract of stem bark of *Amphimas pterocarpoides* may be considered as relatively safe of toxicity. As the extract used differs from the traditional preparation (usually decoction), this could account for the inconsistent adverse effects observed. Therefore, further studies with the traditional way of preparation are needed to extrapolate the safety of this plant in human.

## Conflict of Interest

The authors declare that there are no conflicts of interest.

## Transparency document

The [Transparency document](#) associated with this article can be found in the online version.

## Acknowledgements

This work was supported by a grant from the International Foundation of Science (Reference: F/3336-2F) to Dieudonné Njamen.

## References

- [1] WHO, Traditional Medicine Strategy 2014–2023, World Health Organization, Geneva, 2013.
- [2] M. Zhu, K.T. Lew, P.L. Leung, Protective effect of a plant formula on ethanol-induced gastric lesions in rats, *Phytother. Res.* 16 (2002) 276–280.
- [3] C.W. Fennell, M.E. Light, S.G. Sparg, G.I. Stafford, J. Van Staden, Assessing African medicinal plants for efficacy and safety: agricultural and storage practices, *J. Ethnopharmacol.* 95 (2004) 113–121.
- [4] I. Haq, Safety of medicinal plants, *Pak. J. Med. Res.* 43 (2004) 203–210.
- [5] WHO, Traditional Medicine Strategy 2002–2005, World Health Organization, Geneva, 2002.
- [6] T. Jiofack, I. Ayissi, C. Fokunang, N. Guedje, V. Kemeu, Ethnobotany and phytomedicine of the upper Nyong valley forest in Cameroon, *Afr. J. Pharm. Pharm.* 3 (2009) 144–150.
- [7] A.T. Tchinda, P. Tané, *Amphimas pterocarpoides* Harms, in: D. Louppe, A.A. Oteng-Amoako, M. Brink (Eds.), *Plant Resources of Tropical Africa 7(1)*. Timber 1, PROTA Foundation, Wageningen/Backhuys Publishers, Leiden/CTA, Wageningen, 2008, pp. 72–75.
- [8] N.P.C. Biapa, G.A. Agbor, J.E. Oben, J.Y. Ngogang, Phytochemical studies and antioxidant properties of four medicinal plants used in Cameroon, *Afr. J. Tradit. Complement. Altern. Med.* 4 (2007) 495–500.
- [9] N.P.C. Biapa, J.E. Oben, J.Y. Ngogang, Scavenging radical kinetic and antianemic screening properties of some medicinal plants used in Cameroon, *Int. J. Appl. Res. Nat. Prod.* 4 (2011) 29–35.
- [10] E.P.F. Saah, V.T. Sielinou, V. Kuete, S.T. Lacmata, A.E. Nkengfack, Antimicrobial and antioxidant isoflavonoid derivatives from the roots of *Amphimas pterocarpoides*, *Zeitschrift fur Naturforschung* 68 (2013) 931–938.
- [11] J. Tchoumtchoua, D. Njamen, J.C. Mbanya, A.L. Skaltsounis, M. Halabalaki, Structure-oriented UHPLC-LTQ Orbitrap-based approach as a dereplication strategy for the identification of isoflavonoids from *Amphimas pterocarpoides* crude extract, *J. Mass Spectrom.* 48 (2013) 561–575.
- [12] OECD, OECD Guidelines for testing of chemicals, in: *Acute oral toxicity—Acute Toxic Class Method*, OECD, Paris, 2001.
- [13] R.D. Bruce, An up-and-down procedure for acute toxicity testing, *Fundam. Appl. Toxicol.* 5 (1985) 151–157.
- [14] R.L. Lipnick, J.A. Cotruvo, R.N. Hill, R.D. Bruce, K.A. Stitzel, A.P. Walker, I. Chu, M. Goddard, L. Segal, J.A. Springer, R.C. Myers, Comparison of the up-and-down, conventional LD<sub>50</sub>, and fixed-dose acute toxicity procedures, *Food Chem. Toxicol.* 33 (1995) 223–231.
- [15] OECD, Guidelines for testing of chemicals: repeated dose 28-day oral toxicity in rodents, OECD, Paris, 2008.
- [16] G.L. Kennedy, R.L. Ferenz, B.A. Burgess, Estimation of acute oral toxicity in rats by determination of the approximate lethal dose rather than the LD<sub>50</sub>, *J. Appl. Toxicol.* 6 (1986) 145–148.
- [17] OECD, Harmonised Integrated Classification System for Human Health and Environmental Hazards of Chemical Substances and Mixtures, OECD, Paris, 2001.
- [18] Y. Piao, Y. Liu, X. Xie, Change trends of organ weight background data in Sprague Dawley rats at different ages, *J. Toxicol. Pathol.* 26 (2013) 29–34.
- [19] D.P.M. Souza, A.C. Paulino, P.C. Maiorka, S.L. Gorniak, Administration *Senna occidentalis* seeds to adult and juvenile rats: effects on thymus, spleen and in hematological parameters, *J. Pharm. Toxicol.* 5 (2010) 46–54.
- [20] H.A. Harper, *Review of Physiological Chemistry*, Lange Medical Publications, Los Altos, California, 1973.
- [21] A. Diallo, G.K. Eklu, A. Agbonon, K. Aklikokou, E.E. Creppy, M. Gbeassor, Acute and subchronic (28-day) oral toxicity studies of hydro-alcoholic extract of *Lannea kerstingii* Engl. and K. Krause (Anacardiaceae) stem bark, *J. Pharm. Toxicol.* 5 (2010) 343–349.
- [22] G.L. Voigt, Anemia and polychythenias, in: G.L. Voigt (Ed.), *Hematology Techniques and Concepts for Veterinary Technicians*, Iowa State University Press, Iowa, 2000, pp. 95–101.
- [23] M.T. Fallon, Rats and Mice, in: K. Laber-Laird, M.M. Swindle, P. Flecknell (Eds.), *Handbook of Rodent and Rabbit Medicine*, Elsevier Science Ltd., Oxford, 1996, pp. 1–38.
- [24] Y. Han, S. Song, J. Lee, D. Lee, H. Yoon, Multienzyme-modified biosensing surface for the electrochemical analysis of aspartate transaminase and alanine transaminase in human plasma, *Anal. Bioanal. Chem.* 400 (2011) 797–805.
- [25] P. Witthawaskul, A. Panthong, D. Kanjanapothi, T. Taesothikul, N. Lertprasertsuke, Acute and subacute toxicities of the saponin mixture isolated from *Schefflera leucantha* Viguier, *J. Ethnopharmacol.* 89 (2003) 115–121.
- [26] S. Karthikeyan, K. Gobianand, K. Pradeep, C.V. Raj Mohan, M.P. Balasubramanian, Biochemical changes in serum, lung, heart and spleen tissues of mice exposed to subacute toxic inhalation of mosquito repellent mat vapor, *J. Environ. Biol.* 27 (2006) 355–358.
- [27] S.K. Ramaiah, A toxicologist guide to the diagnostic interpretation of hepatic biochemical parameters, *Food Chem. Toxicol.* 45 (2007) 1551–1557.
- [28] H.F. Herlong, Approach to the patient with abnormal liver enzymes, *Hosp. Prac.* 29 (1994) 32–38.
- [29] G.B. McDonald, M.S. Hinds, L.D. Fisher, H.G. Schoch, J.L. Wolford, M. Banaji, B.J. Hardin, H.M. Shulman, R.A. Cliff, Venous-occlusive disease of the liver and multiorgan failure after bone marrow transplantation: a cohort study of 355 patients, *Ann. Intern. Med.* 118 (1993) 255–267.
- [30] O.E. Orisakwe, O.J. Afonne, M.A. Chude, E. Obi, C.E. Dioka, Subchronic toxicity studies of the aqueous extract of *Boerhavia diffusa* leaves, *J. Health Sci.* 49 (2003) 444–447.
- [31] S.I. Bearman, The syndrome of hepatic veno-occlusive disease after marrow transplantation, *Blood* 85 (1995) 3005–3020.
- [32] J.J.P. Kastelein, W.A. van der Steeg, I. Holme, M. Gaffney, N.B. Cater, P. Barter, P. Deedwania, A.G. Olsson, S.M. Boekholdt, D.A. Demicco, M. Szarek, J.C. LaRosa, T.R. Pedersen, S.M. Grundy, Lipids, Apolipoproteins, and their ratios in relation to cardiovascular events with statin treatment, *Circulation* 117 (2008) 3002–3009.