



Original Article

Functional characteristics of left ventricular synchronization via right ventricular outflow-tract pacing detected by two-dimensional strain echocardiography

Yasutaka Hirayama, MD^a, Yuichiro Kawamura, MD, PhD^b, Nobuyuki Sato, MD, PhD^{b,*}, Tatsuya Saito, MD, PhD^c, Hideichi Tanaka, MD, PhD^a, Yasuaki Saijo, MD, PhD^d, Kenjiro Kikuchi, MD, PhD^a, Katsumi Ohori, MD, PhD^c, Naoyuki Hasebe, MD, PhD^b

^a Division of Cardiology, Hokkaido Cardiovascular Hospital, Sapporo, Japan

^b Department of Cardiology, Asahikawa Medical University, Asahikawa Medical University, Midorigaoka Higashi 2-1-1, Asahikawa, 078-8510, Japan

^c Division of Cardiovascular Surgery, Hokkaido Cardiovascular Hospital, Sapporo, Japan

^d Division of Community Medicine and Epidemiology, Department of Health Science, Asahikawa Medical University, Midorigaoka Higashi 2-1-1, Asahikawa, 078-8510, Japan

ARTICLE INFO

Article history:

Received 25 November 2015

Received in revised form

7 April 2016

Accepted 2 May 2016

Available online 24 June 2016

Keywords:

Right ventricular apical pacing
Right ventricular outflow-tract pacing
Right ventricular mid-septal pacing
2D strain echocardiography
Left ventricular synchronization

ABSTRACT

Background: Recently, due to the detrimental effects on the ventricular function associated with right ventricular apical (RVA) pacing, right ventricular septal (RVS) pacing has become the preferred pacing method. However, the term RVS pacing refers to both right ventricular outflow-tract (RVOT) and mid-septal (RVMS) pacing, leading to a misinterpretation of the results of clinical studies. The purpose of this study, therefore, was to elucidate the functional differences of RVA, RVOT, and RVMS pacing in patients with atrioventricular block.

Methods: We compared the QRS duration, global longitudinal strain (GLS), and left ventricular (LV) synchronization parameters at the three pacing sites in 47 patients. The peak systolic strain (PSS) time delay between the earliest and latest segments among the 18 LV segments and standard deviation (SD) of the time to the PSS were also calculated for the 18 LV segments at each pacing site using two-dimensional (2D) strain echocardiography.

Results: RVMS pacing was associated with a significantly shorter QRS duration compared with RVA and RVOT pacing (154.4 ± 21.4 vs 186.5 ± 19.9 and 171.1 ± 21.5 ms, $P < 0.001$). In contrast, RVOT pacing revealed a greater GLS (-14.69 ± 4.92 vs -13.12 ± 4.76 and $-13.51 \pm 4.81\%$, $P < 0.001$), shorter PSS time delay between the earliest and latest segments (236.0 ± 87.9 vs 271.3 ± 102.9 and $281.9 \pm 126.6\%$, $P = 0.007$), and shorter SD of the time to the PSS (70.8 ± 23.8 vs 82.7 ± 30.8 and 81.5 ± 33.7 ms, $P = 0.002$) compared with RVA and RVMS pacing.

Conclusions: These results suggest that the functional characteristics of RVOT pacing may be a more optimal pacing site than RVMS, regardless of the pacing QRS duration, in patients with atrioventricular conduction disorders.

© 2016 Japanese Heart Rhythm Society. Published by Elsevier B.V. This is an open access article under the CC BY-NC-ND license (<http://creativecommons.org/licenses/by-nc-nd/4.0/>).

1. Introduction

The implantation of permanent pacemakers has become an established technique for treating bradyarrhythmias such as atrioventricular block (AVB) over the last several decades. In this procedure, right ventricular apical (RVA) pacing is typically applied to preserve a desirable heart rate. However, several long-term observational studies have shown that RVA pacing may elicit an inappropriate ventricular function [1–5]. To avoid this disadvantage of RVA pacing,

RV septal (RVS) pacing, which is comprised of RV mid-septal (RVMS) [6–9] and outflow-tract (RVOT) pacing [10–13], has been suggested as an alternative ventricular pacing method because it leads to predominantly better cardiac function compared to that with RVA pacing. Most investigations have compared the cardiac function between patient groups with RVA and RVOT or RVMS pacing. However, as the interpretation of the previous clinical studies has been misleading due to the lack of clarity as to which pacing method was employed [14,15], it is unknown which pacing method is superior.

Previously, we compared the differences in the left ventricular (LV) function among the pacing sites in the same individual to avoid the above-mentioned problem [16]. However, an assessment of the LV function, in particular the assessment of the LV

* Corresponding author. Tel.: +81 166 68 2442; fax: +81 166 68 2449.

E-mail address: nsato@asahikawa-med.ac.jp (N. Sato).

synchronization, was not completed. In the present study, we compared the detailed LV synchronization parameters in the RVA, RVOT, and RVMS pacing sites, and clarified the functional characteristics of each site. Our aim was to evaluate the superiority of a pacing site in the same individual prior to permanent pacemaker implantation in patients with AVB.

2. Material and methods

2.1. Study population

The protocol of the present study was approved by the ethical committee of Hokkaido Cardiovascular Hospital. Subsequently, the patients received a full explanation of the study protocol from the investigators, and provided written informed consent. The inclusion and exclusion criteria for the study are shown in Table 1. Patient recruitment began on November 27, 2009 and ended on June 19, 2012. We recruited 47 patients.

2.2. Methods

Temporary pacing leads were applied in all patients prior to the study. In each patient, a temporary atrial pacing lead was positioned in the right atrial appendage (RAA), and a temporary ventricular lead was positioned according to the intended pacing site in the RVA, RVMS, and RVOT sites, in sequence.

2.2.1. Pacing lead positioning procedure

Each ventricular lead placement site was determined by guidance with both 12-lead surface electrocardiography (ECG) and fluoroscopy (Figs. 1 and 2). The RVA lead was positioned in the RV apex. The method of lead positioning for the RVS pacing (RVMS or RVOT) was as follows: the tip of the electrode was advanced into the pulmonary artery through the pulmonary artery valve, withdrawing the electrode carefully until its tip was placed just below the pulmonary valve, and positioned at the RVOT. The RVMS is just below the septoparietal trabeculation and roof of the tricuspid valve [14,15]. Hence, the tip of the electrode was positioned between the RVOT and RVA, facing rightward on the septal wall as viewed from the 50° left anterior oblique fluoroscopy view, thereby distinguishing the septal wall from the RV free wall (Fig. 2). The paced QRS morphology showed a narrower and smaller shape for RVMS pacing and a wider and taller shape for RVOT pacing, especially in the limb leads (Fig. 1).

2.2.2. Pacing procedure

DDD pacing using temporary pacing leads was applied with an identical pacing rate of 20 beats per minute above the sinus rate,

identical pacing output, and identical AV delay time for each ventricular pacing position in each patient. After pacing for five minutes in each pacing position, ECG and echocardiography were performed at each pacing position.

2.2.3. ECG

A 12-lead surface ECG was recorded using a 25 mm/s paper speed with a gain of 10 mm/mV at each pacing position. The paced QRS duration was calculated mainly from leads II, III, and aVF in order to clearly differentiate the QRS features of RVA, RVMS, and RVOT pacing.

2.2.4. Echocardiography

The global longitudinal strain (GLS), the time delay of the peak systolic strain (PSS) between the earliest and latest segments among the 18 LV segments, and standard deviation (SD) of the time to the PSS among the 18 LV segments were calculated using the two-dimensional (2D) longitudinal strain method for each pacing position. All images were obtained using a Vivid E9 echocardiography machine (General Electric Healthcare, Horten, Norway), and all data were stored on an Echopac (General Electric Healthcare) for off-line analysis. The echocardiographer was well trained for raw data analyses, with no bias regarding the pacing position.

2.2.5. Statistical analysis

A one-way repeated measures analysis of variance with post-hoc Bonferroni pairwise comparison was used to compare the means of the QRS, GLS, time delay of the PSS, and SD of the time to the PSS among the RVA, RVMS, and RVOT pacing groups. *P*-values < 0.05 were considered statistically significant. All calculations were conducted using IBM SPSS Statistics 20.0 for Windows software (SPSS Inc., Chicago, IL, USA).

3. Results

3.1. Patient characteristics

Forty-seven consecutive AVB patients (30 with complete AVB and 17 with non-complete AVB) were recruited, with no randomization. The patient characteristics are shown in Table 2. Four patients with a baseline LVEF of < 40% were included; one of the four patients had dilated cardiomyopathy and was undergoing regular hemodialysis.

3.2. QRS analysis on the ECG

RVMS pacing was associated with a significantly shorter QRS duration compared with RVA and RVOT pacing (154.4 ± 21.4 vs 186.5 ± 19.9 and 171.1 ± 21.5 ms, $n=47$, $P < 0.001$), and RVOT pacing was associated with a significantly shorter QRS duration compared with RVA pacing (171.1 ± 21.5 vs 186.5 ± 19.9 ms, $n=47$, $P < 0.001$) (Table 3).

3.3. Echocardiographic analysis

When comparing the GLS at each pacing position, although one of the 47 patients was excluded from the analysis because of insufficient data, RVOT pacing yielded a statistically greater GLS compared with RVMS pacing (-14.69 ± 4.92 vs $-13.51 \pm 4.81\%$, $n=46$, $P=0.015$) and RVA pacing (-14.69 ± 4.92 vs $-13.12 \pm 4.76\%$, $n=46$, $P < 0.001$). On the other hand, no significant difference in the GLS was observed between RVA and RVMS pacing (-13.12 ± 4.76 vs $-13.51 \pm 4.81\%$, $n=46$, $P=0.960$) (Table 3). The 2D longitudinal strain imaging at each pacing position in the individual patients is shown in Fig. 3. The LV wall was divided into 18 segments, each of which showed the individual time to the PSS (Table 4). Fig. 4 shows the average time to the

Table 1

Inclusion and exclusion criteria for the patients in the study.

Inclusion criteria

1. Mobitz II AVB/complete AVB
2. Indication for a permanent pacemaker implantation
3. Age over 20
4. Obtained written informed consent
5. NYHA class I-II

Exclusion criteria

1. Unable to give informed consent
2. Age under 20
3. Atrial fibrillation/atrial flutter
4. Frequent, uncontrolled atrial tachyarrhythmias
5. NYHA class III-IV

AVB, atrioventricular block; NYHA, New York Heart Association.

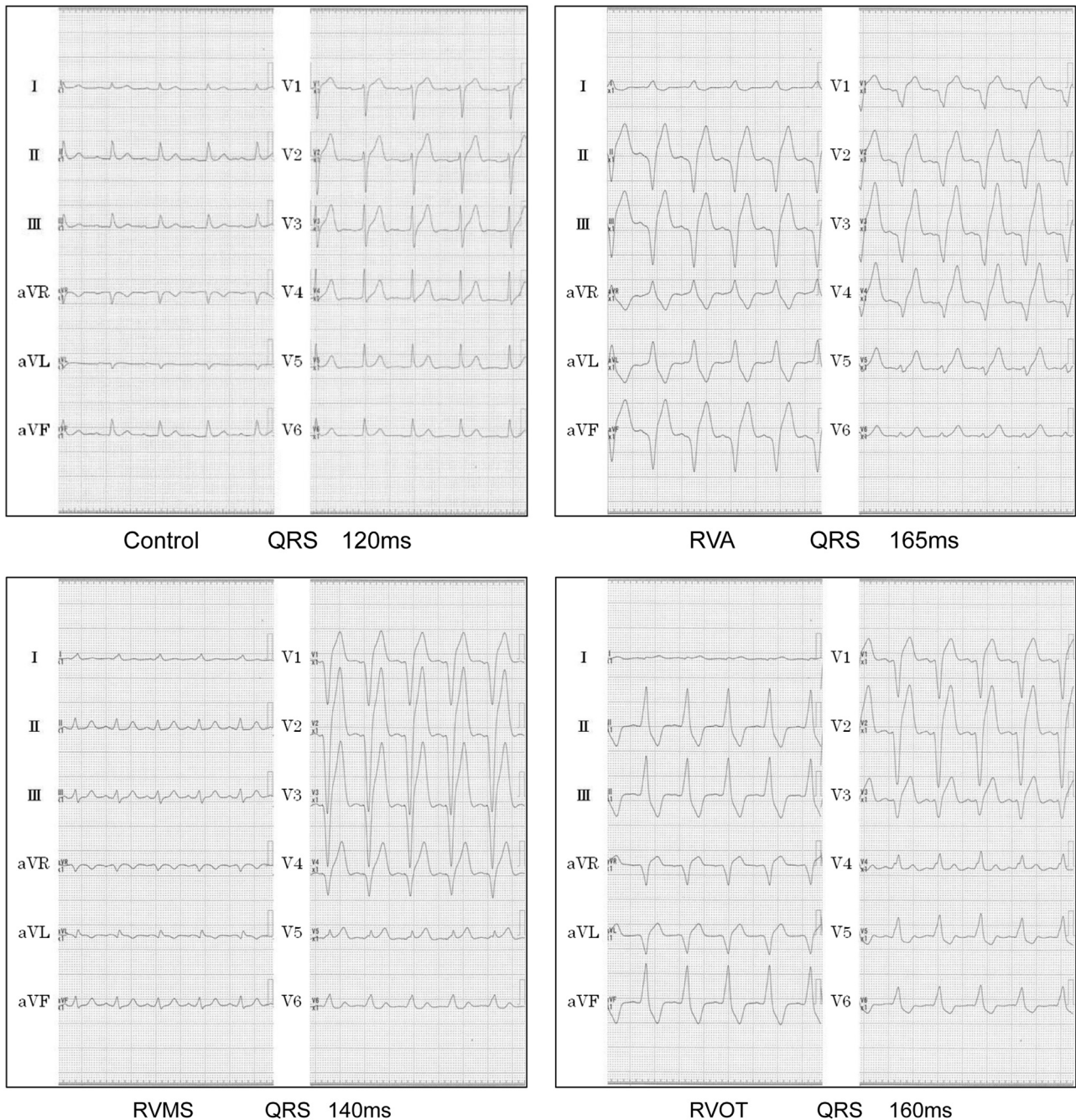


Fig. 1. Typical electrocardiographic appearance at each pacing site. Right ventricular outflow-tract mid-septal (RVMS) pacing (QRS 140 ms) revealed a shorter QRS duration compared with right ventricular apical (QRS 165 ms) and right ventricular outflow-tract pacing (160 ms).

PSS in the 18 segments. These results illustrate the segmental spatial differences and the temporal differences in the PSS and the global changes in the LV synchronization among the RVA, RVMS, and RVOT pacing groups. A quantitative analysis of the time delay of the PSS between the earliest and latest segments or the SD of the time to the PSS in the 18 segments provided differences in the LV synchronization in each pacing site. The time delay of the PSS between the earliest and latest segments was significantly shorter with RVOT pacing than RVMS pacing (236.0 ± 87.9 vs 281.9 ± 126.6 ms, $n=47$, $P=0.005$) and RVA (236.0 ± 87.9 vs 271.3 ± 102.9 ms, $n=47$, $P=0.005$), with no significant difference between RVA and RVMS pacing (271.3 ± 102.9 vs 281.9 ± 126.6 ms, $n=47$, $P=1.000$). The SD of the time to the PSS in the 18 segments was significantly shorter with RVOT pacing compared with RVA and RVMS pacing (70.8 ± 23.8 vs 82.7 ± 30.8 and

81.5 ± 33.7 ms, $n=47$, $P=0.007$), with no significant difference between RVA and RVMS pacing (82.7 ± 30.8 vs 81.5 ± 33.7 ms, $n=47$, $P=1.000$) (Table 3).

4. Discussion

4.1. Main findings

The purpose of our study was to clarify the functional characteristics of RVMS and RVOT pacing in order to achieve optimal RV pacing compared with RVA pacing in terms of better LV function and synchronization. The main findings showed that RVOT pacing exhibited a greater GLS and better LV synchronization parameters than RVA and

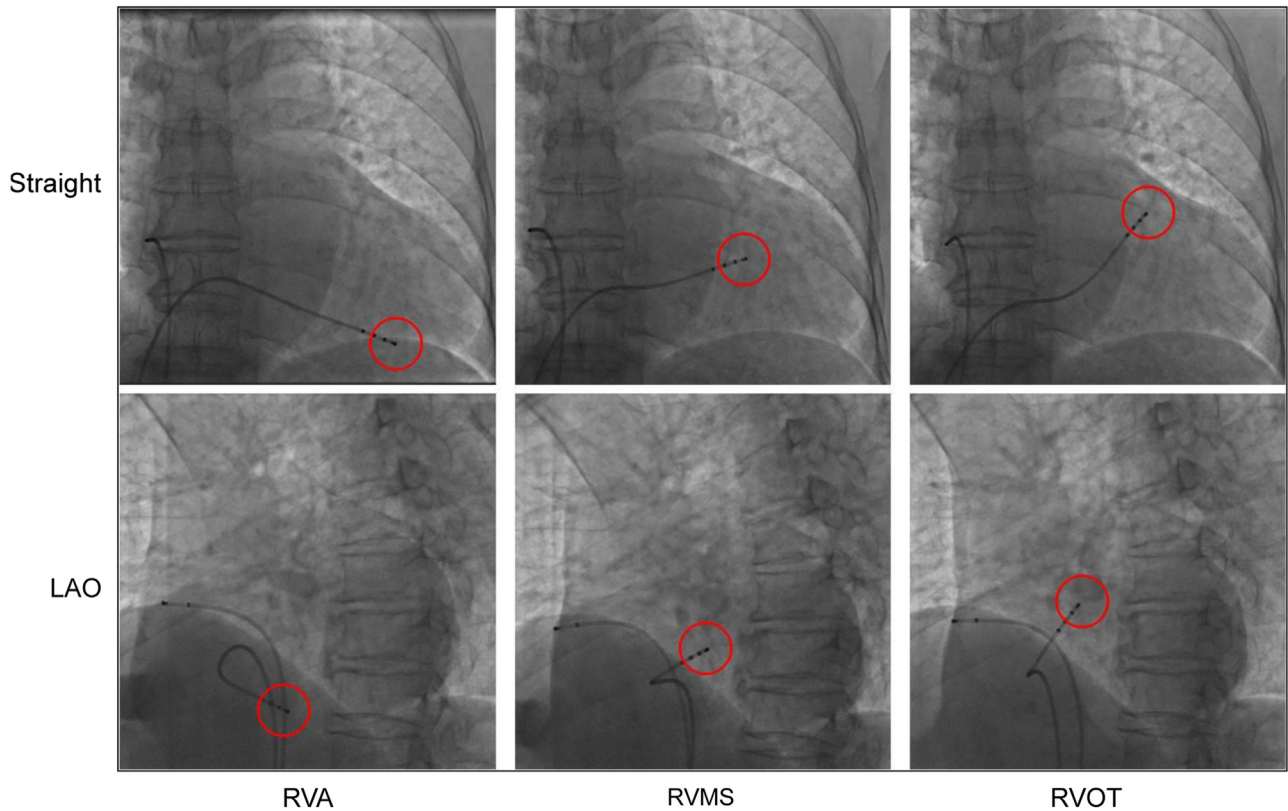


Fig. 2. Fluoroscopic view of each pacing site (red circle). The upper panels show the 0° anterior oblique view. The lower panels show the 50° left anterior oblique view.

Table 2

Patient characteristics (n=47).

Age (years)	77.4 ± 7.8
Male	25 (53.1%)
Complete AVB	30 (63.8%)
Mobitz II AVB	17 (36.2%)
Complications	
Hypertension	27 (57.4%)
Dyslipidemia	11 (23.4%)
Chronic renal failure	11 (23.4%)
Chronic heart failure	10 (21.2%)
Diabetes mellitus	9 (19.1%)
Coronary artery disease	7 (14.8%)
Valvular disease	5 (10.6%)
Cerebral infarction	2 (4.2%)
Dilated cardiomyopathy	1 (2.1%)
Sarcoidosis	1 (2.1%)
Hemodialysis	1 (2.1%)
None	6 (12.7%)
LVEF (%)	61.0 ± 9.9

Values are expressed as mean ± SD or number (%).

AVB, atrioventricular block; LVEF, left ventricular ejection fraction.

Table 3

Changes in the QRS duration, GLS, Peak to peak strain and standard deviation over time to peak systolic strain.

	RVA	RVMS	RVOT	P ⁱ
QRS (ms)	186.5 ± 19.9	154.4 ± 21.4	171.1 ± 21.5	< 0.001 ^a
GLS	-13.12 ± 4.76	-13.51 ± 4.81	-14.69 ± 4.92	< 0.001 ^b
Peak to peak	271.3 ± 102.9	281.9 ± 126.6	236.0 ± 87.9	0.007 ^c
PSS-SD (ms)	82.7 ± 30.8	81.5 ± 33.7	70.8 ± 23.8	0.002 ^d

Values are expressed as mean ± SD.

RVA, right ventricular apical; RVMS, right ventricular mid-septal; RVOT, right ventricular outflow-tract; GLS, global longitudinal strain; Peak to Peak, time delay of peak systolic strain between the earliest and latest segments; PSS-SD, standard deviation over time to peak systolic strain.

^a One-way repeated measure analysis of variance with post-hoc Bonferroni pairwise comparisons

^a RVA vs. RVMS: P<0.001; RVA vs. RVOT: P<0.001; RVMS vs. RVOT: P<0.001.

^b RVA vs. RVMS: P=0.960; RVA vs. RVOT: P<0.001; RVMS vs. RVOT: P=0.015.

^c RVA vs. RVMS: P=1.000; RVA vs. RVOT: P=0.005; RVMS vs. RVOT: P=0.005.

^d RVA vs. RVMS: P=1.000; RVA vs. RVOT: P=0.007; RVMS vs. RVOT: P=0.007.

RVMS pacing. There were intriguing discrepancies between the QRS duration and LV synchronization parameters, namely, the QRS duration was the shortest with RVMS pacing, whereas the LV synchronization parameters were better with RVOT pacing. These RVOT pacing characteristics suggest that RVOT pacing may be an optimal RV pacing site compared with RVMS pacing, regardless of the pacing QRS width.

In general, RVA pacing is thought to cause LV dysfunction due to minimal capture of the normal conduction pathway [17]. In contrast, it is believed that RVS pacing produces a shorter QRS

duration and leads to better LV function due to the maximum capture of the normal electrical pathway. Thus, the beneficial effect of RVS pacing is thought to be a result of the shorter pacing QRS duration [5]. To date, a number of studies on RVMS [6–9] or RVOT [10,12,13] pacing have yielded a shorter pacing QRS duration and revealed better LV function compared with RVA pacing. Hence, RVMS pacing would be expected to achieve a better LV function and synchronization over RVOT pacing through the shorter pacing QRS duration. However, little data are available about the functional differences between RVMS and RVOT pacing. Thus, we attempted to evaluate the differences between RVMS and RVOT pacing based on the following description.

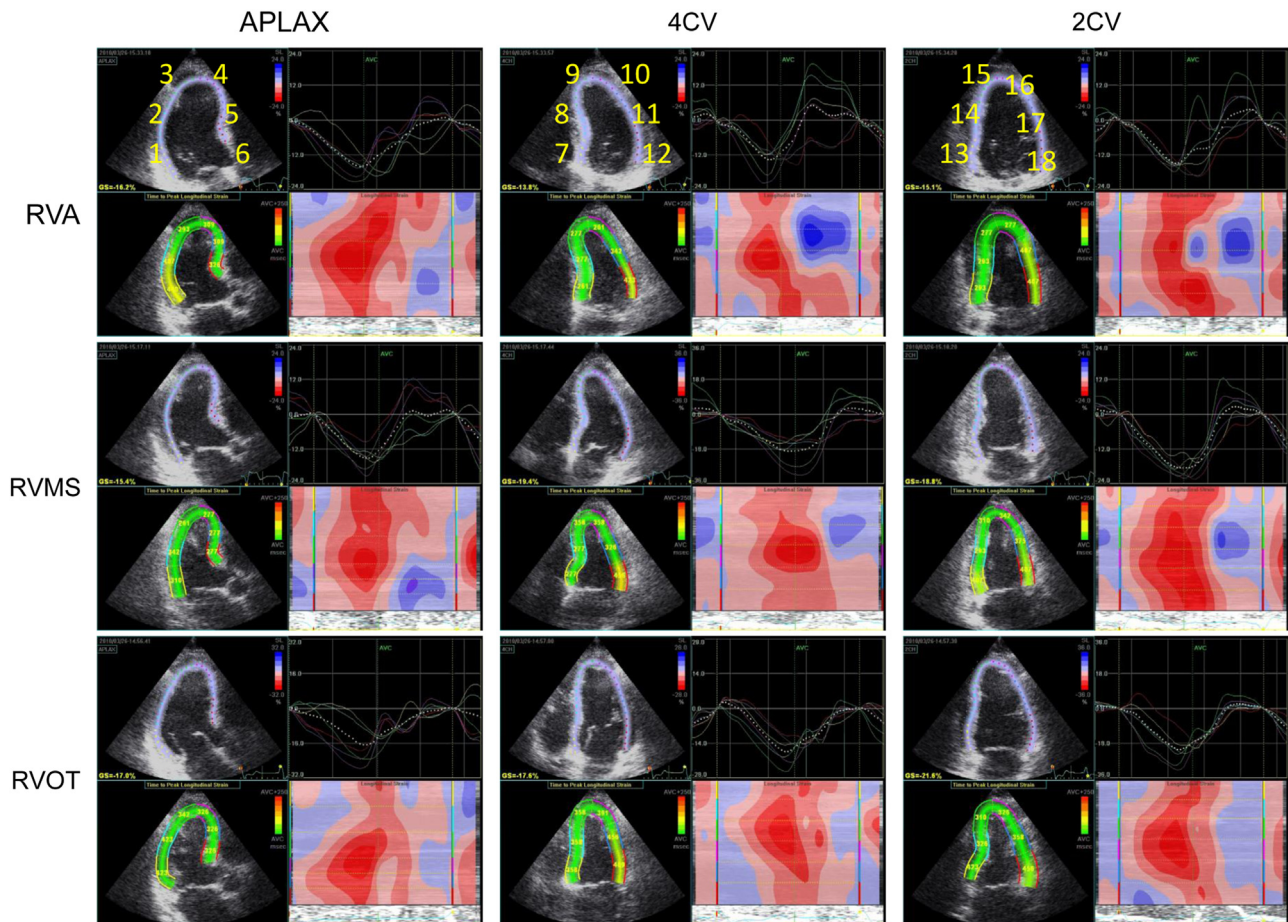


Fig. 3. The 2D longitudinal strain echocardiography in an individual patient. The left ventricular (LV) wall was divided in 18 segments (Nos.1–18), each revealing a longitudinal strain curve and an individual time to peak strain. Using this method, the differences in the LV synchronization could easily be quantified at each pacing site. The upper panels show the right ventricular apical pacing. The middle panels show the right ventricular outflow-tract mid-septal pacing. The lower panels show the right ventricular outflow-tract pacing. APLAX, apical long-axis view; 4CV, four-chamber view; 2CV, two-chamber view.

Table 4

Definition of 18 LV wall segments for quantification of the differences in the LV synchronization at each pacing site.

No.	View	Segment
1	APLAX	Basal-posterior
2	APLAX	Mid-posterior
3	APLAX	Apical-posterior
4	APLAX	Apical-anteroseptal
5	APLAX	Mid-anteroseptal
6	APLAX	Basal-anteroseptal
7	4CV	Basal-septal
8	4CV	Mid-septal
9	4CV	Apical-septal
10	4CV	Apical-lateral
11	4CV	Mid-lateral
12	4CV	Basal-lateral
13	2CV	Basal-inferior
14	2CV	Mid-inferior
15	2CV	Apical-inferior
16	2CV	Apical-anterior
17	2CV	Mid-anterior
18	2CV	Basal-anterior

LV, left ventricular; APLAX, apical long-axis view; 4CV, four-chamber view; 2CV, two-chamber view.

4.2. Technical aspects and comparison with previous studies

First, the anatomical discrimination between the RVMS and RVOT is indispensable for accurate ventricular pacing lead

positioning onto the true RVMS and RVOT. Although one report by Alhous et al. [18] referred to the predominance of RVMS and RVOT pacing compared with RVA pacing in individual patients, the lead position on the RVMS was too close to the RVOT, resulting in similar ECG appearance and LV performance, and thus differentiation between RVMS and RVOT pacing could not be clarified.

On the other hand, in our previous preliminary case report, we clearly indicated the anatomical characteristics for the RVA, RVMS, and RVOT according to the fluoroscopic and ECG guidance in an individual patient [16], as referred to in previous reports by Hillock and Mond. [14,15] We also clarified the fine anatomical differences between the RVMS and RVOT in each patient. This is in contrast with most previous studies, which do not clearly define RVMS and RVOT.

Secondly, the quantification of the temporal difference in each LV segment by means of 2D longitudinal strain imaging would be useful, as in the present study. The 2D strain imaging can distinctly divide the LV wall into 18 segments and provide a superior spatial resolution. Previously, Nahum et al. reported the superiority of the GLS using the 2D longitudinal strain method over the LV ejection fraction (EF) to predict subclinical LV dysfunction and the outcome [19]. Furthermore, Inoue et al. found less dys-synchronization and a better GLS with RVMS pacing compared with RVA [9]. Our case report also visualized better LV synchronization during RVOT pacing compared with RVA and RVMS pacing using 2D longitudinal strain imaging [16]. To confirm the source of the differences in the LV synchronization, measurement of the GLS might be insufficient for comparing the extent of segmental dys-synchronization. Rather, a quantitative evaluation of

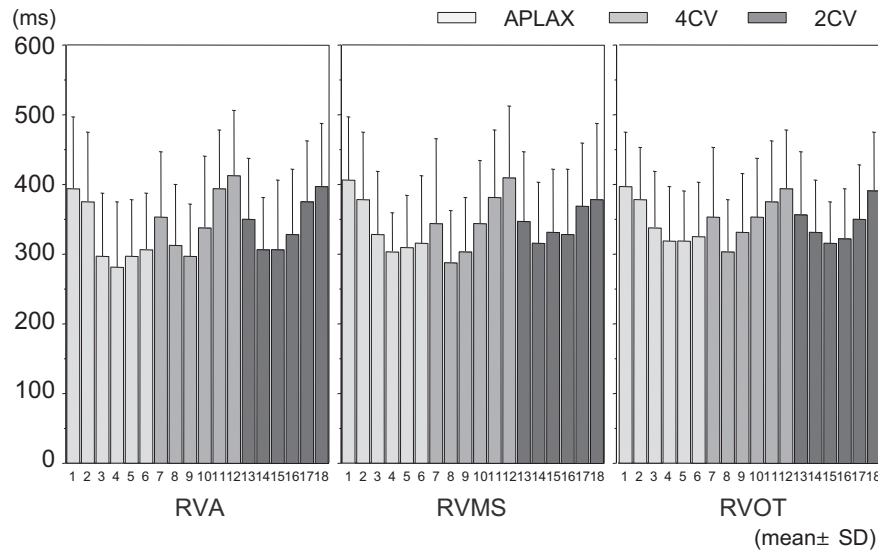


Fig. 4. The average time to peak systolic strain in each of the 18 segments. The temporal delays for the peak systolic strain at the basal-posterior (No. 1), basal-lateral (No. 12), and basal-anterior (No. 18) regions were conspicuous at each pacing site. These segments caused a marked left ventricular dys-synchronization.

the temporal difference in each of the 18 LV segments was considered necessary for a precise analysis among the pacing positions. Hence, we also calculated the time delay of the PSS between the earliest and latest segments and the SD of the time to the PSS among the 18 LV segments using 2D longitudinal strain imaging. With this method, we could easily quantify the segmental time differences from the first peak to the last PSS among the 18 LV segments (Fig. 4). This made it possible for us to clarify the precise functional characteristics of each pacing site and to more specifically predict the optimal pacing position based on the changes in the LV synchronization.

4.3. The possible mechanism of the differences in the LV synchronization

Taking into account the results of these analytical methods, the possible mechanism of the differences in the LV synchronization at each pacing site might be explained by the differences in the LV activation sequence limited by AVB. Recently, Laske et al. reported the differences in the myocardial activation sequences among sinus rhythm, RVMS pacing, and high postero-septal pacing in isolated swine hearts by using the non-contact mapping, EnSite 3000 system [17]. They found a similarity in the activation sequence between sinus rhythm and RVMS pacing, namely, the depolarization wave front that spread down the septal wall and activated the apical region, climbed the lateral wall, and terminated at the high postero-lateral wall. However, the high postero-septal pacing impulse primarily activated the anterior, septal, and lateral wall straight downward low on the lateral wall, which was in contrast with sinus rhythm and RVMS pacing. Laske et al. indicated that RVMS pacing has a greater likelihood of residing within the ventricular myocardium in proximity to the intrinsic conduction system [17]. However, those models might not be applicable in AVB because of the condition preserved atrioventricular electrical conduction pathways.

In patients with AVB, as the conduction of the AV node and His bundle is thought to be nearly completely impaired, the ventricular pacing impulse might be restricted from capturing the normal atrioventricular electrical conduction pathway. In that situation, the pacing impulse triggered by RVA, RVMS, or RVOT pacing might directly activate the adjoining ventricular myocardium, and a depolarization wave front may spread through the proximal myocardium into the Purkinje fiber network in order, and then terminate opposite to each breakout site. As shown in Fig. 4, although the temporal delay in the PSS at the basal-posterior (segment 1), basal-lateral (segment 12), and

basal-anterior (segment 18) regions is particularly marked and common in RVA, RVMS, and RVOT pacing, and facilitates LV dys-synchronization, RVOT pacing is expected to diminish the temporal delay in those segments by tracing the different activation sequences, because the RVOT is relatively close to the basal-posterior, basal-lateral, and basal-anterior regions.

4.4. Possible mechanism for the discrepancy between the SD and QRS duration

One of the most interesting results of our study is the discrepancy between the QRS duration and LV synchronization parameters in RVMS and RVOT pacing. As mentioned above, the QRS duration was the shortest with RVMS pacing, whereas the LV synchronization parameters were considered better with RVOT pacing. The segment of the first peak strain is earlier in the RVMS pacing (segment 8) than the first peak in the RVOT pacing (segment 8) (Fig. 4). Those phenomena explain that RVMS pacing had a shorter QRS duration and could stimulate the septum more rapidly compared with RVOT pacing. On the other hand, the segment of the last peak strain was earlier with the RVOT pacing (segment 1) compared with the last peak of the RVMS pacing (segment 1). In addition, the time to the PSS at the lateral and posterior wall (segments 10, 11, 12, 17, and 18) looked similar between RVMS and RVOT pacing. Those phenomena showed that LV conduction delays exist in RVMS pacing and not in RVOT, and may explain the shortening of the time delay of the PSS between the earliest and latest segments, and the shortening of the SD of the time to the PSS, resulting in the better synchronization parameters of RVOT pacing.

Based on the present study, together with the previous reports [17], it is suggested that the prescriptive factor for clarifying the functional characteristics of RV pacing is not the diminishment of the QRS duration, but rather the pacing site. RVOT pacing might allow preservation of the LV synchronization in the acute phase. In the case of choosing the RVOT for the permanent pacemaker lead implantation site, long-term observation of RVOT pacing might also clarify the usefulness and possibility of preventing complications such as heart failure.

4.5. Limitations

The limitations of our study were that RVA, RVMS, and RVOT pacing were demonstrated temporarily in the acute phase under conditions of almost normal LV function, and the total number of

cases was small. To define the mechanism of RV pacing, a combination of electrophysiological mapping and an ECG analysis at each pacing site is needed. Furthermore, detailed studies that evaluate the chronic phase with a large number of cases under the condition of a low LV function will also be necessary to adequately stratify the patients in order to optimize RV pacing.

In addition, although we also compared the differences in the LVEF as one of the echocardiographic parameters among the RVA, RVMS and RVOT pacing groups, only a 0.6% increase in LVEF was shown in the RVOT pacing group compared with RVMS pacing, which was not considered clinically significant (data not shown). Since the limitations of 2D strain echocardiography for evaluating dys-synchrony and predicting the efficacy of cardiac resynchronization therapy (CRT) have been reported in some clinical trials [20,21], the difference regarding the hemodynamic advantages between RVOT pacing and RVMS pacing might be small. Further large-scale studies will be needed to clarify these points.

5. Conclusions

The present acute phase study clarified the differences in the functional characteristics among RVA, RVMS, and RVOT pacing by 2D strain echocardiography, and RVOT pacing was shown to have a functional superiority over RVMS and RVA pacing. Further investigation and long-term observation will be needed to judge the optimal pacing site for permanent pacemaker implantations.

Conflict of interest

All authors declare no conflict of interest related to this study.

References

- [1] Andersen HR, Nielsen JC, Thomsen PE, et al. Long-term follow-up of patients from a randomized trial of atrial versus ventricular pacing for sick sinus syndrome. *Lancet* 1997;350:1201–16.
- [2] Lamas GA, Orav EJ, Stambler BS, et al. Quality of life and clinical outcomes in elderly patients treated with ventricular pacing as compared with dual-chamber pacing. Pacemaker selection in the elderly investigators. *N Engl J Med* 1998;338:1097–104.
- [3] Wilkoff BL, Cook JR, Epstein AE, et al. Dual Chamber and VVI Implantable Defibrillator Trial Investigators. Dual-chamber pacing or ventricular back up pacing in patients with an implantable defibrillator: the Dual-Chamber and VVI Implantable Defibrillator (DAVID) Trial. *J Am Med Assoc* 2002;288:3115–23.
- [4] Sweeney MO, Hellkamp AS, Ellenbogen KA, et al. Adverse effect of ventricular pacing on heart failure and atrial fibrillation among patients with normal baseline QRS duration in a clinical trial of pacemaker therapy for sinus node dysfunction. *Circulation* 2003;107:2932–7.
- [5] Shukla HH, Hellkamp AS, James EA, et al. Heart failure hospitalization is more common in pacemaker patients with sinus node dysfunction and a prolonged paced QRS duration. *Heart Rhythm* 2005;2:245–51.
- [6] Victor F, Mabo P, Mansour H, et al. A randomized comparison of permanent septal versus apical right ventricular pacing: short-term results. *J Cardiovasc Electrophysiol* 2006;17:238–42.
- [7] Yu CC, Liu YB, Lin MS, et al. Septal pacing preserving better left ventricular mechanical performance and contractile synchronism than apical pacing in patients implanted with an atrioventricular sequential dual chamber pacemaker. *Int J Cardiol* 2007;118:97–106.
- [8] Takemoto Y, Hasebe H, Osaka T, et al. Right ventricular septal pacing preserves long-term left ventricular function via minimizing pacing-induced left ventricular dyssynchrony in patients with normal baseline QRS duration. *Circ J* 2009;73:1829–35.
- [9] Inoue K, Okayama H, Nishimura K, et al. Right ventricular septal pacing preserves global left ventricular longitudinal function in comparison with apical pacing: analysis of speckle tracking echocardiography. *Circ J* 2011;75:1609–15.
- [10] Stambler BS, Ellenbogen K, Zhang X, et al. Right ventricular outflow versus apical pacing in pacemaker patients with congestive heart failure and atrial fibrillation. *J Cardiovasc Electrophysiol* 2003;14:1180–6.
- [11] Dabrowska-Kugacka A, Lewicka-Nowak E, Tybura S, et al. Survival analysis in patients with preserved left ventricular function and standard indications for permanent cardiac pacing randomized to right ventricular apical or septal outflow tract pacing. *Circ J* 2009;73(10):1812–9.
- [12] de Cock CC, Giudici MC, Twisk JW. Comparison of the haemodynamic effects of right ventricular outflow-tract pacing with right ventricular apex pacing: a quantitative review. *Europace* 2003;5:275–8.
- [13] Ishikawa T, Sumita S, Kikuchi M, et al. [Hemodynamic effects of right ventricular outflow pacing.]. *J Cardiol* 1997;30(3):125–30 in Japanese.
- [14] Mond HG. The road to right ventricular septal pacing: techniques and tools. *Pacing Clin Electrophysiol* 2010;33:888–98.
- [15] Hillock RJ, Mond HG. Pacing the right ventricular outflow tract septum: time to embrace the future. *Europace* 2012;14:28–35.
- [16] Hirayama Y, Hotta D, Masuda K, et al. An evaluation of acute phase cardiac wall motion by means of speckle tracking echocardiography among right ventricular apical pacing, mid-septal and outflow tract of right ventricular pacing in an individual patient. *Int Med J* 2010;17(1):63–6.
- [17] Laske TG, Skadsberg ND, Hill AJ, et al. Excitation of the intrinsic conduction system through His and interventricular septal pacing. *Pacing Clin Electrophysiol* 2006;29:397–405.
- [18] Alhous MH, Small GR, Hannah A, et al. Impact of temporary right ventricular pacing from different sites on echocardiographic indices of cardiac function. *Europace* 2011;13:1738–46.
- [19] Nahum J, Bensaid A, Dussault C, et al. Impact of longitudinal myocardial deformation on the prognosis of chronic heart failure patients. *Circ Cardiovasc Imaging* 2010;3:249–56.
- [20] Chung ES, Leon AR, Tavazzi L, et al. Results of the predictors of response to CRT (PROSPECT) trial. *Circulation* 2008;117:2608–16.
- [21] Seo Y, Ito H, Nakatani S, et al. The role of echocardiography in predicting responders to cardiac resynchronization therapy. *Circ J* 2011;75:1156–63.