

Sagittal Alignment After Laminectomy Without Fusion as Treatment for Cervical Spondylotic Myelopathy: Follow-up of Minimum 4 Years Postoperatively

Håkan Löfgren, MD, PhD^{1,2}, Aras Osman, MD^{1,2}, Anders Blomqvist, MD^{1,2}, and Ludek Vavruch, MD, PhD^{1,2}

Global Spine Journal
2020, Vol. 10(4) 425-432
© The Author(s) 2019
Article reuse guidelines:
sagepub.com/journals-permissions
DOI: 10.1177/2192568219858302
journals.sagepub.com/home/gsj



Abstract

Objectives: The aims of this study were to evaluate the incidence of sagittal malalignment including kyphosis following cervical laminectomy without fusion as treatment for cervical spondylotic myelopathy and to assess any correlation between malalignment and clinical outcome.

Study Design: Retrospective cohort study.

Methods: In all, 60 patients were followed up with conventional radiography at an average of 8 years postoperatively. The cervical lordosis (C2-C7 Cobb angle), C2-C7 sagittal vertical axis (cSVA) and C7 slope were measured on both preoperative and postoperative images. Patients completed a questionnaire covering Neck Disability Index (NDI), visual analogue scale for neck pain, and general health (EQ-5D).

Results: Mean C2-C7 Cobb angle was 8.6° (SD 9.0) preoperatively, 3.4° (10.7) postoperatively and 9.6° (14.5) at follow-up. Ultimately, 3 patients showed >20° cervical kyphosis. Mean cSVA was 16.3 mm (SD 10.2) preoperatively, 20.6 mm (11.8) postoperatively, and 31.6 mm (11.8) at follow-up. Mean C7 slope was 20.4° (SD 8.9) preoperatively, 18.4° (9.4) postoperatively, and 32.6° (10.2) at follow-up. The preoperative to follow-up increase in cSVA and C7 slope was statistically significant (both $P < .0001$), but not for cervical lordosis. The preoperative to follow-up change in cSVA correlated moderately with preoperative cSVA ($r = 0.43$, $P = .002$), as did the corresponding findings regarding C7 slope ($r = 0.52$, $P = .0001$). A comparison of radiographic measurements with clinical outcome showed no strong correlations.

Conclusions: No preoperative to follow-up change in cervical lordosis was found in this group; 5.0% developed >20° kyphosis. No clear correlation between sagittal alignment and clinical outcome was shown.

Keywords

laminectomy, lordosis, kyphosis, cervical vertebrae, myelopathy, sagittal alignment, sagittal vertical axis, C7 slope, cervical spondylotic myelopathy, cervical spondylosis

Introduction

Cervical spondylotic myelopathy (CSM) is the most common cause of spinal cord dysfunction in patients older than 55 years.^{1,2} Cervical laminectomy is a well-established surgical treatment option for multilevel CSM,^{3,4} even though the risk of postoperative kyphosis has been a concern since the first reports in the late 1980s,⁵⁻⁷ when Mikawa et al observed 14% and Ishida et al⁷ 24% incidence of kyphosis after laminectomy. A decade later, Guigui et al⁸ reported an incidence of 31% and Matsunaga et al⁹ 34%. Kato et al¹⁰ examined

¹ Neuroorthopedic Center and Department of Radiology, Jönköping, Region Jönköping County, Sweden

² Department of Clinical and Experimental Medicine, Linköping University, Linköping, Sweden

Corresponding Author:

Håkan Löfgren, Neuroorthopedic Center, Ryhov Hospital, SE-551 85 Jönköping, Sweden.
Email: hakan.lofgren@rjl.se



52 patients treated with laminectomy for ossification of the posterior longitudinal ligament (OPLL) and found a 47% incidence of kyphosis. Kaptain et al¹¹ observed that 9 of 42 patients (21%) with either straight or lordotic alignment in the preoperative period developed kyphosis following laminectomy for CSM. Progression of this deformity was more than twice as likely to occur among patients who preoperatively demonstrated a straight spine. These findings are thoroughly discussed in a systematic review by Ryken et al.³ In a more recent study, van Geest et al¹² reported a 15% incidence of kyphosis postoperatively which occurred almost exclusively among patients with preoperative lordosis of less than 20°. However, development of kyphosis following cervical laminectomy has not clearly been shown to influence clinical outcome.^{3,5,8,10-13} Decompression allows dorsal migration of the spinal cord away from anterior compressive osteophytes, decreases compression of the spinal canal itself, and improves vascular perfusion³ in neutral or lordotic cervical spine curves. Cervical kyphosis may impede the posterior drift of the neural structures away from anterior compressive elements, resulting in residual compression of the spinal cord. In addition, sagittal malalignment may have an impact on load bearing involving cervical spine muscles.¹⁴

The aims of this study were to evaluate the incidence of sagittal malalignment following cervical laminectomy without fusion and to assess any correlation between malalignment and clinical outcome.

Methods and Materials

In all, 60 patients who had cervical laminectomy without fusion to treat CSM were followed up an average of 8 years (range 4-13) postop. No patient showed OPLL. We searched our database for patients operated between October 2002 and December 2011. During that period, 37% of patients in our database with a diagnosis of cervical myelopathy were treated with cervical laminectomy without fusion, while 51% had anterior surgery, 10% laminectomy with fusion, 1% laminoplasty, and 1% combined anterior and posterior surgery.

Indications for laminectomy were multilevel stenosis with involvement of at least 3 segments, congenital stenosis, or compression primarily resulting from posterior structures. Contraindications were clear kyphosis ($>5^\circ$) or spondylolisthesis (>2 mm). A mostly straight cervical spine with a Cobb angle of up to 5° of kyphosis was considered acceptable for laminectomy during the inclusion period, for which reason mild kyphosis was treated the same as a straight cervical spine.¹⁵ Under the general policy of our institution as described above, the final choice of surgical method was left to the surgeon. Preoperative standard imaging included both magnetic resonance imaging and conventional radiography with dynamic images.

Eighty-eight patients fulfilled the criteria for the study and were identified from the population register as still alive and not immigrated; a letter was sent inviting them to participate in the study. After providing written consent, 65 of the 88 patients

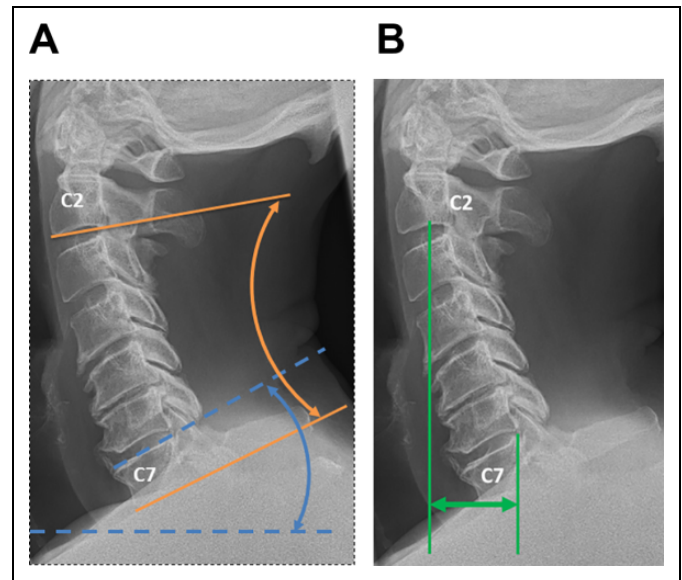


Figure 1. (A) C2-C7 Cobb angle (continuous line). C7 slope, the angle between the horizontal plane and the plane of the superior endplate of the C7 vertebral body (dashed line). (B) C2-C7 sagittal vertical axis (cSVA), the anterior offset of C2 from C7.

were followed-up with conventional radiography and completed a questionnaire covering the Neck Disability Index (NDI),¹⁶ visual analogue scale (VAS) for neck pain, general health (EQ-5D index) and their global assessment of surgical outcome. Data regarding their surgeries was collected from the medical records.

Inclusion criteria for study participation were laminectomy with or without foraminotomy for CSM with or without radiculopathy. Exclusion criteria were other surgical procedures (ie, posterior fusion, anterior surgery, laminoplasty, or combined anterior and posterior surgery), prior cervical spine surgery, or systemic disease with involvement of the cervical spine (eg, rheumatoid arthritis or ankylosing spondylitis).

Five of the 65 patients (8%) were reoperated with fusion of the cervical spine during the follow-up period. These 5 patients have been excluded since the original plan could not be followed, leaving 60 patients without fusion in the presented data.

Average age at surgery was 60 years (SD 9.8, range 37-84 years) and 42 (70%) patients were male. Seven patients were operated with removal of 2 laminae, 21 with 3, 27 with 4, and 5 with removal of 5 laminae. C7 laminectomy was carried out in 18 patients (30%), while no patient had a C2 laminectomy.

The C2-C7 Cobb angle, C2-C7 sagittal vertical axis (cSVA), C7 slope (Figure 1A and B) and T1 slope were all measured on 3 occasions: images taken preoperatively (preop), immediately postoperatively (postop), and at follow-up. Conventional lateral radiographs of patients in seated position were obtained. Postop films were obtained without cervical collar. Measurements of digital images were obtained using Impax software version 6.6.1.5003 2016 (Agfa HealthCare NV, Mortsel, Belgium). All images were measured by the radiologist (AB).

Table 1. Radiologic Measurements.

	Preoperative		P Preoperative vs Postoperative	Postoperative		P Postoperative vs Follow-up	Follow-up		P Preop vs Follow-up
	Mean	SD		Mean	SD		Mean	SD	
Cervical lordosis ^a (deg)	8.6	9.0	<.0001	3.4	10.7	.002	9.6	14.5	ns
cSVA (mm)	16.3	10.2	.02	20.6	11.8	<.0001	31.6	11.8	<.0001
C7 slope (deg)	20.4	8.9	ns	18.4	9.4	<.0001	32.6	10.2	<.0001

Abbreviations: cSVA, C2-C7 sagittal vertical axis; ns, nonsignificant ($P > .05$).

^aCervical lordosis was measured by C2-C7 Cobb angle.

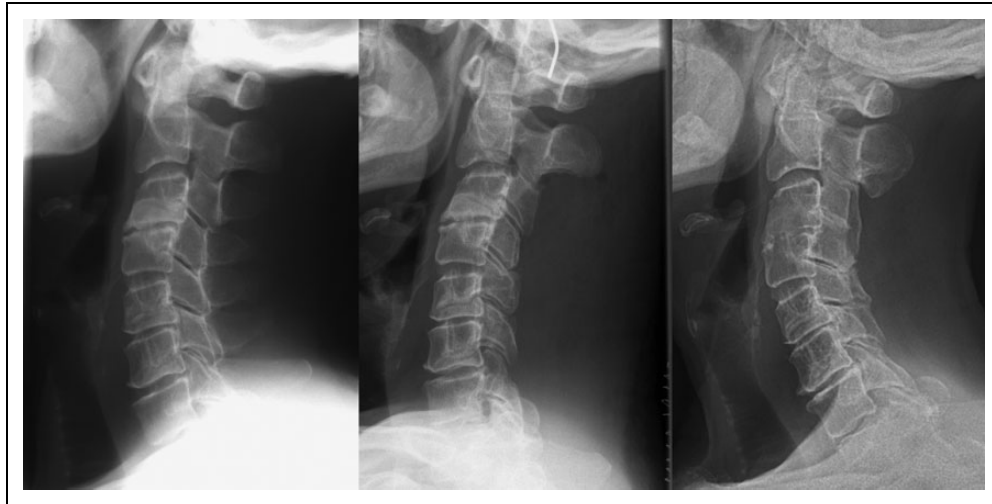

Figure 2. Images preoperative (left), postoperative (center), and at follow-up 11 years postoperatively (right) from the same patient, displaying changes typical of those seen in our study during follow-up. Reduced lordosis postoperatively but regained at follow-up. Increased cSVA and C7 slope at follow-up. The patient had mild neck pain at follow-up and rated the neck pain as improved compared with preoperatively. She was satisfied with the overall outcome.

In the majority of the cases the second measurement was made by author AO, who had not treated any of the patients, while the remaining measurements were made by the first author (HL). If the difference between the 2 measurements was greater than 3° or 3 mm, new measurements were taken until agreement within that interval was reached. The average of the final 2 measurements was then used for further calculations.

Since the T1 slope was impossible to measure on 22% of the images, compared with 2.3% for the C7 slope, and because it has been shown¹⁷ that the C7 slope represents the same properties, although the measurements may not yield identical numbers, we only present the data for the C7 slope and use them in the analyses.

Statistics

We used the paired t test to compare preoperative radiologic measurements with follow-up measurements and the t test to analyze the radiologic measurements for dichotomized clinical data such as gender and whether or not C7 was included in the laminectomy. The Pearson correlation coefficient was used to analyze both the change in radiologic measurements in relation to the initial measurements and also the nondichotomized clinical data. The Spearman correlation coefficient was used to correlate

radiologic measurements with VAS scores for neck pain, NDI and EQ-5D. The SAS/GLM procedure was used to compare radiologic measurements with patient global assessment.

The significance level was set at $P < .05$. The data analysis in this article was generated using SAS/STAT software, Version 9.4 of the SAS System for Windows.

Results

Mean C2-C7 Cobb angle was 8.6° (SD 9.0) preoperatively, 3.4° (10.7) postoperatively, and 9.6° (14.5) at follow-up. There was a statistically significant difference between preop and postop images ($P < .0001$), but not between preop and follow-up. Ultimately, 3 patients showed $>20^\circ$ kyphosis. The preoperative to follow-up increase in cSVA, and C7 slope was statistically significant (all P s $< .0001$). All radiologic measurements are presented in Table 1. Figure 2 shows images from a patient with changes typical of those seen in our study during follow-up.

None of the preoperative measurements correlated with the change in cervical lordosis. The preoperative cSVA and C7 slope correlated moderately with the change in cSVA from preoperative to follow-up, as did the preoperative C7 slope with the change in C7 slope. All correlation data is presented in Table 2.

Table 2. Correlations Between Radiologic Measurements.^a

	Cervical Lordosis Preoperatively	cSVA Preoperatively	C7 Slope Preoperatively	Cervical Lordosis Follow-up	cSVA Follow-up	C7 Slope Follow-up	Difference Cervical Lordosis	Difference cSVA	Difference C7 Slope
Cervical lordosis Preoperatively	—	ns	0.40 (.006)	0.59 (<.0001)	ns	0.45 (.002)	ns	ns	ns
cSVA preoperatively	—	—	0.65 (<.0001)	ns	0.41 (.004)	ns	ns	0.43 (.002)	ns
C7 slope preoperatively	—	—	—	0.38 (.0009)	ns	0.53 (<.0001)	ns	0.52 (.0001)	0.36 (.02)
Cervical lordosis follow-up				—	ns	0.64 (<.0001)			
cSVA follow-up				—	—	0.30 (.03)			

Abbreviations: cSVA, C2-C7 sagittal vertical axis; ns, nonsignificant ($P > .05$).

^aCorrelation coefficients (r) comparing radiologic measurements preoperatively, at follow-up, and with the change from preoperative to follow-up. P values within parentheses.

A comparison of clinical outcomes with radiographic measurements at follow-up showed low to moderate negative correlations of follow-up C7 slope with neck pain (VAS) ($r = -0.28$, $P = .048$) and with neck disability (NDI) ($r = -0.30$, $P = .03$). No statistically significant correlation was found between either cervical lordosis or cSVA at follow-up and neck pain (VAS), neck disability (NDI), general health (EQ-5D index), or the patient's general assessment of clinical outcome.

No statistically significant findings were seen when comparing change in radiologic measurements between preoperative and follow-up images in relation to clinical data such as gender, age at surgery, and length of time until follow-up. Nor were there any statistically significant findings when comparing changes between preoperative and follow-up in radiographic measurements in relation to number of laminae removed and whether or not C7 was included in the laminectomy. Regarding change in C7 slope, the difference in outcome related to whether or not C7 laminectomy was included in the procedure was of borderline statistical significance, with a 95% confidence interval (CI), including the null value (-11.3 to 0.1), but with $P = .056$. Regarding patients in whom C7 laminectomy was included, C7 slope increased an average of 16.4° (SD 9.2) by follow-up, compared with 10.8° (SD 9.2) among laminectomy patients without C7 involvement.

This study focuses on radiographic outcome, yet the overall clinical outcome for the 3 patients with $>20^\circ$ kyphosis at follow-up is of interest and therefore presented: a 56-year-old male at time of surgery with 35° kyphosis at follow-up rated his overall satisfaction with the surgical outcome as "satisfied" (scale: satisfied/uncertain/dissatisfied). He rated the change in neck pain as "significantly improved" (scale: completely disappeared/significantly improved/somewhat improved/unchanged/worse). A 61-year-old female with 37° kyphosis rated her overall satisfaction as "uncertain." She had no neck pain. A third patient, a 53-year-old male with 21° kyphosis, was dissatisfied with the outcome. He scored the neck pain as unchanged. These responses are in line with the 3-month postop visit, where improvement was noted by the first 2

patients, but not the third. In all, 1 of these 3 patients rated the outcome as satisfactory. All had straight cervical spines without lordosis on preoperative imaging and their surgical procedures involved between 2 and 4 levels with duration of follow-up ranging from 76 to 98 months.

Five of the 65 patients (8%) were reoperated with fusion of the cervical spine during the follow-up period. One patient developed progression of myelopathy due to disc herniation of the most caudal decompressed segment C6/7. Anterior cervical decompression and fusion (ACDF) was performed 2 months postlaminectomy, thereby restoring the patient's ability to walk. One patient developed C1-C2 instability with myelopathy 5 years post C3-C6 laminectomy. Posterior fusion from occiput to C3 achieved good clinical results. Another 3 patients were operated with ACDF due to residual radiculopathy, but with no clear reduction of radicular symptoms. These 5 patients were excluded since the original plan to treat without fusion could not be followed. However, the results are very similar when including these patients.

Dropouts

Twenty-three patients declined follow-up. Average age was 66 years (SD 10), compared with 60 years (SD 10) for the study population ($P = .02$); 61% were male, compared with 70% among the study population ($P = 0.4$). Medical records, including our radiologic database, were checked for information concerning reoperation or severe disease progression. One of the 23 patients had additional cervical spine surgery with ACDF due to persistent arm pain 10 months postlaminectomy, but with no clear improvement of symptoms.

Discussion

Radiologic Measurements

Our preoperative radiologic measurements are consistent with those in earlier studies among patients with CSM,¹⁵ those with neck pain with or without radiculopathy¹⁴ and among

asymptomatic individuals.¹⁶⁻¹⁹ For cervical lordosis, a statistically significant difference was found between preoperative and postoperative images, but not between preoperative and follow-up, while concerning cSVA and C7 slope, a difference was seen between preoperative and follow-up images. Normal aging might have influenced the changes, since average follow-up time was 8 years. Cervical lordosis increased with age in normal populations as shown in several studies,¹⁸⁻²² though Oe et al²³ found an increase only among women. Moreover, cervical lordosis may be considered to be a spinal segment adaptation related to global alignment in order to maintain horizontal gaze,²⁴ which compensates for the increase in thoracic kyphosis observed with increasing age.^{20,22,23,25} Our study found no correlation between the duration of the follow-up period and changes in any of the radiologic measurements. However, unaltered cervical lordosis at follow-up in our study may be due to a combination of factors, such as neutralization of normal aging-related lordosis and postoperative changes. We interpret the initial reduced lordosis seen in the postoperative images, that is, straightening of the cervical spine, to result from postoperative neck pain combined with the detachment of the extensor muscles required by the posterior approach.

Both cSVA and C7 slope increased during the follow-up period in our study, which we attribute to the influence of normal aging. Earlier studies have shown an increase in cSVA with age^{18,19,22,23}; C7 slope²⁰ also increases with age, as does T1 slope,^{18,19,22,23} all of which are consistent with the increase in thoracic kyphosis seen with age.^{20,22,23,25} However, the magnitude of the increase varies between the studies, as does gender influence and the age interval during which the changes are most pronounced. Studies of elderly Asian populations²⁰⁻²³ present data from large subgroups. Data from 2 large studies for each parameter are presented in Table 3 together with data from our study. Large studies of C7 slope are rare (presented only by Yeh et al²⁰), but data on T1 slope is more readily available and useful for comparison. In summary, the increase in our study is more pronounced than might be expected at follow-up compared with the studies presented above; there is, however, considerable variation among these studies. Similar studies of individuals with spondylosis would have been valuable for comparison to elucidate the extent to which increases in cSVA and C7 slope found in our study can be attributed to aging versus to surgical procedure. Tamai et al¹⁷ have demonstrated good agreement between T1 and C7 slope, which is in line with our unpublished data from this study. We found C7 slope impossible to measure on 2% of the images compared with 22% for T1 slope, which makes C7 slope a more useful measurement.

Several studies^{3,5,8-12} report increased kyphosis in 14% to 47% of patients postoperatively, but the frequency of severe kyphosis is rarely reported. van Geest et al¹² found postoperative kyphosis in 10 of 66 patients with preoperative lordosis, including 3 patients with $>10^\circ$ kyphosis. Kyphosis occurred almost exclusively when preoperative lordosis was $<20^\circ$. Our study showed patients with both increased and decreased kyphosis at follow-up and therefore no overall change within

this group. No correlation between any preoperative measurements and changes in lordosis was seen at follow-up. However, 3 of our patients (5%), all of whom had a straight cervical spine preoperatively, ultimately showed $>20^\circ$ kyphosis. This is consistent with the findings of a study by Kaptain et al,¹¹ in which patients with a straight cervical spine preoperatively were at about twice the risk of developing postoperative kyphosis compared with patients with a lordotic spine, 30% and 14% respectively. Kimmell and Maurer²⁶ recommend that "cervical laminectomy should be limited to patients with reasonable lordosis and not utilized in those with a frank kyphosis," while Farrokhi et al¹⁵ suggest a limit of $>10^\circ$ kyphosis, at which point surgical plans should be modified.

In light of these findings, though not clearly shown by our data, it would seem reasonable to consider options other than laminectomy without fusion when preoperative imaging demonstrates a straight cervical spine without lordosis, such as anterior surgery, or posterior decompression with fusion when the kyphotic deformity corrects on extension films.

At follow-up, we found a strong correlation between lordosis and C7 slope and interpret this as an adaptive change in the cervical spine where an increase in lordosis compensates for the increased C7 slope.

Radiologic Measurements Versus Clinical Data

The impact of kyphosis on clinical outcome is a matter of debate.^{1,3,8,10,11} A correlation between local kyphosis and neck pain has been found following anterior fusion for trauma²⁷ and for myelopathy.²⁸ Furthermore, cadaver and animal models have shown that an increase in sagittal malalignment leads to greater cord tension, flattening, and an increase in intramedullary pressure, which results in neurological compromise.²⁴ Biomechanical studies show an increase in load bearing of the muscles in the cervical spine when cSVA or T1 slope are increased.¹⁴

However, no study to date has established a correlation between total cervical lordosis and clinical outcome.^{3,5,8,10-13} Guigui et al⁸ observed that 31% of patients transitioned from a lordotic to a straight or kyphotic spine following laminectomy, with an average change of 14.5° in this patient group, but with no difference in clinical outcome compared with patients who remained lordotic.

We were unable to find any correlation between either cervical lordosis or cSVA and clinical outcome. Low to moderate correlations were found between C7 slope at follow-up and both neck pain (VAS) ($r = -0.28$, $P = .048$) and with neck disability (NDI) ($r = -0.30$, $P = .03$). However, these correlations were negative, which means that increased C7 slope correlates with less neck pain (lower VAS) and less neck disability (lower NDI). The underlying mechanism would be difficult to postulate, and we therefore interpret these findings as likely due to chance alone.

In contrast, in a study of patients following multilevel posterior fusion for cervical stenosis, myelopathy and kyphosis, Tang et al²⁹ observed a correlation between C2-C7 cSVA and neck disability (NDI) and calculated a threshold value of about

Table 3. Sagittal Alignment at Different Ages (>40 Years) From Previous Studies and in the Current Study.^a

Reference	Age-Group (Years)	Cervical Lordosis		Position	Comments
		Males (deg)	Females (deg)		
Yukawa et al, ²⁰ 820 patients 40-79 years	40-49	14 (10)	10 (11)	Standing	
	50-59	18 (13)	16 (12)		
	60-69	18 (12)	17 (11)		
	70-79	21 (12)	19 (11)		
Uehara et al, ²¹ 413 patients in all	50-59	10 (10)	9 (10)	Standing, hands on clavicles	
	60-69	9 (11)	9 (9)		
	70-79	13 (12)	13 (11)		
	80-89	14 (15)	19 (12)		
Current study preoperative 4-13 years postoperative	37-84	9 (9)		Seated	70% males
		10 (15)			
Oe et al, ²² 656 patients in all	50-59	cSVA males (mm)	cSVA females (mm)	Standing, hands on clavicles	Only 36 patients (5%) 50-59 years males + females
	60-69	25 (7)	20 (9)		
	70-79	28 (13)	21 (10)		
	80-89	34 (16)	22 (12)		
Uehara et al, ²¹ 413 patients in all	50-59	23 (14)	18 (11)	Standing, hands on clavicles	
	60-69	28 (15)	16 (8)		
	70-79	29 (12)	17 (11)		
	80-89	31 (17)	19 (16)		
Current study preoperative 4-13 years postoperative	37-84	16 (10)		Seated	70% males
		32 (12)			
Yeh et al, ¹⁷ 278 patients 41-80 years	41-60	C7 Slope Males + Females (deg)		Standing, hands on chest	
	61-80	18 (10)			
		19 (11)			
Our study preoperative 4-13 years postoperative	37-84	20 (9)		Seated	70% males
		33 (10)			
Oe et al, ²² 656 patients in all	50-59	T1 Slope Males (deg)	T1 Slope Females (deg)	Standing, hands on clavicles	Only 36 patients (5%) 50-59 years males + females
	60-69	32 (6)	28 (9)		
	70-79	31 (6)	29 (7)		
	80-89	33 (7)	32 (7)		
Uehara et al, ²¹ 413 patients in all	50-59	25 (6)	23 (7)	Standing, hands on clavicles	
	60-69	27 (8)	22 (7)		
	70-79	29 (9)	25 (10)		
	80-89	31 (10)	30 (14)		

Abbreviation: cSVA, C2-C7 sagittal vertical axis.

^a Values are given as mean (SD). Cervical lordosis = C2-C7 Cobb angle.

40 mm for such a correlation to hold. However, this correlation was weak ($r = 0.20$, $P = .04$), and in our study less than 30% of patients were greater than 40 mm at follow-up.

No correlations were found between the changes in cervical lordosis or cSVA at follow-up and clinical patient data. Regarding change in C7 slope, the difference in outcome related to whether or not C7 laminectomy was included in the procedure was of borderline statistical significance, with a 95% CI including the null value, but with $P = .056$. The number of patients who underwent C7 laminectomy was higher than we had expected but decreased during the study period. We emphasize the importance of avoiding C7 laminectomy because of the substantially higher load on the C7 lamina

compared with those of C3 through C6.³⁰ Including C7 would expose the vulnerable transition zone between the mobile cervical spine and the rigid thoracic spine to the risks of the procedure. We also stress the importance of avoiding detaching the muscles from the C2 spinous process. This approach helps to keep the muscle anchorage as intact as possible. Moreover, we wish to underscore the importance of limiting facetectomy to between 25% and 50%.

Among the 3 patients with $>20^\circ$ kyphosis at follow-up, 1 rated the outcome as "satisfied," 1 as "uncertain," and 1 as "dissatisfied." While it is impossible to draw any concrete conclusions from this small group, the outcome should be viewed in relation to the 55% of all patients in the study who

rated their outcome as “satisfied” and in relation to the 53% of patients in our National Spine Registry who rated their outcome as “satisfied” in response to the same question 1 year after surgery for cervical myelopathy.³¹

Five of the 65 patients (8%) in our study subsequently underwent fusion surgery and were excluded from the study. Considering the relatively large number of patients who required fusion surgery for residual arm pain, we find that this procedure should be considered concurrently in patients who initially present with pronounced radiculopathic pain, since extensive foraminal decompression can be facilitated through fusion, using either the anterior or posterior approach.

Combining laminectomy with fusion in the primary surgery entails a more complicated procedure, likely with higher risk for complications and higher costs. Katonis et al³² studied patients treated with both laminectomy and fusion for the indication CSM and found that reoperation was required in 5.3% of cases due to fusion-related problems such as nerve injury, pseudarthrosis, or screw pull-out. Greiner-Perth et al³³ and Heller et al³⁴ reported a rate of 3% and 3.7%, respectively, of implant-related revisions after posterior instrumentation. Few studies have compared laminectomy with and without fusion, but in a comparison between laminoplasty and laminectomy with fusion, Highsmith et al³⁵ found higher costs associated with fusion, mainly due to the costs of implants.

There are several alternative surgical procedures for posterior decompression. Laminectomy is the traditional method and is still commonly performed³; laminoplasty and laminectomy combined with fusion have long been in widespread use^{2,9} in part because of the reported risk of kyphosis following laminectomy. More recently, new options such as skip laminectomy³⁶ have been introduced because this technique is less invasive, and results have been presented showing that cervical lordosis is maintained at follow-up at least 1 year postop.³⁷

Strengths and Weaknesses

Since our study is retrospective and we lack preoperative clinical data, we are able to compare radiologic measurements with final clinical outcome, but not with the change in clinical data between the preoperative period and follow-up, nor can we compare final clinical outcome with preoperative findings. Preop and postop images were taken with the patients in seated position; consequently, the images taken at follow-up had the patients in the same position. Our study focused on alignment of the cervical spine, without considering the thoracic or lumbar spine. The various segments of the spine do not function independently of each other; for example, cervical lordosis may compensate for thoracic kyphosis.^{19,24}

In summary, our study shows that cervical laminectomy without fusion produces an acceptable radiographic outcome when used on a select group of patients with CSM. Within the group, no differences were found between preoperative images and follow-up images for cervical lordosis, while cSVA and C7 slope did increase. Ultimately, 3 patients (5%) showed >20° kyphosis, all of whom had a straight cervical spine

preoperatively. No clear correlation was found between radiographic measurements and clinical outcome data.

Acknowledgments

Thanks to statistician Mats Nilsson, PhD, at Futurum for statistical analyses and advices.


Declaration of Conflicting Interests

The author(s) declared no potential conflicts of interest with respect to the research, authorship, and/or publication of this article.

Funding

The author(s) disclosed receipt of the following financial support for the research, authorship, and/or publication of this article: The authors acknowledge financial support paid to the Department from Futurum (Academy for Health and Care, Region Jönköping County).

ORCID iD

Håkan Löfgren  <https://orcid.org/0000-0002-5249-5848>

Ethical Approval

The study was approved by the regional ethics committee in Linköping, Sweden (No. 2015/272-31) and was conducted according to the Helsinki declaration.

References

- Karadimas SK, Erwin WM, Ely CG, Dettori JR, Fehlings MG. Pathophysiology and natural history of cervical spondylotic myelopathy. *Spine (Phila Pa 1976)*. 2013;38(22 suppl 1):S21-S36. doi:10.1097/BRS.0b013e3182a7f2c3.
- Klineberg E. Cervical spondylotic myelopathy: a review of the evidence. *Orthop Clin North Am*. 2010;41:193-202. doi:10.1016/j.joc.2009.12.010.
- Ryken TC, Heary RF, Matz PG, et al. Cervical laminectomy for the treatment of cervical degenerative myelopathy. *J Neurosurg Spine*. 2009;11:142-149. doi:10.3171/2009.1.spine08725.
- Wiggins GC, Shaffrey CI. Dorsal surgery for myelopathy and myelofasciopathy. *Neurosurgery*. 2007;60(1 suppl 1):S71-S81. doi:10.1227/01.neu.0000215379.90537.0b.
- Mikawa Y, Shikata J, Yamamuro T. Spinal deformity and instability after multilevel cervical laminectomy. *Spine (Phila Pa 1976)*. 1987;12:6-11.
- Batzdorf U, Batzdorff A. Analysis of cervical spine curvature in patients with cervical spondylosis. *Neurosurgery*. 1988;22:827-836.
- Ishida Y, Suzuki K, Ohmori K, Kikata Y, Hattori Y. Critical analysis of extensive cervical laminectomy. *Neurosurgery*. 1989;24:215-222.
- Guigui P, Benoist M, Deburge A. Spinal deformity and instability after multilevel cervical laminectomy for spondylotic myelopathy. *Spine (Phila Pa 1976)*. 1998;23:440-447.
- Matsunaga S, Sakou T, Nakanishi K. Analysis of the cervical spine alignment following laminoplasty and laminectomy. *Spinal Cord*. 1999;37:20-24.
- Kato Y, Iwasaki M, Fuji T, Yonenobu K, Ochi T. Long-term follow-up results of laminectomy for cervical myelopathy caused

- by ossification of the posterior longitudinal ligament. *J Neurosurg*. 1998;89:217-223. doi:10.3171/jns.1998.89.2.0217.
11. Kaptain GJ, Simmons NE, Replogle RE, Pobereskin L. Incidence and outcome of kyphotic deformity following laminectomy for cervical spondylotic myelopathy. *J Neurosurg*. 2000;93(2 suppl): 199-204.
 12. van Geest S, de Vormer AM, Arts MP, Peul WC, Vleggeert-Lankamp CL. Long-term follow-up of clinical and radiological outcome after cervical laminectomy. *Eur Spine J*. 2015;24(suppl 2):229-235. doi:10.1007/s00586-013-3089-6.
 13. Sielatycki JA, Armaghani S, Silverberg A, McGirt MJ, Devin CJ, O'Neill K. Is more lordosis associated with improved outcomes in cervical laminectomy and fusion when baseline alignment is lordotic? *Spine J*. 2016;16:982-988. doi:10.1016/j.spinee.2016.04.009.
 14. Patwardhan AG, Khayatzaadeh S, Havey RM, et al. Cervical sagittal balance: a biomechanical perspective can help clinical practice. *Eur Spine J*. 2018;27(suppl 1):25-38. doi:10.1007/s00586-017-5367-1.
 15. Farrokhi MR, Ghaffarpasand F, Khani M, Gholami M. An evidence-based stepwise surgical approach to cervical spondylotic myelopathy: a narrative review of the current literature. *World Neurosurg*. 2016;94:97-110. doi:10.1016/j.wneu.2016.06.109.
 16. Vernon H, Mior S. The Neck Disability Index: a study of reliability and validity. *J Manipulative Physiol Ther*. 1991;14: 409-415.
 17. Tamai K, Buser Z, Paholpak P, Sessumpun K, Nakamura H, Wang JC. Can C7 slope substitute the T1 slope? An analysis using cervical radiographs and kinematic MRIs. *Spine (Phila Pa 1976)*. 2018;43:520-525. doi:10.1097/brs.0000000000002371.
 18. Iyer S, Lenke LG, Nemani VM, et al. Variations in occipitocervical and cervicothoracic alignment parameters based on age: a prospective study of asymptomatic volunteers using full-body radiographs. *Spine (Phila Pa 1976)*. 2016;41:1837-1844. doi:10.1097/brs.0000000000001644.
 19. Scheer JK, Tang JA, Smith JS, et al. Cervical spine alignment, sagittal deformity, and clinical implications: a review. *J Neurosurg Spine*. 2013;19:141-159. doi:10.3171/2013.4.spine12838.
 20. Yeh KT, Lee RP, Chen IH, et al. Are there age- and sex-related differences in spinal sagittal alignment and balance among Taiwanese asymptomatic adults? *Clin Orthop Relat Res*. 2018;476: 1010-1017. doi:10.1007/s11999.0000000000000140.
 21. Yukawa Y, Kato F, Suda K, Yamagata M, Ueta T. Age-related changes in osseous anatomy, alignment, and range of motion of the cervical spine. Part I: Radiographic data from over 1200 asymptomatic subjects. *Eur Spine J*. 2012;21:1492-1498. doi: 10.1007/s00586-012-2167-5.
 22. Uehara M, Takahashi J, Ikegami S, et al. Sagittal spinal alignment deviation in the general elderly population: a Japanese cohort survey randomly sampled from a basic resident registry. *Spine J*. 2019;19:349-356. doi:10.1016/j.spinee.2018.06.346.
 23. Oe S, Togawa D, Nakai K, et al. The influence of age and sex on cervical spinal alignment among volunteers aged over 50. *Spine (Phila Pa 1976)*. 2015;40:1487-1494. doi:10.1097/brs.0000000000001071.
 24. Ames CP, Blondel B, Scheer JK, et al. Cervical radiographical alignment: comprehensive assessment techniques and potential importance in cervical myelopathy. *Spine (Phila Pa 1976)*. 2013;38(22 suppl 1):S149-S160. doi:10.1097/BRS.0b013e3182a7f449.
 25. Asai Y, Tsutsui S, Oka H, et al. Sagittal spino-pelvic alignment in adults: the Wakayama Spine study. *PLoS One*. 2017;12: e0178697. doi:10.1371/journal.pone.0178697.
 26. Kimmell KT, Maurer PK. Cervical laminectomy and laminoforaminotomy. In: Steinmetz MP, Benzel EC, eds. *Benzel's Spine Surgery: Techniques, Complication Avoidance, and Management*. 4th ed. Philadelphia, PA: Elsevier; 2017:563-567.
 27. Jenkins LA, Capen DA, Zigler JE, Nelson RW, Nagelberg S. Cervical spine fusions for trauma. A long-term radiographic and clinical evaluation. *Orthop Rev*. 1994;(suppl):13-19.
 28. Kawakami M, Tamaki T, Yoshida M, Hayashi N, Ando M, Yamada H. Axial symptoms and cervical alignments after cervical anterior spinal fusion for patients with cervical myelopathy. *J Spinal Disord*. 1999;12:50-56.
 29. Tang JA, Scheer JK, Smith JS, et al. The impact of standing regional cervical sagittal alignment on outcomes in posterior cervical fusion surgery. *Neurosurgery*. 2015;76(suppl 1):S14-S21. doi:10.1227/01.neu.0000462074.66077.2b.
 30. Pal GP, Routal RV. The role of the vertebral laminae in the stability of the cervical spine. *J Anat*. 1996;188(pt 2): 485-489.
 31. Fritzell P, Hägg O, Gerdhem P, et al. Swespine 2018 annual report—follow up of spine surgery performed in Sweden in 2017. http://www.4s.nu/pdf/180910_Swespine_%20arsrapport_2018_eng_isbn.pdf. Published September 2018. Accessed June 3, 2019.
 32. Katonis P, Papadakis SA, Galanakis S, et al. Lateral mass screw complications: analysis of 1662 screws. *J Spinal Disord Tech*. 2011;24:415-420. doi:10.1097/BSD.0b013e3182024c06.
 33. Greiner-Perth R, Allam Y, El-Saghir H, Röhl F, Franke J, Böhm H. Analysis of reoperations after surgical treatment of degenerative cervical spine disorders: a report on 900 cases. *Cent Eur Neurosurg*. 2009;70:3-8. doi:10.1055/s-0028-1082061.
 34. Heller JG, Silcox DH 3rd, Sutterlin CE 3rd. Complications of posterior cervical plating. *Spine (Phila Pa 1976)*. 1995;20: 2442-2448.
 35. Highsmith JM, Dhall SS, Haid RW Jr, Rodts GE Jr, Mummaneni PV. Treatment of cervical stenotic myelopathy: a cost and outcome comparison of laminoplasty versus laminectomy and lateral mass fusion. *J Neurosurg Spine*. 2011;14:619-625. doi:10.3171/2011.1.spine10206.
 36. Shiraishi T. Skip laminectomy—a new treatment for cervical spondylotic myelopathy, preserving bilateral muscular attachments to the spinous processes: a preliminary report. *Spine J*. 2002;2: 108-115.
 37. Nori S, Shiraishi T, Aoyama R, et al. Muscle-preserving selective laminectomy maintained the compensatory mechanism of cervical lordosis after surgery. *Spine (Phila Pa 1976)*. 2018;43: 542-549. doi:10.1097/brs.0000000000002359