

Autolytic debridement and management of bacterial load with an occlusive hydroactive dressing impregnated with polyhexamethylene biguanide

Stefano Mancini¹, Roberto Cuomo², Mauro Poggialini¹, Carlo D'Aniello², Giuseppe Botta¹

¹Flebology Centre, University of Siena, Italy; ²Unit of Plastic and Reconstructive Surgery, University of Siena, Italy

Summary. *Background:* Debridement and control of bacterial load are key-points of wound care. The aim of this study is to evaluate the effectiveness of autolytic debridement and management of bacterial load (bioburden) of an occlusive hydro-active dressing impregnated with polyhexamethylene biguanide (PHMB). *Methods:* We used an occlusive dressing of hydro-active for leg ulcers' treatment (TenderWet-plus® – Hartmann). Inclusion criteria were: presence of a fibrinous ulcer with multiple etiopathogenesis, in absence of clinical infection, no hypersecretion and diameter within 5 cm. Swab for bacterial bioburden control were made at start of the study, after 3 and 7 days. We made also a measurement of the amount of granulation tissue and of pain with VAS scale; bacterial bioburden control inside the dressing was made too. *Results:* 28 leg ulcers were treated (12 venous, 5 diabetic, 8 traumatic, 3 mixed) in 25 patients. The ulcer has been completely covered with fibrin in almost all cases and the bacterial load was represented mainly by *Staphylococcus aureus* (80% of the cases) with a load within 10.000UFC/plate in 81,5% of the cases. Control at 3 and 7 days have shown the appearance of granulation tissue up to 67,8% of the wound surface. Bacterial bioburden (load) remained constant in 50% of the cases, decreased in 15%, increased in 35% of the cases. *Conclusion:* TenderWet-plus® has proven to be effective and quick in autolytic debridement and at the same time be able to handle the bacterial load in most cases. It can then be used for home treatment. (www.actabiomedica.it)

Key words: autolytic debridement, leg ulcer, advanced dressing; home treatment, skin infection

Introduction

The increase of obesity and aging in population is correlated on an increase of chronic wounds linked to diabetes, foot ulcers, pressure ulcers, vascular (arterial and venous) leg ulcers (1-3).

In USA more than 2% of population suffers from chronic wounds (4). Active venous ulcers are found in about 0.3% of the adult population in the West and the overall prevalence of active and healed ulcers has

been put at 1%, rising to 3% in the over-70 age bracket (5).

One of the most important problems that involve chronic wounds healing is bacteria colonization (5).

The most frequent bacteria that compromise wound healing are *Pseudomonas aeruginosa* (5) and *Staphylococcus aureus*, in particular methicillin-resistant strains (2).

Bacteria colonization contributes to non-healing of the wounds and often these bacteria forms biofilm

(6). So bacterial contamination control is a key-step to promote the healing of chronic wounds (7, 8).

There are many procedures more or less invasive for cleaning and decrease of the bacterial bioburden and knowledge of their characteristics is important for the appropriate choice for any single case (or patient) (Tab. 1).

Surgical debridement is faster and less expensive than other techniques, but needs an adequate anaesthesia, so is not available in home therapy.

Autolytic debridement is a selective and no aggressive method, which produces digestion of necrotic tissue and slough, utilizing endogenous proteolytic enzymes and activated phagocytes (79-11). This is due to the physiological moist wound environment, which exerts its own debriding capacity (4, 6, 7).

In this study we tested the efficacy of an occlusive dressing (TenderWet-plus® - Hartmann) which doesn't need a secondary medication, and its efficacy on bacterial bioburden control for the presence of inside its structure of polyhexamethylene biguanide (PHMB), and its effectiveness in home treatment.

Tenderwet Plus® is an occlusive dressing consisting in a superabsorbent polyacrylate (SAP) integrated into a core of cellulose flake, activated with Ringer solution and impregnated with polyhexamethylene biguanide (PHMB). Ringer's solution made a washing of wound for a maximum of three days. The dressing should be changed maximum every 72 hours.

Materials and methods

Protocol study our Centre included a complete anamnesis and a duplex scan exam for leg ulcer classification.

Inclusion criteria were:

- wounds with necrosis or slough at multiple pathogenesis
- absence of signs of clinical infection
- no hypersecretion
- diameter within 5 cm

All patients signed an informed consent.

Wounds were treated with an occlusive hydroactive dressing whose central component was a super-absorbent (SAP) embedded in cellulose fluff. The antibacterial substance polyhexamethylene biguanide (PHMB) was contained into the SAP and activated with Ringer's solution. The absorbent core was covered with polypropylene knitted fabric on all sides (TenderWet-plus® - Hartmann).

Wound edges were covered with non adhesive gauze or hydrocolloidal plaque for preventing secondary edge maceration, even if Ringer's solution doesn't lead to maceration of vital cells.

At T⁰ we performed swab of the wound fund and edge for bacterial bioburden control, photograph and measure of lesion and granulation tissue quantization (MiMix - Microlab), pain evaluation with Visual Analogical Scale (VAS) and medication.

At T¹, 3 days later, we performed bacterial bioburden control of wound fund and of the dressing too, photograph and measure of lesion and granulation tissue quantization, pain evaluation with Visual Analogical Scale (VAS) and medication.

At T², 7 days after the start, we repeated the same of T⁰.

Bacterial bioburden was classified with a semi-quantitative value in the culture plate (Tab. 2)

In all cases a low pressure monolayer elastic tubular was used.

Table 1. Criteria for choice of debridement method

	Enzymatic	Autolytic	Mechanical	Surgical
Quickness	Good	Poor	Adequate	High
Selectivity	High	Adequate	Poor	Good
Pain	Good	High	Adequate	Poor
Exudate	Poor	Adequate	Good	High
Infection	Adequate	Poor	Good	High
Cost	Good	High	Adequate	Poor

Table 2. Bacterial bioburden classification

Rare colonies	= 1 - 10	UFC/plate
Few colonies	= 10 - 100	UFC/plate
Frequent colonies	= 100 - 1.000	UFC/plate
Numerous colonies	= 1.000 - 10.000	UFC/plate
High colonies	> 100.000	UFC/plate

Results

We treated 28 wounds (12 venous, 5 diabetic, 8 traumatic and 3 mixed) of 25 patients (18 female and 7 male) with mean age 80.16 ± 9.72 d.s. (range 67-91 years).

Wound was completely covered with slough in 89.2% of the cases and more than 90% in the resting 10.8% of the cases.

Control at 3 and 7 days demonstrated that exudates was completely entrapped inside the dressing in 92.8% of the cases. Wound edge was wet, but never present a secondary maceration.

A progressive reduction of slough was recorded with substitution with granulation tissue until 67.8% of wound surface (Tab. 5).

Bacterial flora was principally composed by Gram positive, with *Staphylococcus Aureus* in the 80% of the cases (Tab. 3). Wound surface bioburden concentration was higher than edge in 35% of the cases, the same in 40% of the cases and fewer in 25% of the cases.

Bacterial bioburden >100.000 UFC/plate, considered like a possible critical colonization, was present only in 18.5% of the cases (Tab. 4).

At first control (T¹) TenderWet-plus® kept it unchanged in 70% of the cases at T¹, reduced in 10% of the cases and increased in 20% of the cases. At second control (T²) the bacterial bioburden was reduced in 65% of the cases and increased in 35% of the cases (Tab. 6). In these last cases appeared the characteristic smell in absence of any other direct signs of infection, so we preferred to discontinue this kind of dressing and to introduce a systemic an antibiotic therapy.

Inside the dressing the bacterial bioburden was higher than wound in 60% of the cases, the same in 35% of the cases and lower in 5% of the cases.

Pain was intermittent, higher in the night, with VAS calculated in 4.7 media points (range 3.8-5.5) and practically unchanged at T2 with VAS=4.4 media points.

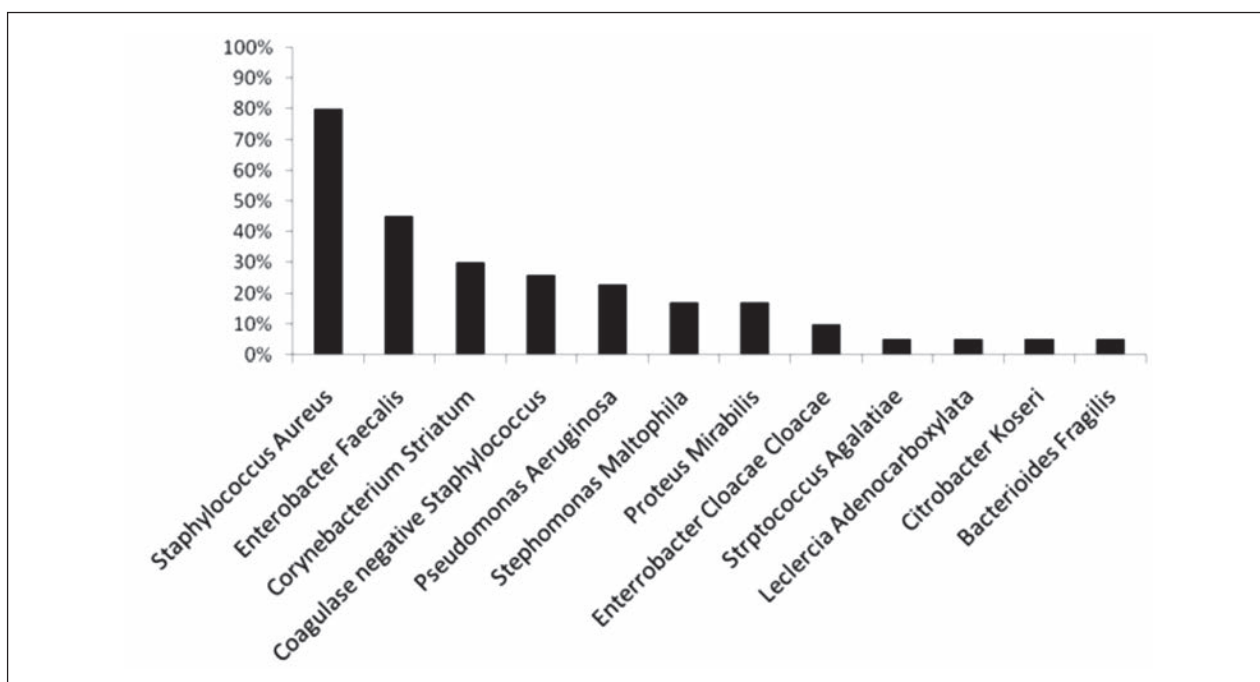
Table 3. Bacterial bioburden distribution

Table 4. Bacterial bioburden

Rare colonies	(= 1 - 10 UFC/piastra)	7.4%
Few colonies	(= 10 - 100 UFC/ piastra)	7.4%
Frequent colonies	(= 100 - 1.000 UFC/ piastra)	29,5%
Numerous colonies	(= 1.000 - 10.000 UFC/ piastra)	37.0%
High colonies	(> 100.000 UFC/ piastra)	18.5%

Table 5. Percentage of granulation tissue at T2

0-20%	-	0 case
21-40%	46.4%	13 cases
41-50%	42.8%	12 cases
51-70%	10.8%	3 cases
>70%	-	0 case

Table 6. Wound bacterial bioburden controls

	T ¹	T ²
Unchanged	70%	
Reduced	10%	65%
Increased	20%	35%

Dressing change was without pain and it was not necessary to add analgesics therapy during the study. There were not cases of allergy and drop-out.

Discussion

Chronic wounds, which presented slough or necrotic tissue, are a favorable environment for microbial growth (12, 13). In these cases the most frequently detected bacteria are *Staphylococcus Aureus* and *Pseudomonas Aeruginosa*. First therapeutic step (T phase of the wound bed preparation - TIMEH) is the debridement, which is the act of removing necrotic material, eschar, devitalized or infected tissue, serous crusts, hyperkeratosis, slough, pus, hematomas, foreign bodies, debris, bone fragment, which also reduces the bacterial bioburden (14-16).

The choice of the appropriate debridement technique depends on many parameters like: type of tissue, type of bioburden that cover the wound bed (13, 17, 18), state of wound edges and skin, exudate and additionally, but not secondary, amount of pain from the procedure, patient's environment, age and choice, skill

and resources of the caregiver, patient's quality of life, regulations and guidelines.

Autolytic debridement is a painless and safe technique, but with slow action, so with high costs, because dressing are usually changed once a day (19). With enzymatic debridement it is the conservative approach preferred in home wound treatment.

Autolytic dressing are hydrogel, paste or granule with needed to be cover by a secondary occlusive dressing for creating the optimal environment to activate macrophages.

It is indicated for acute or chronic wounds with necrotic tissue or fibrin coatings to rehydrate, soften and liquefy hard eschar and slough. It should be use in wounds with moderate or no exudates wounds. It is not indicated in bleeding wounds, fistula, body cavities and highly exudative wounds. Finally it is contraindicated in infected wounds and in those with a high potential for anaerobic infections.

TenderWet-plus[®] is an occlusive dressing which doesn't need secondary dressings. It could be useful utilize non adhesive gauze or hydrocolloid patch for edges defense in particularly delicate skin (E.g. in chronic cortisone therapy case).

This dressing releases Ringer's solution into the wound for up to three days. Interactive and continuous wound irrigation takes place since the TenderWet-plus[®] absorbs wound exudates at the same time.

The PHMB bound in the core of the SAP has an antibacterial effect and inhibits bacterial proliferation inside the wound dressing pad. This reduces the risk of recontamination over the entire period of application of up to three days. Moreover SAP inactivates matrix metalloproteinases (MMP) that impair the wound healing process.

Conclusions

Our experience confirmed that TenderWet-plus[®] could remain until three days without problems, with evident debridement results in few time, demonstrated by the appearance of granulation tissue in about half wound with only two medication in 42,8% of the cases.

Different response depend on fibrin or slough thickness, wound localization and etiology too. In

some cases we continued to use TenderWet-plus® for reaching complete slough removing in maximum three weeks (6 medication).

Dressing change was not painful and safe, suitable for home treatment. However particularly attention to possible starting of wound infection, which not always is accompanied by characteristic Celso's signs like in ancient, diabetic and immunocompromised patients. Smell remains one of the first signal, which indicates an evolution toward a critical colonization or an infection. In these cases is needs selective antibiotic therapy.

Concluded the phase T of the TIME, wound treatment continued with other dressings or with autologous or homologous grafts.

References

- Jockenhofer F, Chapot V, Stoffels-Weindorf M, et al. Bacterial spectrum colonizing chronic leg ulcers: a 10-year comparison from a German wound care center. *Journal der Deutschen Dermatologischen Gesellschaft = Journal of the German Society of Dermatology: JDDG* 2014; 12(12): 1121-7.
- Jockenhofer F, Gollnick H, Herberger K, et al. Bacteriological pathogen spectrum of chronic leg ulcers: Results of a multicenter trial in dermatologic wound care centers differentiated by regions. *Journal der Deutschen Dermatologischen Gesellschaft = Journal of the German Society of Dermatology: JDDG* 2013; 11(11): 1057-63.
- Cuomo R, Sisti A, Grimaldi L, D'Aniello C. Modified Arrow Flap Technique for Nipple Reconstruction. *Breast J* 2016; 22(6): 710-1.
- Gawande PV, Clinton AP, LoVetri K, Yakandawala N, Rumbaugh KP, Madhyastha S. Antibiofilm Efficacy of DispersinB(R) Wound Spray Used in Combination with a Silver Wound Dressing. *Microbiology insights* 2014; 7: 9-13.
- O'Meara S, Cullum N, Majid M, Sheldon T. Systematic reviews of wound care management: (3) antimicrobial agents for chronic wounds; (4) diabetic foot ulceration. *Health technology assessment* 2000; 4(21): 1-237.
- James GA, Swogger E, Wolcott R, et al. Biofilms in chronic wounds. *Wound repair and regeneration: official publication of the Wound Healing Society [and] the European Tissue Repair Society* 2008; 16(1): 37-44.
- Gottrup F. A specialized wound-healing center concept: importance of a multidisciplinary department structure and surgical treatment facilities in the treatment of chronic wounds. *American journal of surgery* 2004; 187(5A): 38S-43S.
- D'Aniello C, Cuomo R, Grimaldi L, et al. Superior Pedicle Mammoplasty without Parenchymal incisions after Massive Weight Loss. *J Invest Surg* 2016: 1-11.
- Cuomo R, D'Aniello C, Grimaldi L, et al. EMLA and Lidocaine Spray: A Comparison for Surgical Debridement in Venous Leg Ulcers. *Advances in wound care* 2015; 4(6): 358-61.
- Korber A, Schmid EN, Buer J, Klode J, Schadendorf D, Dissemmond J. Bacterial colonization of chronic leg ulcers: current results compared with data 5 years ago in a specialized dermatology department. *Journal of the European Academy of Dermatology and Venereology: JEADV* 2010; 24(9): 1017-25.
- Zerini I, Sisti A, Cuomo R, et al. Cellulite treatment: a comprehensive literature review. *J Cosmet Dermatol* 2015; 14(3): 224-40.
- D'Antonio A, Cuomo R, Angrisani B, Memoli D, Angrisani P. Desmoplastic cellular neurothekeoma mimicking a desmoplastic melanocytic tumor. *Journal of the American Academy of Dermatology* 2011; 65(2): e57-8.
- Grimaldi L, Cuomo R, Brandi C, Botteri G, Nisi G, D'Aniello C. Octyl-2-cyanoacrylate adhesive for skin closure: eight years experience. *In vivo*. 2015; 29(1): 145-8.
- Cuomo R, Russo F, Sisti A, et al. Abdominoplasty in Mildly Obese Patients (BMI 30-35 kg/m²): Metabolic, Biochemical and Complication Analysis at One Year. *In vivo*. 2015; 29(6): 757-61.
- Cuomo R, Zerini I, Botteri G, Barberi L, Nisi G, D'Aniello C. Postsurgical pain related to breast implant: reduction with lipofilling procedure. *In vivo*. 2014; 28(5): 993-6.
- D'Antonio A, Addesso M, Memoli D, et al. Lymph node-based disease and HHV-8/KSVH infection in HIV seronegative patients: report of three new cases of a heterogeneous group of diseases. *Int J Hematol* 2011; 93(6): 795-801.
- Cuomo R, Nisi G, Grimaldi L, Brandi C, Sisti A, D'Aniello C. Immunosuppression and Abdominal Wall Defects: Use of Autologous Dermis. *In vivo*. 2015; 29(6): 753-5.
- Nisi G, Barberi L, Ceccaccio L, et al. Effect of repeated subcutaneous injections of carbon dioxide (CO₂) on inflammation linked to hypoxia in adipose tissue graft. *European review for medical and pharmacological sciences* 2015; 19(23): 4501-6.
- Nisi G, Cuomo R, Brandi C, Grimaldi L, Sisti A, D'Aniello C. Carbon dioxide therapy and hyaluronic acid for cosmetic correction of the nasolabial folds. *Journal of cosmetic dermatology* 2016; 15(2): 169-75.

Received: 6 October 2016

Accepted: 11 February 2017

Correspondence:

Roberto Cuomo M.D.

Unit of Plastic and Reconstructive Surgery,

University of Siena – Mario Bracci street

Santa Maria Alle Scotte Hospital

53100 Siena (SI), Italy

Tel. +0039 0577 585158

E-mail: robertocuomo@outlook.com