

# Occam's Razor Need Not Apply: A Case of Concurrent Cryptococcal Meningitis and Primary Central Nervous System Lymphoma in an Human Immunodeficiency Virus/Acquired Immune Deficiency Syndrome Patient

Xiao Jing Wang<sup>1</sup> and Colleen F. Kelley<sup>2</sup>

<sup>1</sup>J. Willis Hurst Internal Medicine Residency Program, Department of Internal Medicine, Emory University School of Medicine, and <sup>2</sup>Division of Infectious Diseases, Department of Medicine, Department of Epidemiology, Emory University School of Medicine, Rollins School of Public Health, Atlanta, Georgia

## CLINICAL VIGNETTE

A 28-year-old man with human immunodeficiency virus (HIV)/acquired immune deficiency syndrome (AIDS) (CD4<sup>+</sup> cells 4/1%) was diagnosed and treated for cryptococcal meningitis (CM) 3 weeks before admission with a 14-day course of amphotericin and flucytosine and subsequently discharged on oral fluconazole. However, surveillance of cerebrospinal fluid (CSF) cultures collected before discharge later turned positive for *Cryptococcus neoformans* and he was called back for evaluation.

On admission, the patient reported headache, diplopia, and overall malaise. A head computed tomography showed new enhancing mass lesions in the left and right caudate nuclei with vasogenic edema (Figure 1). Repeat lumbar puncture showed a high opening pressure of 35 mmH<sub>2</sub>O and *C neoformans* detected by antigen and CSF culture. He was resumed on amphotericin and flucytosine induction therapy for presumed relapsed CM with possible cryptococcoma.

A magnetic resonance imaging (MRI) of the brain was obtained and showed 2 different lesions with increased density, restricted diffusion, and low T2 signal relative to normal brain parenchyma, which were most concerning for central nervous

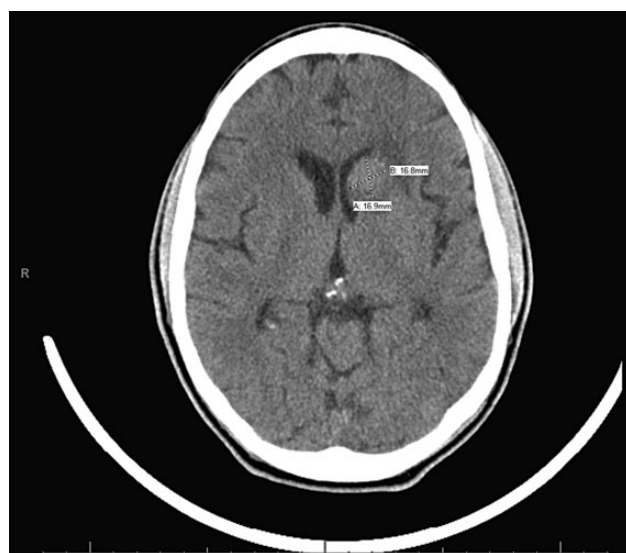
system (CNS) lymphoma or toxoplasmosis and less concerning for cryptococcoma by radiographic appearance (Figure 2).

Further CSF studies ruled out toxoplasmosis but showed positive Epstein-Barr virus DNA polymerase chain reaction, again concerning for CNS lymphoma. A brain biopsy could not be obtained due to the location of lesions. Therefore, MRI spectroscopy was performed and showed an increase in the size of both masses suggestive of malignancy (Figure 3) and an elevated choline peak with decreased *N*-acetylaspartate (NAA) peak, consistent with high-grade CNS lymphoma (Figure 4).

The patient was started on antiretroviral therapy and steroids with initial improvement in symptoms, but he subsequently developed acute neurologic decompensation requiring emergent whole brain radiation therapy, which was complicated by hemodynamic instability and hypothermia. He eventually stabilized and was discharged on oral fluconazole and to complete radiation as an outpatient followed by high-dose methotrexate therapy (Figure 5).

## DISCUSSION

Occom's razor is a principle of diagnostic parsimony that pushes physicians for a unifying diagnosis. However, for patients with advanced HIV/AIDS, the presence of multiple opportunistic infections is not uncommon and parsimony is often impossible. In our patient, Occom's razor would suggest that cryptococcoma, although rare, would be the most likely diagnosis given recent infection and persistently positive CSF cultures.



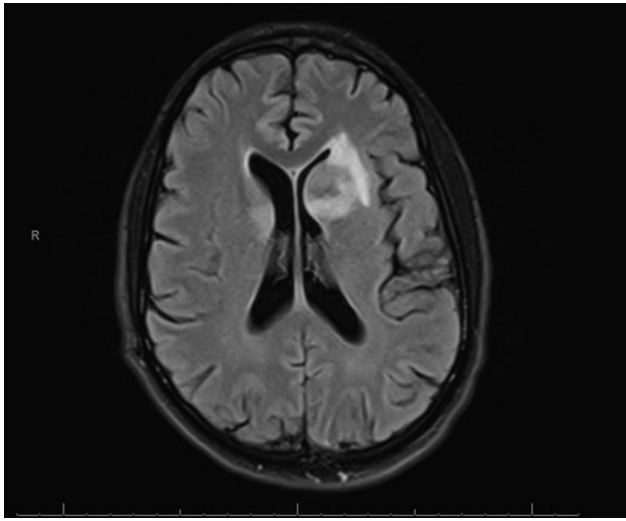
**Figure 1.** A noncontrast computed tomography of the head showed an expansile, hyperattenuating lesion arising from the left caudate head.

Received 27 August 2015; accepted 30 November 2015.

Correspondence: X. J. Wang, 3302 Westchester Ridge NE, Atlanta, GA 30329 (xjwang@emory.edu).

Open Forum Infectious Diseases®

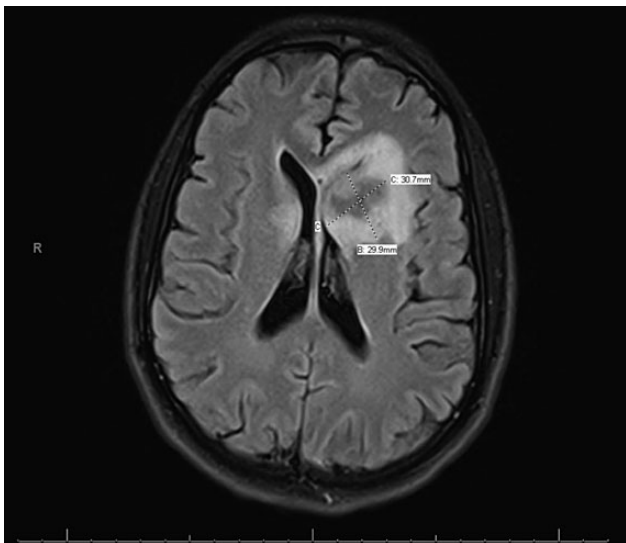
© The Author 2015. Published by Oxford University Press on behalf of the Infectious Diseases Society of America. This is an Open Access article distributed under the terms of the Creative Commons Attribution-NonCommercial-NoDerivs licence (<http://creativecommons.org/licenses/by-nc-nd/4.0/>), which permits non-commercial reproduction and distribution of the work, in any medium, provided the original work is not altered or transformed in any way, and that the work is properly cited. For commercial re-use, please contact [journals.permissions@oup.com](mailto:journals.permissions@oup.com). DOI: 10.1093/ofid/ofv187



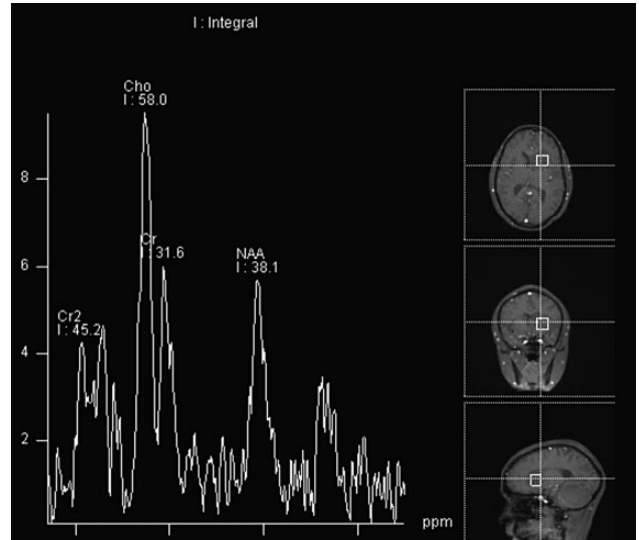
**Figure 2.** A representative T2 flair magnetic resonance image of the brain showed abnormal signal and mass effect involving the head of the left caudate with hyperintensity measuring 2.5 × 2 cm extending into the surrounding white matter and along the external and extreme capsules. The anterior aspect of the putamen is involved along with the anterior limb of the internal capsule and the superior anterior aspect of the globus pallidus. There is an area of similar mass effect and abnormal T2 signal involving the posterior superior aspect of the right caudate head, caudate tail measuring approximately 8 mm in width and approximately 1.3 mm anterior posterior.

However, given advanced immunosuppression, radiographic appearance, and symptom progression despite therapy, the differential diagnosis was broadened.

Diagnosis of CNS lymphoma is difficult and often requires brain biopsy. When location of lesions precludes direct tissue

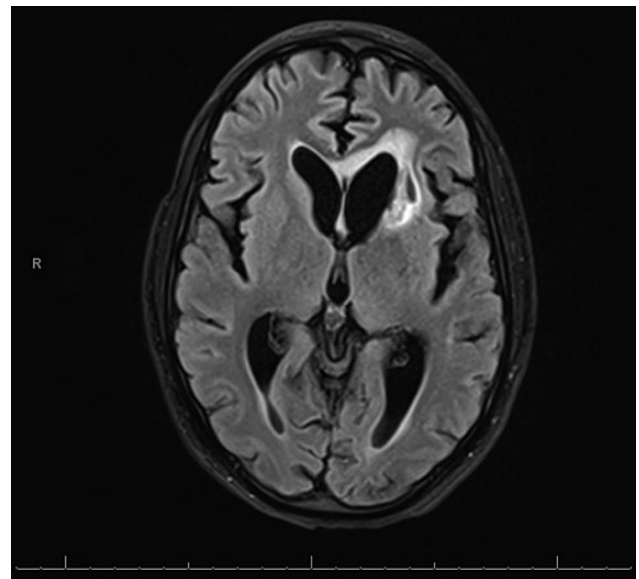


**Figure 3.** A representative image of the magnetic resonance image of fluid-attenuated inversion recovery with spectroscopy shows significant interval increase in the size of periventricular masses in the bilateral caudates with associated restricted diffusion



**Figure 4.** Results of the magnetic resonance spectroscopy showed an elevated choline peak with decreased *N*-acetylaspartate (NAA) peak, findings in keeping with a high-grade neoplasm centered in the left caudate.

sampling, MRI spectroscopy can be used with enhancement of specific frequencies (eg, elevated choline peak) being highly suggestive [1]. Accurate diagnosis is important, because the treatments of these 2 CNS processes are incongruent. Central nervous system lymphoma is treated with urgent antiretroviral initiation, which could potentiate CM immune reconstitution syndrome [2]. Treatment of both diseases can lead to severe side effects such as pancytopenia from flucytosine, hypothermia, and



**Figure 5.** Magnetic resonance image of the brain, T2-fluid-attenuated inversion recovery image 1 month after completion of radiation therapy course showing improvement in lesion size.

encephalopathy from brain radiation [3] and fever with rigors or renal failure from amphotericin.

Our case illustrates the importance of keeping a broad differential diagnosis in immunocompromised patients, diagnosing CNS lymphoma when tissue sampling is unavailable, and the value of diagnostic accuracy to minimize treatment side effects.

### **Acknowledgments**

*Financial support.* We did not receive any funding for the completion of this review.

*Potential conflicts of interest.* All authors: No reported conflicts. All authors have submitted the ICMJE Form for Disclosure of Potential Conflicts of Interest.

### **References**

1. Lu SS, Kim SJ, Kim HS, et al. Utility of proton MR spectroscopy for differentiating typical and atypical primary central nervous system lymphomas from tumefactive demyelinating lesions. *AJNR Am J Neuroradiol* **2014**; 35:270–7.
2. Walker NF, Scriven J, Meintjes G, Wilkinson RJ. Immune reconstitution inflammatory syndrome in HIV-infected patients. *HIV AIDS (Auckl)* **2015**; 7:49–64.
3. Kellogg RG, Straus DC, Karmali R, et al. Impact of therapeutic regimen and clinical presentation on overall survival in CNS lymphoma. *Acta Neurochir (Wien)* **2014**; 156:355–65.