

An unexpected cause of pulmonary hypertension in a young woman: a case report

Judith Aeberhard ¹, Mona Lichtblau ², and Nisha Arenja ^{1,3*}

¹Department of Cardiology, Kantonsspital Olten, 4600 Olten, Switzerland; ²Clinic of Pulmonology, University Hospital Zurich, 8091 Zurich, Switzerland; and ³Faculty of Medicine, University of Basel, Basel, Switzerland

Received 1 March 2023; revised 12 September 2023; accepted 27 September 2023; online publish-ahead-of-print 29 September 2023

Background

Pulmonary hypertension (PH) is defined as a progressive disease that leads to right heart failure and death if untreated. This case report presents a young woman with reversible precapillary PH in the setting of a gastric cancer.

Case summary

A 37-year-old woman presented with exertional dyspnoea and syncope. The transthoracic echocardiographic findings were consistent with a cor pulmonale. Right heart catheterization (RHC) proved a precapillary PH. Specific PH therapy with macitentan and tadalafil was initiated. Shortly thereafter, a gastric carcinoma was diagnosed, and oncologic treatment with neoadjuvant chemotherapy and subsequent gastrectomy was promptly initiated. Retrospectively, we considered a pulmonary tumour thrombotic microangiopathy the most probable cause of PH. Follow-up after successful oncologic treatment and cumulative 10 months of specific PH medication showed an excellent clinical response with complete remission of PH confirmed by RHC at rest.

Discussion

Tumour-related PH is very rare and might be largely underdiagnosed as the clinical course often results in a rapid deterioration and fatal outcome before diagnostics are completed. Post *mortem* studies have documented tumoural emboli in pulmonary microcirculation in ~26% of patients with a solid tumour, markedly associated with adenocarcinoma. Prompt initiation of cancer treatment on tumoural PH is essential. To our knowledge, this report documents the first full recovery of tumoural PH at rest after successful cancer treatment and temporary specific PH medication. We therefore conclude that a multidisciplinary approach with an initially combined oncologic and PH therapy may be most beneficial with the potential of complete remission of PH.

Keywords

Pulmonary hypertension WHO group 5 • pulmonary tumor thrombotic microangiopathy • case report, tumoral pulmonary hypertension

ESC curriculum

2.2 Echocardiography • 6.4 Acute heart failure • 6.7 Right heart dysfunction • 9.6 Pulmonary hypertension

Learning points

- In case of rapid onset hypoxaemia and clinical deterioration in a patient with a neoplastic disease, notably adenocarcinoma, an underlying tumour thrombotic microangiopathy should be considered.
- Tumoural pulmonary hypertension requires a prompt and multidisciplinary diagnostic and therapeutic approach.

Introduction

Pulmonary hypertension (PH), defined as mean pulmonary arterial pressure (mPAP) above 20 mmHg at rest as determined by right heart catheterization (RHC), is a progressive disease that leads to

right heart failure and death if untreated. In clinical practice, we encounter PH in the context of indicative symptoms, such as dyspnoea, fatigue, angina, and syncope, or as an incidental finding in echocardiography. Prior literature has reported a cumulative incidence of PH of 1%.¹

* Corresponding author. Tel: 0041 62 311 41 11, Email: nisha_arenja@spital.so.ch

Handling Editor: Romain Didier

Peer-reviewers: Aiste Monika Jakstaite and Stefano Albani

Compliance Editor: Emmanouil Mantzouranis

© The Author(s) 2023. Published by Oxford University Press on behalf of the European Society of Cardiology.

This is an Open Access article distributed under the terms of the Creative Commons Attribution-NonCommercial License (<https://creativecommons.org/licenses/by-nc/4.0/>), which permits non-commercial re-use, distribution, and reproduction in any medium, provided the original work is properly cited. For commercial re-use, please contact journals.permissions@oup.com

Summary figure

Date	Event
Week 1	Hospital admission due to exertional dyspnoea, syncope, and new onset of T-wave inversions in the electrocardiogram (ECG). Echocardiography: cor pulmonale. Ventilation–perfusion scintigraphy: small peripheral perfusion defects. RHC: precapillary pulmonary arterial hypertension, no vasoreactivity testing due to inconclusive result of the lung scan regarding pulmonary venous occlusive disease. A chronic thromboembolic PH is considered possible. Initiation of therapeutic anticoagulation with heparin.
Week 2	RHC: negative vasoreactivity testing. Start specific PH medication: macitentan, tadalafil. Episode of haematemesis with need of transfusion. Gastroscopy: gastric adenocarcinoma.
Week 4	Platelet count nadir of 23 000/mm ³ , positive screening of heparin-induced thrombocytopenia.
Week 5	Initiation of chemotherapy
Week 14	Follow-up at PH unit. World Health Organization (WHO) functional class I. Continuation of dual PH medication and anticoagulation.
Week 19	Gastrectomy with Roux-en-Y reconstruction and local lymphadenectomy.
Week 36	Completion of neoadjuvant chemotherapy.
Week 47	Follow-up at PH unit. Echocardiography: normalized dimension and function of the right heart. Ventilation–perfusion scintigraphy: homogeneous ventilation and perfusion, no signs of chronic thromboembolic PH. Stop specific PH medication.
Week 52	RHC: normal pulmonary arterial pressure at rest. Stop anticoagulation.

World Health Organization classification has categorized PH into five different groups based on the underlying mechanism.¹ Pulmonary hypertension attributable to multifactorial pathomechanisms is defined as Group 5, which is the most heterogeneous and least studied, and PH in neoplastic diseases is one of its particular entities. This case report presents a young woman with reversible precapillary PH in the setting of a gastric cancer, emphasizing the importance of a multidisciplinary diagnostic and multimodal therapeutic approach.

Case presentation

A 37-year-old woman presented at the emergency department (ED) with exertional dyspnoea New York Class Association (NYHA) functional classes II and III, syncope, and new onset of T-wave inversions in the ECG (Figure 1). She presented in a clinically stable condition with a blood pressure of 130/80 mmHg, a pulse of 90/min, and an

oxygen saturation of 96%. The clinical examination was unremarkable. Her only significant medical history was Crohn's disease, which had been well controlled with adalimumab for 3 years. Computed tomography (CT) ruled out a pulmonary embolism and parenchymal lung disease (Figure 2). The transthoracic echocardiographic (TTE) findings were consistent with a cor pulmonale without signs of an intracardiac shunt or a left ventricular (LV) pathology (see [Supplementary material online, Video S1](#)). Right heart catheterization proved a precapillary PH with a negative vasoreactivity testing (mPAP 33 mmHg, pulmonary vascular resistance 4.8 WU, pulmonary arterial wedge pressure 7 mmHg, and central venous pressure 4 mmHg). Perfusion–ventilation scintigraphy displays small peripheral perfusion defects (Figure 3).

The presence of peripheral perfusion defects in scintigraphy was initially interpreted as possible chronic thromboembolic PH, and anticoagulation with heparin was started. However, the findings were later interpreted as in context of PH Group 1. Therefore, a PH specific therapy with macitentan and tadalafil was initiated under the continuation of heparin. The short-term course was then complicated by a heparin-induced thrombocytopenia (HIT) that was confirmed by a positive antibody test (HIT antibodies: IgG 6.96 U/mL) with otherwise normal coagulation parameters. Shortly thereafter, an episode of haematemesis occurred, and gastroscopy revealed a gastric adenocarcinoma. An escape chemotherapy regimen was launched before completion of tumour staging. Staging CT revealed subpleural nodular ground glass opacities with 'feeding vessel sign' compatible with PH but no metastatic spread of gastric cancer (Figure 2). Consequently, oncologic treatment was changed to a neoadjuvant chemotherapy and subsequent gastrectomy. The patient's symptoms improved shortly after the first administration of chemotherapy and resolved completely within 2 months. Retrospectively, we considered a pulmonary tumour thrombotic microangiopathy (PTTM) the most probable cause of PH. Follow-up after successful oncologic treatment and cumulative 10 months of specific PH medication showed an excellent clinical response; hence, specific PH therapy was ceased (see [Supplementary material online, Video S2; Figure 3](#)). A subsequently performed RHC confirmed complete remission of PH at rest (mPAP 17 mmHg, pulmonary vascular resistance 1.6 WU, pulmonary arterial wedge pressure 9 mmHg, and central venous pressure 5 mmHg).

Discussion

The most common cause of PH is LV dysfunction, followed by pulmonary disease, whereas tumour-related PH is very rare. Concerns are raised that tumoural PH is largely underdiagnosed as the clinical course often results in a rapid deterioration and fatal outcome before diagnostics are completed.² Post mortem studies have documented tumoural emboli in pulmonary microcirculation in ~26% of patients with a solid tumour, markedly associated with adenocarcinoma,^{3–5} whereas PTTM has been observed in ~3.3% of patients with extrathoracic malignancies with highest frequency (26%) in gastric carcinomas. When PTTM is suspected *ante mortem* and RHC is performed, a blood sample of the pulmonary artery can be analysed for tumour cells to further confirm the diagnosis. The available data result from small case series studies or reports and therefore provide low evidence regarding therapeutic strategies and follow-up procedures. Nevertheless, it is suggested that a prompt initiation of cancer treatment on tumoural PH is essential for survival.^{6–9} Furthermore, experimental administration of specific PH medication, antiproliferative and antiinflammatory drugs such as imatinib or glucocorticoids with amelioration of PTTM has been reported.^{10–14}

To our knowledge, this report documents one of only few survived PTTM and the first full recovery of tumoural PH at rest after successful cancer treatment and temporary specific PH medication.⁹ We therefore conclude that a multidisciplinary approach with an initially

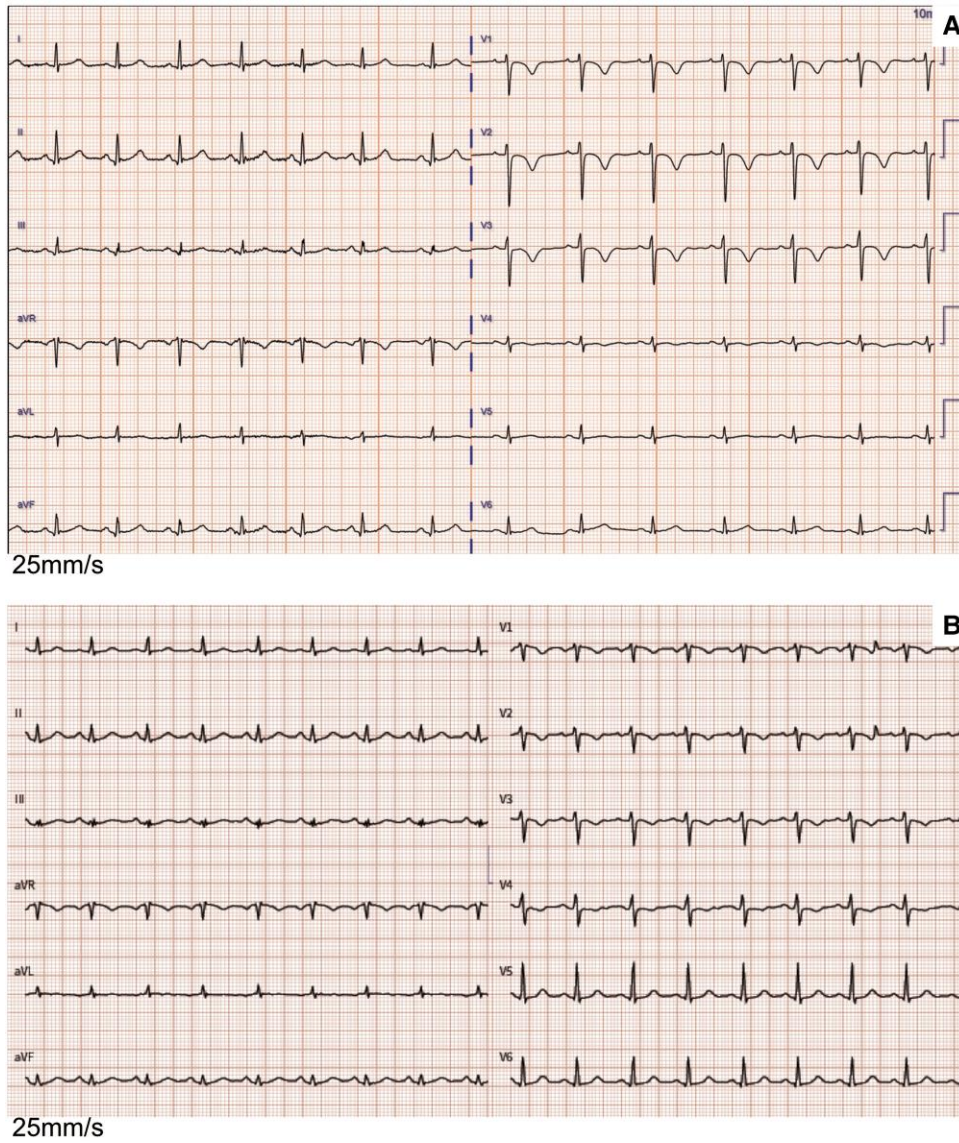


Figure 1 Initial electrocardiogram (A) and follow-up at week 14 (B).

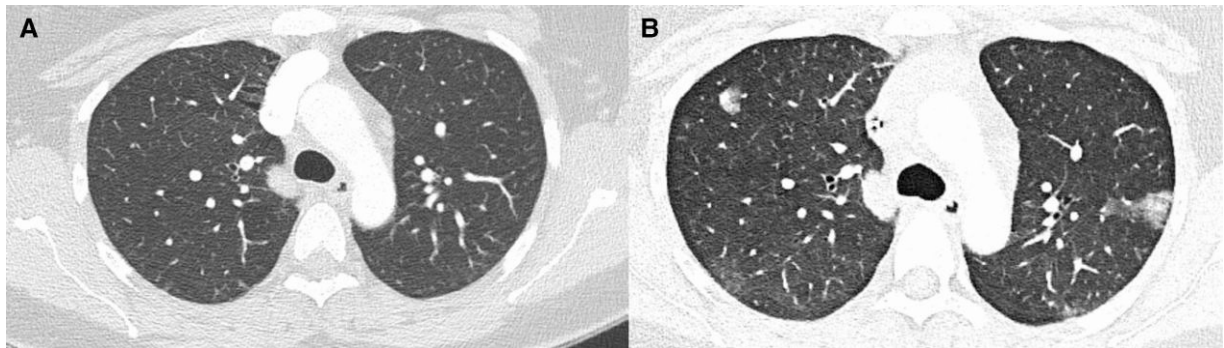
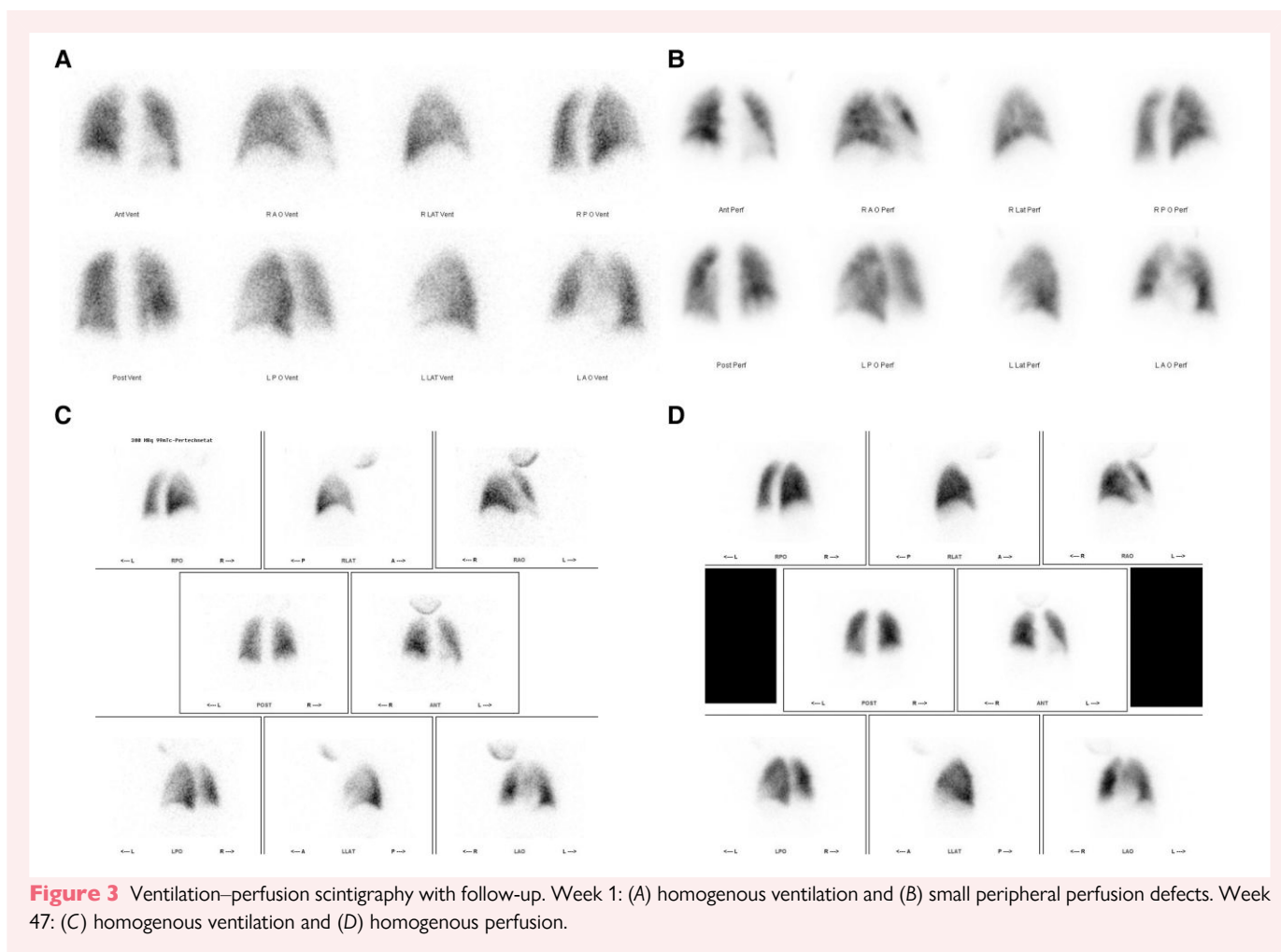


Figure 2 Computed tomography of the lung. (A) Week 1: normal lung parenchyma. (B) Week 4: bipulmonary subpleural nodular ground glass opacities with 'feeding vessel sign'.



combined oncologic and PH therapy may be most beneficial with the potential of complete remission of PH. However, further investigation and long-term follow-up are required.¹⁵

Lead author biography



Judith Aeberhard has recently started her residency programme in cardiology at Olten Hospital Switzerland. She graduated from the University of Berne Switzerland. She then attended her residency programme in internal medicine at the hospitals in Langnau, Biel, and Olten and the Geriatric Department of Zürich Switzerland. She later worked in practice for internal medicine in Rapperswil-Jona, Switzerland.

Supplementary material

Supplementary material is available at *European Heart Journal – Case Reports* online.

Consent: The authors confirm that written consent for submission and publication of this case report has been obtained from the patient in line with COPE guidance.

Conflict of interest: None declared.

Funding: None declared.

Data availability

The data underlying this article are available within the article and in its online [supplementary material](#).

References

- Humbert M, Kovacs G, Hoeper MM, Badagliacca R, Berger RMF, Brida M, et al. 2022 ESC/ERS guidelines for the diagnosis and treatment of pulmonary hypertension. *Eur Heart J* 2022;**43**:3618–3731.
- Rajdev K, Madan U, McMillan S, Wilson K, Fisher K, Hein A, et al. Pulmonary tumor embolism and pulmonary tumor thrombotic microangiopathy causing rapidly progressive respiratory failure: a case series. *J Investig Med High Impact Case Rep* 2022;**10**: 23247096221086453.
- Shields DJ, Edwards WD. Pulmonary hypertension attributable to neoplastic emboli: an autopsy study of 20 cases and a review of literature. *Cardiovasc Pathol* 1992;**1**:279–287.
- Winterbauer RH, Elfenbein IB, Ball WC Jr. Incidence and clinical significance of tumor embolization to the lungs. *Am J Med* 1968;**45**:271–290.
- Kawakami N, Moriya T, Kato R, Nakamura K, Saito H, Wakai Y, et al. Pulmonary tumor thrombotic microangiopathy in occult early gastric cancer that was undetectable on upper endoscopy: a case report and review of similar cases. *BMC Gastroenterol* 2021; **21**:423.

6. Gainza E, Fernández S, Martínez D, Castro P, Bosch X, Ramírez J, et al. Pulmonary tumor thrombotic microangiopathy: report of 3 cases and review of the literature. *Medicine (Baltimore)* 2014;**93**:359–363.
7. Imakura T, Tezuka T, Inayama M, Miyamoto R, Abe A, Otsuka K, et al. A long-term survival case of pulmonary tumor thrombotic microangiopathy due to gastric cancer confirmed by the early diagnosis based on a transbronchial lung biopsy. *Intern Med* 2020;**59**:1621–1627.
8. Merad M, Alibay A, Ammari S, Antoun S, Bouguerba A, Ayed S, et al. Microangiopathie thrombotique tumorale pulmonaire [Pulmonary tumor thrombotic microangiopathy]. *Rev Mal Respir* 2017;**34**:1045–1057.
9. Kim M, Yoon H, Kim MY, Jo JJ, Kang SY, Lee G, et al. Echocardiographic assessment of patients with pulmonary tumor thrombotic microangiopathy first diagnosed in the emergency department. *Diagnostics (Basel)* 2022;**12**:259.
10. Ma G, Wang D, Xu X, Liang L, Xu L. Case report: apatinib plus selexipag as a novel therapy for pulmonary tumor thrombotic microangiopathy accompanied by pulmonary hypertension associated with gastric carcinoma. *Medicine (Baltimore)* 2022;**101**:e29412.
11. Fukada I, Araki K, Minatsuki S, Fujino T, Hatano M, Numakura S, et al. Imatinib alleviated pulmonary hypertension caused by pulmonary tumor thrombotic microangiopathy in a patient with metastatic breast cancer. *Clin Breast Cancer* 2015;**15**:e167–e170.
12. Higo K, Kubota K, Takeda A, Higashi M, Ohishi M. Successful antemortem diagnosis and treatment of pulmonary tumor thrombotic microangiopathy. *Intern Med* 2014;**53**:2595–2599.
13. Ogawa A, Yamadori I, Matsubara O, Matsubara H. Pulmonary tumor thrombotic microangiopathy with circulatory failure treated with imatinib. *Intern Med* 2013;**52**:1927–1930.
14. Minatsuki S, Miura I, Yao A, Abe H, Muraoka H, Tanaka M, et al. Platelet-derived growth factor receptor-tyrosine kinase inhibitor, imatinib, is effective for treating pulmonary hypertension induced by pulmonary tumor thrombotic microangiopathy. *Int Heart J* 2015;**56**:245–248.
15. Price LC, Seckl MJ, Dorfmueller P, Wort SJ. Tumoral pulmonary hypertension. *Eur Respir Rev* 2019;**28**:180065.