



ORIGINAL ARTICLES

Familial cardiomyopathy caused by a novel heterozygous mutation in the gene *LMNA* (c.1434dupG): a cardiac MRI-augmented segregation study

MASHAEL ALFARIH^{1,2,3}, PETROS SYRRIS², ELOISA ARBUSTINI⁴, JOÃO B. AUGUSTO^{1,2}, ALUN HUGHES^{2,5}, GUY LLOYD^{1,2}, LUIS R. LOPES^{1,2}, JAMES C. MOON^{1,2}, SAIDI MOHIDDIN¹ AND GABRIELLA CAPTUR^{1,2,5,6}

¹ Barts Heart Center, The Cardiovascular Magnetic Resonance Imaging Unit, St Bartholomew's Hospital, West Smithfield, London, UK; ² Institute of Cardiovascular Science, University College London, Gower Street, London, UK; ³ Department of Cardiac Technology, College of Applied Medical Sciences, Imam Abdulrahman Bin Faisal University, Dammam, Saudi Arabia; ⁴ Center for Inherited Cardiovascular Diseases, Foundation IRCCS Policlinico San Matteo, University of Pavia, Italy; ⁵ UCL MRC Unit for Lifelong Health and Ageing, 33 Bedford Place, London, UK; ⁶ Cardiology Department, Royal Free Hospital NHS Trust, Pond St, Hampstead, London, UK

In a five-generation family carrying a novel frameshift *LMNA* variant (c.1434dupG, p.Leu479AlafsX72), imaging-augmented segregation analysis supports its association with lamin heart disease. Affected members exhibit conduction abnormalities, supraventricular and ventricular arrhythmias, dilated cardiomyopathy with non-infarct pattern midwall septal fibrosis, heart failure and thromboembolic complications.

Key words: familial dilated cardiomyopathy, lamin A/C, cardiomyopathies

Introduction

Lamin A/C are structural intermediate filaments encoded by the *LMNA* gene. *LMNA* gene mutations are responsible for various multi-system laminopathies including lamin heart disease (LHD) which is characterized by cardiac conduction system disease (CCD), dilated cardiomyopathy (DCM), heart failure, malignant ventricular arrhythmias (VA) and sudden cardiac death (1). Given the high arrhythmogenic risk, early recognition and intervention by implantable cardioverter defibrillator (ICD) can be life-saving.

Defining pathogenicity of novel *LMNA* variants remains a challenge, but long-term surveillance of mutation-positive families permits segregation studies that are

essential contributors to the validation of pathogenic mutations. Advanced tissue characterisation by cardiovascular magnetic resonance (CMR) may help clinicians better understand the potential pathogenicity of variants, especially when segregation studies include family members with borderline/subclinical phenotypes by other imaging modalities.

Here we describe the deep clinical phenotypes associated with a previously unreported *LMNA* variant: c.1434dupG.

Case presentation

We report a family in which all affected members with cardiomyopathy (Fig. 1, left panel) carry the heterozygous *LMNA* variant, c.1434dupG (Tab. 1). The variant is predicted to disrupt protein reading frame creating a premature termination codon confirmed by Alamut® software. As variant pathogenicity was unknown we performed an imaging-assisted segregation study, demonstrating a link between variant and LHD.

Within this five-generation family, four members are confirmed carriers of the variant by DNA testing, expressing a clinical phenotype that includes DCM, myocardial septal fibrosis [anecdotally found in 88% of *LMNA* gene mutation carriers (2)], supraventricular and ventricular arrhythmias, CCD, heart failure and throm-

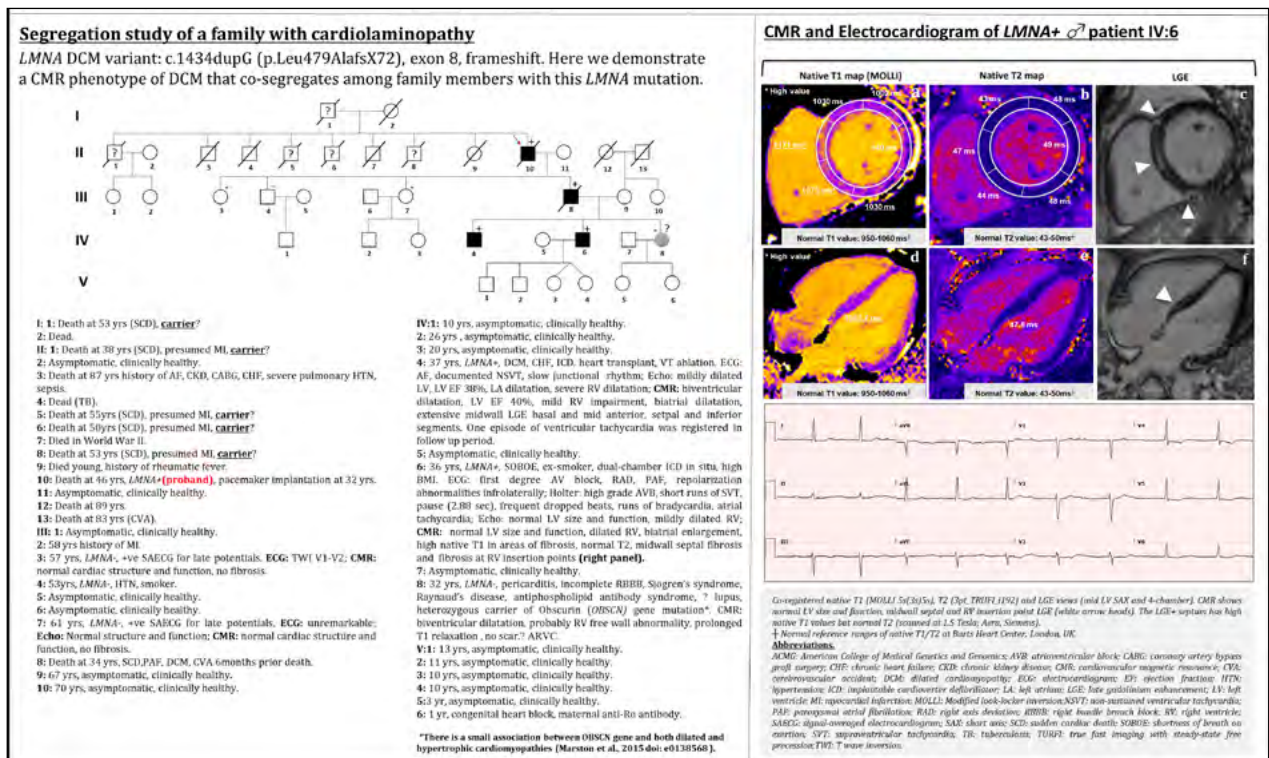


Figure 1. CMR-assisted segregation study for a family with novel LMNA frameshift variant c.1434dupG, p.Leu479AlafsX72 [Classification by ClinVar “not provided”; ACMG: “pathogenic (Ia)”; gnomAD: “absent”].

Table 1. Novel LMNA genetic variant summary.

Variant	c.1434dupG, p.Leu479AlafsX72
Mutation status	Autosomal dominant, heterozygous
Variant type	Frameshift (truncation predicting mutation)
Molecular consequence	NM_170707: c.1434dupG: loss-of-function variant
Genomic location	Chr 1: 156,114,707-156,140,089
Variant location	Exon 8: Single nucleotide duplication, premature termination codon; downstream of the nuclear localization signal (NLS, exon 7) but upstream of the C-terminal tail * Recent data suggests that there is an association between more adverse cardiac phenotype and LMNA mutations upstream of the NLS or upstream of the tail (Captur et al., 2018. Doi: 10.1136/openhrt-2018-000915).
Phenotypic group	Dilated cardiomyopathy-conduction disease (DCM-CD)
GnomAD database	Absent
ClinVar clinical significance	Not reported
ACMG assertion of pathogenicity	Pathogenic (Ia) Using American College of Medical Genetics and Genomics/Association for Molecular Pathology (ACMG/AMP) criteria: the variant fulfills PVS1, PP1, PM2 and PP4 (1 x very strong, 1x moderate and 2 x supporting) implying pathogenicity.
Type of analysis	Direct fluorescent DNA sequencing for exon 8

boembolic complications (Tab. 2). There was a history of sudden death in seven members, interestingly all males [male gender is an adverse prognostic marker in

LHD (3)]: proband II-10 died suddenly in his 40s likely from paternal inheritance of the variant as his father (I-1) died abruptly in his 50s (no genetic data available for

Table 2. Family study-disease progression and results of electrocardiogram, 24-hour Holter and CMR.

Family code	Sex	Genetic status	Adverse events					ECG/holter					CMR
			mVA	SCD	CHF	CVA	DCM	Brady	SVT	AVB	A.Fib/F	PAC/PVC	LGE
I-1	M	NK(?)		+									
II-1	M	NK(?)		+									
II-5	M	NK(?)		+									
II-6	M	NK(?)		+									
II-8	M	NK(?)		+									
II-10	M	LMNA+		+									
III-3	F	LMNA-	-	-	-	-	-	-	-	-	-	-	-
III-4	M	LMNA-	-	-	-	-	-	-	-	-	-	-	-
III-7	F	LMNA-	-	-	-	-	-	-	-	-	-	-	-
III-8	M	LMNA+		+		+	+				+		
IV-4	M	LMNA+	+		+		+	+			+		+
IV-6	M	LMNA+						+	+	+	+		+
IV-8	F	LMNA-	-	-	-	-	-	-	-	-	-	-	-

+/- Indicates presence/absence of the trait; blanks represent missing data. Abbreviations: A.Fib/F: atrial fibrillation/flutter; AVB: Atrio-ventricular block; Brady: bradyarrhythmia; CHF: congestive heart failure; CMR: cardiovascular magnetic resonance; DCM: dilated cardiomyopathy; ECG: electrocardiogram; F: female; LGE: late gadolinium enhancement; M: male; NK(?): Not known (genetic testing not done); PAC: Premature atrial contraction; PVC: premature ventricular contraction; SCD: sudden cardiac death; SVT: supraventricular tachycardia; mVA: malignant ventricular arrhythmia; *LMNA+*: *LMNA* gene mutation present; *LMNA-*: negative for *LMNA* gene mutation.

the latter). Members I-1, II-1, II-5, II-6 and II-8 died young and unexpectedly (no genetic data available). Patient III-8 carries the variant and expresses an overt DCM phenotype together with atrial fibrillation (AF). Two of his children were also found to be carriers: IV-4 expressed DCM with heart failure, advanced CCD and ventricular arrhythmias that required an ICD. A DCM-pattern of extensive myocardial midwall septal fibrosis was noted by cardiovascular magnetic resonance (CMR) imaging. His brother IV-6, exhibited isolated right ventricular enlargement and biatrial dilatation in the context of AF, supraventricular arrhythmias and progressive CCD. Following multidisciplinary team (MDT) meeting discussion family member IV-6 received a primary prevention dual chamber ICD given his two risk factors for sudden cardiac death [male gender and non-missense *LMNA* mutation (4)]. His CMR similarly revealed mid-wall septal fibrosis matched by elevated native myocardial T_1 times (Fig. 1, right panel). On follow-up, post-ICD, we detected a self-terminating ten-beat salvo of non-sustained ventricular tachycardia (VT).

DNA testing in their sister IV-8 with normal CMR, excluded the presence of an *LMNA* mutation but identified a variant of uncertain significance (VUS) in the *Obscurin* gene (*OBSCN*, c.21011C > G, p.Ser7004Cys). Although a few *OBSCN* mutations have been reported in the context of DCM and hypertrophic cardiomyopathy (5), their occurrence in heterozygous states in individuals from the general population argue against their pathogenicity.

Discussion

Our report describes a family in which the proband and affected family member harbour a novel potentially pathogenic mutation in *LMNA* gene (c.1434dupG). The mutation was not previously described in the literature, however the clinical course and ominous outcomes resemble those reported in cardiolaminopathy. In this family there were seven premature sudden deaths (6). In a multicentre study of 269 *LMNA* mutation carriers male gender, non-missense mutation, left ventricular ejection fraction < 45% and presence of non-sustained VT were found to be independent predictors of malignant VA (4). In this regard, member IV-4 with ICD satisfies all four risk factors whilst member IV-6 with progressive CCD and ICD scored positive for two risk factors (male, non-missense mutation).

Pharmacological therapy in our *LMNA* gene mutation carriers with heart failure consisted of usual heart failure medications although in patients with bradyarrhythmias, beta blockers were reserved till after device implantation or else discussed in a dedicated cardiomyopathy MDT meeting. Arrhythmias were managed according to standard clinical practice, and all decisions related to device implantation were reached after considering SCD risk factors and broader MDT discussion.

This pedigree analysis highlights the added value of CMR in segregation studies of LHD. For example, CMR potentially enables clinicians to better: 1) differentiate *LMNA*-DCM from other phenotypic mimics such

as arrhythmogenic cardiomyopathy; 2) exclude ischemic DCM using quantitative perfusion mapping approaches; 3) monitor LHD progression over time; 4) detect sub-clinical phenotypes otherwise missed by other imaging modalities; 5) plan optimal timing of device implantation in patients with borderline phenotypes as part of a multi-disciplinary team meeting discussion.

Previous CMR work reported that non-ischaemic (midwall) scar in patients with LHD and VA predominantly involved the basal septum, basal inferior wall, and sub-aortic mitral continuity (7), which tallies with our current data. Member IV-6 had non-infarct pattern mid-wall LGE in the basal-to-mid septum matched by high myocardial T1 but normal T2 times, suggesting true myocardial septal fibrosis. Indeed he had QRS fragmentation on ECG (Fig. 1, right panel).

Limitations include that other genomic changes in this family cannot be definitively excluded, CMR was not performed on all family members, and genetic data unavailable for the five family members in generations I/II with premature sudden deaths.

Conclusions

LMNA frameshift variant (c.1434dupG) seems to be causative of lamin heart disease on the basis of this CMR-augmented segregation analysis however further studies are necessary to confirm our hypothesis.

Acknowledgment

The authors are grateful to Dr. Rachel Kearns (University college London Hospital), Ms. Ellie Quinn (Barts Heart Center) and Ms. Chrysoula Dalageorgou (University College London), for their valuable assistance and comments that greatly improved the manuscript.

Funding

This study was funded by National Institute for Health Research Rare Diseases Translational Research Collaboration (NIHR RD-TRC, #171603).

Conflicts of interest

The Authors declare to have no conflict of interest.

References

1. Peretto G, Sala S, Benedetti S, et al. Updated clinical overview on cardiac laminopathies: an electrical and mechanical disease. *Nucleus* 2018;9:380-91. <https://doi.org/10.1080/19491034.2018.1489195>.
2. Holmström M, Kivistö S, Heliö T, et al. Late gadolinium enhanced cardiovascular magnetic resonance of lamin A/C gene mutation related dilated cardiomyopathy. *J Cardiovasc Magn Reson* 2011;13:30. <https://doi.org/10.1186/1532-429X-13-30>.
3. Pasotti M, Klersy C, Pilotto A, et al. Long-term outcome and risk stratification in dilated cardiomyopathies. *J Am Coll Cardiol* 2008;52:1250-60. <https://doi.org/10.1016/j.jacc.2008.06.044>
4. Priori S, Lundqvist C, Mazzanti A, et al. ESC Guidelines for the management of patients with ventricular arrhythmias and the prevention of sudden cardiac death. *Eur Heart J* 2015;36:2793-867. <https://doi.org/10.1093/eurheartj/ehv316>
5. Marston S, Montgiraud C, Munster AB, et al. OBSCN mutations associated with dilated cardiomyopathy and haploinsufficiency. *PloS One* 2015;10:e0138568.
6. Bécane H, Bonne G, Varnous S, et al. High incidence of sudden death with conduction system and myocardial disease due to lamin A and C gene mutation. *Pacing Clin Electrophysiol* 2000;23:1661-6. <https://doi.org/10.1046/j.1460-9592.2000.01661.x>
7. Kumar S, Androulakis AF, Sellal JM, et al. Multicenter experience with catheter ablation for ventricular tachycardia in lamin A/C cardiomyopathy. *Circ Arrhythm Electrophysiol* 2016;9: pii: e004357. <https://doi.org/10.1161/CIRCEP.116.004357>.

How to cite this article: Alfarih M, Syrris P, Arbustini E, et al. Familial cardiomyopathy caused by a novel heterozygous mutation in the gene *LMNA* (c.1434dupG): a cardiac MRI-augmented segregation study. *Acta Myol* 2019;38:159-62.

This is an open access article distributed in accordance with the Creative Commons Attribution Non Commercial (CC BY-NC 4.0) license, which permits others to distribute, remix, adapt, build upon this work non-commercially, and license their derivative works on different terms, provided the original work is properly cited, appropriate credit is given, any changes made indicated, and the use is non-commercial. See: <http://creativecommons.org/licenses/by-nc/4.0/>.