

Hypercalcemic crisis due to adult T cell leukemia: a rare cause of paralytic ileus

Sojan George Kunnathuparambil, Pradeep Kumar Payangappadom, Praveen Kumar Yerol, Mukunda Madhavan, Sreejaya Sreesh, Premaletha Narayanan, Krishnadas Devdas, Vinayakumar Ramakrishnan Kattoor

Government Medical College, Thiruvananthapuram, Kerala, India

Abstract

Adult T cell leukemia- lymphoma is a rare aggressive malignancy of the peripheral T lymphocytes, caused by human T cell lymphotropic virus -1 (HTLV-1) infection. Hypercalcemia occurs in about 70% of patients with acute adult T cell leukemia. However, there are very few case reports of adult T cell leukemia presenting as a hypercalcemic crisis. We report a case of a 54-year-old male who presented with abdominal pain, constipation and altered sensorium. On examination he had generalized lymphadenopathy, hepatosplenomegaly and paralytic ileus. Investigation revealed hypercalcemic crisis with low parathormone (PTH) levels. Peripheral smear and bone marrow aspirate were consistent with adult T cell leukemia. HTLV-1 serology was positive. Despite the corrective measures for hypercalcemia and chemotherapy, he succumbed to the illness in a week.

Keywords paralytic ileus, hypercalcemic crisis, adult T cell leukemia, human T cell lymphotropic virus (HTLV) -1

Ann Gastroenterol 2012; 25 (2): 170-172

Introduction

Human T cell lymphotropic virus (HTLV) -1 is a human retrovirus first isolated by Poiesz et al in 1977 [1]. The prevalence of this infection varies widely from 10% in countries like Japan and the Caribbean islands to <0.01% in regions like Europe and North America [2]. In India the prevalence is 0.18% [3]. Hirata et al (1992) reported that the commonest route of transmission is breast feeding (16–30%) [4]. However transfusion of infected peripheral blood mononuclear cells in whole blood is the most efficient route of transmission. Other routes include injected drug abuse and unprotected sexual intercourse [2]. Chronic HTLV-1 infection is proven to cause Adult T cell Leukemia – lymphoma (ATLL).

ATLL is a rare aggressive malignancy of the peripheral T lymphocytes. Nuclear factor- κ B activation by the HTLV protein Tax is found to be an important factor for tumorigenesis. Interferon- γ with its angiostatic effects plays a role in the

regulation of ATLL [5]. ATLL occurs predominantly in the adults and is 1.5 times more common in males. WHO Classification (2008) describes four distinct variants of ATLL: acute, lymphomatous, chronic and smouldering [6], with a prevalence of 60%, 20%, 15% and 5% respectively [7]. The acute form is characterized by skin lesions (papulonodular lesions, erythroderma), lymphadenopathy, hepatosplenomegaly and elevated lactate dehydrogenase (LDH). Although hypercalcemia occurs in 70% of patients [8], hypercalcemic crisis is extremely rare. We report a case of ATLL presenting with paralytic ileus due to hypercalcemic crisis.

Case report

A 54-year-old diabetic male presented with diffuse abdominal pain, distension and obstipation for 3 days following an alcoholic binge. The patient had severe anorexia and nausea. The patient had become irritable with incomprehensible speech and abnormal behavior over the last two days and his relatives reported an 8 kg decrease in his body weight over the past 2 months. Six years ago he had undergone patellectomy and was transfused with 6 units of whole blood. There was no family history of malignancy. On examination he was dehydrated, tachypneic and cyanosed with a heart rate of 116 bpm and a blood pressure of 200/110 mmHg. His face and trunk were erythematous. He had generalized

Department of Medical Gastroenterology, Government Medical College, Thiruvananthapuram, Kerala, India

Conflict of Interest: None

Correspondence to: Dr Sojan George Kunnathuparambil, Senior Resident, Department of Medical Gastroenterology, SSB – 3, super specialty block 3rd floor, Govt. Medical College, Thiruvananthapuram 695 011, India, Tel: +01 94000 73067, e-mail: sgkunnathil@gmail.com

Received 4 December 2011; accepted 11 January 2012

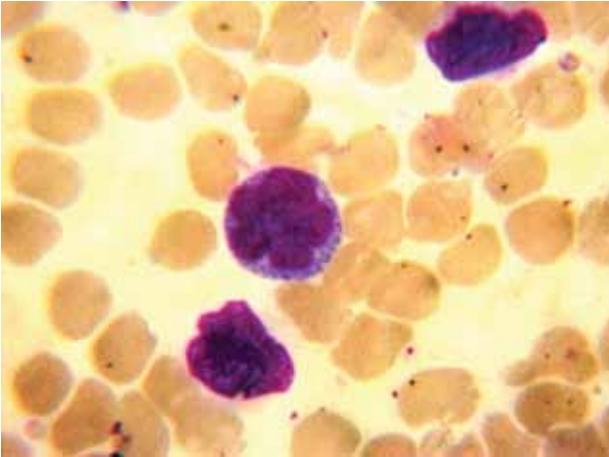


Figure 1 Peripheral smear showing 'flower cells' (magnification 100X)

lymphadenopathy. Abdominal examination revealed hepatosplenomegaly, generalized tympanitic resonance and absent bowel sounds. Auscultation of the chest revealed diffuse crepitations. Neurological examination showed no signs of meningeal irritation. Cardiac examination was unremarkable. The clinical findings were suggestive of paralytic ileus and the differential diagnosis considered included acute pancreatitis, diabetic ketoacidosis (DKA), porphyria and hypercalcemia.

His hemogram was as follows: hemoglobin, 13.8 g/dL; leukocyte count, $174 \times 10^9/L$ with 70% lymphocytes; platelet count, $156 \times 10^9/L$; and ESR, 63 mm. His urea was 112 mg/dL and creatinine level 3.9 mg/dL. He also had hyperkalemia (6.0 mg/dL), hyperuricemia (10.6 mg/dL) and LDH levels >5 times the upper limit of normal (ULN) suggesting the possibility of increased cell turn over. His pancreatic enzymes were normal, urine ketones and porphyrinogen negative, thereby ruling out pancreatitis, DKA and porphyria. He had high calcium (15.8 mg/dL), high phosphate (5.8 mg/dL), normal magnesium and

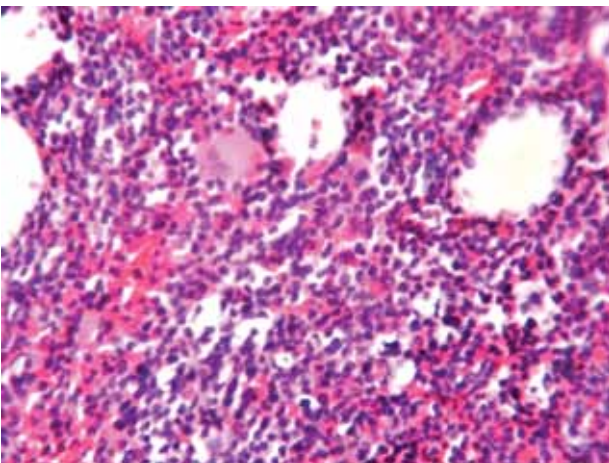


Figure 2 Bone marrow studded with malignant lymphocytes (magnification 10X)

low parathormone levels of 8.8 pg/mL (normal 13-55 pg/mL). His alkaline phosphatase was >3 times the ULN. The results were suggestive of a malignancy-associated hypercalcemia. His duodenal aspirate and biopsy were negative for strongyloides larvae. There was evidence of reticulonodular opacities in both lung fields. ABG analysis showed acute lung injury ($PaO_2/FiO_2 = 252$). Sputum cytology showed malignant cells and was negative on silver stain. ECG showed a corrected QT interval of 0.36 sec. Spinal fluid study was normal and was negative for *Cryptococcus* on Indian ink staining. Dilated bowel loops were seen in the abdominal X-ray. Ultrasound of the abdomen revealed hepatosplenomegaly and intra-abdominal lymphadenopathy. His peripheral smear showed marked leukocytosis, predominantly atypical mononuclear cells with high nucleocytoplasmic ratio. Few lymphocytes had convoluted nuclei suggestive of flower cells (Fig. 1), characteristic of ATLL. Bone marrow was studded with abnormal cells (Fig. 2) and immunophenotyping showed CD3+, CD4+, CD7-, CD8-, CD25+ lymphocytes. His HTLV-1 serology was positive.

The patient was diagnosed with paralytic ileus secondary to hypercalcemic crisis due to adult T cell leukemia caused by HTLV-1. The patient was treated with aggressive hydration, corticosteroids, furosemide, hemodialysis and chemotherapy was initiated. His calcium levels reduced to 12 g/dL and his bowel sounds reappeared. However his leukocyte count increased to $345 \times 10^9/L$. The patient developed anuria with progressive worsening of renal function (creatinine of 6.4 g/dL) and succumbed one week after admission.

Discussion

Acute ATLL is a rare aggressive malignancy of post thymic lymphocytes aetiologically linked to HTLV-1. In this case, the patient is likely to have acquired the infection from a blood transfusion in the past. Though hypercalcemia occurs in 70% cases, hypercalcemic crisis is extremely rare [9]. Hypercalcemic crisis is characterized by serum calcium >14 mg/dL, oliguria, altered mentation and can cause paralytic ileus. After extensive literature search, we could find no reports of ATLL presenting with paralytic ileus.

Several mechanisms have been proposed for hypercalcemia in ATLL, the most prominent being Interleukin 1 (IL-1), Transforming growth factor β (TGF- β) and parathormone-related protein (PTHrP). PTHrP, overexpressed in ATLL cells, causes bone resorption by osteoclast stimulation. Tax phosphoprotein of HTLV-1 upregulates PTHrP gene expression *in vitro* and transactivates the PTHrP promoter [10]. However PTHrP is not always the major mediator. ATLL cells induce the differentiation of the hematopoietic precursor cells to osteoclasts through the RANK ligand expressed on their surface and cause hypercalcemia [11]. The aggressive ATLL has a poor prognosis because of the multidrug resistance of malignant cells, large tumor burden, multiorgan failure, hypercalcemia and infections. The median survival is <1 year.

Strongyloidiasis is found to be associated with ATLL. The altered cytokine milieu may predispose to strongyloidiasis. On the other hand a strongyloides antigen may result in the development of ATLL due to the potent polyclonal T cell mitogenic response and reactivation of HTLV-1 expression [12]. Hence a search for strongyloidiasis is warranted in all cases of ATLL.

In conclusion, hypercalcemic crisis is a rare but potentially fatal complication of ATLL. It can present with paralytic ileus. The prognosis is poor despite aggressive treatment.

Acknowledgement

Our pathologist, Dr Kavitha Ravi, Department of Pathology, Medical College, Thiruvananthapuram.

References

- Poiesz BJ, Ruscetti FW, Reitz MS, et al. Isolation of a new type C retrovirus (HTLV) in primary uncultured cells of a patient with Sézary T-cell leukaemia. *Nature* 1981;**294**:268–271.
- Proietti FA, Carneiro-Proietti AB, Catalan-Soares BC, Murphy EL. Global epidemiology of HTLV-I infection and associated diseases. *Oncogene* 2005;**24**:6058-6068.
- Kumar H, Gupta PK. Is seroprevalence of HTLV-I/II among blood donors in India relevant? *Indian J Pathol Microbiol* 2006;**49**:532-534.
- Hirata M, Hayashi J, Noguchi A, et al. The Effects of Breastfeeding and Presence of Antibody to p40tax Protein of Human T Cell Lymphotropic Virus Type-I on Mother to Child Transmission. *Int J Epidemiol* 1992;**21**:989-994.
- Ratner L. Pathogenesis and treatment of human T-cell leukaemia virus infection. *Immunol Res* 2005;**32**:217-223.
- Ohshima K, Jaffe ES, Kikuchi M. Adult T-cell leukaemia/lymphoma. In: Swerdlow SH, Campo E, Harris NL, Jaffe ES, Pileri SA, Stein H, Thiele J, Vardiman JW (eds). WHO Classification of Tumours of Haematopoietic and Lymphoid Tissues. IARC: Lyon 2008, pp. 281-284.
- Ratner L. Adult T cell leukaemia lymphoma. *Front Biosci* 2004;**1**:2852-2859.
- Van Zaanen HC, Pegels JG. Adult T-cell leukaemia and lymphoma: report of two cases and a brief review of the literature. *Neth J Med* 2002;**60**:330-333.
- Edwards C, Edwards S, Bhumbra R, Chowdhary T. Severe refractory hypercalcaemia in HTLV-1 infection. *J R Soc Med* 2003;**96**:126-127.
- Senba M, Kawai K, Mori N. Pathogenesis of Metastatic Calcification and Acute Pancreatitis in Adult T-Cell Leukaemia under hypercalcemic State. *Leuk Res Treat* 2012; Article ID 128617.
- Nosaka T, Miyamoto T, Sakai H, et al. Mechanism of hypercalcemia in adult T-cell leukaemia: over expression of receptor activator of nuclear factor kb ligand on adult T-cell leukaemia cells. *Blood* 2002;**99**:634-640.
- Gabet AS, Mortreux F, Talarmin A, et al. High circulating proviral load with oligoclonal expansion of HTLV-1 bearing T cells in HTLV-1 carriers with strongyloidiasis. *Oncogene* 2000;**19**:4954-4960.