

Unilateral pathology associated with bilateral etiologies

SHANTANU CHOUDHARI, GOWRI PENDYALA, ASHISH RAURALE, SAURABH JOSHI

Abstract

Hormonal fluctuations affect not only a woman's reproductive system but surprisingly they have a strong influence on the oral cavity also. These changes are not necessarily the result of direct hormonal action on the tissue, but are perhaps best explained as the effects of the local factors (e.g. plaque on tissues exacerbated by hormonal activity). One such case of pubertal induced gingival enlargement associated with chronic generalized periodontitis caused by the combined influence of hormones and the habit of unilateral mastication is presented here. A 14-year-old girl reported with a complaint of swollen gums in the right maxillary and mandibular arches of the mouth since 2 years. The patient also had the habit of unilateral mastication (left side) since childhood which was revealed upon history. Amelioration of the gingival inflammation and the periodontal attachment loss was obtained through conventional periodontal therapy, including plaque control, scaling, root planing, and surgical removal of the soft tissue using Modified Widman Flap and bone grafting. Postoperative follow-up did not show any signs of recurrence. Pubertal induced gingival enlargement with unilateral masticatory habit needs early removal of enlargement to prevent further bone loss.

Keywords: Bone loss, gingival enlargement, hormones, plaque, puberty, unilateral mastication

Introduction

Gingival diseases are a diverse family of complex and distinct pathological entities found within the gingival, which are the result of a variety of etiologies. Gingival enlargement or overgrowth is one of the most important clinical features of gingival pathology.^[1] Gingival hyperplasia due to the concomitant unesthetic appearance and the formation of new niches for the periopathogenic bacteria is considered as a serious adverse reaction.^[2] Several types of gingival enlargement that differ from common lesions have been classified according to etiologic factors and histopathologic findings.

The homeostasis of the periodontium involves complex multifactorial relationships in which the endocrine system plays an important role. Hormones are specific regulatory molecules that modulate reproduction, growth, and development, and maintain internal environment.^[3]

Department of Periodontology, Rural Dental College, Loni, Rahata, Ahmednagar, Maharashtra, India

Correspondence: Dr. Gowri Pendyala, Department of Periodontology, Rural Dental College, Loni, Rahata, Ahmednagar, Maharashtra, India. E-mail: gowri.pendyala@gmail.com

Access this article online	
Quick Response Code: 	Website: www.contempclindent.org
	DOI: 10.4103/0976-237X.91812

Sex steroid hormones have potent effects on the nervous and cardiovascular system, and on the major determinants of the development and integrity of the skeleton and oral cavity, including periodontal tissues. The currently accepted periodontal disease classification recognizes the influence of endogenously produced sex hormones on the periodontium.^[3]

Under the broad category of dental plaque induced gingival diseases that are modified by systemic factors, those associated with the endocrine system are classified as puberty, menstrual cycle, and pregnancy associated gingivitis.^[3]

Puberty is not a single episode, but a complex process of endocrinologic events that produce changes in the physical appearance and behavior of adolescents. The incidence and severity of gingivitis in adolescents are influenced by a variety of factors, including plaque levels, dental caries, mouth breathing, crowding of the teeth, and tooth eruption. There is an increase in gingival inflammation in circumpubertal age individuals of both sexes, without a concomitant increase in plaque levels.^[4]

Here, we present a unique case report of pubertal induced gingival enlargement associated with chronic generalized periodontitis caused by the combined influence of hormones and habit of unilateral mastication.

Case Report

A 14-year-old girl reported to the Department of Pedodontics, Rural Dental College, Loni, with a complaint of swollen gums in the right maxillary and mandibular arches of the mouth since 2 years. The swelling caused difficulties in speech and

mastication, and also it had obvious implications for her esthetic appearance. She reported that the enlargement had begun at around the time of puberty, with a slow progression. Also, the habit of unilateral mastication (left side) since childhood was revealed upon history.

Her family history was unremarkable. There were no relevant findings in her medical history, and she was not taking any regular medication that could have induced gingival enlargement.

Intraoral examination revealed a diffuse enlargement extending from distal aspect of #11 to distal aspect of #17 and from distal aspect of #41 to distal aspect of #47 [Figure 1a].

The gingival enlargement was confined to the marginal and interdental gingiva of anteriors, while it involved marginal, interdental, and attached gingiva of posterior teeth of the first and fourth quadrants.

Gingival enlargement extended upto the occlusal surface,

covering the entire crowns from #14 to #17 in the maxillary arch and from #44 to #47 in the mandibular arch [Gingival Overgrowth Index] = 3 according to Angelopoulos and Goaz index). Both buccal and palatal/lingual gingiva were involved [Figures 1b and c]. The left side of the oral cavity was unaffected.

The gingiva was reddish pink, edematous, soft, friable, and had a shiny surface. Bleeding from the gingival pockets occurred easily on probing. Local factors (plaque and calculus) were present.

Mean probing depth of 6–7 mm and mean loss of attachment of 4–5 mm were recorded in both arches. Panoramic radiograph revealed horizontal type of bone loss extending in both arches and also an angular defect was appreciated radiographically between #16 and #15 interproximally [Figure 2].

Laboratory tests included complete hemogram which showed all blood cell counts within normal limits. Blood sugar (fasting and postprandial levels) were also in normal limits. These observations correlated with absence of any history of systemic disease.

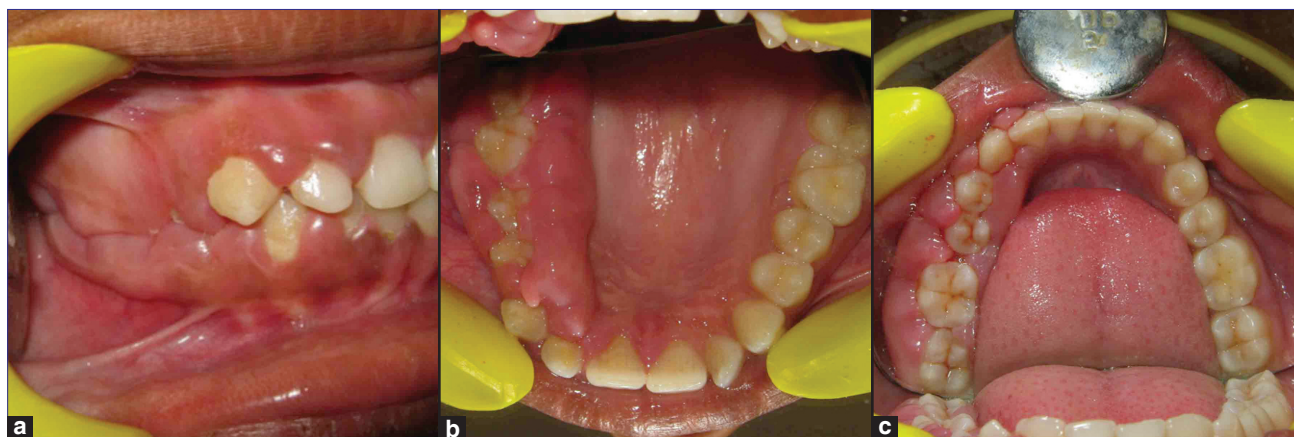


Figure 1: (a-c) Preoperative photograph

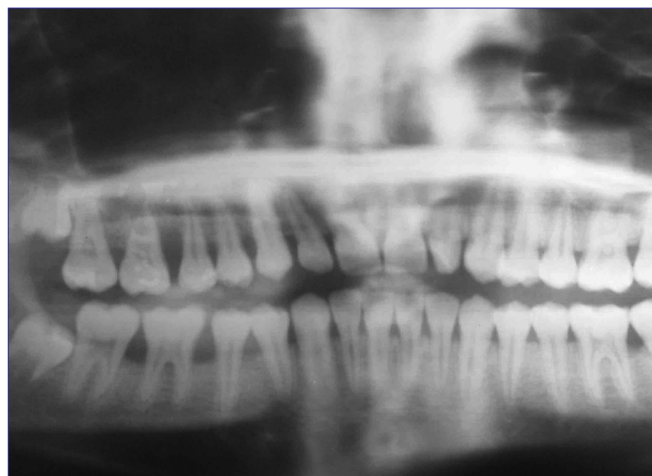

Figure 2: Radiographic picture

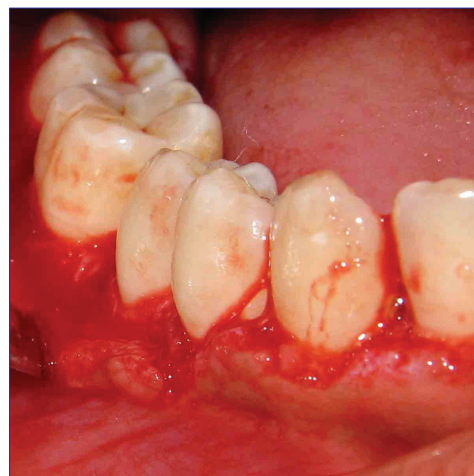


Figure 3: Modified widman flap surgery

An excised sample of the gingival tissues was submitted for histopathologic examination with H/E stain. Histopathologically, parakeratinized stratified squamous epithelium with densely arranged collagen fibers in the underlying connective tissue was seen. Marked inflammatory edema and the predominance of lymphocytes, in addition to other inflammatory cells, were observed [Figure 3].

Thus, after evaluation of clinical, radiographic, and histopathologic data, and since the gingival enlargement was initiated at around puberty, a diagnosis of puberty influenced gingival enlargement associated with chronic generalized periodontitis was made.

Treatment

The patient initially underwent phase I periodontal therapy that comprised scaling and root planing, and oral hygiene instructions. The patient was also instructed to masticate bilaterally.

After 15 days, gingival inflammation subsided, but residual fibrotic enlargement persisted which restricted plaque removal.

Phase II therapy consisted of Modified Widman flap surgical procedure which was performed for the maxillary and mandibular arches of the right side of oral cavity. The surgical intervention was carried out under local anesthesia using internal or reverse bevel and crevicular incisions to remove the residual fibrotic increments of hyperplastic tissues [Figure 4]. Local deposits were found on elevation of the flap.

A two-walled angular defect (crater) was detected interproximally between #15 and #16. Bone grafting using OSSIFI (hydroxyapatite and beta tricalcium phosphate); [Equinox Medical Technologies –Netherlands] was performed for regenerative purposes in the crater.

The patient was prescribed an antibiotic for 24 hours before the surgery and 5 days postoperatively (Amoxicillin 250 mg + Metronidazole 200 mg, three times a day) and an analgesic for 3 days postoperatively (Diclofenac sodium 50 mg, twice a day) to relieve postoperative pain. Sutures (3-0, silk) and a periodontal dressing (Coe-Pak; GC America Alsip, Illinois, U.S.A) were placed and removed after 1 week.

Periodontal maintenance phase (performed at monthly intervals) comprised hand and ultrasonic scaling and reinforcement of instructions to chew bilaterally.

There was no recurrence of gingival enlargement until 1 year later [Figure 5]. Probing pocket depth of 2–3 mm was achieved (improvement of 4–5 mm) while there was a relative clinical gain of attachment. There was also improvement seen in the attachment levels which was evident radiographically.

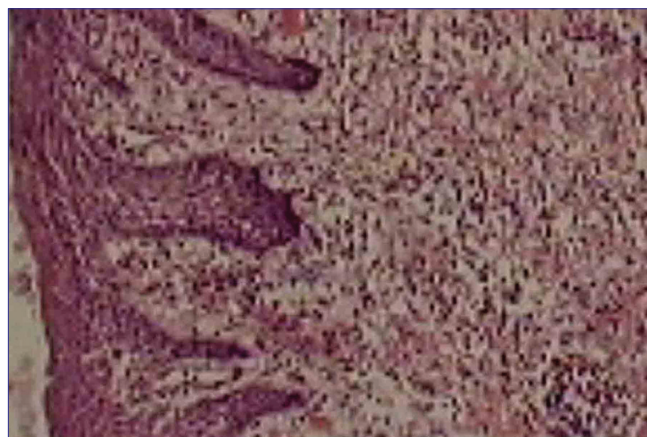

Figure 4: Histopathological picture

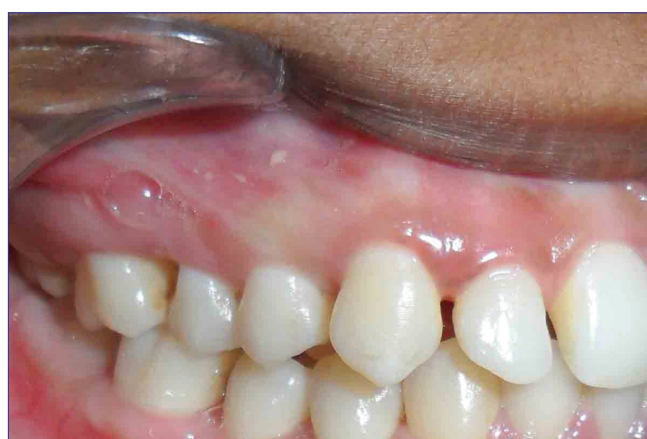

Figure 5: Post operative photograph

Discussion

Sex hormones originating from the adrenal glands supposedly play an important part in the pubertal maturation processes (Sizonenko 1975). Although it is generally accepted that skeletal maturity is under endocrinologic control, the details of mechanisms of action and clinical influence of sex hormones are still unknown.^[5]

The gingiva acts as a target tissue for the action of sex steroid hormones. The interaction of these hormones with inflammatory mediators explains the inflammation in puberty.^[6]

In our case, the gingival enlargement coincided with the onset of puberty. Puberty is a known modifying factor as it has the potential to modify the following:^[4]

1. Susceptibility to disease
2. Plaque microbiota
3. Clinical presentation of periodontal disease
4. Disease progression
5. Response to treatment

Unilateral masticatory habit usually leads to accumulation of plaque and calculus on the contralateral side, leading to tooth decay and periodontitis.

This patient demonstrated gingival enlargement with the clinical features of the enlarged gingiva, and it being smooth, friable, and edematous. Moderate pockets associated with attachment loss were generalized in the first and fourth quadrants. Generalized alveolar bone loss was present radiographically in the same region. Histopathologically, intense edema and inflammatory cell infiltration was seen, indicative of inflammatory pathology of gingiva.

In our 14-year-old patient, it would appear that unilateral mastication led to plaque accumulation on the contralateral side. Local plaque irritation modified by puberty had produced the gingival enlargement which then deepened the gingival pockets. Such a condition may have allowed sub-gingival peri-odontopathic bacteria, including *Bacteroides. gingivalis*, to colonize and proliferate, and the alveolar bone loss might then have advanced. Periodontal treatment prevented further loss of the alveolar bone.

The present case was unique as it depicts an unusual condition of two independent disease entities due to submergence of inter-related factors.

Conclusion

Hormonal changes during puberty might result in gingival enlargement for which other local factors may play a significant role. The resulting difficulty in mastication due to gingival enlargement needs the removal of the enlargement at the earliest evidence to prevent further bone loss.

References

1. Bittencourt LP, Campos V, Moliterno LF, Ribeiro DP, Sampaio RK. Hereditary gingival fibromatosis: review of the literature and a case report. *Quintessence Int* 2000;31:415-8.
2. Takada K, Sugiyama H, Umezawa K, Mega J, Hirasawa M. The subgingival microflora in phenytoin-induced gingival hyperplasia. *J Periodontol Res* 2003;38:477-81.
3. Armitage GC. Development of a classification system for periodontal diseases and conditions. *Ann Periodontol* 1999;4:1-6.
4. Mascarenhas P, Gapski R, Al-Shammari K, Wang HL. Influence of sex hormones on the periodontium. *J Clin Periodontol* 2003;30:671-81.
5. Mariotti A. Sex steroid hormones and cell dynamics in the periodontium. *Crit Rev Oral Biol Med* 1994;5:27-53.
6. Amar S, Chung KM. Influence of hormonal variation on the periodontium in women. *Periodontol* 1994;6:79-87.

How to cite this article: Choudhari S, Pendyala G, Raurale A, Joshi S. Unilateral pathology associated with bilateral etiologies. *Contemp Clin Dent* 2011;2:394-7.

Source of Support: Nil. **Conflict of Interest:** None declared.