

Unusual presentation of hydatid cyst - ruptured intraventricular hydatid

Sneha H Thakur, Priscilla C Joshi, AB Kelkar, N Seth

Department of Radiodiagnosis, Bharati Vidyapeeth Deemed Medical College, Pune, Maharashtra, India

Correspondence: Dr. Sneha Thakur, Department of Radiodiagnosis, Bharati Vidyapeeth Deemed Medical College, Pune, Maharashtra, India.
E-mail: snehaht86@gmail.com

Abstract

Echinococcosis in humans occurs as a result of infection by the larval stages of taenid cestodes of the genus *Echinococcus*. Most of the intracranial hydatids develop in brain parenchyma. Hydatid cyst within the cerebral ventricle is quite unusual. Literature review showed few case reports of childhood as well as adult intraventricular hydatid cysts. None of these cases presented for the first time with features of ruptured intraventricular cyst. This is a very rare presentation of a common disease. The possibility of infestation with *E. granulosus* should be included in the differential diagnosis of raised intracranial tension in patients reporting from endemic areas, because the prognosis following surgical intervention is excellent, especially in the pediatric age group.

Key words: Hydatid cyst, intraventricular, ruptured

Introduction

Hydatidosis caused by the cestode *Echinococcus granulosus* is a disease reported globally, however, it is endemic in Asia,^[1,2] the Middle East, North Africa and Australia. It is much more frequent in Mediterranean countries.^[3]

The adult taenia lives in the small intestine of carnivores such as dogs, foxes and wolves as the main host. Taenia eggs are excreted in the feces of these animals and either, directly or by contamination of plants, fruits, or vegetables, enters the gut of herbivores where the enzymes dissolve the eggs and the larvae are released. The parasite again enters the main host as these contaminated animals are eaten by carnivores. Man is an intermediate or accidental host of this parasite, and is infected by consuming contaminated plants or vegetables, or by contact with dogs.^[3] *Echinococcus* produce cysts that implant in different organs.

Intraventricular hydatid cyst is extremely rare. Although patients may remain asymptomatic for many years or have only mild nonspecific symptoms, they might experience life-threatening complications. Because the cyst grows very slowly, the disease is diagnosed with long delay after infection.^[3]

Case Report

A 15-year-old female child presented with a short history of frontal headache, projectile vomiting, and intermittent fever since 10 days. She deteriorated in the last 2 days and was brought with altered sensorium to our hospital. No signs of meningism were seen. A provisional clinical diagnosis of meningoencephalitis was made. Her general condition rapidly deteriorated with worsening sensorium, which needed intubation and ventilatory support.

This is an open access article distributed under the terms of the Creative Commons Attribution-NonCommercial-ShareAlike 3.0 License, which allows others to remix, tweak, and build upon the work non-commercially, as long as the author is credited and the new creations are licensed under the identical terms.

For reprints contact: reprints@medknow.com

Cite this article as: Thakur SH, Joshi PC, Kelkar AB, Seth N. Unusual presentation of hydatid cyst – ruptured intraventricular hydatid. Indian J Radiol Imaging 2017;27:282-5.

Access this article online

Quick Response Code:



Website:
www.ijri.org

DOI:
10.4103/ijri.IJRI_70_16

Emergency computed tomography (CT) of the brain [Figure 1] revealed a nonenhancing lesion having a tiny speck of calcification in the body of right lateral ventricle. Asymmetric dilatation of the right lateral ventricle was seen with an entrapped posterior body and temporal and occipital horns. Midbrain compression was also noted. A provisional diagnosis of intraventricular cystic lesion was made and magnetic resonance imaging (MRI) was suggested.

MRI revealed multiple spherical lesions of varying sizes and varying signal intensity predominantly in the posterior body and temporal horn of the right lateral ventricle [Figures 2 and 3]. Dilatation of the posterior body and occipital and temporal horns of the right lateral ventricle was noted. The temporal horn was seen descending through the tentorial hiatus into the quadrigeminal plate cistern compressing the midbrain. The 4th ventricle was normal. Although very rare, diagnosis of a ruptured hydatid cyst was made with daughter cysts in the right lateral ventricle causing ventricular "trapping."

Because the patient had an acute onset of symptoms and imaging revealed an entrapped right lateral ventricle with tentorial herniation, she was taken up for emergency surgery.

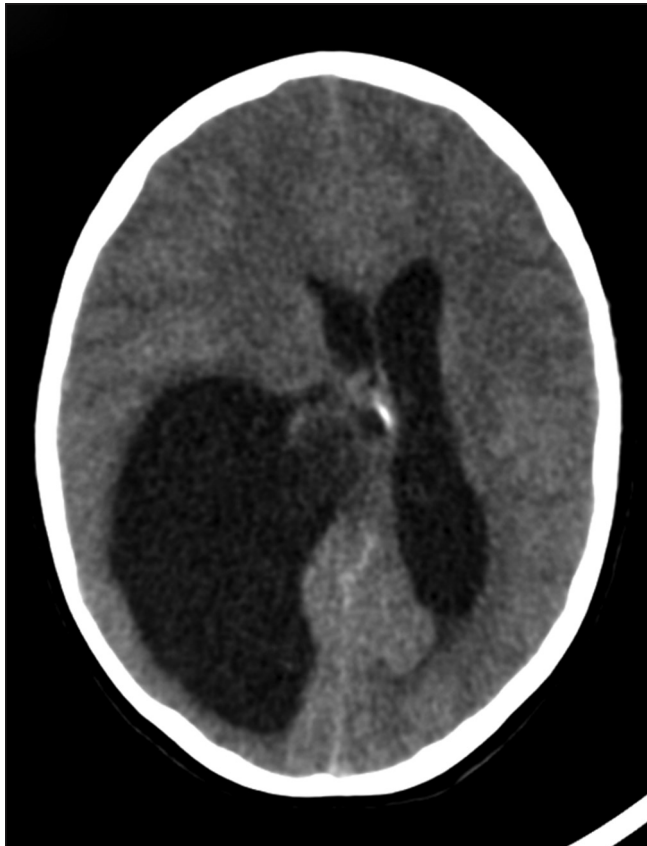

Figure 1: CT reveals a lesion having a tiny speck of calcification in the body of right lateral ventricle. Asymmetric dilatation of the ipsilateral lateral ventricle is seen with an entrapped posterior body

A right parietal craniotomy was done. The temporal horn was accessed and the cystic mass was removed successfully by gentle irrigation of the cleavage plane between the cyst wall and the ventricular interface with saline. After cyst removal, the ventricle was irrigated several times with 3% hypertonic saline. Ventricular drains were inserted.

Gross pathology demonstrated pearly white cystic lesions of varying sizes, containing clear fluid. Culture sensitivity revealed cysts with brood capsules with protoscolices. Histopathology revealed pieces of hooklets and inner layer of cyst wall, which was consistent with our diagnosis [Figure 4A and B].

Postoperatively prior to extubation a repeat MRI was done [Figure 5], which revealed complete clearance of the cysts. Her postoperative course was uneventful, and she was discharged 10 days after surgery. The patient was continued on anthelmintic albendazole.

Discussion

Echinococcosis is also known as hydatidosis or hydatid disease. Six species have been recognized, four of which are of public health concern.^[4] Hydatid disease is commonly caused by the parasite *E. granulosus*.

It is a zoonosis in which the primary host is a dog and other carnivores and sheep are the intermediate host, whereas humans are the accidental/intermediate host who do not complete the life-cycle of the parasite. Humans become infected by the ingestion of food or milk or water contaminated by dog feces containing the ova of the parasite.

The greatest prevalence of cystic echinococcosis in human and animal hosts is found in countries of the temperate zones. Intracranial hydatid disease is rare, with reported incidence of 1–2% of all cases with hydatid disease;^[2,5] cerebral involvement is more common in children.

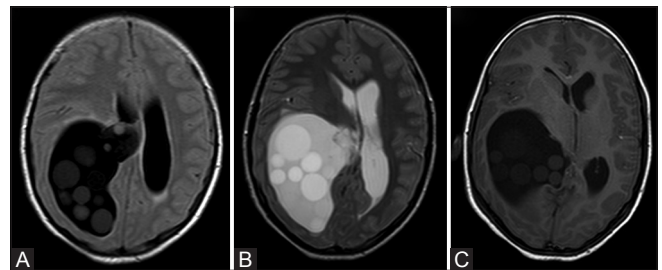


Figure 2 (A-C): (A and B) FLAIR and T2 axial images at the level of body of lateral ventricles. The multiple varying sized lesions in the temporal and occipital horn are well depicted. The lesions appear brighter than CSF on all sequences. And are well seen on the FLAIR images. (C) T1W axial section at slightly lower level at the thalamus revealing similar findings

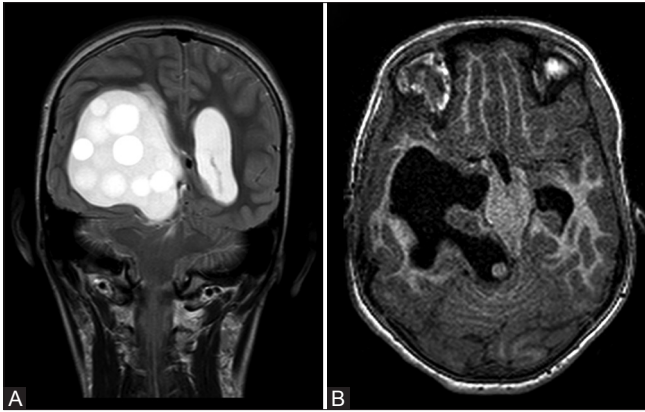


Figure 3 (A and B): (A) T2 Coronal image at the level of occipital horns, depicting multiple round lesions of varying sizes, appearing brighter than CSF, in the right lateral ventricle. The temporal horn is seen descending through the tentorial hiatus. (B) 3D T1 image at the level of midbrain showing the severe mass effect. The herniated temporal horn having a small hyperintense cyst is also seen

The incidence of intracranial hydatid in India is 0.2%, and is endemic in the Kurnool district of Andhra Pradesh, Madurai district of Tamil Nadu and Punjab.^[6]

The typical cerebral hydatid cyst presents as a well-defined solitary cystic lesion in the usually intraparenchymal and supratentorial compartment in the middle cerebral artery territory especially in the parietal lobes, although they can be seen in any location including the skull vault, extradural compartment, intraventricular, over the meningeal surface, posterior fossa and brainstem.^[5,7]

The cerebral hydatid cysts are usually slow growing; the growth rate has been variably reported between 1.5 and 10 cm/year.^[8,9] They may reach a considerable size before the patient becomes symptomatic. As a rule, the hydatid cyst of the brain tends to be solitary and spherical.^[10] Intracranial hydatid cysts may also be classified as primary or secondary.^[11] Primary intracranial hydatid infection is caused by embryos bypassing hepatic and pulmonary barriers and occur as a result of direct infestation of the larvae in the brain without demonstrable involvement of other organs. These are the most common types and are solitary. Secondary cysts are usually multiple which may follow embolization of the ruptured cardiac cyst or spontaneous, traumatic, and surgical rupture of a primary cyst in other organs. They lack brood capsule and scolices.^[12]

It is commonly thought that *E. granulosus* lesions in the central nervous system are typically secondary, however, a number of studies have indicated that brain and vertebral involvement may more frequently be primary.^[13,14] It is proposed that the high rates of secondary involvement reported previously may have been due to delayed diagnosis and insufficient treatment during the pre-CT

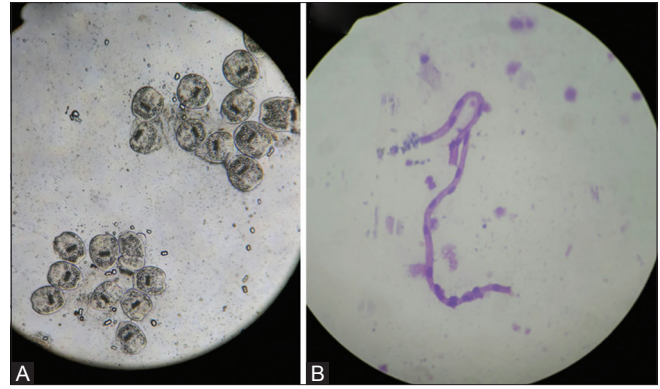


Figure 4 (A and B): (A) Wet mount of the cyst and fluid. (B) Histopathology slide showing pieces of hooklets and inner layer of cyst wall

era.^[13] The case we present supports this view in that no evidence of any other organ involvement was found by imaging studies or laboratory tests.

Patients with intracranial hydatids usually present with nonspecific signs and symptoms, most common ones being a headache, papilledema, vomiting, and symptoms of raised intracranial pressure due to interference with pathway of cerebrospinal fluid can be seen.^[15-17] Focal symptoms usually depend on the site and size of the lesion.

Our patient showed multiple well-defined round intraventricular lesions of varying signal intensity, few of which were bright on T1, not showing signal loss on the fat suppressed images or blooming on the gradient echo images. These cysts were thought to contain proteinaceous fluid. No enhancement was seen excluding other infective/parasitic as well as other cystic and neoplastic lesions. A hypointense capsule seen in the body of the right lateral ventricle on T2-weighted images prompted diagnosis of intraventricular hydatid. The capsule showed a break in continuity-suggestive of a ruptured cyst. The presence of daughter cysts on MRI is one of the rare but pathognomonic features.^[17] It is likely that the hydatid cyst was present in the lateral ventricle for a long time and its spontaneous rupture made the patient symptomatic.

We reviewed the literature and came across few case reports on intraventricular hydatid cysts in adults as well as children. All these cases presented with varying manifestations of raised ICT,^[1] however, none of them presented with rupture liberating the daughter cysts in the lateral ventricle. Furthermore, previously reported cases demonstrated few cysts in the ventricles, however, our case report highlights existence and successful surgical clearance of multiple daughter cysts from lateral ventricle with uneventful postoperative course. This highlights the importance of having high clinical suspicion as the prognosis following surgical intervention is good.

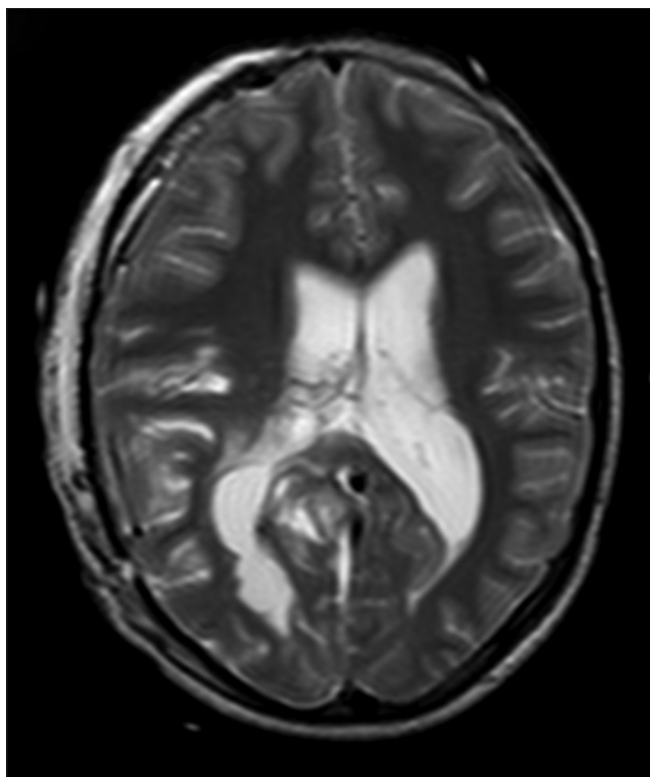


Figure 5: Post operative T2 axial MRI revealing clearance of the cysts

It is known that human parasitic zoonoses sometimes cause diagnostic and therapeutic problems more so when located at atypical sites. Despite newly developed neuroradiologic and serologic methods, these entities are rarely diagnosed preoperatively.^[5]

Preoperative diagnosis of intraparenchymal hydatid cysts can be made by CT and confirmed by an MRI scan. Other investigations such as ultrasonography of the abdomen and pelvis, echocardiography and X-ray chest are necessary to differentiate primary and secondary hydatid cysts.

Surgically, intact cyst excision is the ideal treatment. Medical treatment with albendazole seems to be beneficial both pre and postoperatively. In an unruptured cyst, pericystic hydraulic method (Dowling–Orlando technique) gives better results in removing these cysts intact.^[7] The definitive diagnosis can be made by histopathologic examination.

Conclusion

Intraventricular hydatid cysts although rare can prove to be dangerous if not diagnosed and treated earlier. Slow growth rate and appearance of symptoms in later stage of the disease adds to the morbidity and mortality. Therefore, keeping high index of suspicion in a person residing or hailing from endemic area is important for a correct preoperative diagnosis. Imaging techniques and

histopathology aid to reach a correct diagnosis. Preventing infection in humans depends on the education to improve hygiene and sanitation.^[1]

Financial support and sponsorship

Nil.

Conflicts of interest

There are no conflicts of interest.

References

- Pandey S, Pandey D, Shende N, Sahu A, Sharma V. Cerebral intraventricular echinococcosis in an adult. *Surg Neurol Int* 2015;6:138.
- Kamath SM, Mysorekar VV, Rao SG, Varma RG. Intraventricular hydatid cyst in a child. *Indian J Pathol Microbiol* 2009;52:571-2.
- Mirzaie A, Erfanian-Taghvaei MR, Mirzaie M, Sharifi-Noghabi R. Interventricular septum hydatid cyst: successful seven-year follow up- case report. *Iranian Journal of public health* 2014;43:1295-8.
- Rumboldt Z, Jednacak H, Talan-Hranilović J, Rumboldt T, Kalousek M. Unusual appearance of cisternal hydatid cyst. *AJNR Am J Neuroradiology* 2003;24:112-4.
- Dharker SR. Hydatid disease. In: Ramamurthi B, Tandon PN, editors. *Text Book of Neurosurgery*. 2nd ed. New Delhi: Churchill Livingstone; 1996. pp. 535-44.
- Miabi Wani RA, Wani I, Malik AA, Parray FQ, Wani AA, Dar AM. Hydatid disease at unusual sites. *Int J Case Rep Images* 2012;3:1-6.
- Pasaoglu A, Orhon C, Akdemir H. Multiple primary hydatid cysts of the brain. *Turk J Pediatr* 1989;31:57-61.
- Sierra J, Oviedo J, Berthier M, Leiguarda R. Growth rate of secondary hydatid cysts of the brain. *Case report. J Neurosurg* 1985;62:781-2.
- Abbassioun K, Amirjamshidi A. Diagnosis and management of hydatid cyst of the central nervous system: Part 1: General considerations and hydatid disease of the brain. *Neurosurg Q* 2001;11:1-9.
- Miabi Z, Hashemi H, Ghaffarpour M. Clinicoradiological findings and treatment outcome in patients with intracranial hydatid cyst. *Acta Med Iran* 2005;43:359-64.
- Sharma V, Sharma A, Sharma M, Sharma A, Khajuria A. Primary intracranial multiple hydatid cysts in adult. *Int J Med Public Health* 2015;5:247-9.
- Tsitouridis J, Dimitriadis AS. CT and MRI in vertebral hydatid disease. *Eur Radiol* 1997;7:1207-10.
- Onal C, Unal F, Barlas O, Izgi N, Hepgul K, Turantan MI, *et al.* Long-term follow-up and results of thirty pediatric intracranial hydatid cysts: Half a century of experience in the Department of Neurosurgery of the School of Medicine at the University of Istanbul (1952–2001). *Pediatr Neurosurg* 2001;35:72-81.
- Beskonakli E, Cayli S, Yalçınlar Y. Primary intracranial extradural hydatid cyst extending above and below the tentorium. *Br J Neurosurg* 1996;10:315-6.
- Bükte Y, Kemaloglu S, Nazaroglu H, Ozkan U, Ceviz A, Simsek M. Cerebral hydatid disease: CT and MR imaging findings. *Swiss Med Wkly* 2004;134:459-67.
- Khalidi M, Mohamed S, Kallel J, Khouja N. Brain hydatidosis: Report on 117 cases. *Childs Nerv Syst* 2000;16:765-9.
- Vidhate MR, Singh D, Sharma P, Singh MK. Cerebral hydatid cyst showing pathognomonic daughter cysts. *Ann Indian Acad Neurol* 2011;14:217-8.