

Case report

Open Access

## Intrauterine pregnancy following low-dose gonadotropin ovulation induction and direct intraperitoneal insemination for severe cervical stenosis

E Scott Sills\*<sup>1,2</sup> and Gianpiero D Palermo<sup>3</sup>

Address: <sup>1</sup>Georgia Reproductive Specialists LLC; Atlanta, Georgia USA, <sup>2</sup>Division of Reproductive Endocrinology and Infertility, Department of Obstetrics and Gynecology, Atlanta Medical Center; Atlanta, Georgia USA and <sup>3</sup>Cornell Institute for Reproductive Medicine, Weill Medical College of Cornell University; New York, New York USA

E-mail: E Sills\* - dr.sills@ivf.com; Gianpiero D Palermo - gdpalerm@med.cornell.edu

\*Corresponding author

Published: 26 November 2002

Received: 25 September 2002

*BMC Pregnancy and Childbirth* 2002, **2**:9

Accepted: 26 November 2002

This article is available from: <http://www.biomedcentral.com/1471-2393/2/9>

© 2002 Sills and Palermo; licensee BioMed Central Ltd. This is an Open Access article: verbatim copying and redistribution of this article are permitted in all media for any purpose, provided this notice is preserved along with the article's original URL.

**Keywords:** cervical factor infertility, intraperitoneal insemination, ovulation induction

### Abstract

**Background:** We present a case of primary infertility related to extreme cervical stenosis, a subset of cervical factor infertility which accounts for approximately 5% of all clinical infertility referrals.

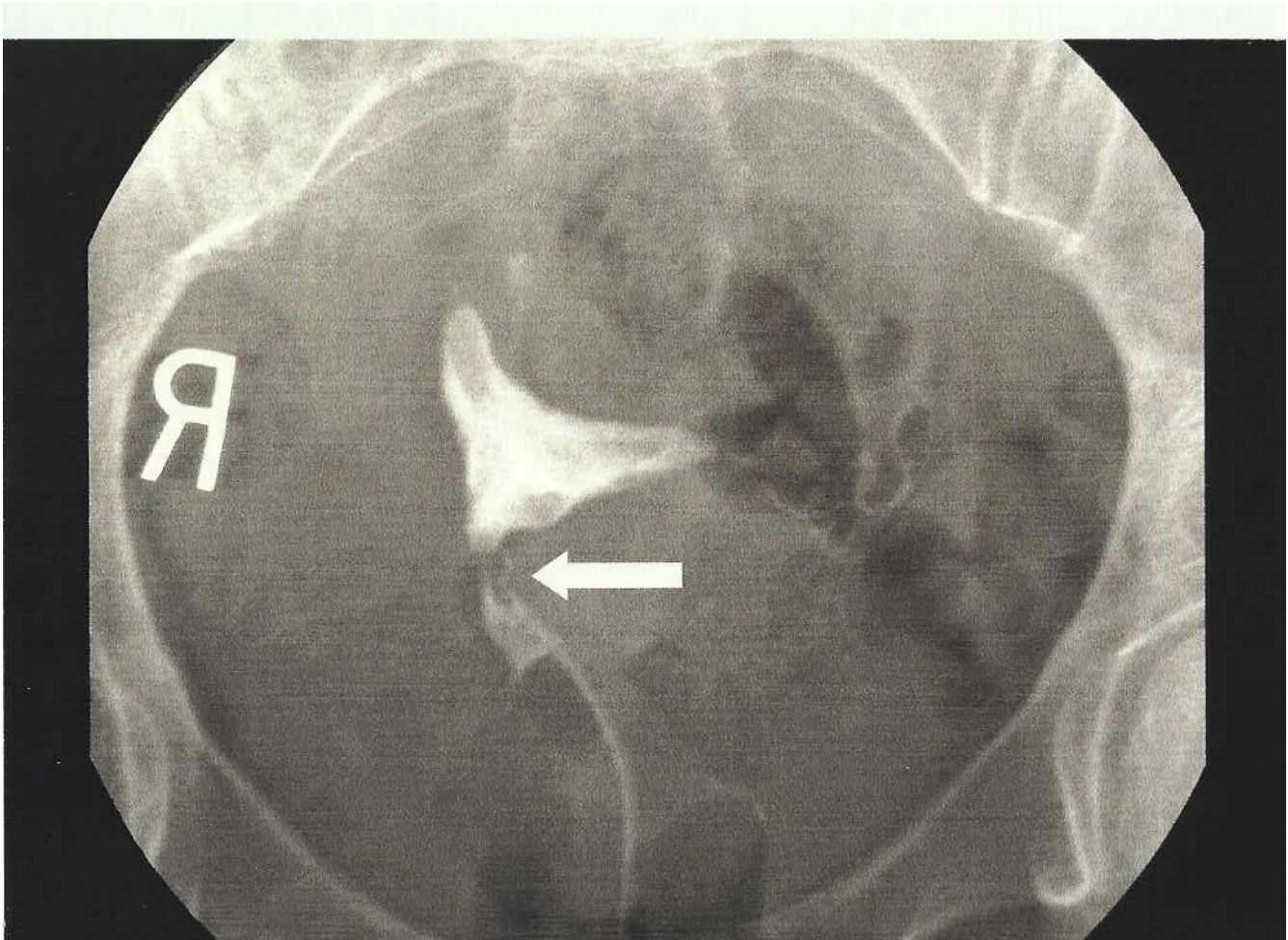
**Case presentation:** A 37 year-old nulligravida was successfully treated with ovulation induction via recombinant follicle stimulating hormone (FSH) and direct intraperitoneal insemination (IPI). Anticipating controlled ovarian hyperstimulation with in vitro fertilization/embryo transfer (IVF), the patient underwent hysteroscopy and cervical recanalization, but safe intrauterine access was not possible due to severe proximal cervical stricture. Hysterosalpingogram established bilateral tubal patency and confirmed an irregular cervical contour. Since the cervical canal could not be traversed, neither standard intrauterine insemination nor transcervical embryo transfer could be offered. Prepared spermatozoa were therefore placed intraperitoneally at both tubal fimbria under real-time transvaginal sonographic guidance using a 17 gage single-lumen IVF needle. Supplementary progesterone was administered as 200 mg/d lozenge (troche) plus 200 mg/d rectal suppository, maintained from the day following IPI to the 8<sup>th</sup> gestational week. A singleton intrauterine pregnancy was achieved after the second ovulation induction attempt.

**Conclusions:** In this report, we outline the relevance of cervical factor infertility to reproductive medicine practice. Additionally, our andrology evaluation, ovulation induction approach, spermatozoa preparation, and insemination technique in such cases are described.

### Background

Cervical factor infertility accounts for ~5% of all clinical infertility referrals, and common treatments for cervical stenosis include gamete or zygote intrafallopian transfer, and corrective surgical procedures designed to lyse stric-

tures responsible for stenosis. However, intrauterine insemination (IUI) is usually suggested early as an appropriate therapeutic consideration when semen parameters are normal and the suspicion for tubal pathology is low. However, should the cervical canal be tortuous or



**Figure 1**

Early fill view from hysterosalpingogram obtained from our patient with severe cervical stenosis (arrow). Extensive cervical stricture prohibited passage of insemination or embryo transfer catheters; safe transcervical instrumentation was also impossible. Bilateral tubal patency was confirmed in the subsequent images.

occluded, neither IUI nor transcervical embryo transfer (ET) after in vitro fertilization (IVF) may be technically feasible. While such anatomical challenges essentially render the intrauterine compartment inaccessible from below, for selected patients direct intraperitoneal insemination (IPI) can be an effective treatment option, as described in this report.

### Case report

A 37 year-old Caucasian nulligravida and her husband presented for evaluation of primary infertility of approximately one year duration. Both were in good general health and neither were smokers. A normal Pap test was obtained eight months before presentation, and there was no history of any prior cervical cytology abnormality. The provisional diagnosis of cervical stenosis had been made based on an abnormal hysterosalpingogram (HSG) per-

formed approximately six months before referral. Although the radiograph was technically difficult because of the inability to pass the catheter fully through the cervical canal, the study was able to show a pronounced filling defect near the area of the internal cervical os (Figure 1). Fallopian tubes were patent bilaterally, and free intraperitoneal spill without peritubal loculation was documented.

Ovarian reserve was estimated as reported previously [1], with cycle day #2 serum FSH and E<sub>2</sub> measured at 7.0 mIU/ml and <32 pg/ml, respectively. All other laboratory tests were within normal limits. Andrology evaluation consisted of a semen analysis, which showed total spermatozoa concentration of 70.5 M/ml, 60% forward progression motility, and 17% normal forms morphology (1999 WHO criteria). A previous urology consultation had iden-

tified a varicocele, which was repaired without complication approximately one month before the couple presented at our center. Four months post-varicocelectomy, repeat semen analysis found total spermatozoa concentration to be 46 M/ml, 70% forward progression motility, and 3% normal forms morphology (Kruger strict criteria).

The couple elected to undergo ovulation induction followed by IUI, with the understanding that should such therapy fail, IVF with intracytoplasmic sperm injection (ICSI) would be considered [2]. Prior to either therapy however, hysteroscopy was recommended to map cervical anatomy with greater precision. Therefore, about one month after presentation, assessment of cervical and endometrial contours was attempted under general anesthesia, via 3 mm hysteroscope. However, due to extensive cervical fibrosis, instrumentation proximal to the internal cervical os was impossible and hysteroscopy was abandoned.

The defect identified at surgery was consistent with the stricture suggested on HSG, which appeared as a "D"-shaped protrusion into the cervical canal. When the patient was informed of the operative findings, she essentially decompensated and expressed suicidal ideation. The planned outpatient procedure was therefore modified to include a brief hospital stay to facilitate psychiatry consultation and formal mental status examination. She was discharged home in stable condition 14 h after hysteroscopy following psychiatric clearance for continued fertility therapy.

Follow-up consultation two weeks post-hysteroscopy included discussion of controlled ovarian hyperstimulation with gamete intrafallopian transfer [3]. IVF+ICSI, followed either by tubal embryo transfer [4] or transmyometrial embryo transfer [5] was also contemplated, as was ovulation induction with direct intraperitoneal insemination (IPI). After evaluating the risks and benefits of such therapies, the couple elected the latter option. An initial ovulation induction treatment with IPI occurred two months after the aborted hysteroscopy, but the patient did not conceive. The following month, the patient underwent a second gonadotropin ovulation induction sequence using 150 IU/d recombinant FSH (Gonal-F<sup>®</sup>, Serono Laboratories; Norwell, Massachusetts USA) plus 150 IU/d human menopausal gonadotropin (Repronex<sup>®</sup>, Ferring Pharmaceuticals; Copenhagen, Denmark), both administered subcutaneously [6]. After a six day follicular recruitment phase, there were 3 follicles with mean diameter >16 mm. Terminal serum estradiol was ~1200 pg/ml, and a 12 mm trilaminar endometrium was noted. Nonrecombinant hCG (10,000 IU; Novarel<sup>®</sup>, Ferring) was ad-

ministered subcutaneously when serum estradiol and transvaginal sonography suggested follicular maturity [7].

The patient returned 24 h after hCG injection, where informed consent was again obtained for direct IPI under real-time transvaginal sonographic guidance. On the day of insemination, the partner's semen parameters were 70 M/ml with 60% motile cells (morphology analysis not performed). The specimen was washed twice with human tubal fluid, and then layered upon a dual-density (90%/45%) gradient (PureSperm<sup>®</sup>, Nidacon International; Gothenburg, Sweden) and centrifuged at 300 g [8]. Resuspended to a volume of 10 ml, the sample was then divided into two components of 5 ml each. These two equivalent samples were injected directly into the intraperitoneal cavity (5 ml to each tubal fimbria). IPI was accomplished by 17 gage single-lumen oocyte retrieval needle (Cook IVF; Spencer, Indiana USA) passed under transvaginal sonographic guidance. No intravenous sedation was administered, but each vaginal fornix was pretreated with 1% lidocaine without epinephrine (AstraZenica Pharmaceuticals LP; Wilmington, Delaware USA) via 25 gage spinal needle. After transvaginal mucosal puncture, the proximal vagina was reexamined and good hemostasis was noted. She tolerated the procedure well and there were no complications. Luteal support commenced the day after IPI, following a 400 mg/d transmucosal protocol as described previously [9].

The patient had no menses two weeks post-procedure; she returned for pregnancy test and a serum hCG of 223 mIU/ml was registered. Two days later, the value had increased to 411 mIU/ml. One month after insemination, transvaginal sonogram revealed a single intrauterine gestational sac with mean diameter of 15 mm (5 6/7 weeks gestation). A 5 mm fetal pole (6 0/7 weeks gestation) was also seen, with embryonic cardiac activity documented by B-mode Doppler pulse sonography (rate = 124/min). The intrapartum course remains uncomplicated through the 20<sup>th</sup> gestational week.

## Discussion

While cervical factor infertility accounts for only about 5% of reproductive endocrinology consultations [10], this subset of patients nevertheless represents a clinical group where satisfactory outcomes are attainable when therapy is properly targeted. In this report, we describe the management of severe cervical stenosis in a woman with bilateral tubal patency and a normal intrauterine cavity. Although prepared to undergo IVF-ET at our facility, the couple first wanted to attempt pregnancy by a less complicated and less costly method. Unfortunately, the tight cervical canal suggested by HSG (and corroborated at hysteroscopy) represented an unexpected technical challenge frustrating their plans both for IVF and IUI.

Intraperitoneal insemination (IPI) warrants consideration in such cases of cervical stenosis where tubal patency has been confirmed, no intrauterine contour defects exist, and there is no profound male factor infertility diagnosis [11–13]. As with the more commonly performed IUI, the efficacy of IPI is directly related to the overall spermatozoa concentration, motility, and morphology [14,15]. Because tubal patency had been demonstrated radiographically in this case, we discussed laparoscopic gamete (or zygote) intrafallopian transfer as well as ovulation induction with IPI. The rationale for laparoscopy-based treatments would have been strengthened if multiple intraperitoneal inseminations had failed, yet controversy remains as to how many such unsuccessful inseminations should be performed prior to embarking on the advanced reproductive technologies [16].

How best to determine which couples would benefit most from IPI remains undecided, but our decision was influenced by semen parameters and the patient's willingness to undergo transvaginal needle punctures. Previous investigators have compared pregnancy rates after IPI and standard IUI, and found the outcomes to be roughly equivalent [16]. However, in this case the inability to attain safe instrumentation through an abnormal cervical canal sharply limited the options for fertility treatment, so IUI was not possible.

The relationship between *de novo* cervical stenosis and intrapartum events has received less study than the cervical injury attributable to ablative procedures and subsequent obstetric outcome [18]. Yet, whether or not the cervical stenosis observed in our case will be associated later with a complicated intrapartum course (perhaps mediated by impaired cervical dilation) remains to be seen and forms the basis of ongoing research.

### Conclusions

Although the anatomical challenges associated with severe cervical stenosis essentially render the intrauterine compartment inaccessible from below, for selected patients IPI represents an effective and relatively inexpensive treatment option. In the absence of fallopian tubal disease and profound male factor diagnoses, IPI may merit consideration for couples undergoing fertility treatment when cervical stenosis is encountered.

### Competing interests

None declared.

### Author's contributions

ESS carried out the ovulation induction and intraperitoneal insemination, and was responsible for initial manuscript drafts. GDP was the senior clinical consultant during the case and participated in final manuscript devel-

opment. Both authors read and approved the final manuscript.

### Acknowledgements

Written consent was obtained from the patient for publication of this report.

### References

1. Perloe M, Levy DP, Sills ES: **Strategies for ascertaining ovarian reserve among women suspected of subfertility.** *Int J Fertil Womens Med* 2000, **45**:215-224
2. Palermo GD, Neri QV, Hariprashad JJ, Davis OK, Veeck LL, Rosenwaks Z: **ICSI and its outcome.** *Semin Reprod Med* 2000, **18**:161-169
3. Rombauts L, Dear M, Breheny S, Healy DL: **Cumulative pregnancy and live birth rates after gamete intrafallopian transfer.** *Hum Reprod* 1997, **12**:1338-1342
4. Chen CD, Ho HN, Yang YS: **Tubal embryo transfer improves pregnancy rate.** *Hum Reprod* 1997, **12**:629-631
5. Anttila L, Penttila TA, Suikkari AM: **Successful pregnancy after in vitro fertilization and transmyometrial embryo transfer in a patient with congenital atresia of cervix: case report.** *Hum Reprod* 1999, **14**:1647-1649
6. Sills ES, Drewe CD, Perloe M, Kaplan CR, Tucker MJ: **Periovulatory serum human chorionic gonadotropin (hCG) concentrations following subcutaneous and intramuscular nonrecombinant hCG use during ovulation induction: a prospective, randomized trial.** *Fertil Steril* 2001, **76**:397-399
7. Sills ES, Schattman GL, Veeck LL, Liu H-C, Prasad M, Rosenwaks Z: **Characteristics of consecutive in vitro fertilization cycles among patients treated with follicle stimulating hormone (FSH) and human menopausal gonadotropin versus FSH alone.** *Fertil Steril* 1998, **69**:831-835
8. Sills ES, Wittkowski KM, Tucker MJ, Perloe M, Kaplan CR, Palermo GD: **Comparison of centrifugation- and noncentrifugation-based techniques for recovery of motile human sperm in assisted reproduction.** *Arch Androl* 2002, **48**:141-145
9. Sills ES, Perloe M, Kaplan CR, Sweitzer CL, Morton PC, Tucker MJ: **Uncomplicated pregnancy and normal singleton delivery after surgical excision of heterotopic (cornual) pregnancy following in vitro fertilization/embryo transfer.** *Arch Gynecol Obstet* 2002, **266**:181-184
10. Miller JH, Weinberg RK, Canino NL, Klein NA, Soules MR: **The pattern of infertility diagnoses in women of advanced reproductive age.** *Am J Obstet Gynecol* 1999, **181**:952-957
11. Ben Rhouma K, Ben Miled E, Ben Marzouk A, Rihani M, Bakir M: **Direct intraperitoneal insemination and controlled ovarian hyperstimulation in subfertile couples.** *J Assist Reprod Genet* 1994, **11**:189-192
12. Misao R, Itoh M, Nakanishi Y, Tamaya T: **Direct intraperitoneal insemination in ovarian hyperstimulation cycles induced with gonadotropin-releasing hormone agonist.** *Clin Exp Obstet Gynecol* 1997, **24**:133-134
13. Tiemessen CH, Bots RS, Peeters MF, Evers JL: **Direct intraperitoneal insemination compared to intrauterine insemination in superovulation cycles: a randomized cross-over study.** *Gynecol Obstet Invest* 1997, **44**:149-152
14. Barciulli F, Ricci G, Levi D'Ancona R, et al: **Our experience with direct intraperitoneal insemination (DIPI) as a treatment for infertile couples.** *Acta Eur Fertil* 1990, **21**:251-256
15. Turhan NO, Artini PG, D'Ambrogio G, Droghini F, Volpe A, Genazzani AR: **Studies on direct intraperitoneal insemination in the management of male factor, cervical factor, unexplained and immunological infertility.** *Hum Reprod* 1992, **7**:66-71
16. Le Lannou D: **Is the limitation to 6 cycles of insemination with donor sperm justified?** *Gynecol Obstet Fertil* 2002, **30**:129-132
17. Gregoriou O, Papadias C, Konidaris S, Gargaropoulos A, Kalampokas E: **A randomized comparison of intrauterine and intraperitoneal insemination in the treatment of infertility.** *Int J Gynaecol Obstet* 1993, **42**:33-36
18. Kalstone C: **Cervical stenosis in pregnancy: a complication of cryotherapy in diethylstilbestrol-exposed women.** *Am J Obstet Gynecol* 1992, **166**:502-503

### Pre-publication history

The pre-publication history for this paper can be accessed here:

<http://www.biomedcentral.com/1471-2393/2/9/prepub>

Publish with **BioMed Central** and every scientist can read your work free of charge

*"BioMed Central will be the most significant development for disseminating the results of biomedical research in our lifetime."*

Sir Paul Nurse, Cancer Research UK

Your research papers will be:

- available free of charge to the entire biomedical community
- peer reviewed and published immediately upon acceptance
- cited in PubMed and archived on PubMed Central
- yours — you keep the copyright

Submit your manuscript here:

[http://www.biomedcentral.com/info/publishing\\_adv.asp](http://www.biomedcentral.com/info/publishing_adv.asp)

