

## Bilateral pulmonary vein stenting for pulmonary vein obstruction after surgical correction of total abnormal pulmonary venous connection

**Ibrahim Cansaran Tanıdır, Pelin Ayyıldız, Erkut Öztürk, Yakup Ergül, Alper Güzeltaş**  
 Department of Pediatric Cardiology, İstanbul Mehmet Akif Ersoy Thoracic and Cardiovascular Surgery Center and Research Hospital; İstanbul-Turkey

### Introduction

Pulmonary vein stenosis (PVS), either acquired or congenital, is a rare condition that can lead to worsening pulmonary hypertension and cardiac failure in children, and it is frequently lethal. The condition is often progressive and is associated with poor survival (1, 2). Pulmonary vein stenting is an option for acute symptomatic relief and significant improvements in diameter, peak PA pressure/systemic pressure ratio, and trans-stenotic gradient (3). Here we report bilateral PVS in an 11-month-old girl after total anomalous pulmonary venous connection (TAPVC) repair who was successfully treated with bilateral stent implantation.

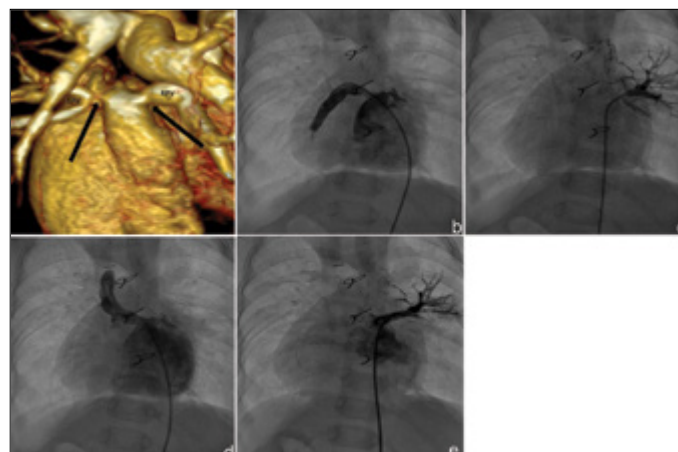
### Case Report

An 8-month-old girl weighing 6 kg was referred to our hospital for surgery. Her initial diagnoses were right atrial isomerism, dextrocardia, unbalanced complete atrioventricular septal defect, double outlet right ventricle, severe pulmonary stenosis, and supracardiac non-obstructive TAPVC. She underwent Glenn anastomosis with TAPVC repair when she was 9 months old. Two months after the surgery, she was referred to our clinic because of cyanosis, respiratory distress, hypoxia, and severe upper extremity and palpebral edema. On admission, she was gasping with bradycardia and severe metabolic acidosis. She was immediately admitted to the pediatric cardiac intensive care; endotracheal intubation and inotropic support were started. Her oxygen saturation level was in the low 70s with 100% oxygen supplement. Her echocardiography revealed pulmonary venous obstruction, Glenn dysfunction, and pulmonary hypertension. Anti-pulmonary hypertensive treatment was added to her treatment. An emergent computed tomography angiography (Fig. 1a) showed severe bilateral pulmonary venous stenosis at the junction of the collector sac and pulmonary vein.

**Table 1. Pressure gradients before and after stent implantation**

	Pre-intervention	Gradient*	Post-intervention	Gradient
PA	33/13 (mean 26)		26/19 (mean 22)	
RPV	25/23 (mean 24)	11	17/16 (mean 17)	2
LPV	34/26 (mean 27)	14	19/15 (mean 17)	2
CA	mean 13		mean 15	

\*Gradients were between the veins and atrium  
 CA - common atrium; LPV - left pulmonary vein; PA - pulmonary artery; RPV - right pulmonary vein; pressures are in mm Hg.



**Figure 1. a-e. (a) Posterior volume rendering the multiple detector computed tomography image, (b) posterior–anterior angiographic view of the right pulmonary vein, (c) posterior–anterior angiographic view of the left pulmonary vein, (d) posterior–anterior angiographic view of the right pulmonary vein after stent implantation, and (e) posterior–anterior angiographic view of the left pulmonary vein after stent implantation.**  
 LPV: left pulmonary vein; RPV: right pulmonary vein

Urgent cardiac catheterization for stenting the pulmonary veins was planned. Initially, pressure gradients were gathered (Table 1). Selective right and left pulmonary angiography and direct injection of contrast to the proximal segment of the pulmonary veins showed a narrowing at the junction of the collector sac and pulmonary veins. The narrowest parts were 4 mm and its proximal side was 7 mm on the right pulmonary vein and measurements were 1.5 mm and 4.2 mm, on the left pulmonary vein, respectively (Fig. 1b, c).

Initially, a 7 × 12-mm Palmaz Blue balloon-expandable peripheral stent (Cordis Endovascular, Warren, NJ) was placed across the stenosis on the right pulmonary vein and was dilated until the waist completely disappeared (Fig. 1d, e, Video 1). However, stenting the left pulmonary vein was more complex because it was more stenotic and the left upper and lower pulmonary veins combined together before narrowing. Placing a stent in the lower vein will jail the upper vein or vice versa. After consulting with the surgeons, a 4 × 8-mm Liberte bare coronary stent (Boston Scientific, Natick, MA) was placed across the stenosis. After stent implantation, pressure gradients across the stents dropped to normal levels (Table 1). The patient's oxygen saturation level was elevated to the low 90s. Acetylsalicylic acid, clopidogrel, and standard heparin were initiated after the procedure. She was extubated 3 days after the procedure and was discharged 12 days later. Four months after the procedure, a second catheterization was performed

to dilate both stents. The patient is still asymptomatic, and her echocardiographic examination revealed mild stenosis during her 9-month follow-up.

## Discussion

PVS in infants and children is uncommon. In majority of cases, it occurs following the surgical repair of anomalous pulmonary venous connection, although it may rarely occur as an isolated pathology. The condition is often progressive, leading to pulmonary hypertension and death. Various therapeutic strategies, including surgery and balloon dilatation, have been utilized to deal with this problem (4). Neither surgery nor transcatheter intervention has yielded satisfactory long-term results when recurrent PVS occurs (1). Also in this growing population of acquired PVS, there is no consensus on the optimal treatment approach.

Stenting pulmonary veins is preferable as the time free from re-stenosis is significantly longer than that from balloon angioplasty (3). It is reported that stent implantation is acutely effective in the focal relief of stenosis with few procedural complications. However, stent obstruction and re-intervention are common (1, 2, 5). Unfortunately, a stent implantation diameter of at least 7 mm is associated with longer freedom from re-intervention during follow-up in more than half of the patients requiring re-intervention (balloon dilatation of narrowing stents) in 1 year (1, 5). Our aim is to palliate patients till the Fontan–Kreutzer procedure and to perform both Fontan–Kreutzer palliation and pulmonary venous connection repair.

## Conclusion

PVS is a rare but life-threatening condition. Stenting the pulmonary veins seems to be an effective and a life-saving strategy in the short term.

## References

1. Balasubramanian S, Marshall AC, Gauvreau K, Peng LF, Nugent AW, Lock JE, et al. Outcomes after stent implantation for the treatment of congenital and postoperative pulmonary vein stenosis in children. *Circ Cardiovasc Interv* 2012; 5: 109-17. [\[CrossRef\]](#)
2. Waki K, Arakaki Y, Baba K. Successful release of recurrent pulmonary venous obstruction after repair of totally anomalous pulmonary venous connection by transcatheter implantation of stents. *Cardiol Young* 2006; 16: 507-9. [\[CrossRef\]](#)
3. Matsumoto T, Zahn EM, Kar S. Percutaneous pulmonary vein stenosis angioplasty complicated by rupture: successful stenting with a polytetrafluoroethylene-covered stent. *Catheter Cardiovasc Interv* 2014; 83: 292-5. [\[CrossRef\]](#)
4. Sreeram N, Emmel M, Trieschmann U, Brockmeier K, Bennink G. Pulmonary vein stents in infants and children: is there lasting benefit? *Clin Res Cardiol* 2008; 97: 463-6. [\[CrossRef\]](#)
5. Tomita H, Watanabe K, Yazaki S, Kimura K, Ono Y, Yagihara T, et al. Stent implantation and subsequent dilatation for pulmonary vein stenosis in pediatric patients: maximizing effectiveness. *Circ J* 2003; 67: 187-90. [\[CrossRef\]](#)

### Video 1. Angiography of the procedure

**Address for Correspondence:** Dr. Alper Güzeltaş  
İstanbul Mehmet Akif Ersoy Eğitim Araştırma Hastanesi  
İstasyon Mah. Turgut Özal Bulvarı No:11  
Küçükçekmece, İstanbul-Türkiye  
Phone: +90 212 692 20 00  
E-mail: [alperguzeltas@hotmail.com](mailto:alperguzeltas@hotmail.com)



©Copyright 2015 by Turkish Society of Cardiology - Available online at [www.anatoljcardiol.com](http://www.anatoljcardiol.com)  
DOI:10.5152/AnatolJCardiol.2015.6627