

Clinical examination and patients' history are not suitable for neonatal hip screening

Journal of Children's Orthopaedics
2022, Vol. 16(1) 19–26
© The Author(s) 2022
DOI: 10.1177/18632521221080472
journals.sagepub.com/home/cho

Christian Maximilian Ziegler¹, Katharina Maria Ertl¹, Maria Delius², Kai Martin Foerster³, Alexander Crispin⁶, Ferdinand Wagner^{1,4,5} , and Bernhard Heimkes⁷

Abstract

Purpose: To assess the percentage of missed developmental dysplasia of the hip, which escape the German criteria for newborn hip high-risk screening, we analyzed our data gained from the general neonatal sonographic hip screening performed at our department. The aim of the study was to determine the number of potentially belatedly treated developmental dysplasia of the hip.

Methods: The data from 1145 standardized newborn hip ultrasound examinations according to the Graf technique were analyzed retrospectively comparing findings for general neonatal sonographic hip screening and high-risk screening subgroups.

Results: We diagnosed developmental dysplasia of the hip in 18 of the 1145 newborns via ultrasound. A total of 10 out of 18 developmental dysplasia of the hip would have been missed by high-risk screening, which corresponds to a proportion of 55.6% false-negative results. The sensitivity of high-risk screening was only 44.4% and specificity, 78.3%. The positive predictive value was 3.2%. Family history as a screening criterion yielded false-negative results in 77.8% and false-positive results in 16.8%. In all, 83.3% of the children who were born with developmental dysplasia of the hip but not from breech position as a risk factor were false negative. The clinical examination was false negative in 88.9% and false positive in 0.6%.

Conclusion: High-risk screening detected less than every second developmental dysplasia of the hip, rendering the first month as the most effective treatment window unavailable for inapparent dysplastic hips, potentially resulting in the need for more invasive treatment. Due to the high sensitivity of ultrasound in the detection of developmental dysplasia of the hip, we recommend to replace the current German high-risk screening guidelines with a general newborn screening for all neonates using Graf ultrasound in the first week of life.

Level of evidence: Level II.

Keywords: Developmental dysplasia of the hip, neonatal hip screening, hip sonography, diagnosis, DDH, CDH

¹Musculoskeletal University Center Munich, Department of Orthopedics and Trauma Surgery, University Hospital, Ludwig-Maximilians-University Munich, Munich, Germany

²Department of Obstetrics and Gynecology, University Hospital, Ludwig-Maximilians-University Munich, Munich, Germany

³Department of Neonatology, Dr. von Hauner Children's Hospital, Ludwig-Maximilians-University Munich, Munich, Germany

⁴Institute of Health and Biomedical Innovation, Queensland University of Technology (QUT), Brisbane, QLD, Australia

⁵Department of Pediatric Surgery, Dr. von Hauner Children's Hospital, Ludwig-Maximilians-University Munich, Munich, Germany

⁶Institute for Medical Information Processing, Biometry and Epidemiology, Ludwig-Maximilians-University Munich, Munich, Germany

⁷Department of Pediatric Surgery, Pediatric Orthopedic Section, Klinikum Dritter Orden, Munich, Germany

Date received: 21 September 2021; accepted: 22 December 2021

Corresponding Author:

Bernhard Heimkes, Department of Pediatric Surgery, Pediatric Orthopedic Section, Klinikum Dritter Orden, Menzinger Straße 44, 80639 Munich, Germany.

Emails: info@ortho-heimkes.de; bernhard.heimkes@dritter-orden.de



Introduction

Developmental dysplasia of the hip (DDH) is one of the most frequent skeletal disorders, which occurs in 2%–4% of all newborns.^{1–4} Clinical and radiologic examination for DDH was improved by hip ultrasound (US) during the 1980s. The number of necessary surgical interventions due to this disorder decreased dramatically in countries that implemented US into their newborn hip screening.⁵ Therefore, the initiators of the screening recommended general neonatal hip sonography screening (GNHS) for all newborns within the first week of life in order to be able to start the necessary treatment as soon as possible and consequently to further reduce the number of surgical interventions.^{4,6,7}

Critics of this early screening algorithm argued that GNHS leads either to overtreatment or later to costly additional sonography.⁸ In order to improve the cost-effectiveness, they recommended screening all children at U3—a standardized mandatory general pediatric examination in Germany—scheduled between fourth and sixth week of age. To avoid delay in the treatment of severe DDH, an additional “high-risk” hip screening (HRS) was implemented aiming at children with early clinical signs, family history, or other risk factors for DDH such as intrauterine breech position and oligohydramnios.⁹ Newborns meeting these criteria should receive an early US at the third to tenth day of life (so-called U2 screening).

To assess the percentage of children with DDH who would have received delayed treatment using the current German HRS algorithm in comparison with a GNHS, we analyzed the outcomes of hip USs within the first days of life of all babies born at our neonatology department during a 1-year period

Methods

Patient collection

All infants born at the Munich University Hospital perinatal high-risk obstetrics center (Campus of the Ludwig Maximilians University) in Germany, between 1 February 2013 and 1 February 2014 were examined once at the Department of Pediatric Orthopaedics and screened for DDH during the first 10 days after delivery. Therefore, all parents were asked to present at our Department before discharge. Parents agreed to participate in the study via written informed consent. We excluded patients older than 10 days of age. In addition, we excluded data from preterm infants born before 37 weeks of gestation. The study was approved by the local ethics committee of the Ludwig Maximilians University (EthiNo.: 175-13) and conducted according to the guidelines of the Declaration of Helsinki.

Data recording

Data from a standardized clinical and sonographic examination sheet were analyzed retrospectively. Information about

the child's presentation at birth, mode of delivery, and family history regarding DDH provided by the parents was recorded. The criteria for a positive family history comprised the use of an abduction brace, treatment with Spica cast, or hip surgery during the newborn or infancy period of a close relative (sibling, parents, aunt or uncle, grandparents). Statements like “possible DDH,” “wide wrapping,” or “double diapering” were considered a negative history for DDH.

The presence of limited abduction and a positive Ortolani test as well as other clinical signs of DDH were documented on the examination sheet. In addition, the variables “normal clinical examination,” “instable hip,” “displaceable hip,” “dislocated hip,” or “limited abduction” as well as the side of the hip were recorded.

Ultrasound examination

A 7.5-MHz transducer was used in the subsequent hip sonography (Sonoline G20; Siemens, Germany). We examined all children according to the standardized protocol for US examination and diagnosis according to the Graf technique.² Measurements of the alpha and beta angles of the right and left hips and their corresponding classification of the infant hip according to Graf were recorded (Ia/b, IIa (+ >55° alpha angle), IIa (– <55° alpha angle), IIb, IIc stable, IIc unstable, D, IIIa, IIIb, IV).

In addition, the diagnoses “physiological hip maturity,” “physiological immaturity” (type IIa+ according to Graf), “dysplasia” (type IIa– <55° alpha angle or worse according to Graf and therefore requiring immediate treatment), and “dislocation” were recorded depending on the sonography findings. All children with hip types IIa (– <55° alpha angle), IIc, D, III, and IV were double-checked by a specialist for pediatric orthopedics (n=3) in order to avoid incorrect false-positive results. These specialists were certified by the national medical board as specialists for orthopedic surgeons who completed an additional 18-month training at a department of pediatric orthopedics.

Statistical analysis

For statistical analysis, we used SPSS for Windows, Version 22.0 (SPSS Inc., USA). The metric variables were calculated as mean values and medians, while the measures of variance were given as standard deviations and quartiles. The categorized or nominal data were given as absolute and relative frequency. The comparison of the results of the screening test and the diagnosis of DDH was carried out with the help of the modified chi-square test according to McNemar. The generated ROC (receiver operating characteristic) curves were used to depict the influence of sensitivity and specificity, with sensitivity being shown against the complementary specificity set to the value 1.

For the multivariate analysis, the binary logistic regression with forward inclusion was carried out using the likelihood ratio criterion (inclusion p-value ≤0.05; exclusion

p-value >0.1). A two-sided significance check was carried out for all tests, with a p-value <0.05 being regarded as statistically significant for all statistical tests.

Results

Patients' characteristics

We recorded data from a total of 1362 patients. Of these, 217 data sets were excluded so that 1145 infants (570 females (49.8%), 575 males (50.3%)) were included in the analysis. In all, 613 children (53.5%) had been delivered spontaneously, 135 by vacuum extraction, and 397 via cesarean section. In total, 1063 (93%) children presented in a cephalic presentation at birth, 58 children in the full breech position, 9 in double footling breech, 3 in single footling breech, 5 in Frank breech, and 5 in the transverse position. Thus, combined breech position totaled 6.6%. Recording of birth position was missed in two cases.

Only 16.6% of patients with DDH had a positive family history. In 46 patients (4.0%), an assessment of risk factors for DDH was not possible due to communication problems or the absence of family members during the examination. According to the statistical technique of majority voting, that allows cases with unknown values of a variable to be assigned the value of the majority of cases, these patients were labeled to have a "negative family history."

The mean alpha angle for the right hip was 63.0° and for the left hip was 64.8°; the median was 64.0° for both sides (standard deviation right $\pm 4.70^\circ$, left $\pm 4.89^\circ$). The smallest alpha angle was 34° for the right hip and 20° for the left hip, and the largest alpha angle was 78° on both sides. For the evaluation of the alpha angle, three data sets were missing for the right hip and five for the left hip.

Table 1 illustrates the distribution of hip types according to the classification of Graf. The sonographic examination of the right hip showed 74.7% mature infant hips (type Ia/b). In all, 24.3% were immature but still healthy hips (type IIa±). Hip dysplasia (types IIc–IV) accounted for a percentage of 1.0%. Similar findings resulted from the sonographic evaluation of the left hips.

Prevalence of DDH in correspondence to HRS

DDH was detected via US in 18 of a total of 1145 patients included in the evaluation, which corresponds to a prevalence of 1.6% (see Figure 1). HRS was positive in 22.1% (n=253) of the cases, and 77.9% (n=892) of the patients showed no abnormalities.

Relationship between the outcome of the HRS and the actual existence of DDH

McNemar test is a modification of the chi-square test and is used exclusively for dichotomy variables. Two dependent

Table 1. Distribution of hip types according to the classification of Graf.

	Right hips		Left hips	
	n	%	n	%
Ia/b	855	74.7	855	74.7
IIa+	278	24.2	275	24.0
IIa-	1	0.1	1	0.1
IIc	3	0.3	2	0.2
IIc stable	–	–	–	–
IIc unstable	–	–	1	0.1
D	6	0.5	8	0.7
III	2	0.2	2	0.2
IV	–	–	1	0.1
Total	1145	100	1145	100

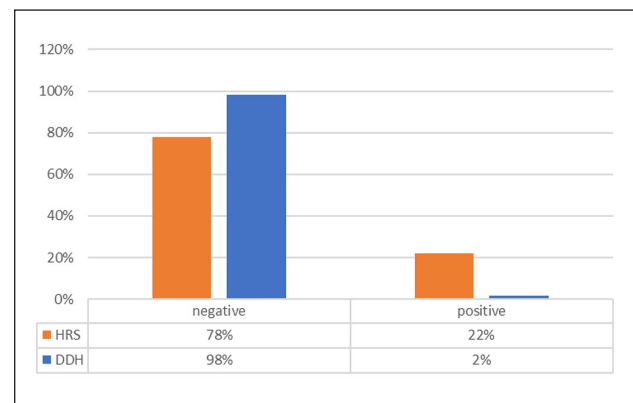


Figure 1. Depicted are the percentage of positive HRS compared with sonographically detected DDH.

variables (sonography vs HRS) determine whether there is a change in value distribution. Sonography was defined as the gold standard: a positive sonography result means that hip dysplasia is present in the hip. HRS, which summarizes the parameters of breech position, clinical examination, and positive family history, was considered as positive once one of these three criteria was present.

Table 2 shows the relationship between the outcome of the HRS and the actual existence of DDH. In 882 infants, no abnormalities were documented in HRS as well as in US (true negative, representing 78.3% of children without DDH). The number of false-positive cases in which HRS was conspicuous but no DDH was detected in US included 245 patients (representing 21.7% of children without DDH).

However, 10 out of 18 sonographically identified hip dysplasia or displacements escaped the diagnosis applying the HRS criteria (55.6% of children with DDH). These infants had no abnormalities in family anamnesis, clinical examination, or birth position, although US definitely detected the presence of DDH. Eight out of 18 hips with DDH were detected with the criteria of HRS (representing 44.4% of DDH, true positive).

Table 2. Relationship between the outcome of the HRS and the actual existence of DDH.

		HRS			
		Negative	Positive	Total	
DDH	No	n	882	245	1127
		% of DDHs	78.3	21.7	100
		% of HRS	98.9	96.8	98.4
	Yes	n	10	8	18
		% of DDHs	55.6	44.4	100
		% of HRS	1.1	3.2	1.6
Total	n	892	253	1145	
	% of DDHs	77.9	22.1	100	
	% of HRS	100	100	100	
Chi-square tests		Exact significance (two-tailed)			
McNemar test		≤0.000			
Number of valid cases		1145			

HRS: high-risk screening; DDH: dysplasia of the hip.

Postulating HRS as a reference for the presence of DDH, the following results should be mentioned: in 253 cases, a positive HRS result was obtained suggesting DDH. Among these, eight patients (3.2%) had DDH; the remaining 245 infants had no hip maturation disorder (96.8%). Of the 892 patients who had a negative HRS result, 10 patients had DDH (1.1% of cases), while 882 had an inconspicuous hip US (98.9% of cases). There are highly significant differences between the two methods (HRS vs US): more than half of the patients with DDH (55.6%) were not detected by HRS. McNemar analysis calculated a significance of $p \leq 0.000$ for this finding.

Calculation of predictive values

According to Table 3, the sensitivity of HRS (percentage of HRS-positive patients) was 44.4%. The specificity (percentage of HRS negatives of all health infants) was calculated to be 78.2%. Assuming that the prevalence in this sample reflected the general population, the calculated positive predictive value (probability of DDH with positive test result) was 3.2%. The negative predictive value (probability of non-existing DDH in the case of negative test result) was 98.9%.

ROC analysis. ROC analysis was used in order to test the reliability of HRS for the detection of DDH. With the ROC curve, the sensitivity is compared to the specificity value complementary to 1 (false-positive rate). A diagnostic value without any predictive force would result in a diagonal (see Figure 2, dashed line). Hip sonography as an ideal diagnostic instrument with a strike rate of 100% (all dysplasia are identified as such) and an error rate of 0% (no healthy child is found as sick) generates a point in the upper left corner of the chart. The more bulbous the ROC

curve, the greater the predictive value of the test. A measure of this is the area below the ROC curve (=area under the ROC curve=AUC), which is 0.5 for a test without any predictive force and 1 in the ideal test. With HRS as a diagnostic tool, we calculated a low AUC of 0.614.

Discussion

An estimated 10% of total hip arthroplasties result from untreated or insufficiently treated hip dysplasia.¹⁰ This equates to more than 11,000 hip implants for Germany,¹¹ generating a substantial socio-medical and economic impact, when costs for physician consultations, surgical and rehabilitative measures, drug prescriptions, and disability pensions are factored in. Therefore, the aim of this work was to determine the percentage of overlooked congenital dysplasia and displacement of the hip that escape postnatal diagnosis with the current criteria of neonatal HRS and result in delayed treatment for DDH.

In Germany, the Federal Association of Health Insurance Funds as part of childhood disease pre-existing conditions detection program¹² introduced a selective hip sonography screening on 1 January 1996. The accompanying guideline suggests a two-step algorithm: only in the presence of anamnestic or clinical risk factors, a US examination of the infant's hips has to be performed during the first week of life (within the framework of the German general medical newborn screening=U2). Risk factors include birth from breech position, the presence of hip joint dysplasia in the family history, joint instability, or limited abduction of the hip during clinical examination. Children without corresponding risk factors should be sonographed between the fourth and fifth week of life (=U3). Until this second screening date, 90% of the early detected IIA hips mature spontaneously to type I hips.^{10,13-16} This approach constituted an economic and logistic compromise, since inconspicuous newborns could still be diagnosed later but would escape appropriate therapy before the sixth week of life.

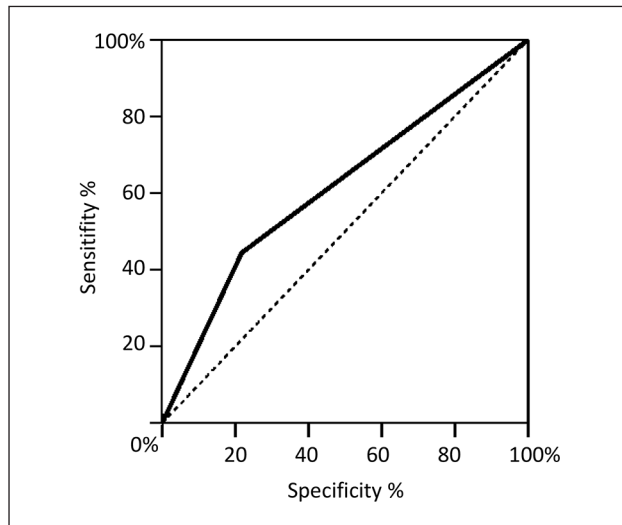
Godward and Dezateux¹⁷ were able to show that stand-alone clinical screening cannot achieve a decrease in surgery for DDH. However, the rate of surgical interventions decreased significantly after the introduction of sonographic hip screening.^{13,18-22} In order to decrease this number even further, the GNHS suggested by Graf should provide hip US for all infants at two different time points: regardless of the existence of risk factors within the first week of life and again during the sixth to eighth week of life.²³

Several factors support an early US in the first week of life. With regard to the hip maturation curve of Graf and Tschauner, conservative treatment has the best chance of restoring full anatomical healing when started as early as possible.^{13,24,25} Graf achieved anatomical healing in 100% of cases when starting therapy before the sixth week. Eight

Table 3. Sensitivity, specificity, and positive and negative predictive value for HRS; 95% confidence interval.

Sensitivity	True positive/(true positives + false negatives)	8/(8 + 10) = 44.4% 95% CI = 22%–69%
Specificity	True negatives/(true negatives + false positives)	882/(882 + 245) = 78.2% 95% CI = 75.7%–80.6%
Positive predictive value	True positive/(true positive + false positive)	8/(8 + 245) = 3.2% 95% CI = 1.4%–6.1%
Negative predictive value	True negatives/(true negatives + false negatives)	882/(882 + 10) = 98.9% 95% CI = 97.9%–99.5%

CI: confidence interval.

**Figure 2.** ROC analysis for HRS.

percent of the children ended up with residual dysplasia (type IIb) if therapy started after that time point.¹³ Klapsch et al.²⁶ even showed pathological hip joint maturation if starting therapy at the fourth week. Currently, the average patient's age at U3 is 5.5 weeks.²⁷

The median gestational age at birth was 39.2 weeks comparing favorably to Partenheimer et al.,²⁸ while they also included babies beginning from the 24th week of pregnancy. So far, no significant correlation of the parameters "pregnancy week" and "alpha angle" were found by several researchers.^{29–31} Graf et al.¹⁸ stated an increased proportion of immature but not pathological joints in pre-term babies. Nevertheless, we excluded preterm babies in our study.

According to our results, the present screening strategy is inadequate. Especially the clinical examination is not suitable for screening, as it searches for late signs relying on highly investigator-dependent methods. Just 2 (11.1%) out of 18 dysplastic hips were discovered by clinical examination in our study. Jari et al. found 2 out of 34 and Seidl et al. found 1 of 74 pathological hips affected by a limited abduction of the hip.^{10,32} In addition, according to Seidl et al.,³² 71% of hips in need of therapy remained

clinically mute when performing the Ortolani test. Rosendahl et al.³³ found a 63% detection rate of DDH clinical examination in neonatal age, which is in line with the results of Riboni and De Pellegrin.^{30,34} Tönnis et al. showed that more than half (52.2%) of the pathological hips detected by US were inconspicuous in the clinical examination. Ortolani test and limited abduction provided no evidence of the present dysplasia, in 75% of type IIc and 58% of IIId hips. The majority of the dysplastic hips in need for therapy showed an unlimited abduction; only type IV hips showed a typical spread inhibition in 65%.^{3,35} In our study, the number of false-negative clinical instability was even higher with 88.9%.

The high number of different investigators (n = 3) might also be regarded as a point of criticism of our work. Nevertheless, the reliability of clinical findings usually decreases with the increasing number of investigators.^{36–38} In addition, the sensitivity of the Ortolani sign is less than 60%. For inexperienced investigators, it decreases even further.^{32,39,40} The medical specialty of the investigator also influences the results of clinical examination: orthopedists are twice as likely to document true-positive instability findings as pediatricians (0.6% vs 0.3%).^{41,42} However, we tried to overcome this concern as all examinations were carried out only by orthopedists.

In contrast to HRS, the US screening of the hip developed by Graf is set up with strict algorithms that hardly allow false results. Nevertheless, the technique contains sources of error when handled insecurely.⁴² In our study, we attempted to avoid false-positive results by examining all children with hip types IIa (–), IIc, D and IV a second time by our specialists in the pediatric orthopedic outpatient clinic.

Our study reveals HRS as a non-suitable tool for diagnosing DDH in the first week of life. With a sensitivity of 44%, less than one in two hip dysplasia were detected. Seidl et al. came to similar conclusions, which showed that in a total of 2550 newborns examined, only 34 out of 74 pathological hip joints had been detected. The sensitivity was given at 48.6% and the specificity at 78.1%.^{32,43} Falliner et al.¹⁹ determined the sensitivity of HRS as 52% and the specificity as 73%. However, the sensitivity of a screening strategy should be 60%–90% in general. HRS is

therefore hardly able to identify the diseased as diseased, which is also evident in the high proportion of false-negative results of 55.6%. Other studies also indicated that up to 50% of DDHs showed no clinical risk factors or anamnestic abnormalities.^{35,44} Our HRS was conspicuous in 22.1%, which is in line with the findings of other authors (27%).^{3,4,39,44} On the other hand, Seidl et al.^{32,43} detected a high rate of false-positive findings of 51.4%.

A limitation of our study is the fact that we only analyzed the data collected within 1 year and therefore ended up with a lower patient number compared to other studies. Talbot et al analyzed 64,670 children born in the United Kingdom prospectively and detected 31 infants with an irreducible dislocation of the hip. Fifty-eight percent of these children presented late, despite universal clinical and selective US screening. Seventy-two percent of these late presenting cases had no risk factors.^{45,46}

In addition, Biedermann et al. recently detected a treatment rate of 1% for DDH in 28,092 neonates screened immediately after birth. Approximately 10% of these underwent closed or open reduction. This strengthens the conviction that early identification and treatment is crucial for successful conservative treatment (Biedermann et al., 2018).⁴⁷

Conclusion

Our results suggest that the current HRS strategy as provided for by the German health insurance funds cannot be recommended as an appropriate screening strategy. Essential aspects of the screening criteria established by Wilson and Jungner⁴⁸ are not met, in particular the stage at which the disease is latent but not recognized. The significance of anamnestic risk factors and clinical examination is low. We still consider the orthopedic clinical examination of every newborn child as essential. Nevertheless, we discontinued to trust any clinically normal-appearing hip and focused more on other orthopedic conditions such as foot, spine, and upper limb deformities. Like Kolb et al.⁴⁴ and Graf et al., we postulate a GNHS in the first week of life.

The earliest diagnosis possible offers the highest chance of anatomical healing with conservative methods and reduced therapy.⁴⁹ HRS does not provide timely therapy to sufferers.

Author Contributions

CMZ conceptualized and designed the study, and performed ultrasound and data collection. He drafted the initial manuscript, and reviewed and revised the manuscript. KME conceptualized and designed the study, performed data collection as well as data analysis, drafted the initial manuscript, and reviewed and revised the manuscript. MD conceptualized and designed the study with the focus on aspects concerning the field of obstetrics. She organized patients' acquisition. She reviewed and revised the manuscript. KMF conceptualized and designed the study with the

focus on aspects concerning the field of neonatology. He organized patients' acquisition. He reviewed and revised the manuscript. AC conceptualized and designed the study with the focus on aspects of statistical data analysis. He reviewed and revised the manuscript. FW conceptualized and designed the study, and performed data analysis. He reviewed and revised the manuscript and gave significant input on the field of orthopedic surgery. He critically reviewed the manuscript for important intellectual content. BH conceptualized and designed the study, and coordinated and supervised data collection. All authors approved the final manuscript as submitted and agree to be accountable for all aspects of the work.

Declaration of conflicting interests

The author(s) declared no potential conflicts of interest with respect to the research, authorship, and/or publication of this article.

Ethical approval

All procedures involving human participants were in accordance with the ethical standards of the institutional research committee (Ethical approval number XXX) and with the 1964 Helsinki declaration and its later amendments or comparable ethical standards.

Funding

The author(s) received no financial support for the research, authorship, and/or publication of this article.

Informed consent

No case details, personal information, or images of patients and other individuals are included in the article.

ORCID iD

Ferdinand Wagner  <https://orcid.org/0000-0002-5227-2812>

References

1. Küllmer K, Theis C, Meurer A, et al. Diagnostik und Therapie der Hüftdysplasie und -luxation im ersten Lebensjahr. *Zentralbl Kinderchir* 2002; 11(4): 205–208.
2. Graf R. *Sonographie der Säuglingshüfte und therapeutische Konsequenzen*. Stuttgart: Thieme Georg, 2010.
3. Tönnis D. *Die angeborene Hüftdysplasie und Hüftluxation im Kindes- und Erwachsenenalter*. Berlin; Heidelberg; New York: Springer, 1984.
4. Tönnis D, Storch K, Ulbrich H. Results of newborn screening for CDH with and without sonography and correlation of risk factors. *J Pediatr Orthop* 1990; 10(2): 145–152.
5. Dogruel H, Atalar H, Yavuz OY, et al. Clinical examination versus ultrasonography in detecting developmental dysplasia of the hip. *Int Orthop* 2008; 32(3): 415–419.
6. Lehmann HP, Hinton R, Morello P, et al. Developmental dysplasia of the hip practice guideline: technical report—Committee on Quality Improvement, and Subcommittee on Developmental Dysplasia of the Hip. *Pediatrics* 2000; 105(4): E57.

7. Von Kries R, Ihme N, Oberle D, et al. Effect of ultrasound screening on the rate of first operative procedures for developmental hip dysplasia in Germany. *Lancet* 2003; 362(9399): 1883–1887.
8. Bialik V, Bialik GM, Wiener F. Prevention of overtreatment of neonatal hip dysplasia by the use of ultrasonography. *J Pediat Orthop: Part B* 1998; 7(1): 39–42.
9. Leitlinie für das hüftsonographische Screening—Konsensusstatement? *Dtsch Arztebl Int* 1996; 93(1–2): 58.
10. Jari S, Paton RW, Srinivasan MS. Unilateral limitation of abduction of the hip. A valuable clinical sign for DDH? *J Bone Joint Surg Br* 2002; 84(1): 104–107.
11. Grimberg A, Jansson V. Endoprothesenregister Deutschland—Jahresbericht 2016. 2016, https://www.eprd.de/fileadmin/user_upload/Dateien/Publikationen/Berichte/EPRD-Jahresbericht_2016_Einzelseiten_Online-Version.pdf
12. Linnane E, Paul A, Parry R. Screening of newborn infants for cholestatic hepatobiliary disease: does test fulfil screening criteria? *BMJ* 1999; 319(7222): 1435–1436.
13. Farr S, Grill F, Muller D. [When is the optimal time for hip ultrasound screening?]. *Orthopade* 2008; 37(6): 538540.
14. Yawn BP, Mabry IR, Ko S. Ultrasonography in the assessment of developmental dysplasia of the hip. *Am Fam Phys* 2006; 74(8): 1284–1285.
15. Catterall A. The early diagnosis of congenital dislocation of the hip. *J Bone Joint Surg Br* 1994; 76(4): 515–516.
16. Patel H. Preventive health care, 2001 update: screening and management of developmental dysplasia of the hip in newborns. *CMAJ: Can Med Assoc J/J Assoc Med Can* 2001; 164(12): 1669–1677.
17. Godward S, Dezateux C. Surgery for congenital dislocation of the hip in the UK as a measure of outcome of screening: MRC Working Party on Congenital Dislocation of the Hip—Medical Research Council. *Lancet* 1998; 351(9110): 1149–1152.
18. Graf R. Die Hüftsonographie beim Neugeborenen. *Pädiatr Prax* 1990; 39: 611–619.
19. Falliner A, Hahne HJ, Hassenpflug J. Sonographic hip screening and early management of developmental dysplasia of the hip. *J Pediat Orthop: Part B* 1999; 8(2): 112–117.
20. Wirth T, Hinrichs F, Stratmann L. Verlaufsbeobachtungen der Inzidenz der Hüftdysplasie nach 14-jähriger Anwendung eines sonographischen Neugeborenen Screenings. In: Reichel H, Krauspe R (eds) *Langzeitergebnisse in der Kinderorthopädie*. Heidelberg: Steinkopff, 2003, pp. 111–122.
21. Angliss R, Fujii G, Pickvance E, et al. Surgical treatment of late developmental displacement of the hip: results after 33 years. *J Bone Joint Surg Br* 2005; 87(3): 384–394.
22. Eggl H, Krismer M, Klestil T, et al. [Results of ultrasonographic screening: an epidemiological study]. *Orthopade* 1993; 22(5): 277–279.
23. Graf R. New possibilities for the diagnosis of congenital hip joint dislocation by ultrasonography. *J Pediat Orthop* 1983; 3(3): 354–359.
24. Tschauner C, Klapsch W, Baumgartner A, et al. [Maturation curve of the ultrasonographic alpha angle according to Graf's untreated hip joint in the first year of life]. *Zeitschrift Orthop Ihre Grenzgeb* 1994; 132(6): 502–504.
25. Sahlstrand T, Malmgren N, Ahlgren SA, et al. Management of neonatal hip instability: an analysis of the efficiency in a consistent treatment program. *J Pediat Orthop* 1985; 5(5): 540–545.
26. Klapsch W, Tschauner C, Graf R. [Cost control using general ultrasound hip screening]. *Monatsschr Kinderheilkd* 1991; 139(3): 141–143.
27. Günther K-P, Allhoff P, Kries Rv Niethard FU, et al. Klinisches und sonographisches Screening der Säuglingshüfte. *Dtsch Arztebl Int* 2000; 97(23): 1593.
28. Partenheimer A, Scheler-Hofmann M, Lange J, et al. [Correlation between sex, intrauterine position and familial predisposition and neonatal hip ultrasound results]. *Ultraschall in der Medizin* (Stuttgart, Germany: 1980) 2006; 27(4): 364–367.
29. Schüle B, Wissel H, Neumann W, et al. Verlaufskontrollen von Hüftbefunden im sonographischen Neugeborenen Screening. *Ultraschall Med* 1999; 20(4): 161–164.
30. Riboni G, Bellini A, Serantoni S, et al. Ultrasound screening for developmental dysplasia of the hip. *Pediat Radiol* 2003; 33(7): 475–481.
31. Yamamuro T, Hama H, Takeda T, et al. Biomechanical and hormonal factors in the etiology of congenital dislocation of the hip joint. *Int Orthop* 1977; 1(3): 231–236.
32. Seidl T, Lohmaier J, Trouillier H-H. Früherkennung der Hüftdysplasie: Ist das zweigeteilte Risikoscreening effektiv? *Monatsschr Kinderheilkd* 2011. <https://www.springermedizin.de/frueherkennung-der-hueftdysplasie/8049144#:~:text=Schlussfolgerung,der%20ersten%20Lebenswoche%20erkannt%20worden>.
33. Rosendahl K, Markestad T, Lie RT. Developmental dysplasia of the hip: prevalence based on ultrasound diagnosis. *Pediat Radiol* 1996; 26(9): 635–639.
34. De Pellegrin M, Tessari L. Early ultrasound diagnosis of developmental dysplasia of the hip. *Bulletin* 1996; 54(4): 222–225.
35. Heimkes B. Erkrankungen des kindlichen Hüftgelenks Hüftentwicklung—diagnostische und therapeutische Prinzipien. *Monatsschr Kinderheilkd* 2013; 161: 355–368.
36. Ihme N, Altenhofen L, von Kries R, et al. [Hip ultrasound screening in Germany: results and comparison with other screening procedures]. *Orthopade* 2008; 37(6): 541548–546549.
37. Ziegler J, Thielemann F, Mayer-Athenstaedt C, et al. The natural history of developmental dysplasia of the hip. *Der Orthopäde* 2008; 37(6): 515–524.
38. Tschauner C, Furnrath F, Saba Y, et al. Developmental dysplasia of the hip: impact of sonographic newborn hip screening on the outcome of early treated decentered hip joints—a single center retrospective comparative cohort study based on Graf's method of hip ultrasonography. *J Child Orthop* 2011; 5(6): 415–424.
39. Schilt M. [Optimal age for hip sonography screening]. *Ultraschall Medizin* 2001; 22(1): 39–47.
40. Leonhardi A, Reither M. Ultraschall-Screening für Neugeborene (NG). Nutzen und Bedeutung in der Routinediagnostik. *Klin Pädiatr* 1993; 205: 383–388.
41. Schuler P. [Ultrasonic diagnosis of hip dysplasia and hip luxation]. *Deuts Med Wochens* 1988; 113(11): 428–431.

42. Schuler P, Feltes E, Kienapfel H, et al. Ultrasound examination for the early determination of dysplasia and congenital dislocation of neonatal hips. *Clin Orthop Rel Res* 1990(258): 18–26.
43. Seidl T, Trouillier H-H. Früherkennung der Hüftdysplasie: Kann sie die Therapieinvasivität senken. ? *Pädiatr Prax* 2013; 80: 671–679.
44. Kolb A, Schweiger N, Mailath-Pokorny M, et al. Low incidence of early developmental dysplasia of the hip in universal ultrasonographic screening of newborns: analysis and evaluation of risk factors. *International Orthopaedics* 2016; 40(1): 123–127.
45. Talbot C, Adam J, Paton R. Late presentation of developmental dysplasia of the hip: a 15-year observational study. *Bone Joint J* 2017; 99-B: 1250–1255.
46. Biedermann R, Eastwood DM. Universal or selective ultrasound screening for developmental dysplasia of the hip? A discussion of the key issues. *J Children Orthop* 2018; 12(4): 296–201.
47. Biedermann R, Riccabona J, Giesinger JM, et al. Results of universal ultrasound screening for developmental dysplasia of the hip: a prospective follow-up of 28 092 consecutive infants. *Bone Joint J* 2018; 100-B(10): 1399–1404.
48. Wilson JM, Jungner YG. [Principles and practice of mass screening for disease]. *Boletin Ofic San Panamer Am Sanit Bure* 1968; 65(4): 281–393.
49. Thaler M, Biedermann R, Lair J, et al. Cost-effectiveness of universal ultrasound screening compared with clinical examination alone in the diagnosis and treatment of neonatal hip dysplasia in Austria. *J Bone Joint Surg Br* 2011; 93(8): 1126–1130.