



Since January 2020 Elsevier has created a COVID-19 resource centre with free information in English and Mandarin on the novel coronavirus COVID-19. The COVID-19 resource centre is hosted on Elsevier Connect, the company's public news and information website.

Elsevier hereby grants permission to make all its COVID-19-related research that is available on the COVID-19 resource centre - including this research content - immediately available in PubMed Central and other publicly funded repositories, such as the WHO COVID database with rights for unrestricted research re-use and analyses in any form or by any means with acknowledgement of the original source. These permissions are granted for free by Elsevier for as long as the COVID-19 resource centre remains active.



Covid-19 Case Report

A Probable Covid-19 Case Presented with Acute Upper Limb Ischemia

Gulen Sezer Alptekin Erkul, Sinan Erkul, Ali Ihsan Parlar, and Ahmet Cekirdekci

Abstract: The arterial revascularization procedure is still a challenging issue in Covid-19 associated limb ischemia. Herein we aimed to present a case of a 64 year-old woman with acute ischemic signs in upper extremity who was diagnosed as a probable Covid-19 case incidentally after admission. Although late admission and failed recurrent embolectomies lead to an eventful course, intra-arterial thrombolysis seemed to present a benefitable treatment option for our patient.

Covid-19 disease has been defined as a respiratory tract infection. The hypercoagulable effect and venous thromboembolic events were broadly adopted as some of the other presentations of the disease. However, the recent reports of acute arterial ischemic events which were observed in Covid-19 patients emerge another aspect of the disease.¹ The pathophysiology of arterial thrombembolism in Covid-19 is still unclear. Herein we aimed to present a case of an acute upper limb ischemia associated with Covid-19 as a rare and challenging case.

CASE PRESENTATION

A 64 year-old woman, with a history of hypertension, presented with left hand pain and coldness for the last 6 days. According to her history, she had flu-like symptoms and weakness ten days before. Palmar surface of the hand and the fingers were cyanotic (Fig.1A). The radial artery pulse was palpable whereas the ulnar artery pulse was

nonpalpable. There was no flow on ulnar arterial and palmar arch trace with hand-held Doppler ultrasound. The electrocardiogram was showing normal sinus rhythm. The D-Dimer level was 2256 ng/mL on admission. Because of the severe ischemic signs, an emergent embolectomy was performed. An organized thrombus was obtained from the ulnar artery. Intravenous heparin with intermittent doses and peroral acetylsalicylic acid was administered. The nasopharyngeal swab and embolectomy material were both negative when were tested with polymerase chain reaction (PCR) for Sars-CoV-2. Given the pain and ischemic findings on left hand after 12 hours from the operation, a computed tomography angiography (CTA) for the upper limb combined with thoracic computed tomography was performed. The CTA revealed occlusion in brachial artery at bifurcation level, a floating thrombus in descending aorta and peripheral ground-glass opacities in lungs which were diagnostic for mild Covid-19 pneumonia² (Fig. 2A, B). Re-embolectomy was performed and followed by continuous intravenous infusion of heparin and iloprost. The radial and ulnar artery pulses were pulsatile with Doppler ultrasound postoperatively although the pain was not regressed entirely. The other medications involved peroral favipiravir, vitamin D, ascorbic acid, and zinco. After two days she started complaining about an increase in severity of pain and cyanosis that began at her left hand. Doppler ultrasound revealed no flow in both radial and ulnar arteries. Local

Department of Cardiovascular Surgery, Faculty of Medicine, Kutahya University of Health Sciences, Kütahya, Turkey

Correspondence to: Gulen Sezer Alptekin Erkul, Department of Cardiovascular Surgery, Faculty of Medicine, Kutahya University of Health Sciences, Yunus Emre Mah. Mescid-i Aksa Sok. Park Bulvar Evleri No: 1, Kütahya43020, Turkey; E-mail: gsezeralptekin@hotmail.com

Ann Vasc Surg 2021; 76: 285–288

<https://doi.org/10.1016/j.avsg.2021.05.003>

© 2021 Elsevier Inc. All rights reserved.

Manuscript received: February 27, 2021; manuscript revised: April 24, 2021; manuscript accepted: May 5, 2021; published online: 14 May 2021

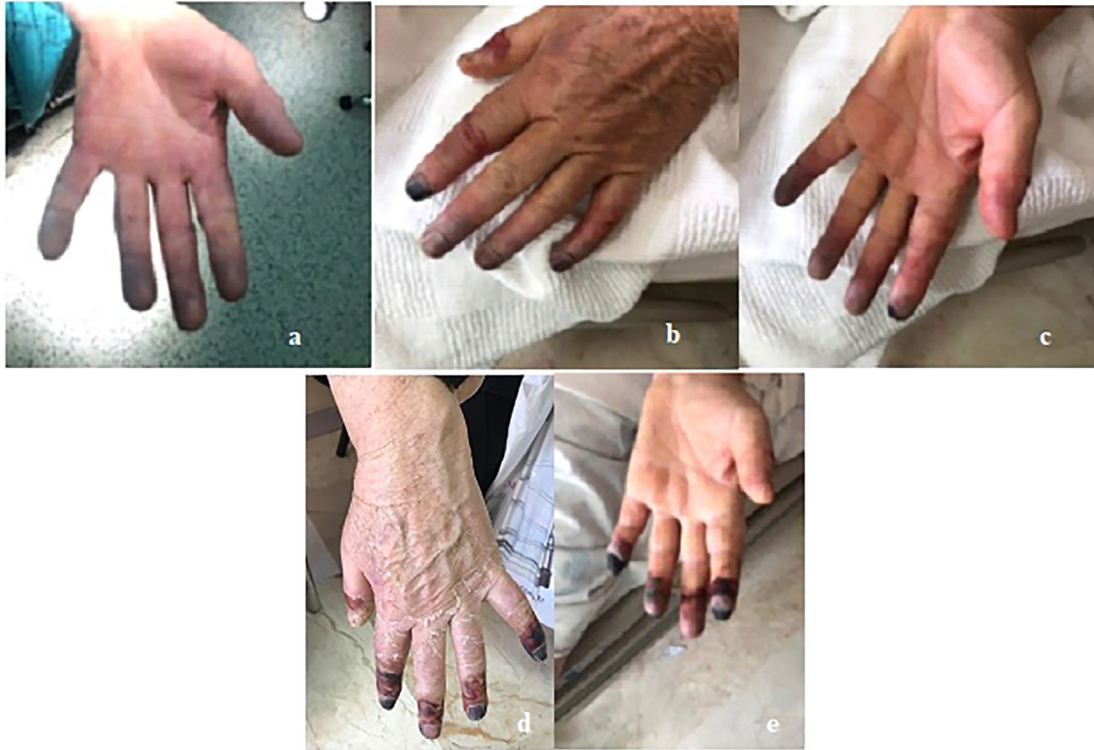

Fig. 1. (A) The cyanosis at the palmar surface of the hand and the fingers on admission. (B,C) The cyanosis was limited to the distal phalanges on the 12th day. 1.d.e. The necrotic areas at the distal phalanges before the amputation of the fifth finger and the debridement of the second, third and fourth fingers.

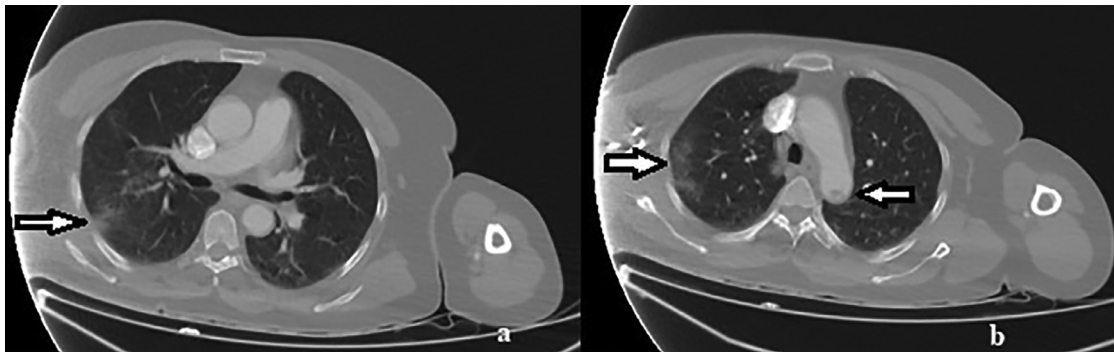


Fig. 2. (A) Computed tomography, axial image, right arrow: the ground glass opacities in lungs. (B) Computed tomography angiography, axial image, right arrow: the ground glass opacities in lungs; left arrow: floating thrombus in aorta.

thrombolysis was planned. Local thrombolytic infusion with alteplase (Actylise, Boehringer Ingelheim, Germany) was started with a dosage of 1 mg/hour from a 16 Gauge intra-arterial cannula (Maisflon, India) which was placed retrograde in brachial artery proximally to the level of embolectomy incision. The local thrombolysis was discontinued at 16th hour due to the mild hemorrhage from embolectomy incision. After discontinuation, the hemorrhage was controlled

without any surgical intervention. Following local thrombolysis, the pain was reduced, and ischemic signs were regressed. Subsequently the dual antiplatelet therapy and anticoagulant therapy was applied.

The cyanosis was limited to the distal phalanges and there were necrotic wounds at the tips of the phalanges on the 12th day (Fig. 1B,C). The patient had neither hypoxemia nor poor hemodynamical disposition at follow-up. Subsequent two

nasopharyngeal swab tests for Sars-CoV-2 were also negative. Neither intracardiac pathology nor hematological hypercoagulable disorders were detected. Antibody test was negative during hospitalization.

The distal phalanx of the fifth finger was amputated with an additional debridement of the necrotic areas at the tips of the second, third, and fourth fingers at the third week (Fig. 1D,E). After discharge she is in good condition within the fourth month with normal laboratory findings and adequate Doppler flow on radial and ulnar arteries and palmar arch as well. A written informed consent was obtained.

DISCUSSION

The preliminary data were consistent with increased risk of venous thromboembolic events and acute myocardial infarctions in Covid-19. Bellosta et al reported that the number of patients presenting with acute limb ischemia has significantly increased in 2020 compared with the same period in 2019 which may be considered as a sign of acute limb ischemia (ALI) related with Covid 19.³ Recent data's from limited number of studies also demonstrated the occurrence of acute arterial occlusions in aorta, mesenteric and cerebral arteries.⁴ Several reports described skin changes of the lower extremities and the so-called Covid toes, however upper extremity manifestations were rarely reported.⁵

Although ischemic events were relatively rare when compared with venous thromboembolic events in Covid-19, they were mostly observed in Intensive Care Unit (ICU) patients.⁴ Our patient was incidentally diagnosed as a probable case of Covid-19. Long et al reported that CT sensitivity was 97.2%, whereas the sensitivity of initial PCR was only 83.3% at presentation. PCR may produce initial false negative results.² Although PCR tests were negative, CTA revealed the typical findings of mild Covid-19 pneumonia in our case. A negative PCR from nasopharyngeal swab test is insufficient to rule out COVID-19.⁶ The highest percentage of virus detection was from nasopharyngeal sampling between 0- and 4-days post-symptom onset at 89% dropping to 54% after 10–14 days. PCR misses detection of people with SARS-CoV-2 infection; early sampling minimizes false negative diagnoses.⁷ Also negative antibodies do not rule out SARS-CoV-2 infection.⁸ In many trials it was observed that weak humoral response to Covid-19 leads to negative seroconversion. 78% of PCR-positive volunteers had undetectable antibodies.⁹ The prevalence of seroconversion was 11.6% when

considering positivity in at least one assay. In 5% of PCR positive individuals, no systemic IgG were detected. The short lifespan of the serological systemic responses suggests an underestimation of the true prevalence of infection.¹⁰ Considering our patient admitted after ten days from the symptom onset, the negative PCR and antibody testing of our case may be comprehensible. Therefore it may be suggested that the clinicians should be vigilant about the anamnesis that consists of any infectious disease concerning last days in history of ALI patients.

Elevated D-Dimer levels were considered as the predictor of the severity of the disease particularly for ICU patients. However, D-Dimer levels are elevated in all patients with ALI and it does not seem to be directly related with the severity of the event.¹¹

Intraluminal floating thrombus in aorta was observed in many ischemic events associated with Covid-19.^{3,4,11} Thus it may be regarded as a finding of Covid-19 disease.

For arterial embolism of the extremities, conservative therapies such as heparin, vasodilator drugs and fibrinolytic agents are only adjunct to embolectomy which is the method of choice and applicable in almost all cases.¹¹ Late arterial embolectomy may be indicated and is often successful if the limb shows signs of viable tissues.¹² However, the hypercoagulable state of the patients with Covid-19 may result in technical failure.³ The presence of COVID-19-related pneumonia was not significantly associated with successful revascularization.³

It was well-defined that the intact arterial intima, nonadherence of the emboli or thrombi to the intima, patent distal arterial tree and pretreatment with anticoagulants are the necessary factors that govern the successful outcomes of embolectomy.¹² It is obvious that the latter factor is fulfilled in many cases. Therefore a damaged arterial intima, the excessive adherence of the thrombi or emboli to the intima or an occluded distal arterial tree may be accused of the re-occlusion after revascularization procedures in Covid-19 disease.

Intraoperative thrombolysis was reported as an adjunct to embolectomy for distally located thrombus of tibial vessels.³ Because the embolectomy catheters reach proximally and distally to the entire arterial bed with a proximal pulsatile flow and adequate backflow from both radial and ulnar arteries, thrombolysis was not considered during the embolectomy procedures for our case. The novel percutaneous mechanical thrombectomy devices have not shown satisfactory results in small arteries.¹³ Catheter-

directed thrombolysis have beneficial results with alteplase.¹³ However appropriate catheter size was inaccessible for our case in such emergent situation. Also a 16 G arterial cannula served to the purpose of local thrombolysis for our case. Additionally local thrombolysis would rather be performed concomitant with or before an embolectomy procedure to preclude the bleeding complications.

CONCLUSION

Acute limb ischemia is increasingly diagnosed concomitantly with Covid-19 in recent data's. We consider that such distally located recurrent thrombus at limb arteries with an additional clinical or diagnostic finding is highly relevant with Covid-19 disease even for outpatients with mild symptoms. However the arterial revascularization procedure is still a challenging issue in Covid-19 associated limb ischemia. Further studies are needed to put forth the direct correlation and the underlying pathophysiology.

DECLARATION OF COMPETING INTEREST

None declared.

REFERENCES

1. Garg K, Barfield ME, Pezold ML, et al. Arterial thromboembolism associated with COVID-19 and elevated D-dimer levels. *J Vasc Surg Cases and Innovative Techniques* 2020;6:348–51.
2. Long C, Xu H, Shen Q, et al. diagnosis of the coronavirus disease (COVID-19): rRT-PCR or CT? *Eur J Radiol* 2020;126. doi:10.1016/j.ejrad.2020.108961.
3. Bellosta R, Luzzani L, Natalini G, et al. Acute limb ischemia in patients with COVID-19 pneumonia. *J Vasc Surg* 2020;72:1864–72.
4. Levolger S, Bokkers RPH, Wille J, et al. Arterial thrombotic complications in COVID-19 patients. *J Vasc Surg Cases and Innovative Techniques* 2020;6:454–9.
5. Heald M, Fish J, Lurie F. Skin manifestations of COVID-19 resembling acute limb ischemia. *J Vasc Surg Cases and Innovative Techniques* 2020;6:514–15.
6. El Gilany AH. COVID-19 caseness: An epidemiologic perspective. *J Infect Public Health* 2021;14:61–5.
7. Mallett S, Allen AJ, Graziadio S, et al. At what times during infection is SARS-CoV-2 detectable and no longer detectable using RT-PCR-based tests? A systematic review of individual participant data. *BMC Med* 2020;18:346. doi:10.1186/s12916-020-01810-8.
8. Solbach W, Schiffner J, Backhaus I, et al. Antibody Profiling of COVID-19 Patients in an Urban Low-Incidence Region in Northern Germany. *Front Public Health*. 2020;8:570543. doi: 10.3389/fpubh.2020.570543.
9. Schwarzkopf S, Krawczyk A, Knop D, et al. Cellular Immunity in COVID-19 Convalescents with PCR-Confirmed Infection but with Undetectable SARS-CoV-2-Specific IgG. *Emerg Infect Dis*. 2021;27. doi: 10.3201/2701.203772.
10. Anna F, Goyard S, Lalanne AL, et al. High seroprevalence but short-lived immune response to SARS-CoV-2 infection in Paris. *Eur J Immunol* 2021;51:180–90. doi:10.1002/eji.202049058.
11. Gomez-Arbelaez D, Ibarra-Sanchez G, Garcia-Gutierrez, et al. COVID-19-related aortic thrombosis: a report of four cases. *Ann Vasc Surg* 2020;67:10–13.
12. Haimovici H. Arterial embolism of the extremities & technique of embolectomy. *Vascular Surgery*, Haimovici 2004:388–408 5th edition.
13. Abdelaty MH D, Aborahma AM, Elheniedy MA, et al. Outcome of catheter directed thrombolysis for popliteal or infrapopliteal acute arterial occlusion. *Cardiovasc Interv and Ther* 2020. doi:10.1007/s12928-020-00702-1.