

Efficacy and safety of transanal opening of intersphincteric space in the treatment of high complex anal fistula: A meta-analysis

CHUNQIANG WANG¹, TIANYE HUANG² and XUEBING WANG³

¹Department of Anorectal Surgery, Affiliated Xiaoshan Hospital, Hangzhou Normal University, Hangzhou, Zhejiang 311200, P.R. China; ²Department of Anorectal Surgery, Linyi Central Hospital, Linyi, Shandong 276401, P.R. China; ³Department of Anorectal Surgery, Taian Municipal Hospital, Taian, Shandong 271021, P.R. China

Received September 29, 2023; Accepted May 1, 2024

DOI: 10.3892/etm.2024.12595

Abstract. The best treatment of high complex anal fistula (HCAF) is to avoid anal incontinence while improving the cure rate. On this basis, several surgical procedures for preserving the anal sphincter have been proposed. The purpose of the present study was to evaluate the efficacy and safety of transanal opening of intersphincteric space for treating HCAF. PubMed, Cochrane Library, China National Knowledge Infrastructure and the Wanfang databases were searched to collate all the articles on transanal opening of intersphincteric space for treating HCAF. A total of two researchers independently completed the whole process, from screening and inclusion to data extraction and the data was included in the RevMan 5.3 software for analysis. The main outcomes included the patients' essential characteristics, primary healing rate, management after recurrence, final healing rate, anal incontinence score before and after surgery, postoperative complication rate and types of complications. A total of six articles were included in this meta-analysis. The results showed that the weighted final healing rate of patients following transanal opening of intersphincteric space was 89% [risk differences (RD)=0.89; 95% confidence interval (CI)=0.86-0.92; I²=0%; P<0.00001]. The results of the anal incontinence score showed that there was no significant difference between the results before and after transanal opening of intersphincteric space surgery mean differences [(MD)=-0.04, CI=-0.10-0.02, I²=0%; P=0.21]. Only 11 patients were reported to have complications, including urinary retention and bleeding following transanal opening of intersphincteric space with a complication rate of 8% (11/138) and the weighted average complication rate was 6% (RD=0.06, 95% CI=0.02-0.10; I²=9%; P=0.003). Transanal

opening of intersphincteric space has a high cure rate, a favorable anal incontinence score, fewer types of postoperative complications and a low complication rate; it can be used as a minimally invasive and sphincter-preserving surgical method for treating HCAF and is worthy of further promotion and research in clinical practice.

Introduction

As one of the most common anorectal diseases, the incidence of anal fistula is reported to be ~3.6% (1). When the fistula involves more than 1/3 of the external sphincter and contains two or more external mouths connected to the internal opening through the fistula or complicated with branching fistulas, it is called a high complex anal fistula (HCAF). Surgery is the primary treatment for the anal fistula (2,3). The fistula of HCAF involves an integral part of the sphincter complex [internal anal sphincter (IAS) and external anal sphincter (EAS)]. Therefore, when the sphincter is damaged, it may lead to anal incontinence (4). How to improve the cure rate of HCAF, reduce the rate of postoperative complications and recurrence and improve the quality of life of patients under the premise of maximum preservation of anal sphincter function has always been one of the main problems faced by anorectal surgeons and also one of the key areas of current research.

Traditional surgery, such as anal fistulectomy, has become the gold standard for anal fistula due to its high success rate. However, it is easy to damage the anal sphincter and the anal sphincter injury can lead to anal incontinence, so it is unsuitable for HCAF (5). With the promotion of the minimally invasive concept, sphincter-preserving surgery has gradually received more attention. Although some sphincter-sparing surgical procedures have emerged, such as ligation of intersphincteric fistula tract (LIFT), video-assisted anal fistula treatment (VAAFT), fistula laser closure (FiLaC) and anal fistula plug (AFP) (6-8), these surgical methods may markedly reduce the occurrence of postoperative anal incontinence, but the cure rate is not satisfactory.

In 2017, Garg (9) proposed a new surgical method to treat HCAF and termed it the transanal opening of intersphincteric space (TROPIS). Through the transanal approach, the IAS part of the fistula is opened and the EAS retained. It is reported that the postoperative cure rate of TROPIS is 90.4% (9). However,

Correspondence to: Dr Chunqiang Wang, Department of Anorectal Surgery, Affiliated Xiaoshan Hospital, Hangzhou Normal University, 728 Yucai North Road, Xiaoshan, Hangzhou, Zhejiang 311200, P.R. China
E-mail: wangchunqiang93@126.com

Key words: high anal fistula, complex anal fistula, transanal opening of intersphincteric space, efficacy, safety

as a new surgical method, it inevitably needs more research data on large samples and the long-term efficacy and safety need to be further observed.

The present study aimed to evaluate the efficacy and safety of the surgery by systematically searching the relevant literature, collecting data and analyzing the cure rate and anal incontinence rate following TROPIS.

Materials and methods

Search strategy. The Preferred Reporting Items for Systematic Reviews and Meta-Analyses (PRISMA) screening guidelines were followed, while all the literature from inception through April 2024 was searched in the electronic databases PubMed, Cochrane Library, China National Knowledge Infrastructure and the Wanfang Database. Articles assessing TROPIS were collected by including the following keywords in combination with free words: ‘transanal opening of intersphincteric space,’ ‘anorectal fistula,’ ‘fistula-in-ano,’ ‘high anal fistula,’ ‘complex anal fistula,’ ‘rectal fistula,’ ‘FIA’ and ‘TROPIS.’

Inclusion and exclusion criteria. The inclusion criteria were as follows: The disease was diagnosed as HCAF; the surgical procedure was TROPIS; and clinical research. The exclusion criteria were as follows: Studies in which the demographic data of patients were incomplete and the original data could not be extracted for statistical analysis; republished literature; irrelevant articles, editorials, letters, case reports, reviews and meta-analysis; and studies that did not report the cure, complication and anal incontinence rates following the operation.

Data extraction. Then two investigators screened the retrieved studies independently according to the inclusion and exclusion criteria and then cross-checked them. Controversial studies were evaluated by a third party and unified by discussion. The two investigators extracted relevant information from the included studies, including first author, publication year, publication country, sample size, age, sex, follow-up time, cure rate, complication rate, management of recurrence and anal incontinence score.

Procedure of TROPIS. As shown in Fig. 1, a curved artery forceps is inserted through the internal opening into the intersphincteric part of the fistula tract. The mucosa and the internal sphincter over the artery forceps are cut with electrocautery. Thus, the intersphincteric space is opened into the anal canal. This wound is left open to heal by secondary intention. The lateral fistula tract (external) to the EAS can be managed by any method convenient to the surgeon (including excision and curettage) (9).

Statistical analysis. The present study performed statistical analysis using the Cochrane Collaboration Revman 5.3. Dichotomous variables are presented as risk differences (RD) and 95% confidence interval (CI). Continuous variables were presented as mean differences (MD) and 95% CI). Heterogeneity was evaluated by I^2 tests. Studies with values of $I^2 > 75\%$ indicated substantial heterogeneity, using the random effects model to estimate the pooled OR or MD. Otherwise, the fixed effects model was adopted. The Z test was used to

determine the pooled OR and MD. Forest plots were conducted to investigate possible bias. $P < 0.05$ was considered to indicate a statistically significant difference.

Results

Eligible studies. A total of 34 relevant articles were found in this meta-analysis. By carefully reading the titles and abstracts and screening the articles by inclusion and exclusion criteria, nine reports were obtained and re-excluded by reading the complete text. Finally, six articles (10-15) were included in the present study. Specific retrieval and screening process are shown in Fig. 2.

Primary characteristics of included literature. A total of six articles, including 485 patients, were included in this analysis. These articles were published between 2021 and 2023, with four articles from China and two from India. The primary characteristics of the included studies are provided in Table I.

Cure rate. The six articles reported cure rates in HCAF. The inverse variance statistical method was used to estimate the fixed-effects model and the results showed that the weighted average cure rate of each study was 89% (RD=0.89; 95% CI=0.86-0.92; $I^2=0\%$; $P < 0.00001$) as shown in Table II and Fig. 3.

Complications rate. A total of four studies reported complication rates in the HCAF. A total of 11 patients (8%) developed postoperative-related complications, including four cases of urinary retention (36.4% of the total complication rate), six cases of bleeding (54.5% of the total complication rate) and one case of incontinence to flatulence (9.1% of the total complication rate). The inverse variance statistical method was used to estimate the fixed-effects model and the results showed that the weighted average complications rate of each study was 6% (RD=0.06, 95%; CI=0.02-0.10; $I^2=9\%$; $P=0.003$) as shown in Table III and Fig. 4.

Anal incontinence rate. In three articles, including 374 patients, the anal function score showed no heterogeneity in the preoperative vs. postoperative ($P=0.94$; $I^2=0\%$). The inverse variance statistical method and estimate of the fixed-effects model were used for analysis (MD=-0.04; 95% CI=-0.10 to 0.02; $I^2=0\%$; $P=0.21$). Detailed data are shown in Table IV and Fig. 5.

Discussion

HCAF is a refractory disease in colorectal anal surgery. The main reasons for this are difficulty in understanding the pathophysiology, risk of coprocrasia and high recurrence rates (16-18). Since Eisenhammer (19) emphasized the importance of the inner sphincter plane in the pathogenesis and spread of the fistula in 1953, the role of the sphincter space in the pathogenesis of the anal fistula is gaining increasing recognition (20,21). Studies have found that sphincter space infection is an important cause of the pathogenesis of most complicated anal fistulas (22-24). Therefore, recent research in the management of high complex fistula has highlighted three essential principles: First, the intersphincteric tract is like an

Table I. Primary characteristics of the included studies.

First author/s, year	Country	Patients, n (male/female)	Mean age, years	Follow-up time (months)	(Refs.)
Huang <i>et al</i> (2021)	China	48 (41/7)	40±11.7	12	(10)
Garg <i>et al</i> (2021)	India	306	39.9±10.9	36	(11)
Mishra <i>et al</i> (2023)	India	35 (30/5)	33.32±10.52	3	(12)
Hou <i>et al</i> (2022)	China	27 (24/3)	41.96±12.28	10.19	(13)
Chen <i>et al</i> (2022)	China	28 (21/7)	39.5±9.0	6.00	(14)
Li <i>et al</i> (2021)	China	41 (35/6)	38.6±13.2	22.2	(15)

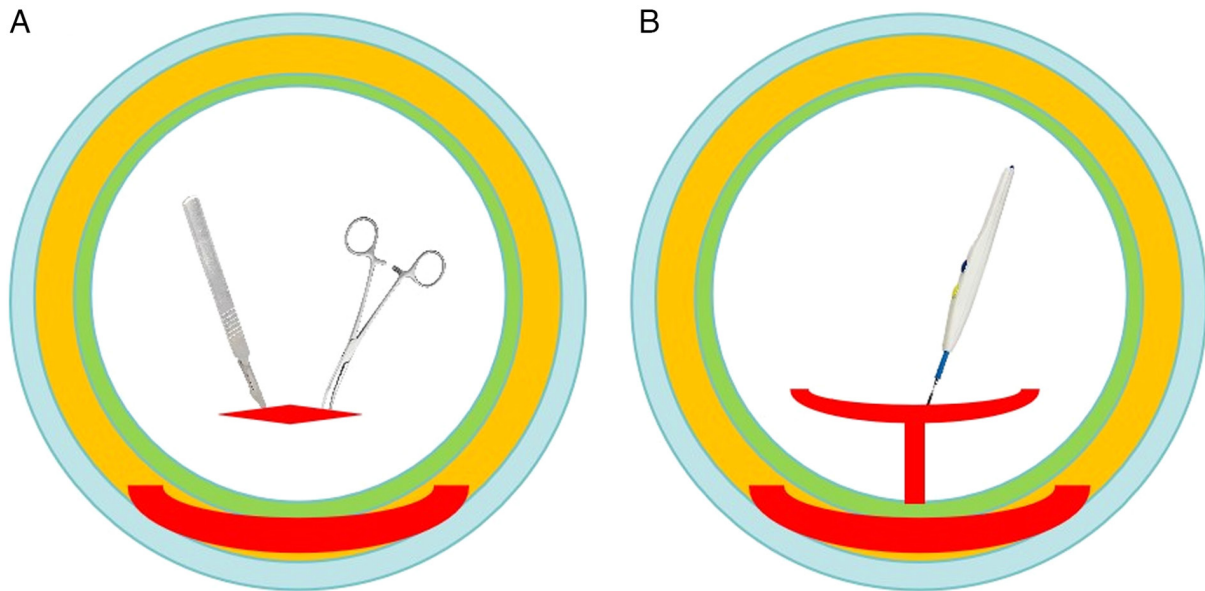


Figure 1. Procedure of TROPIS. (A) Curved artery forceps were inserted through the internal opening into the intersphincteric part of the fistula tract. (B) The mucosa and the internal sphincter over the artery forceps were cut with electrocautery. TROPIS, transanal opening of intersphincteric space.

abscess in a closed space (ISTAC) and it is necessary to open it up and drain it adequately; second, drain all pus and ensure continuous drainage (DRAPED) until the wound is healed; third, remove the sinus tract as intact as possible and simultaneously reduce the sphincter injury (16,22). Although the surgical methods used to treat HCAF, such as LIFT, VAAFT and fibrin glue, reduce the risk of anal sphincter injury, they are not satisfactory regarding cure rate and recurrence rate results. According to the relevant research reports, the cure rate of LIFT is 76%, the cure rate of VAAFT is 76.01-82.3% and fibrin glue in the treatment of complex anal fistula cure rate is even less than 10% (25-29). The overall cure rate is still suboptimal (30).

In view of the research on the theory of sphincter space infection, the TROPIS surgical approach was proposed by Garg (9) for the treatment of HCAF. In 2021, Garg *et al* (11) reported the clinical efficacy of TROPIS in 306 HCAF, with a cure rate of 87.6%. Although its good therapeutic effect has been confirmed by a number of studies, as a new surgical method, it inevitably lacks large samples and its long-term efficacy and safety in HCAF need to be further observed (9).

A total of six articles, including 485 patients, were included in the present study. The results showed that the mean

preoperative anal incontinence score was 0.061±0.22 and the mean postoperative anal incontinence score was 0.09±0.27. There was no statistically significant difference between the preoperative and postoperative anal incontinence scores, indicating that the anal sphincter function was well preserved in patients undergoing TROPIS surgery. The leading cause of anal incontinence following anal surgery is anal sphincter injury, especially EAS, which is more critical than IAS (31). TROPIS opens the fistulous sinus tract through the sphincter space and although the external anal sphincter is preserved, the internal anal sphincter is inevitably partly cut. As an essential part of the muscles around the anal canal, the internal anal sphincter is mainly responsible for maintaining the resting anal pressure. It plays a vital role in anal self-control. The damage of IAS can lead to anal incontinence, especially urge and flatulence incontinence (32-34). However, this type of anal incontinence is usually reversible. Some studies have shown that cutting the internal anal sphincter and opening the sphincter space fistula during anal fistula surgery is safe and effective (35,36).

The analysis of the present study showed that the weighted final healing rate of TROPIS was 89%. Improving the cure rate of HCAF while avoiding anal incontinence has always been the goal of anorectal doctors. Certain surgical methods, such

Table II. Healing rate and management of recurrence.

First author/s, year	Primary healing rate (%)	Final healing rate (%)	Management of recurrence (n)	(Refs.)
Huang <i>et al</i> (2021)	87.5	93.8 (45/48)	TROPIS (6)	(10)
Garg <i>et al</i> (2021)	78.4 (240/306)	87.6 (268/306)	TROPIS (35); fistulotomy (1); no surgery (30)	(11)
Mishra <i>et al</i> (2023)	82.86 (29/35)	91.4 (32/35)	Curettage (6)	(12)
Hou <i>et al</i> (2022)	85.19	85.19 (23/27)	Incision and drainage (1)	(13)
Chen <i>et al</i> (2022)	100	100 (28/28)	No	(14)
Li <i>et al</i> (2021)	85.3 (35/41)	100 (41/41)	Loose seton (2); fistulotomy (4)	(15)

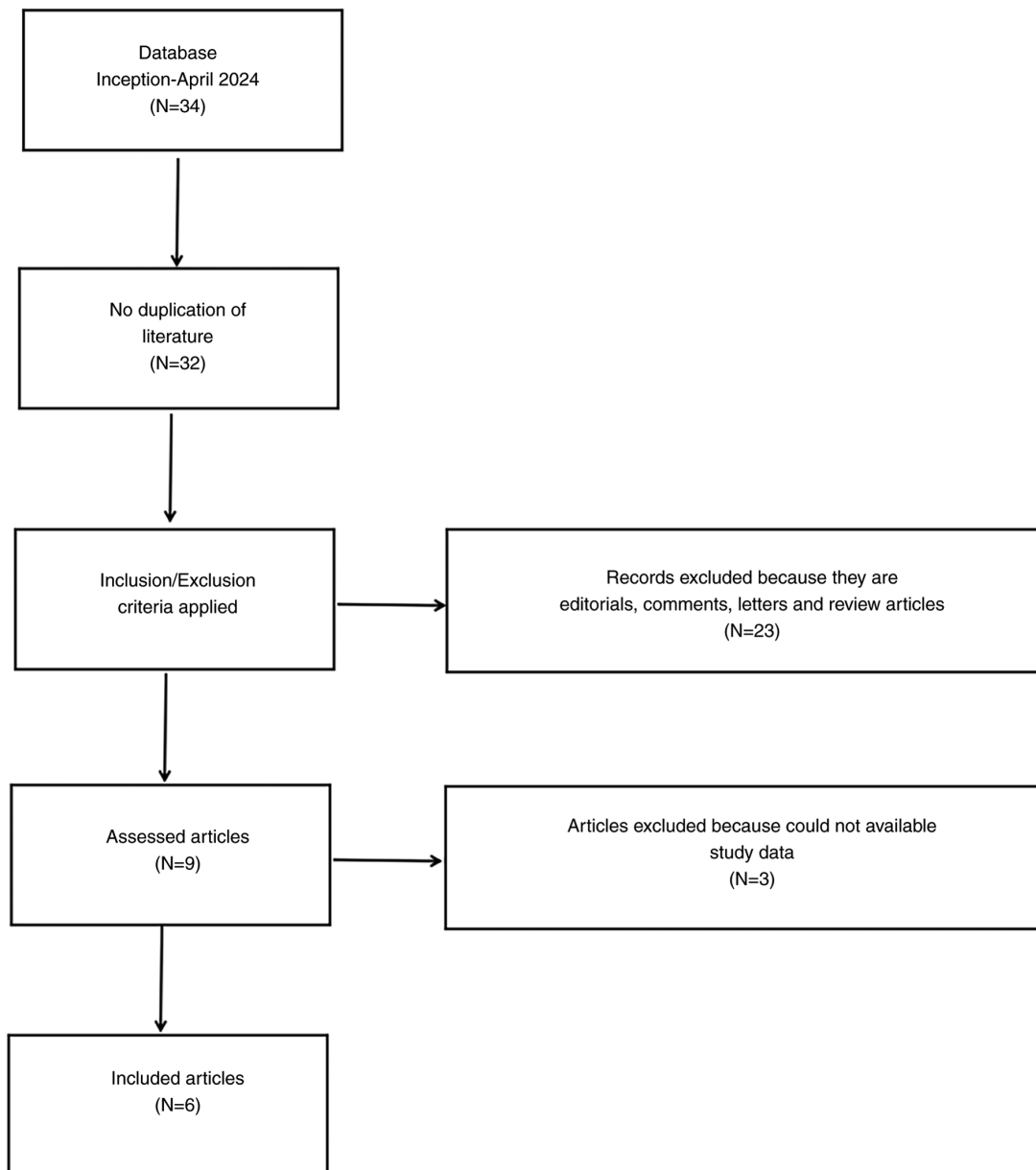


Figure 2. PRISMA flow diagram for the literature search. PRISMA, Preferred Reporting Items for Systematic Reviews and Meta-Analyses.

as LIFT, AFP, VAAFT and FiLaC, reduce the damage to the anal sphincter and avoid the occurrence of anal incontinence to some extent. However, AFP, VAAFT and FiLaC are not consistent with the ISTAC and DRAPED principles and perhaps

this is the reason why the postoperative cure rate of these surgical methods is unsatisfactory (37). A recent comparative meta-analysis of sphincter-sparing surgical procedures showed the highest cure rate for TROPIS (38). For complete healing of

Table III. Complications and type of complication.

First author/s, year	Complications (%)	Type of complication (n)	(Refs.)
Huang <i>et al</i> (2021)	8.3	Bleeding (3); urinary retention (1)	(10)
Mishra <i>et al</i> (2023)	2.9	Flatulent incontinence (1)	(12)
Hou <i>et al</i> (2022)	14.8	Bleeding (1); urinary retention (3)	(13)
Chen <i>et al</i> (2022)	7.1	Bleeding (2)	(14)

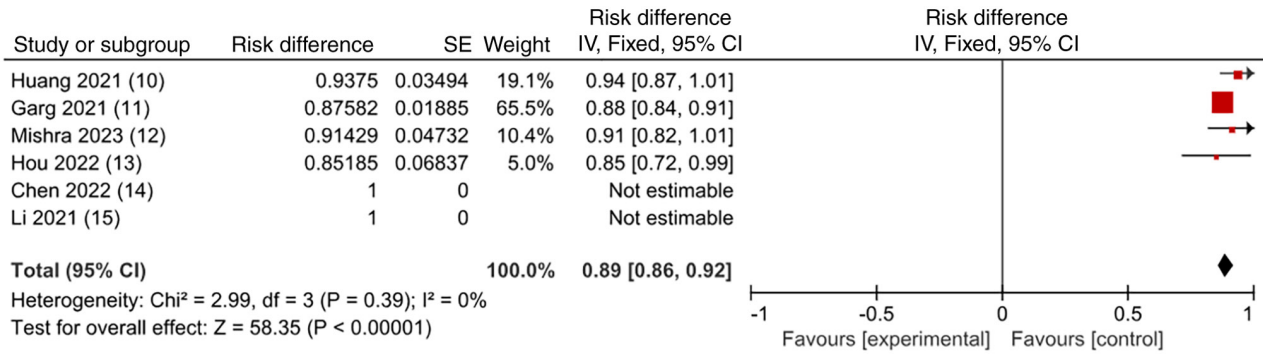


Figure 3. Cure rate. SE, standard error; CI, confidence interval.

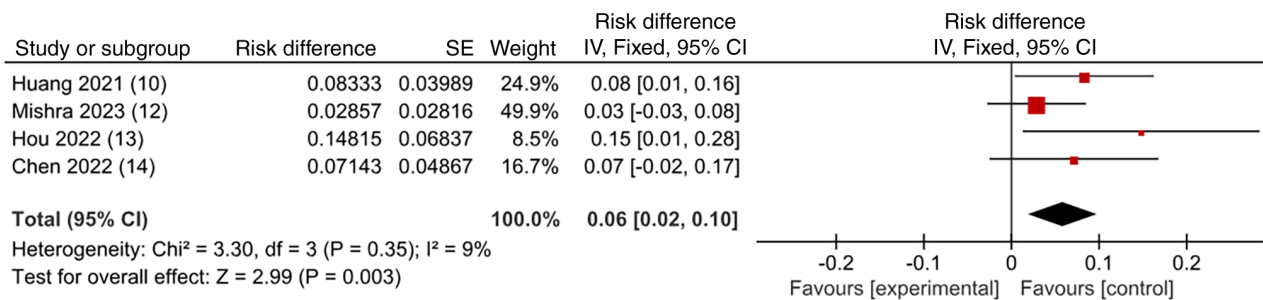


Figure 4. Complications. SE, standard error; CI, confidence interval.

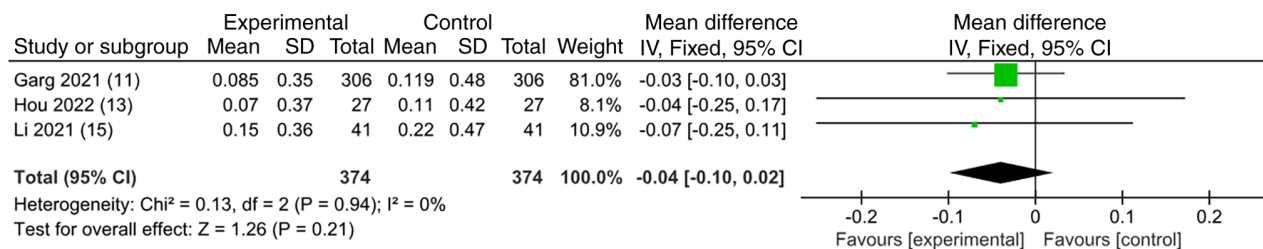


Figure 5. Anal incontinence rates. SE, standard error; CI, confidence interval.

the fistula, all three components of the fistula, internal opening, intersphincteric portion of the fistula and the external tract in the ischiorectal fossa (the lateral part of the fistula outside the external anal sphincter), need to be totally healed.

Previous study hypothesized that inaccuracy or inability in finding the internal orifice (IO) is the only important reason for the recurrence of anal fistula (39). Most popular surgical methods, such as LIFT, VAAFT and fibrin glue, all try to close the IO (29). However, recent studies have shown that TROPIS

has an improved therapeutic effect, even if the location of the IO cannot be determined; this is a big advantage that is different from other surgical methods. Garg *et al* (40) found that TROPIS surgery in 546 patients (IO found) and 154 patients (IO not found) had roughly the same cure rate (89 vs. 90.9%) and there was no significant difference in postoperative anal incontinence scores between the two groups. This was subsequently confirmed by Yagnik *et al* (41) who showed that even if the IO cannot be determined, the cure rate of TROPIS can reach 87.8%.

Table IV. Anal incontinence score.

First author/s, year	Anal incontinence score (preoperative)	Anal incontinence score (postoperative)	(Refs.)
Garg <i>et al</i> (2021)	0.085±0.35	0.119±0.48	(11)
Hou <i>et al</i> (2022)	0.07±0.37	0.11±0.42	(13)
Li <i>et al</i> (2021)	0.15±0.36	0.22±0.47	(15)

For HCAF, it is necessary to open the sphincter space, maintain continuous drainage and remove the sinus tract as completely as possible while reducing sphincter injury. LIFT surgery ligates the fistula bundle in the sphincter space, accord the ISTAC principle and it preserves the IAS and the EAS, which greatly avoids the risk of anal incontinence (42). However, LIFT has high technical requirements for the surgeon; how to correctly find the plane between two sphincters (IAS and EAS) and identify the sinus tract through the sphincter gap is a great challenge. In addition, since the wound is primary healing, it can greatly shorten the recovery time. However, it does not meet the DRAPED principle due to incomplete handling of infected anal recess glands. In TROPIS, direct incision of the IO and fistula involving the internal sphincter is easy to operate without risk of entering the wrong spatial plane of the sphincter. The wound is completely open with continuous drainage and secondary healing, in line with the principles of ISTAC and DRAPED. Of course, the TROPIS also has some disadvantages, such as the long recovery time of secondary healing, the partial incision of the IAS leading to the occurrence of anal incontinence in the short term (although long-term follow-up shows that anal incontinence does not deteriorate or become markedly worse) (43).

A study suggested that sepsis is present in almost all the sphincter spaces of an HCAF, presenting as an abscess in the closed space, ignoring that this sepsis is one of the causes of recurrence and that therefore the intersphincteric part of the fistula should also be drained appropriately (23). In patients with acute fistula abscess, inflammation causes swelling around the IO and blockage, causing a clinically difficult examination (42). It has been reported that in up to 88% of patients cannot be accurately located the IO by doctors, which is identified as a major bottleneck in the definitive treatment of acute fistula abscess (44). When infection is present in the sphincter space, the infection can easily induce local tissue degeneration and necrosis and severe inflammatory response, and the epidermis can regenerate only when the infection is controlled and the necrotic tissue is cleared, which may be the reason for the high healing rate of TROPIS in complex fistulas (11). A recent study showed that the cure rate of TROPIS in acute fistula-abscess was 85.2% (155/182) (41).

In the present meta-analysis, the weighted average complication rate of TROPIS was 6%. Compared with other postoperative complication rates such as LIFT (13.9%) and VAAFT (11%), the rate of postoperative complications after TROPIS is low and acceptable to patients and surgeons (29,45). Of 138 patients in the present study, only four had postoperative urinary retention, six had

postoperative bleeding and one had flatulence incontinence. This may be related to incomplete intraoperative hemostasis and poor postoperative management and has no apparent relationship with the surgical technique. Moreover, most of these complications were mild and did not cause significant adverse effects on the patients.

Limitations of the present study may affect the results and conclusions of the analysis. First, the main limitation was the small number of articles and patients included. In addition, since the study statistics of Garg *et al* (11) accounted for >50% of the total analysis, this may bias the results of the present study. Second, the short follow-up of patients in most included studies prevents drawing any firm conclusions on the long-term outcome of the technique. Therefore further prospective studies are required. However, despite its limitations, the present study provided a reference value for subsequent analyses.

The present study found that TROPIS surgery is a sphincter-sparing procedure that deserves further investigation. TROPIS has a high cure rate, a favorable anal incontinence score, few types of postoperative complications and a low complication rate. It can be used as a minimally invasive and sphincter-preserving surgical method for treating HCAF. It is worthy of further promotion and research in clinical practice.

Acknowledgements

Not applicable.

Funding

No funding was received.

Availability of data and materials

The data generated in the present study are included in the figures and/or tables of this article.

Authors' contributions

TH and XW participated in the whole process of literature selection, inclusion, quality evaluation and bias risk assessment. CW conducted data analysis, article writing and table and figure production. CW and TH confirm the authenticity of all the raw data. All authors read and approved the final manuscript.

Ethics approval and consent to participate

Not applicable.

Patient consent for publication

Not applicable.

Competing interests

The authors declare that they have no competing interests.

References

1. Felt-Bersma RJ and Bartelsman JF: Haemorrhoids, rectal prolapse, anal fissure, peri-anal fistulae and sexually transmitted diseases. *Best Pract Res Clin Gastroenterol* 23: 575-592, 2009.

2. Cooper CR and Keller DS: Response to letter to the editor on 'Resident's Corner: Perianal Fistulas', *Dis Colon Rectum* 63: e515, 2020.
3. Ribaldone DG, Resegotti A, Pellicano R, Astegiano M, Saracco GM and Morino M: The role of topical therapy for perianal fistulizing Crohn's disease: Are we forgetting something? *Minerva Gastroenterol Dietol* 65: 130-135, 2019.
4. Garg P, Sodhi SS and Garg N: Management of complex cryptoglandular anal fistula: Challenges and solutions. *Clin Exp Gastroenterol* 13: 555-567, 2020.
5. Abramowitz L, Soudan D, Souffran M, Bouchard D, Castinel A, Suduca JM, Staumont G, Devulder F, Pigot F, Ganansia R, *et al*: The outcome of fistulotomy for anal fistula at 1 year: A prospective multicentre French study. *Colorectal Dis* 18: 279-285, 2016.
6. Regusci L, Fasolini F, Meinerio P, Caccia G, Ruggeri G, Serati M and Braga A: Video-Assisted anal fistula treatment (VAAFT) for complex anorectal fistula: Efficacy and risk factors for failure at 3-year follow-up. *Tech Coloproctol* 24: 741-746, 2020.
7. Narang SK, Keogh K, Alam NN, Pathak S, Daniels IR and Smart NJ: A systematic review of new treatments for cryptoglandular fistula in ano. *Surgeon* 15: 30-39, 2017.
8. Lin H, Jin Z, Zhu Y, Diao M and Hu W: Anal fistula plug vs rectal advancement flap for the treatment of complex cryptoglandular anal fistulas: A systematic review and meta-analysis of studies with long-term follow-up. *Colorectal Dis* 21: 502-515, 2019.
9. Garg P: Transanal opening of intersphincteric space (TROPIS)-A new procedure to treat high complex anal fistula. *Int J Surg* 40: 130-134, 2017.
10. Huang B, Wang X, Zhou D, Chen S, Li B, Wang Y and Tai J: Treating highly complex anal fistula with a new method of combined intraoperative endoanal ultrasonography (IOEAUS) and transanal opening of intersphincteric space (TROPIS). *Wideochir Inne Tech Maloinwazyjne* 16: 697-703, 2021.
11. Garg P, Kaur B and Menon GR: Transanal opening of the intersphincteric space: A novel sphincter-sparing procedure to treat 325 high complex anal fistulas with long-term follow-up. *Colorectal Dis* 23: 1213-1224, 2021.
12. Mishra S, Thakur DS, Somashekar U, Verma A and Sharma D: The management of complex fistula in ano by transanal opening of the intersphincteric space (TROPIS): Short-term results. *Ann Coloproctol*: Mar 31, 2023 (Epub ahead of print).
13. Hou XT, Chen H, Chen YN and Zhang R: Transanal opening of intersphincteric space to treat complex anal fistula. *Mod Med J* 50: 588-591, 2022.
14. Chen XQ, Ren YY, Li YY, Sun F, Zhao YC and Jin X: Clinical efficacy of anal sphincterotomy (TROPIS) in the treatment of high sphincter type anal fistula. *Journal of Colorectal & Anal Surgery* 28: 479-487, 2022 (In Chinese).
15. Li YB, Chen JH, Wang MD, Fu J, Zhou BC, Li DG, Zeng HQ and Pang LM: Transanal opening of intersphincteric space for Fistula-in-Ano. *Am Surg* 88: 1131-1136, 2022.
16. Włodarczyk M, Włodarczyk J, Sobolewska-Włodarczyk A, Trzcinski R, Dziki L and Fichna J: Current concepts in the pathogenesis of cryptoglandular perianal fistula. *J Int Med Res* 49: 300060520986669, 2021.
17. Jeong HY, Song SG, Nam WJ and Lee JK: puborectalis muscle involvement on magnetic resonance imaging in complex fistula: A new perspective on diagnosis and treatment. *Ann Coloproctol* 37: 51-57, 2021.
18. Jayne DG, Scholefield J, Tolan D, Gray R, Senapati A, Hulme CT, Sutton AJ, Handley K, Hewitt CA, Kaur M, *et al*: A multicenter randomized controlled trial comparing safety, efficacy and cost-effectiveness of the surgisis anal fistula plug versus surgeon's preference for transsphincteric Fistula-in-Ano: The FIAT Trial. *Ann Surg* 273: 433-441, 2021.
19. Eisenhammer S: The internal anal sphincter; its surgical importance. *S Afr Med J* 27: 266-270, 1953.
20. Garcia-Aguilar J, Belmonte C, Wong WD, Goldberg SM and Madoff RD: Anal fistula surgery. Factors associated with recurrence and incontinence. *Dis Colon Rectum* 39: 723-729, 1996.
21. Jordan J, Roig JV, Garcia-Armengol J, Garcia-Granero E, Solana A and Lledo S: Risk factors for recurrence and incontinence after anal fistula surgery. *Colorectal Dis* 12: 254-260, 2010.
22. Garg P: A new understanding of the principles in the management of complex anal fistula. *Med Hypotheses* 132: 109329, 2019.
23. Garg P: Intersphincteric component in a complex Fistula-in-Ano is like an abscess and should be treated like one. *Dis Colon Rectum* 61: e26, 2018.
24. Zhang H, Zhou ZY, Hu B, Liu DC, Peng H, Xie SK, Su D and Ren DL: Clinical significance of 2 deep posterior perianal spaces to complex cryptoglandular fistulas. *Dis Colon Rectum* 59: 766-774, 2016.
25. Emile SH, Elfeki H, Shalaby M and Sakr A: A Systematic review and meta-analysis of the efficacy and safety of video-assisted anal fistula treatment (VAAFT). *Surg Endosc* 32: 2084-2093, 2018.
26. Gottgens KW, Smeets RR, Stassen LP, Beets G and Breukink SO: Systematic review and meta-analysis of surgical interventions for high cryptoglandular perianal fistula. *Int J Colorectal Dis* 30: 583-593, 2015.
27. Cestaro G, De Rosa M and Gentile M: Treatment of fistula in ano with fibrin glue: Preliminary results from a prospective study. *Minerva Chir* 69: 225-228, 2014.
28. Damin DC, Rosito MA, Contu PC and Tarta C: Fibrin glue in the management of complex anal fistula. *Arq Gastroenterol* 46: 300-303, 2009.
29. Emile SH, Khan SM, Adejumo A and Koroye O: Ligation of intersphincteric fistula tract (LIFT) in treatment of anal fistula: An updated systematic review, meta-analysis and meta-regression of the predictors of failure. *Surgery* 167: 484-492, 2020.
30. Prosst RL and Joos AK: Short-term outcomes of a novel endoscopic clipping device for closure of the internal opening in 100 anorectal fistulas. *Tech Coloproctol* 20: 753-758, 2016.
31. Matos D, Lunniss PJ and Phillips RK: Total sphincter conservation in high fistula in ano: Results of a new approach. *Br J Surg* 80: 802-804, 1993.
32. Sainio P: A manometric study of anorectal function after surgery for anal fistula, with special reference to incontinence. *Acta Chir Scand* 151: 695-700, 1985.
33. Soltani A and Kaiser AM: Endorectal advancement flap for cryptoglandular or Crohn's fistula-in-ano. *Dis Colon Rectum* 53: 486-495, 2010.
34. Uribe N, Balciscueta Z, Minguez M, Martin MC, Lopez M, Mora F and Primo V: 'Core out' or 'curettage' in rectal advancement flap for cryptoglandular anal fistula. *Int J Colorectal Dis* 30: 613-619, 2015.
35. Omar W, Alqasaby A, Abdelnaby M, Youssef M, Shalaby M, Anwar Abdel-Razik M and Emile SH: Drainage seton versus external anal sphincter-sparing seton after rerouting of the fistula tract in the treatment of complex anal fistula: A randomized controlled trial. *Dis Colon Rectum* 62: 980-987, 2019.
36. El-Said M, Emile S, Shalaby M, Abdel-Razik MA, Elbaz SA, Elshobaky A, Elkaffas H and Khafagy W: Outcome of Modified Park's technique for treatment of complex anal fistula. *J Surg Res* 235: 536-542, 2019.
37. Garg P, Song J, Bhatia A, Kalia H and Menon GR: The efficacy of anal fistula plug in fistula-in-ano: A systematic review. *Colorectal Dis* 12: 965-970, 2010.
38. Garg P, Kaur B, Goyal A, Yagnik VD, Dawka S and Menon GR: Lessons learned from an audit of 1250 anal fistula patients operated at a single center: A retrospective review. *World J Gastrointest Surg* 13: 340-354, 2021.
39. Mei Z, Wang Q, Zhang Y, Liu P, Ge M, Du P, Yang W and He Y: Risk Factors for Recurrence after anal fistula surgery: A meta-analysis. *Int J Surg* 69: 153-164, 2019.
40. Garg P, Kaur B, Singla K, Menon GR and Yagnik VD: A simple protocol to effectively manage anal fistulas with no obvious internal opening. *Clin Exp Gastroenterol* 14: 33-44, 2021.
41. Yagnik VD, Kaur B, Dawka S, Sohal A, Menon GR and Garg P: Non-Locatable internal opening in anal fistula associated with acute abscess and its definitive management by garg protocol. *Clin Exp Gastroenterol* 15: 189-198, 2022.
42. Rojanasakul A, Booning N, Huimin L, Pongpirul K and Sahakitrungruang C: Intersphincteric exploration with ligation of intersphincteric fistula tract or attempted closure of internal opening for acute anorectal abscesses. *Dis Colon Rectum* 64: 438-445, 2021.
43. Garg P: Comparison between recent sphincter-sparing procedures for complex anal fistulas-ligation of intersphincteric tract vs transanal opening of intersphincteric space. *World J Gastrointest Surg* 14: 374-382, 2022.
44. Tang CL, Chew SP and Seow-Choen F: Prospective randomized trial of drainage alone vs. drainage and fistulotomy for acute perianal abscesses with proven internal opening. *Dis Colon Rectum* 39: 1415-1417, 1996.
45. Tian Z, Li YL, Nan SJ, Xiu WC and Wang YQ: Video-assisted anal fistula treatment for complex anorectal fistulas in adults: A systematic review and meta-analysis. *Tech Coloproctol* 26: 783-795, 2022.

