

Anesthetic considerations in a patient with multiple system atrophy-cerebellar for lower limb surgery

Sir,

A 61-year-old male with multiple system atrophy-cerebellar type (MSA-C) was posted for fracture shaft of the right femur fixation. His magnetic resonance imaging of the brain revealed the classic hot cross bun sign [Figure 1a and b]. He had syncope, intension tremors, dysdiadochokinesia, decreased plantar reflexes, positive Babinski sign, sluggish reaction of pupils to light, vocal cords paresis, and positive tonometric hand grip and cold pressor tests. His heart rate was 68 beats/min with no sinus arrhythmia. Blood pressure was 110/70 mmHg with insignificant postural variation. His relevant blood and clinical investigations were within normal limits.

After an informed high-risk consent, monitors were attached. Central venous and invasive blood pressures were also measured. Injection ondansetron 0.1 mg/kg was given. After preloading with 10 ml/kg lactated Ringer's solution, combined spinal epidural anesthesia (CSEA) was administered. Sensory level of T10 was achieved with intrathecal 2.5 ml of 0.5% bupivacaine (hyperbaric). Hypotension was corrected with injection phenylephrine 50 mcg intravenously. Five milliliters of 0.5% bupivacaine (normobaric) was given on regression of sensory level. Surgery lasted for 3 h and blood loss was within allowable limits. Patient's vitals remained stable. Postoperative continuous epidural infusion with 5 ml/h of 0.125% bupivacaine (normobaric) facilitated early mobilization.

MSA-C denotes a distinctive motor subtype characterized by progressive adult-onset sporadic gait ataxia, scanning dysarthria, limb ataxia, and cerebellar oculomotor dysfunction. In addition, there is an autonomic failure and variable degrees of parkinsonism.^[1] At present, no definitive cure is available.

The anesthetic considerations are as follows:

- **Airway:** MSA may manifest with central or obstructive sleep apnea, dysrhythmia, dyspnea, hypoxemia, inspiratory sighs, and laryngeal stridor.^[2] Selective paralysis of vocal cord abductors worsens during sleep and may lead to airway obstruction and death.^[3] When administered general anesthesia (GA), patients may require prolonged ventilation, reintubation, or emergency tracheostomy postoperatively
- **Hemodynamics:** Autonomic neuropathy involves both sympathetic and parasympathetic nervous systems. Supine hypertension induces pressure natriuresis and worsens orthostatic hypotension.^[4] It occurs due to fluid redistribution from inferior limbs; medications such as

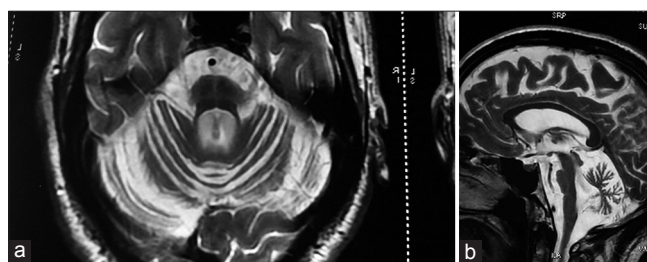


Figure 1: (a) The hot cross bun sign of pons (b) T2 flair hyperintense signal of pons

9-alpha-fludrocortisone, impairment of baroreceptor activity, and sympathetic hypersensitivity.^[5] GA may cause arrhythmias or hypertension (tracheal intubation/extubation), or hypotension (induction agents, volatile anesthetics, or positive pressure ventilation) aggravated with positioning and rapid blood loss or fluid resuscitation. Subarachnoid block may cause profound hypotension

- Risk of aspiration due to impaired gastric motility
- Thermoregulation: Inability to sweat or lacking thermoregulatory vasoconstriction^[4] causes hypo/hyperthermia
- Procedural and patient positioning difficulties due to tremors, dystonia, and rigidity. Aseptic necrosis of pressure points may occur due to impaired periosteal vascular control
- Patient noncooperation due to depression or cognitive impairment
- **Drugs:** Patients may show increased sensitivity or resistance to vasopressor and vasoactive drugs. Phenylephrine with selective adrenergic alpha-1 agonist activity and early peak effect is preferred for hypotension. The enzyme dopamine beta-hydroxylase which converts dopamine to norepinephrine may be deficient or completely absent.^[4] Hence, noradrenaline is the preferred vasopressor. Bradycardia may not respond to atropine since vagal tone is already diminished. Hence, alternatives such as isoproterenol and temporary pacemaker can be lifesaving.^[4] Opioids are avoided. The effects of prolonged steroid (fludrocortisone) treatment should be considered.

Our patient was cooperative with mild tremors, dysautonomia, and vocal cord dystonia. Thus, the previously unreported CSEA (with titrated drug dosages) seemed better with lesser airway complications and hemodynamic fluctuations compared to general or spinal anesthesia. Continuous epidural analgesia postoperatively provided excellent patient satisfaction and early ambulation. To conclude, in MSA-C patients, managing

the three D's - Dysautonomia, Dystonia (vocal cords), and Drugs with guided fluid therapy are the cornerstone for a successful outcome.

Financial support and sponsorship

Nil.

Conflicts of interest

There are no conflicts of interest.

SANDHYA AGARWAL, RITU AGGARWAL

Department of Anaesthesiology and Critical Care, Deen Dayal Upadhyay Hospital, New Delhi, India

Address for correspondence:


Dr. Ritu Aggarwal,
Department of Anaesthesiology and Critical Care, Deen Dayal Upadhyay Hospital, Hari Nagar, New Delhi, India.
E-mail: rituagg20@rediff.com

References

1. Ciolli L, Krismer F, Nicoletti F, Wenning GK. An update on the cerebellar subtype of multiple system atrophy. *Cerebellum Ataxias* 2014;1:14.
2. Flabeau O, Meissner WG, Tison F. Multiple system atrophy: Current and future approaches to management. *Ther Adv Neurol Disord* 2010;3:249-63.

3. Lim YS, Kennedy NJ. Multiple system atrophy as a cause of upper airway obstruction. *Anesthesia* 2007;62:1179-82.
4. Mustafa HI, Fessel JP, Barwise J, Shannon JR, Raj SR, Diedrich A, *et al.* Dysautonomia: Perioperative implications. *Anesthesiology* 2012;116:205-15.
5. Jordan J, Biaggioni I. Diagnosis and treatment of supine hypertension in autonomic failure patients with orthostatic hypotension *J Clin Hypertens (Greenwich)* 2002;4:139-45.

This is an open access article distributed under the terms of the Creative Commons Attribution-NonCommercial-ShareAlike 3.0 License, which allows others to remix, tweak, and build upon the work non-commercially, as long as the author is credited and the new creations are licensed under the identical terms.

Access this article online	
<p>Website: www.saudija.org</p>	<p>Quick Response Code</p> 
<p>DOI: 10.4103/sja.SJA_57_17</p>	

How to cite this article: Agarwal S, Aggarwal R. Anesthetic considerations in a patient with multiple system atrophy-cerebellar for lower limb surgery. *Saudi J Anaesth* 2017;11:365-6.

© 2017 Saudi Journal of Anesthesia | Published by Wolters Kluwer - Medknow