



Feasibility of anterior pedicle screw fixation in lumbosacral spine: a radiographic and cadaveric study

Wei-Xing Xu, Bin Xu, Wei-Guo Ding, Hong-Feng Sheng, Di Lu, Tian-Hong Hu

Department of Orthopaedics, Tongde Hospital of Zhejiang Province, Hangzhou, China

Contributions: (I) Conception and design: WX Xu, HF Sheng; (II) Administrative support: WX Xu; (III) Provision of study materials or patients: WX Xu; (IV) Collection and assembly of data: B Xu, HF Sheng, TH Hu; (V) Data analysis and interpretation: B Xu, WG Ding, D Lu; (VI) Manuscript writing: All authors; (VII) Final approval of manuscript: All authors.

Correspondence to: Bin Xu. Department of Orthopaedics, Tongde Hospital of Zhejiang Province, 234# Gu-cui Road, Hangzhou 310012, China. Email: spotxu@163.com.

Background: The anterior pedicle screw (APS) technique for L5 and S1 is crucial for proper anterior lumbar interbody fusion (ALIF). This study aimed to determine the projection, screw trajectory angle, and bone screw passageway length (BSPL), as well as the screw insertion regularity and the operating area within which it is safe to perform insertion.

Methods: Forty patients with low back pain, all of whom had lumbar computed tomography scans available, was included in this retrospective analysis. Radiographic parameters were measured, including: the distances from the projection to the upper endplate, lower endplate, and midline; the transverse and sagittal screw angles; and the BSPL. In addition, 10 fresh adult cadaveric lumbosacral spine segments were selected to determine the safe anatomic area in which to operate. Finally, APSs were inserted in L5 and S1 to determine the regularity of APS insertion.

Results: We measured the anterior projection parameters, including: the distances to the upper endplate (L5: 12.5 ± 1.3 mm; S1: 4.54 ± 0.87 mm), lower endplate (L5: 17.3 ± 1.6 mm), and midline (L5: 6.6 ± 0.7 mm; S1: 6.6 ± 0.6 mm); the screw trajectory angle, including the transverse screw angle (L5: $25.3 \pm 2.8^\circ$; S1: $25.7 \pm 2.6^\circ$), sagittal screw angle (L5: $17.1 \pm 1.7^\circ$; S1: $22.4 \pm 1.1^\circ$); and the BSPL (L5: 48.6 ± 3.5 mm; S1: 48.0 ± 3.5 mm). The regularity of APS insertion in L5 and S1 was determined. Upon the needle reaching a point in the lateral view, it reached the corresponding point in the anteroposterior (AP) view. The anatomic parameters of the safe operating area were as follows: the distance from the abdominal aortic bifurcation to the L5 lower edge (40.50 ± 9.40 mm); the distance from the common iliac vein confluence to the L5 lower edge (27.80 ± 8.60 mm); and the horizontal distance from the inner edge of the common iliac vein to the L5 lower edge (37.50 ± 1.30 mm). We also determined the distance between S1 holes (29.30 ± 1.30 mm), the L5/S1 intervertebral height (17.20 ± 1.50 mm), and the safe operating area ($2,058.20 \pm 84.30$ mm²).

Conclusions: This study has determined the projection, screw trajectory angle, and BSPL of APSs in L5 and S1, their insertion regularity, and the area in which the operation can be safely performed.

Keywords: Anterior pedicle screw (APS); lumbosacral spine; radiographic measurement; safe operating area

Submitted Mar 23, 2021. Accepted for publication Jun 03, 2021.

doi: 10.21037/atm-21-2143

View this article at: <http://dx.doi.org/10.21037/atm-21-2143>

Introduction

Lumbar interbody fusion is an effective treatment for spinal disease, including recurrent disc degeneration,

spondylolisthesis, degenerative disc disease, pseudarthrosis, and spine deformity, spine infection, and tumors (1,2). Compared with posterior lumbar interbody fusion, anterior lumbar interbody fusion (ALIF) has the potential to permit

more extensive disc removal, avoid scarring of the neural canal, and preserve the posterior elements (3). Because biomechanical studies and clinical experience suggest that ALIF augmented with a posterior pedicle screw (ALIF-PPS) provides a superior construct, it is the technique used most often at present. However, ALIF-PPS can increase the number of incisions, the operating time, and blood loss. Stand-alone ALIF has the potential benefits of having a shorter operating time, less blood loss, and avoiding posterior muscle damage (4,5).

Hence, many anterior lumbar internal fixation systems for ALIF have been designed and applied, most of which are vertebral screw-plate fixation systems, with stability and biomechanical properties that are worse than those of pedicle screw fixation systems (3). Compared with the vertebral screw-plate fixation system, the pedicle screw fixation system is simple to use and provides good stability for 3-column spinal injuries. Thus, augmentation with an anterior pedicle screw (APS) would provide better stability for ALIF. Karim *et al.*, who presented a technique that allows the ALIF procedure to be augmented with an APS (ALIF-APS) fixation, found that the stability of the ALIF-APS technique is comparable to that provided with ALIF-PPS (3). However, they did not provide the detailed procedure for APS fixation, including the parameters of projection, screw trajectory angle, and screw depth.

As 2 of the most frequently involved segments of the spine, both L5 and S1 have complex anterior anatomy and unique biomechanics, which pose a clinical challenge for anterior surgical treatment. Due to the complexity of the lumbosacral anatomic structure, ALIF is associated with various complications, including vascular complications, abdominal wall problems, and bladder, nerve, ureter, and bowel injuries (6). With respect to the complex anatomy of the anterior lumbosacral area and the related surrounding tissue, the concept of a clear space zone (a triangular area on major blood vessels or nerve trunks) in front of the lumbosacral spine has emerged (7). The detailed anatomic parameters of the clear space zone, however, remain unknown.

We therefore conducted this study to obtain radiographic measurements of the insertion of APSs in L5 and S1, which we expected to reveal the following: (I) the position of the APS projection; (II) the screw's trajectory angle, including the transverse screw and sagittal screw angles; (III) the bone screw passageway length (BSPL); (IV) the regularity of APS insertion; and (V) the anatomic parameters of the safe operating area.

We present the following article in accordance with the STROBE reporting checklist (available at <http://dx.doi.org/10.21037/atm-21-2143>).

Methods

Specimens

We used 10 dry adult cadaveric lumbosacral spine segments in this study. Exclusion criteria for the specimens included (I) the presence of destructive pathology (tumor, infection, prior surgery, or severe degeneration) and (II) severe osteoporosis.

Guide needle placement

The Ebraheim method (8) was used to determine the pedicle axis and the anterior projection point of both L5 and S1. Line X in the transverse plane and line Y in the sagittal plane were drawn on the specimens, as described previously (8). The 2 lines intersected on the anterior aspect, and the crossing point was marked as the anterior pedicle axis projection point. Guide needles (Kirschner wire) were inserted from the anterior pedicle axis projection point along lines X and Y, according to the sagittal and transverse angles. In total, 20 needles were inserted to guide the APS in each segment (both sides of the 10 cadaveric segments). C-arm radiography was performed when the front end of the guide needle was at each of 4 points (anterior projection point, middle of the vertebra, posterior edge of the vertebra, the posterior projection point) to ensure accurate positioning of the guide needle. The regularity of the 4 points, which also meant the trajectory of the pedicle guide needle, was recorded.

Parameter measurements

All procedures performed in this study involving human participants were in accordance with the Declaration of Helsinki (as revised in 2013). This study was approved by the Ethics Committee of Tongde Hospital of Zhejiang Province (2019-098). Individual consent for this retrospective analysis was waived.

From Jun 2020 to October 2020, we retrospectively included 40 patients with low back pain in Tongde hospital of Zhejiang province, each of whom had undergone lumbar CT scanning. None of the patients had lumbar structural damage, malformations, a history of surgery, or lumbosacral transitional vertebrae. Syngo 3D software

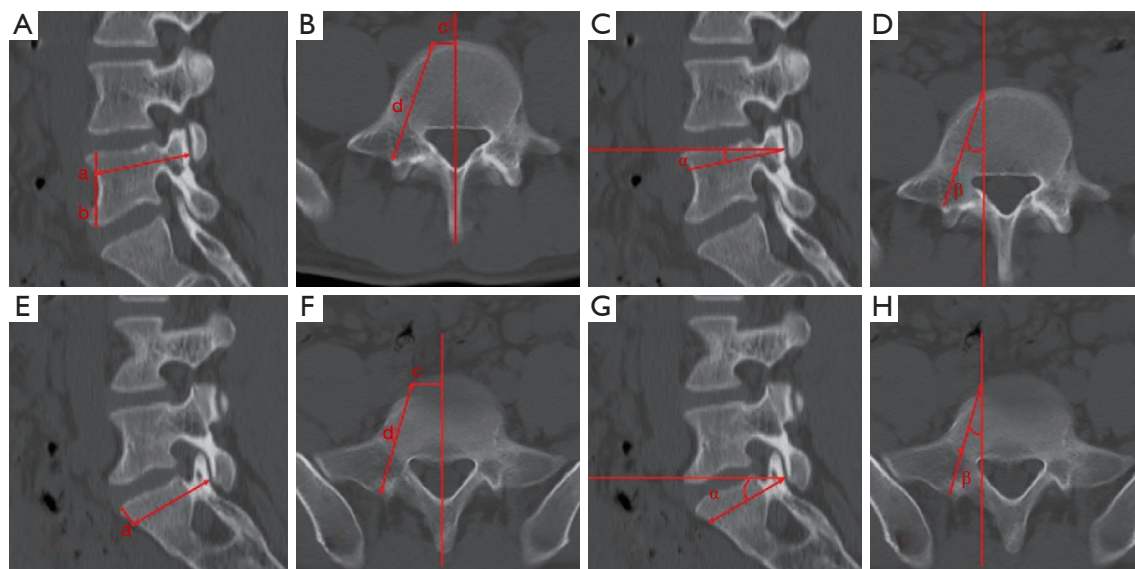


Figure 1 Radiographic parameter measurements of anterior projection in patients. (A,B,C,D) Show L5, and (E,F,G,H) show S1. Distance to upper endplate (a); distance to lower endplate (b); distance to midline (c); bone screw passageway length (d); sagittal screw angle (α); and transverse screw angle (β).

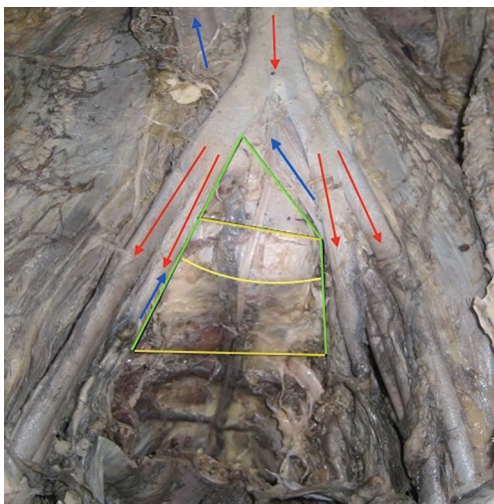


Figure 2 The safe operating area. The red arrows represent arteries; the blue arrows represent veins; the green lines represent the inner edge of the internal iliac veins; the upper yellow line represents the lower endplate of L5, the middle yellow line represents the upper endplate of S1 and the lower yellow line represent the connecting line between both sacral foramina of S1. The safe operating area is the area within the green lines and the lower yellow line.

(Siemens Medical Solutions USA, Inc., Malvern, PA, USA) was used to perform radiographic measurements (*Figure 1*), including the anatomic parameters of anterior projection (distances to the upper endplate, lower endplate, and midline), and the theoretical transverse screw angle, sagittal screw angle, and BSPL. Anatomical parameter measurements were performed using calipers and a standard ruler (precision of 1 mm) for linear measurements. The safe operating area was calculated in the cadaveric specimens. The parameters included the safe operating area (distance from the abdominal aortic bifurcation to the L5 lower edge, distance from the common iliac vein confluence to the L5 lower edge, horizontal distance from the inner edge of the common iliac vein to the L5 lower edge, distance between S1 holes, L5/S1 vertebral height, and the area in which operating was safe; *Figure 2*). Two investigators independently measured and recorded the outcome. The mean was calculated as the final result.

Statistical analysis

All data analysis was performed by SPSS version 22 (SPSS

Table 1 Radiographic parameters of anterior entry point, screw angle, and bone screw passageway length in L5 and S1 ($\bar{x}\pm s$, n=40)

Parameters	L5	S1
Distance to upper endplate (mm)	12.5±1.3	4.54±0.87
Distance to lower endplate (mm)	17.3±1.6	–
Distance to midline (mm)	6.6±0.7	6.6±0.6
Transverse screw angle (°)	25.3±2.8	25.7±2.6
Sagittal screw angle (°)	17.1±1.7	22.4±1.1
Bone screw passageway length (mm)	48.6±3.5	48.0±3.5

Inc., USA). The measurement data was presented as mean \pm standard deviation.

Results

Anterior entry point, screw angle, and BSPL of L5 and S1 in the patients

The anterior projection parameters for L5 and S1 in the patients are listed in *Table 1*.

Regularity of APS insertion

The regularity of APS insertion in L5 and S1 is shown in *Figures 3* and *4*, respectively. When the needle was in the anterior projection in the lateral view, it was at the midpoint between the spinous process and the inner edge of the pedicle in the anteroposterior (AP) view. When it reached the posterior vertebral edge in the lateral view, it was at the inner edge of the pedicle in the AP view. When it reached the middle of the pedicle in the lateral view, it was in the middle of the pedicle in the AP view. Finally, when the needle reached the posterior projection in the lateral view, it was at the outer edge of the pedicle in the AP view.

Safe operating area

Our study found that the anatomic parameters of the safe operating area were as follows: the distance from the abdominal aortic bifurcation to the L5 lower edge (40.50±9.40 mm); the distance from the common iliac vein confluence to the L5 lower edge (27.80±8.60 mm); and the horizontal distance from the inner edge of the common iliac vein to the L5 lower edge (37.50±1.30 mm). We also determined the distance between S1 holes (29.30±1.30 mm),

the L5/S1 intervertebral height (17.20±1.50 mm), and the safe operating area (2,058.20±84.30 mm²).

Discussion

Since Boucher initially reported using a posterior transpedicular screw for lumbosacral fusion fixation in 1959 (9), various pedicle screw fixation systems have been used in spinal surgical procedures, because they provide superior postoperative spinal stability and have promoted advances in spinal surgery (10). Various studies have researched PPS procedures in detail, including the projection parameters, trajectory angle, and depth of screw insertion (11,12), as well as the regularity of pedicle screw insertion (12), each of which is important if PPS is to be performed with high accuracy.

As an effective method of pedicle screw fixation, the APS not only provides superior postoperative spinal stability for ALIF, but ensures a shorter operating time, less blood loss, and minimal posterior muscle damage (4,5). ALIF was begun to be developed from 1932, as posterior approaches were correlated with higher morbidity including paravertebral musculature disruption, sagittal imbalance and pseudarthrosis (1). There are many anterior lumbar internal fixation systems for ALIF have been developed, including femoral ring allografts (13), stand-alone lumbar interbody cage (14), anterior locking plates (15) and APS (16). Gerber *et al.* compared the biomechanical flexibility among stand-alone ALIF, ALIF plus anterior screw-plate and ALIF plus posterior pedicle screws-rods, found that biomechanical stability of an L5–S1 ALIF with anterior screw-plate fixation was not significantly different from the stability of an L5–S1 ALIF with pedicle screws-rods (17). Karim *et al.* demonstrate a new technique in a cadaveric specimen whereby the ALIF procedure is augmented with APS fixation and found the ALIF-APS has comparable stability with ALIF-PPS (3). Limited studies, however, have reported on the details of procedures using the APS.

We conducted the present study to determine the anatomic and radiographic parameters of L5 and S1, including projection, the screw's trajectory angle, and the depth of insertion. We found limited information in the literature on the location of the anterior projection, which is important for maximal performance of the APS. Poor placement of the projection may cause the guide needle to be misplaced and result in complications.

The anterior projection in our study was based on the

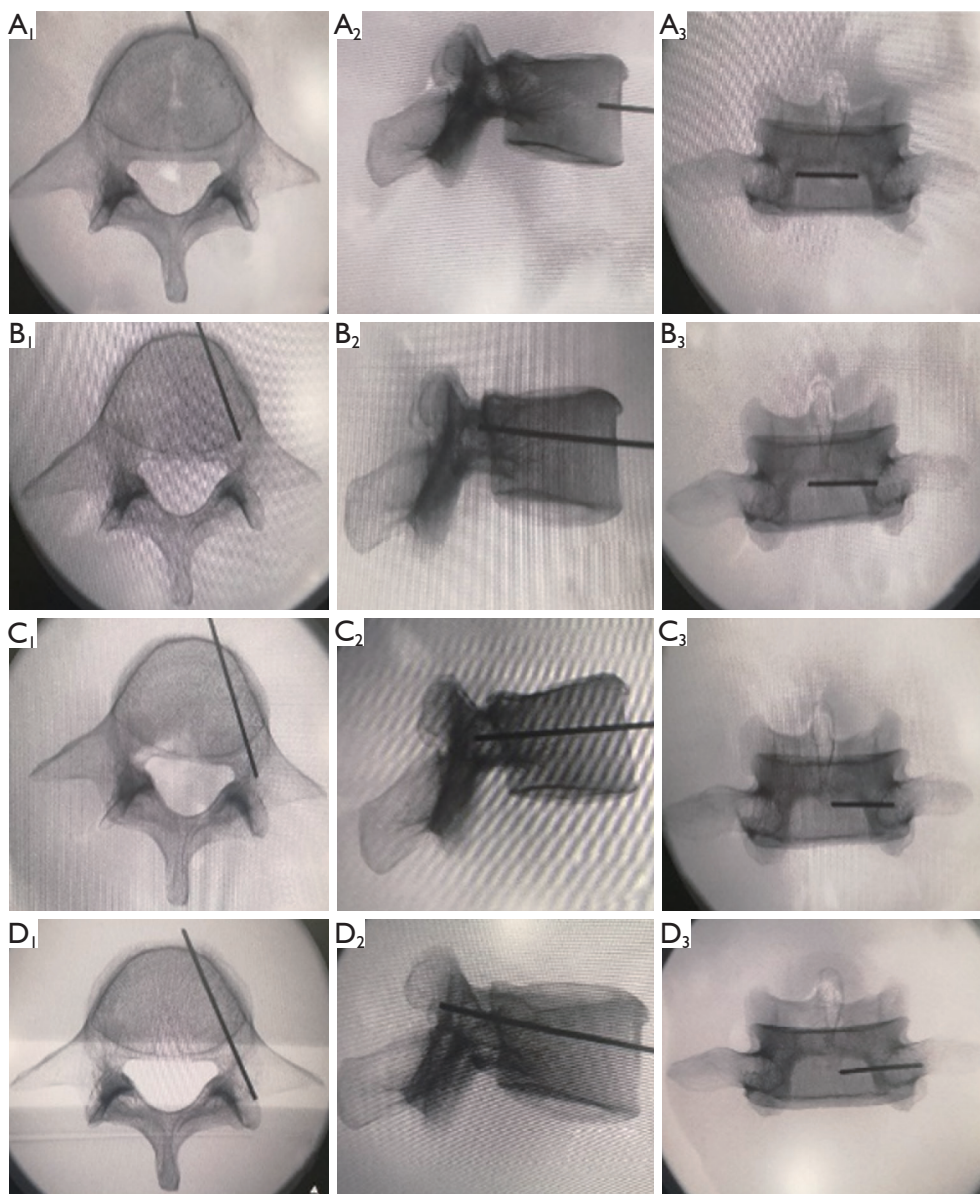


Figure 3 The regularity of anterior pedicle screw insertion in L5 of the cadaveric specimens. Anterior projection point in the vertical view (A1), lateral view (A2), and anteroposterior (AP) view (A3). Middle of the vertebrae in the vertical view (B1), lateral view (B2), and AP view (B3). Posterior edge of the vertebrae in the vertical view (C1), lateral view (C2), and AP view (C3). Posterior projection point in the vertical view (D1), lateral view (D2), and AP view (D3).

method of Ebraheim *et al.* (8). The parameters used to determine its location included the distances of the APS to the upper endplate, lower endplate, and midline. The screw trajectory angle was also determined (8), and the transverse and sagittal screw angles were measured. The screw trajectory angles for the APS and PPS in the same patient should be the same. Ebraheim *et al.* (8) reported

that the transverse angle of L5 was $40.6 \pm 2.6^\circ$ in men and $39.6 \pm 3.2^\circ$ in women, while the sagittal angle of L5 was $2.7 \pm 1.1^\circ$ in men and $2.6 \pm 0.9^\circ$ in women. To determine the screw trajectory depth, the BSPL was measured. Ebraheim *et al.* (8) also reported that the pedicle length of L5 was 48.3 ± 2.3 mm in men and 48.3 ± 2.4 mm in women. Our anatomic measurements revealed a BSPL of 48.6 ± 3.5 mm

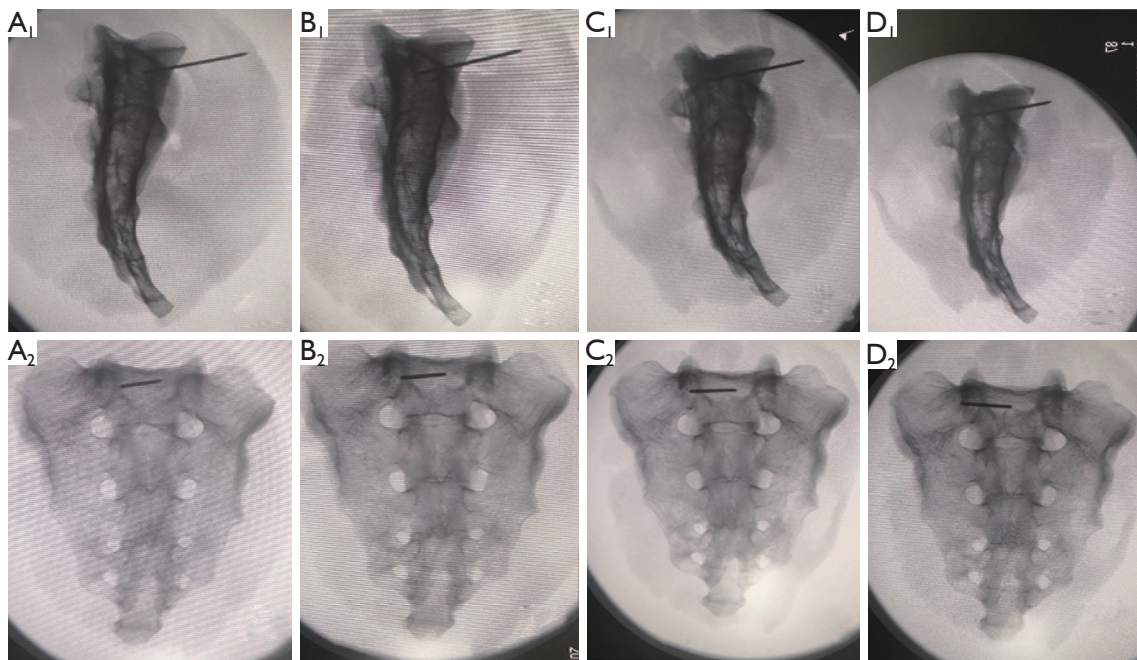


Figure 4 The regularity of anterior pedicle screw insertion in S1 of the cadaveric specimens. Anterior projection point in the lateral view (A1) and anteroposterior (AP) view (A2). Middle of the vertebrae in the lateral view (B1) and AP view (B2). Posterior edge of the vertebrae in the lateral view (C1) and AP view (C2). Posterior projection point in the lateral view (D1) and AP view (D2).

for L5 and 48.0 ± 3.5 mm for S1. We found that the body size of the patients, including height, rather than their sex, was responsible for measurement differences.

The BSPL is defined by the length of the screw. Because the vertebra forms an irregular cylinder, with the front of vertebral body exhibiting the most anterior border in the lateral view, the needle may perforate the anterolateral cortex, even though the lateral view suggests that the needle is still within the vertebra (11). Therefore, it is important to obtain the ideal needle depth/vertebral width ratio on the lateral view. Weinstein *et al.* considered the suitable ratio to be 50–80% (18). Du *et al.* suggested that the ratio should be 85–90% in the lumbar vertebrae (19), whereas Açıkbash and Tuncer reported that the suitable ratio was $60\% \pm 9\%$ in the lumbar vertebrae (20). Wang *et al.* found that the ratio was not the same in different lateral projection angle views, even if the real length of the needle in the vertebra remained unchanged (11). They suggested that the suitable ratio of the needle depth/vertebral width ratio in the standard lateral view varied from $71.53\% \pm 5.72\%$ to $93.28\% \pm 3.72\%$ and that the ratio for L5 was $88.20\% \pm 6.72\%$. More work is obviously needed to establish the suitable ratio for the APS needle depth.

We also evaluated the regularity of APS insertion in this study, which was guided with high accuracy. A previous study (12) reported that the regularity of PPS insertion was apparent when, progressively, the needle reached the posterior projection in the lateral view, was on the outer edge of the pedicle in the AP view, reached the middle of the pedicle (lateral view), was in the middle of the pedicle (AP view), reached the posterior vertebral edge (lateral view), and was at the inner edge of the pedicle (AP view). Wang *et al.* reported that the posterior projection of PPS was at the 9 o'clock to 11 o'clock position of the left pedicle and at the 1 o'clock to 3 o'clock position of the right pedicle (11). This regularity can also be applied to the APS when the needle reaches the posterior projection.

Compared with PPS, APS has a higher risk of damaging lumbar vessels. There is great variability in the vascular anatomy in front of the L5–S1 disc space. The left common iliac vein is at greater risk than the common iliac arteries (3). Ebraheim *et al.* found a triangular safety zone averaging 60 mm in width and 40 mm in height between the left common iliac vein and the right common iliac artery in 40 human cadavers (21). In our study, we found that the distance from the abdominal aortic bifurcation to

the L5 lower edge was 40.50 ± 9.40 mm, the distance from the common iliac vein confluence to the L5 lower edge was 27.80 ± 8.60 mm, and the horizontal distance from the inner edge of the common iliac vein to the L5 lower edge was 37.50 ± 1.30 mm, and the safe operating area was $2,058.20 \pm 84.30$ mm².

Lumbar fusion has been shown to accelerate adjacent segments degeneration (ASD) and it has been reported that ALIF may have an advantage over PLIF in preventing ASD (22). Compared with PLIF, ALIF is less likely to damage the integrity of the posterior complex, which may be helpful in preventing accelerated ASD after spinal fusion (23). Although percutaneous PPS during ALIF has been performed (24), we believe that APS has comparable results to PPS with the potential benefit of preventing accelerated ASD, and more studies should be performed on this topic.

There are several limitations in our study: (I) the sample size of our study is relatively small, further study with larger sample size is need to confirm these results; (II) only adults were included in this study, the characteristics about children need to be studied in the future.

Conclusions

We successfully measured the projection, screw trajectory angle, and BSPL of the APS in L5 and S1, proved its insertion regularity, and determined the safe operating area. These results can guide APS insertion and improve its accuracy. We plan to use the APS in L5 and S1 based on these results and will evaluate the accuracy of positioning the screw.

Acknowledgments

We thank Nancy Schatken BS, MT(ASCP), from Liwen Bianji, Edanz Group China (www.liwenbianji.cn/ac), for editing the English text of a draft of this manuscript.

Funding: The study was supported by the Zhejiang Province Public Welfare Technology Application Research Project (CN) (LGF19H060006). The costs involving designing the study, collection, analysis, interpretation of data are funded by this project.

Footnote

Reporting Checklist: The authors have completed the STROBE reporting checklist. Available at <http://dx.doi.org/10.21037/atm-21-2143>

<http://dx.doi.org/10.21037/atm-21-2143>

Data Sharing Statement: Available at <http://dx.doi.org/10.21037/atm-21-2143>

Conflicts of Interest: All authors have completed the ICMJE uniform disclosure form (available at <http://dx.doi.org/10.21037/atm-21-2143>). The authors report that the study was supported by Zhejiang Province Public Welfare Technology Application Research Project (CN) (LGF19H060006). The authors have no other conflicts of interest to declare.

Ethical Statement: The authors are accountable for all aspects of the work in ensuring that questions related to the accuracy or integrity of any part of the work are appropriately investigated and resolved. All procedures performed in this study involving human participants were in accordance with the Declaration of Helsinki (as revised in 2013). This study was approved by the Ethics Committee of Tongde Hospital of Zhejiang Province (2019-098). Individual consent for this retrospective analysis was waived.

Open Access Statement: This is an Open Access article distributed in accordance with the Creative Commons Attribution-NonCommercial-NoDerivs 4.0 International License (CC BY-NC-ND 4.0), which permits the non-commercial replication and distribution of the article with the strict proviso that no changes or edits are made and the original work is properly cited (including links to both the formal publication through the relevant DOI and the license). See: <https://creativecommons.org/licenses/by-nc-nd/4.0/>.

References

- Giang G, Mobbs R, Phan S, et al. Evaluating outcomes of stand-alone anterior lumbar interbody fusion: a systematic review. *World Neurosurg* 2017;104:259-71.
- Hoff EK, Strube P, Pumberger M, et al. ALIF and total disc replacement versus 2-level circumferential fusion with TLIF: a prospective, randomized, clinical and radiological trial. *Eur Spine J* 2016;25:1558-66.
- Karim A, Mukherjee D, Ankem M, et al. Augmentation of anterior lumbar interbody fusion with anterior pedicle screw fixation: demonstration of novel constructs and evaluation of biomechanical stability in cadaveric specimens. *Neurosurgery* 2006;58:522-7.
- Choi KC, Kim JS, Shim HK, et al. Changes in

- the Adjacent Segment 10 Years After Anterior Lumbar Interbody Fusion for Low-Grade Isthmic Spondylolisthesis. *Clin Orthop Relat Res* 2014;472:1845.
5. Wang WJ, Chen WK, Yan YG, et al. Application of anterior debridement and reconstruction with anatomical screw-plate fixation for lumbosacral tuberculosis: A 2-year-plus follow-up. *Medicine* 2017;96:e7103.
 6. Wang W, Liu S, He G, et al. Application of Laparoscopic Lumbar Discectomy and Artificial Disc Replacement: At Least Two Years of Follow-Up. *Spine* 2016;41 Suppl 19:B38.
 7. Inamasu J, Kim DH, Logan L. Three-dimensional computed tomographic anatomy of the abdominal great vessels pertinent to L4-L5 anterior lumbar interbody fusion. *Minim Invasive Neurosurg* 2005;48:127-31.
 8. Ebraheim NA, Rollins JR Jr, Xu R, et al. Projection of the lumbar pedicle and its morphometric analysis. *Spine (Phila Pa 1976)* 1996;21:1296-300.
 9. Boucher HH. A method of spinal fusion. *J Bone Joint Surg Br* 1959;41-B:248-59.
 10. Kasten MD, Rao LA, Priest B. Long-term results of iliac wing fixation below extensive fusions in ambulatory adult patients with spinal disorders. *J Spinal Disord Tech* 2010;23:e37-42.
 11. Wang G, Yang H, Chen X, et al. Standard fluoroscopic views in cadavers for determining the entry point and depth of a guide needle for use in transpedicular procedures of the thoracolumbar spine. *J Clin Neurosci* 2010;17:588-91.
 12. Bai JY, Zhang W, An JL, et al. True anteroposterior view pedicle screw insertion technique. *Ther Clin Risk Manag* 2016;12:1039-47.
 13. Than KD, Wang AC, Rahman SU, et al. Complication avoidance and management in anterior lumbar interbody fusion. *Neurosurg Focus* 2011;31:E6.
 14. Kornblum MB, Turner AWL, Cornwall GB, et al. Biomechanical evaluation of stand-alone lumbar polyether-ether-ketone interbody cage with integrated screws. *Spine J* 2013;13:77-84.
 15. Crawford B, Lenarz C, Watson JT, et al. Complication with removal of a lumbar spinal locking plate. *Case Rep Orthop* 2015;2015:787249.
 16. Motosuneya T, Asazuma T, Nobuta M, et al. Anterior lumbar interbody fusion: changes in area of the dural tube, disc height, and prevalence of cauda equina adhesion in magnetic resonance images. *J Spinal Disord Tech* 2005;18:18-22.
 17. Gerber M, Crawford NR, Chamberlain RH, et al. Biomechanical assessment of anterior lumbar interbody fusion with an anterior lumbosacral fixation screw-plate: comparison to stand-alone anterior lumbar interbody fusion and anterior lumbar interbody fusion with pedicle screws in an unstable human cadaver model. *Spine (Phila Pa 1976)* 2006;31:762-8.
 18. Weinstein JN, Spratt KF, Spengler D, et al. Spinal pedicle fixation: reliability and validity of roentgenogram-based assessment and surgical factors on successful screw placement. *Spine* 1988;13:1012.
 19. Du XR, Zhao LX, Ye QB. Radiological anatomy study in selecting the length of pedicle screw in lumbar spine. *Chinese Journal of Clinical Anatomy* 2002;20:15-7.
 20. Açıkbaş SC, Tuncer MR. New method for intraoperative determination of proper screw insertion or screw malposition. *J Neurosurg* 2000;93:40-4.
 21. Ebraheim NA, Xu R, Farooq A, et al. The quantitative anatomy of the iliac vessels and their relation to anterior lumbosacral approach. *J Spinal Disord* 1996;9:414-7.
 22. Lee DY, Lee SH, Maeng DH. Two-level anterior lumbar interbody fusion with percutaneous pedicle screw fixation: a minimum 3-year follow-up study. *Neurol Med Chir (Tokyo)* 2010;50:645-50.
 23. Park P, Garton HJ, Gala VC, et al. Adjacent segment disease after lumbar or lumbosacral fusion: review of the literature. *Spine* 2004;29:1938-44.
 24. Min JH, Jang JS, Lee SH. Comparison of anterior- and posterior-approach instrumented lumbar interbody fusion for spondylolisthesis. *J Neurosurg Spine* 2007;7:21-6.

(English Language Editor: K. Brown)

Cite this article as: Xu WX, Xu B, Ding WG, Sheng HF, Lu D, Hu TH. Feasibility of anterior pedicle screw fixation in lumbosacral spine: a radiographic and cadaveric study. *Ann Transl Med* 2021;9(12):968. doi: 10.21037/atm-21-2143