

Received: 2017.10.10
Accepted: 2017.11.14
Published: 2017.11.29

Clinical Efficacy of Anterior Partial Corpectomy and Titanium Mesh Fusion and Internal Fixation for Treatment of Old Fracture Dislocation of the Lower Cervical Spine

Authors' Contribution:
Study Design A
Data Collection B
Statistical Analysis C
Data Interpretation D
Manuscript Preparation E
Literature Search F
Funds Collection G

ABEF De-chao Miao
CD Bao-yang Zhang
BC Tao Lei
AG Yong Shen

Department of Spine Surgery, The Third Hospital of Hebei Medical University, Shijiazhuang, Hebei, P.R. China

Corresponding Author: Yong Shen, e-mail: 18630159778@163.com
Source of support: Departmental sources

Background: The aim of this study was to analyze the clinical features and to evaluate the efficacy of anterior partial corpectomy and titanium mesh fusion and internal fixation of old fracture dislocation of the lower cervical spine.





Material/Methods: We retrospectively analyzed the clinical data of 52 patients with old lower cervical fracture and dislocation treated with anterior partial corpectomy and titanium mesh fusion fixation between January 2008 and December 2013, with a mean follow-up period of 4.1 years. There were 35 males and 17 females. Patient radiological data and clinical parameters were recorded and compared before and after the operations.

Results: The average follow-up was 4.1 years. Intervertebral height and physiological curvature were well-reconstructed for all cases. No loosening or rupturing of titanium plate or screw occurred. The neurological function of the patients with incomplete spinal cord injury was significantly improved, and the function of the nerve roots at the injury level was also improved in patients with complete spinal cord injury. Bone fusion was completed within 6 months to 1 year after surgery.

Conclusions: Completed decompression, sequence and physiological curvature of the cervical vertebra, immediate and long-term anterior cervical column support, and nerve function restoration can be achieved by using anterior partial corpectomy and titanium mesh fusion and internal fixation to treat old fracture dislocation of the lower cervical spine. For cases with locked facet joints or posterior structures invading the vertebral canal, the combined anterior and posterior approaches should be performed, when necessary, to achieve better results.

MeSH Keywords: **Dislocations • Fracture Fixation, Internal • Spinal Cord Injuries • Spinal Fractures**

Full-text PDF: <https://www.medscimonit.com/abstract/index/idArt/907470>

 2743  2  2  22



Background

For most cases of lower cervical fracture dislocation, the reduction of the dislocated vertebral body can be achieved by skull traction and proper reduction technique. But with more and more traffic accidents and falls from a height, there have been more cases of high-energy damage. Therefore, there is a greatly increasing incidence of fracture and dislocation of the lower cervical spine complicated with other critical organ injuries. There is also a steadily increasing number of cases of lower cervical fracture dislocation that are not identified in time, as well as delayed treatment, which can endanger life.

For most patients with old lower cervical spine fracture and dislocation, simple skull traction is often difficult to perform and surgery is often required to restore the dislocated vertebral body [1]. Old fracture and dislocation of the lower cervical spine are usually accompanied by a degree of damage to the spinal cord and nerve roots. Because of the persistent presence of dislocation and the apparent instability of the injury segment, the spinal cord is subjected to continuous static compression, which further aggravates spinal cord injury. The treatment principle is complete decompression, reconstruction of cervical spine stability, and restoring the physiological curve of the cervical spine as much as possible. The present study assessed the efficacy of anterior partial corpectomy and titanium mesh cage fusion and internal fixation for treatment of old fracture dislocation of the lower cervical spine from January 2008 to December 2013.

Material and Methods

Patients

We conducted a retrospective analysis of 52 cases (35 males and 17 females) who were diagnosed with old lower cervical fracture dislocation and who accepted anterior partial corpectomy and titanium mesh cage fusion and internal fixation surgery from January 2008 to December 2013. Patients' ages ranged from 20 to 62 years, with a mean age of 42.8 years. The causes of injury included 22 cases of falling injuries, 13 cases of bruise injuries caused by a falling heavy object, and 17 cases of road traffic injuries. The time from injury to surgery was 4–16 weeks, with an average of 8.6 weeks. Regarding preoperative spinal cord function (JOA score), complete spinal cord injury occurred in 12 cases (average JOA score of 1) and incomplete spinal cord injury in 40 cases (average JOA score of 10.1). For classification of ASIA grade, encompassing complete injury (grade A) to normal (grade E), 12 cases were grade A, 4 cases were grade B, 18 cases were grade C, 14 cases were grade D, and 4 cases were grade E (Table 1).

Imaging data

All patients were imaged using cervical X-rays, as well as CT scanning and MRI of the cervical spine. Plain radiography and CT showed dislocations at C4–C5 (14 patients), C5–C6 (20 patients), and C6–C7 (18 patients). There were 16 fractures with different degrees of anterior superior margin of the vertebral body. In all cases, there was thickening of the anterior soft tissue and deformity of the posterior segment of the dislocation, with a Cobb angle range of 5–17 degrees. Three-dimensional reconstructions of CT showed 20 cases of unilateral articular locking accompanied by a superior articular process fracture, 8 cases of bilateral facet locking, and 24 cases of bilateral fracture of the vertebral arch. The sagittal diameter of the cervical canal and the anteroposterior diameter of the vertebral body (C/V) ratio in the dislocation site was measured and calculated at the narrowest portion of the sagittal CT (Figure 1). There were 36 cases of moderate spinal canal narrow (C/V >0.5) and 16 cases of severe stenosis (C/V=0.5). The cervical spine MRI showed spinal cord hematoma and cystic degeneration, the intervertebral disc of the dislocated segment protruded posteriorly, and the lower vertebral body compressed the spinal cord.

Surgical technique (using C6–C7 dislocation as an example)

After general anesthesia, the patient placed in supine position and with the neck properly extended. The conventional anterior cervical approach was used. First, the intervertebral discs of C6–C7 and C7–T1 segments were removed, and the longus colli of both sides of C6–T1 segments was loosened at the same time. To reduce the kyphosis angle of the C6–C7 intervertebral space we opened it by using the intervertebral space distraction forceps. Caspar spreader screws were fixed perpendicular to the C6 and T1 vertebral bodies, and gradually opened to restore the height of the vertebral body when using the Caspar retractor. With the force of the retractor, the screw fixed to the C6 vertebral body was progressively moved parallel to the screw of the T1 to achieve partial correction of kyphosis. The C7 vertebral body that compressed the spinal cord was resected between the bilateral longus colli. Then, the Caspar spreader was further stretched so that the C6 and the T1 vertebral endplate were parallel to achieve restoration of the cervical spine sequence. Cartilage of the C6 lower endplate and T1 superior endplate was removed after confirmation by the intraoperative C-arm X-ray machine. Then an appropriate height of the titanium mesh cage filled with autogenous bone (the excised vertebral body) was implanted, anterior cervical spine locking titanium plate fixation was performed. Drainage was placed inside the wound, and a neck collar was used for 6 weeks postoperatively.

Table 1. General data of enrolled cases.

Variable	Number/range	Mean
Total cases	52	
Sex		
Male	35 (67.3%)	
Female	17 (32.7%)	
Age (years)	20–62	42.8
Cause of injury		
High fall injury	23 (44.3%)	
Bruise injury by heavy object	13 (25%)	
Road traffic injury	17 (32.7%)	
Duration from injury to surgery (weeks)	4–16	8.6
Spinal cord function		
Complete spinal cord injury	12 (23.1%)	
Incomplete spinal cord injury	40 (76.9%)	
Injured segment		
C4–C5	14 (26.9%)	
C5–C6	20 (38.5%)	
C6–C7	18 (34.6%)	
Type of fracture dislocation		
Unilateral facet locking	20 (38.5%)	
Bilateral facet locking	8 (15.4%)	
Bilateral fracture of the vertebral arch	24 (46.1%)	
Cervical spinal stenosis		
Moderate stenosis (C/V >0.5)	36 (69.2%)	
Severe stenosis (C/V ≤0.5)	16 (30.8%)	
Follow-up (years)	3–6	4.1

Statistical methods

SPSS 22.0 statistical software (IBM, Armonk, NY, USA) was used for statistical analysis. Data were recorded as mean ± SD, and the paired *t* test was used to compare the indexes before and after the operation. *P* value <0.05 was considered statistically significant.

Results

The average follow-up period was 4.1 years (range 3–6 years). The mean operative time was 121.5±19.9 min (range 90–150 min), and the average bleeding volume was 300±32.5 ml

(range. 250–350 ml). There were no complications such as incision infection or nerve injury. During the follow-up period, the X-ray examination showed that the height of the vertebral segments, the overall curvature of the cervical spine, and the stability of the damaged segments remained good. The correction of kyphosis was satisfactory, and the Cobb angle of kyphosis was significantly less than before the operation, but there was no significant change in Cobb angle between 3 months and 1 year postoperatively (*p*>0.05). In 12 patients with complete spinal cord injury, the root symptoms of the damage plane were relieved postoperatively, but the spinal cord function was not restored. Patients with incomplete spinal cord injury before the operation had different degrees of sensory and motor function recovery, and the JOA score was

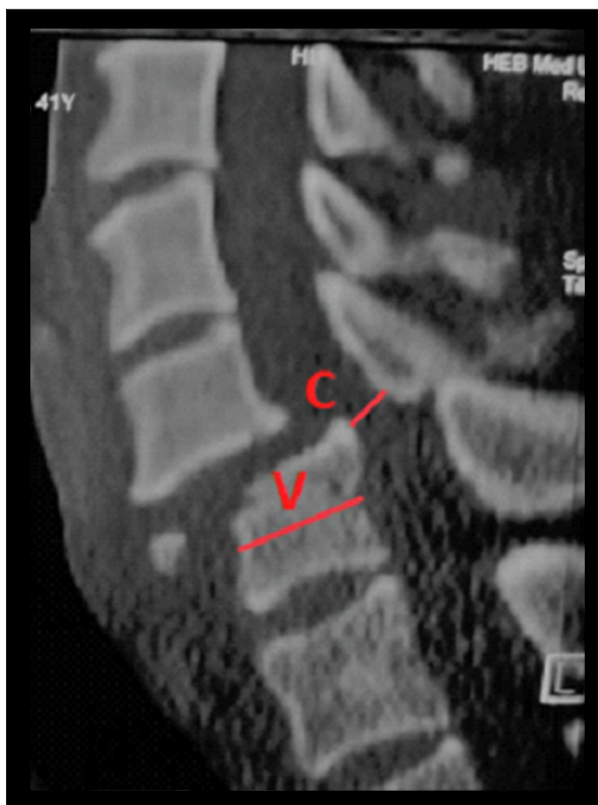


Figure 1. Calculation of C/V ratio. “C” represents the sagittal diameter of the spinal canal. “V” represents the sagittal diameter of inferior vertebral body.

significantly increased compared to before surgery and continued to improve during the whole follow-up period. The ASIA grade of most patients improved by at least 1 grade. The postoperative C/V ratio was also significantly increased in all patients after the operation, but there was no obvious change between 3 months after the operation and the last follow-up ($p > 0.05$). Bony fusion was completed at 1-year follow-up in all cases (Table 2). Figure 2 shows typical case imaging data.

Table 2. Summary of clinical outcomes.

Time points	JOA scores	Cobb angle (°)	C/V	ASIA grade				
				A	B	C	D	E
Preoperative	7.88±5.18 ^a	10.73±3.49 ^a	0.54±0.11	12	4	18	14	4
Postoperative	9.50±5.38 ^{ab}	-5.07±1.35 ^{ab}	0.86±0.05	11	3	12	18	8
3 months		-3.50±1.10 ^{bc}	0.88±0.07	10	3	7	20	12
6 months	11.15±5.35 ^{bc}			9	4	5	17	17
1 year		-3.54±0.90 ^c		8	4	2	14	24
Last follow-up	12.46±5.37 ^c		0.87±0.08	8	4	1	15	24

JOA scores: ^a $t = -8.75$, ^a $p < 0.001$; ^b $t = -6.85$, ^b $p = 0.000$; ^c $t = -8.75$, ^c $p = 0.000$; Cobb angle: ^a $t = 22.74$, ^a $p = 0.000$; ^b $t = -4.79$, ^b $p = 0.000$; ^c $t = 0.328$, ^c $p = 0.746$; C/V ratio: ^a $t = -22.66$, ^a $p = 0.000$; ^b $t = -1.39$, ^b $p = 0.176$; ^c $t = 0.313$, ^c $p = 0.757$.

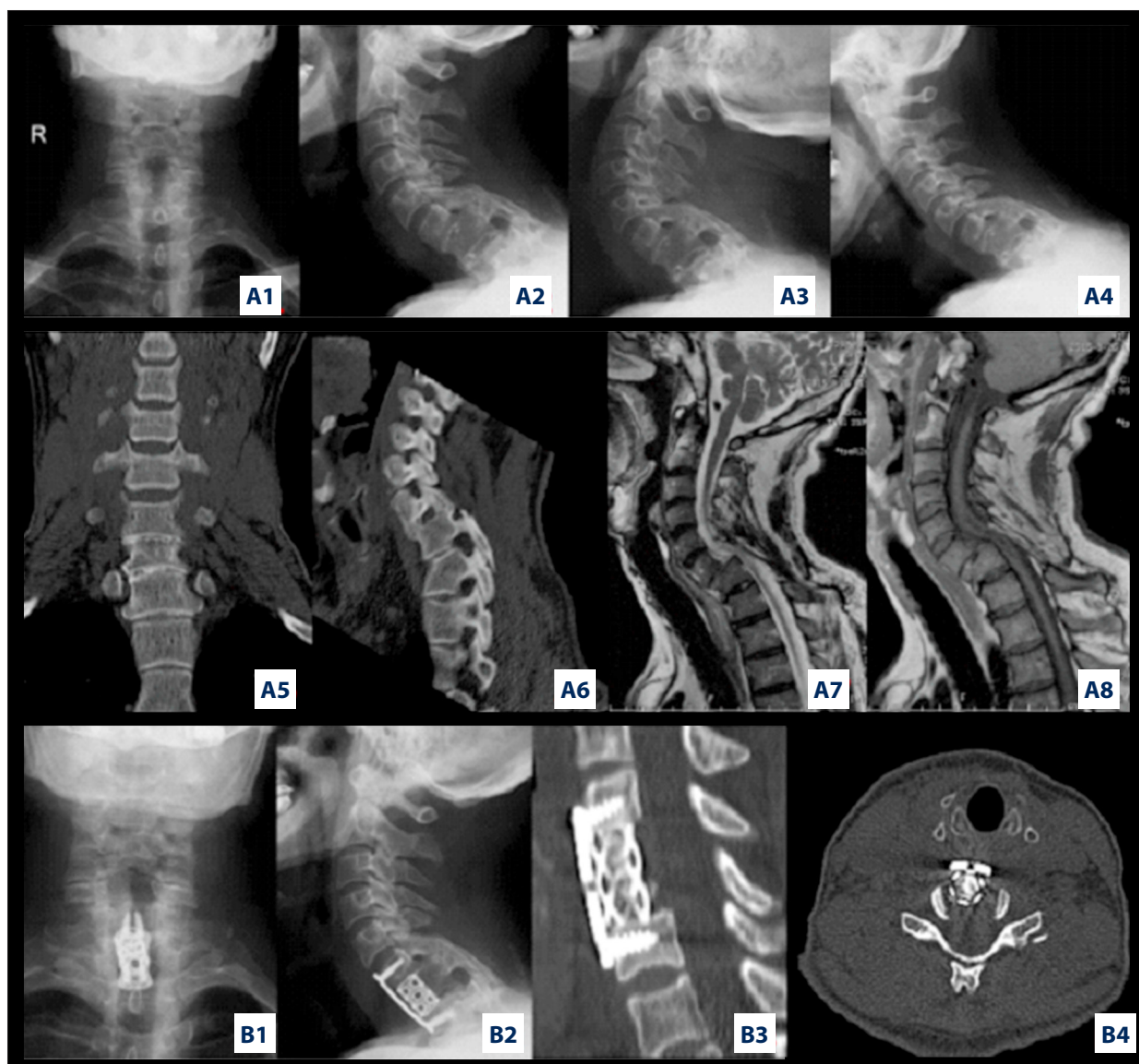
Discussion

Early treatment of cervical spine injuries is beneficial for functional recovery and avoidance of neurological deterioration [2]. Injury of the cervical spine over 3 weeks old is known as an old injury. A variety of factors can cause acute cervical injury to develop into old cervical fracture dislocation. In our study population, this was mainly due to the following reasons. First, patients with severe chest or abdominal trauma, shock, or infection did not undergo timely surgery. Second, due to severe compound injury, the patient was comatose and missed diagnosis of cervical fracture, dislocation, and spinal cord injury, or because the emergency treatment only deals with the relatively obvious trauma and disregards the treatment of fracture and dislocation of the cervical spine [3]. Third, in patients with fracture dislocation of C6–C7, X-ray examination did not reveal the lower vertebral body in some patients due to the occlusion of the shoulder blades, and no CT or MRI examinations were performed. Fourth, the treatment of fracture and dislocation of the cervical spine was inappropriate or only the skull traction was used, and no operative intervention was performed in time. The treatment principle of cervical fracture and dislocation is to restore the cervical spine sequence, relieve the compression of the spinal cord and nerve roots, and stabilize the cervical spine. In dealing with specific cases, proper surgical procedures must be selected according to specific pathological features. For old fracture dislocations, once found, the patient should be operated on as soon as possible [4].

According to the data of this group, the pathological features of the old fracture and dislocation of the lower cervical spine have the following special features. First, scar healing; in this study, all cases showed the presence of prevertebral soft tissue thickening and dislocation segment backward angular deformity, suggesting that seriously injured anterior and posterior longitudinal ligaments, intervertebral disc, interspinous ligament, and nuchal ligament have developed scar adhesion,

and the segment of the dislocation is relatively fixed. The spinal cord and nerve roots are subjected to 'static compression' sustained by the lower vertebral body at the lower segment of the dislocation. Second, there persists instability in the injured segment; in this study, preoperative flexion-extension lateral X-ray images of 32 patients showed instability in the damaged segments but could not be reset by themselves. This indicates that scar tissue lacks sufficient strength to inflict instability in the damaged segment. The spinal cord and nerve roots are constantly subject to minor shocks from the vertebral body and vertebral lamina in the dislocated state, which is 'dynamic compression'. Third, scars occupy space, resulting in traction reduction difficulties. Because the facet joint and the vertebral body continue to be dislocated, the anatomic position of the facet joint and the vertebral body is filled with sclerotic scar tissue, so closed reduction is very difficult.

Fourth, traumatic myelopathy, in which the spinal cord parenchyma and the nutrient vessels are continuously stretched and compressed, causing the spinal cord blood flow and the anterior horn cells of the spinal cord to be further damaged, and traumatic inflammation associated with segmental instability, causing some patients with incomplete spinal cord injury to have worsening spinal cord function at the later stage of injury, which is traumatic myelopathy. Because of the above features of the old cervical fracture and dislocation, the principle of treatment should be based on completely reduction and stability, without the need for absolute anatomical reduction. Decompression mainly involves the removal of the structures that directly compress the spinal cord and nerve roots, and, under the premise of complete decompression, restore the sequence of the cervical spine as much as possible [5-7].



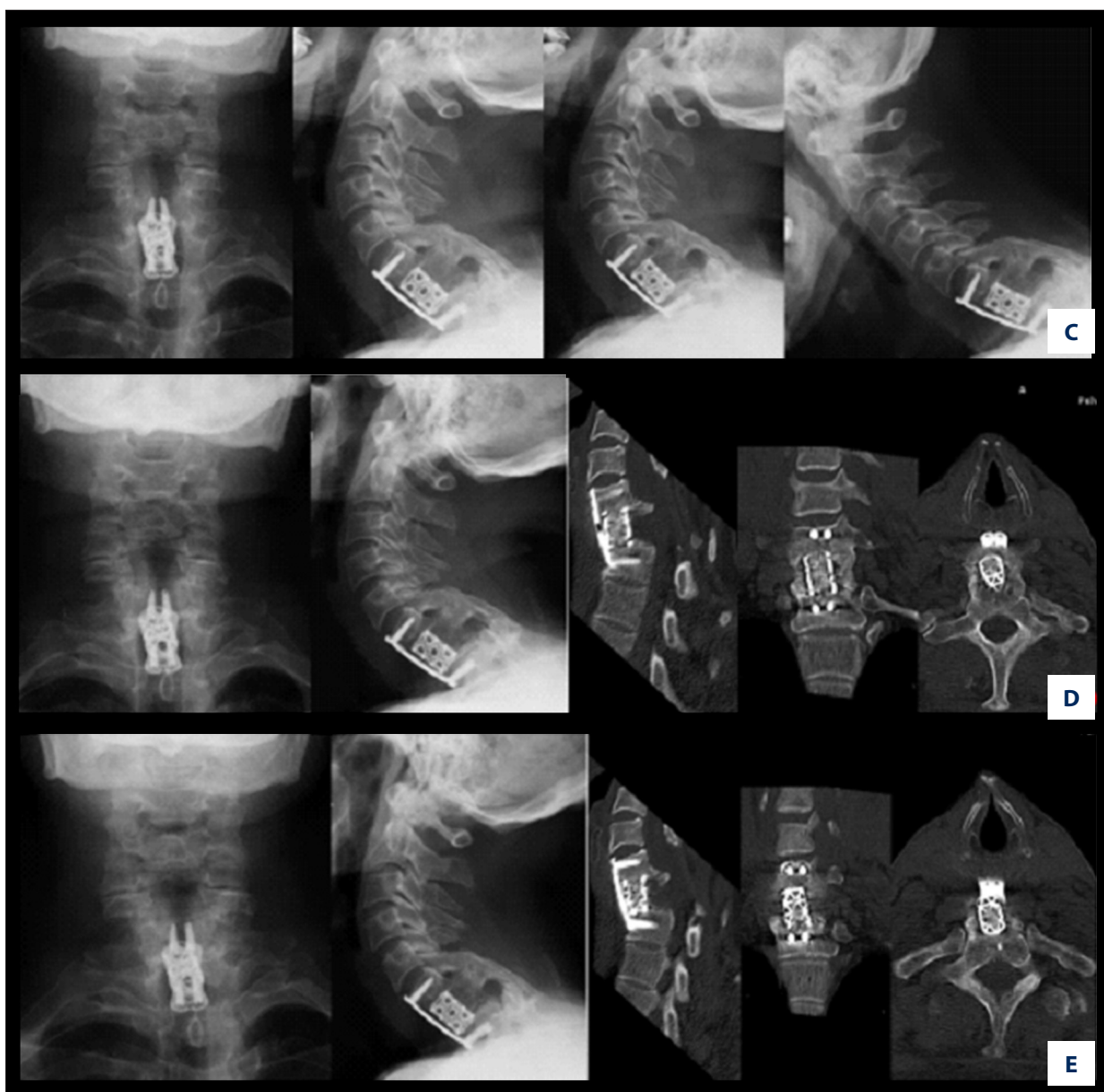


Figure 2. Typical case imaging data of a 62-year-old man who had a traffic accident. The C6–C7 dislocation was discovered 3 months after injury. **A1–A4** indicates the patient's anteroposterior and lateral position as well as the hyperextension and flexion X-ray images. CT images (**A5, A6**) showing the C6-7 old dislocation with unilateral locked facet, and the MRI images (**A7, A8**) indicate contracture of scar tissue, prominent intervertebral discs, and signal changes in the spinal cord. **B1–B4** indicates the X-ray and CT scans images postoperative, and indicates that satisfactory restoration of the dislocation was achieved. **C–E** show the imaging data 3 months after surgery, 1 year after surgery, and at last follow-up. Images show that interbody fusion has been completed, and surgery can effectively restore the cervical sequence and physiological curvature, obtaining permanent stability.

Skull traction is the first choice for the treatment of fresh fracture and dislocation of the cervical spine. But for old cervical fracture dislocations, because of the fibrous scar hyperplasia around the dislocated segment or facet joint fracture, soft tissue insertion is used to contract the dislocation segment tissue at the deformity site. It is therefore difficult to obtain a

reduction simply by skull traction [8,9]. Hassan et al. [10] reported that the success rate of closed reduction in old fracture dislocation cases was as low as 16%. Closed reduction was also attempted for old fracture and dislocation by Liu et al., but the results were not satisfactory [11]. In addition, some scholars believe that closed reduction can increase pain and

may cause secondary damage to the spinal cord [12]. For these reasons, our study did not attempt preoperative closed traction reduction. Instead, anterior open reduction surgery was performed directly.

The surgical treatment of old fracture and dislocation of the lower cervical spine has been controversial [13,14]. Bartel et al. recommend the posterior-anterior-posterior surgery for the treatment of old fracture and dislocation of the lower cervical spine [8], while other scholars report that the anterior-posterior surgery is the best choice for this kind of injury [15,16]. However, combined surgery has the disadvantages of multiple postures and great trauma. We believe that anterior approach should be the first choice for old fracture and dislocation of the lower cervical spine. The main cause of dislocation of the cervical spine is the destruction and instability of the anterior structure. In addition, the scar contracture and fibrosis of the posterior structures of old injuries are sufficiently stable and do not require posterior surgery from a stability standpoint. Previous studies have shown that posterior decompression of the lower cervical spine does not compromise spinal cord compression, tension, and ischemia in patients with old lower cervical spine fractures and dislocations [17]. In our study, we used the method of anterior partial corpectomy and titanium mesh cage fusion and internal fixation. In our opinion, it has the following advantages. First, direct decompression can remove the damaged disc and the posterior margin of the vertebral body which posteriorly oppresses the spinal cord. Second, the rotation and distraction of the Caspar spreader screw in the sagittal plane can basically correct the kyphosis deformity, enlarge the intervertebral foramen, and reduce the nerve root. Third, the use of a titanium cage autogenous bone graft can effectively restore the height of the intervertebral space, and it also has good supporting effect. At the same time, the stability of the immediate anterior column and middle column can be obtained by anterior fixation with a titanium plate. It is reported that the reconstruction of cervical spine with autogenous vertebral bone filled with titanium mesh cage can achieve good bone fusion [18]. The purpose of anterior partial corpectomy and titanium mesh cage fusion is to reconstruct the segmental sequence of the vertebrae and to eliminate segmental kyphosis of the cervical spine, and after the correction of kyphosis, moderate vertical distraction can make the scar tissue of the cervical spine tighten and improve the relative stability of this part of the cervical spine. No posterior column instability was found in any patients during the follow-up period in our study.

However, in some case of old dislocation, facet joints are spontaneously fused at the dislocated position. In this case, it is suggested that an anterior approach should be performed first. If the anterior approach failed, then, the combined anterior

and posterior approaches should be used, which can minimize the surgical trauma and complications. An anterior approach alone may also be unlikely to succeed in some cases of old dislocation of the lower cervical spine with articular process locking or with posterior structures invading the spinal canal and compression of the spinal cord. Therefore, it is necessary to prepare a possible posterior approach while preparing for anterior surgery. For cases with locked facet joints or posterior structures invading the vertebral canal, if the lysis and reduction cannot be achieved by an anterior approach alone, the combined anterior and posterior approaches should be performed in order to achieve better results [20,21].

The canal and vertebrae sagittal diameter ratio (C/V) at the dislocation segment can be used as an important index to determine the mode of operation and to evaluate the postoperative effect. First, the C/V ratio can be used to assess the need for closed reduction. Open reduction should be the first choice if the ratio is greater than 0.5, and if less than 0.5, a closed reduction can be attempted, but the success rate is not high [16]. Second, the C/V ratio can be used to assess the need for posterior decompression and is suitable for fresh lower cervical fracture dislocations [19]. Third, it can also be used to evaluate the postoperative effect in patients with cervical spinal cord injury. It indicates the effect of decompression and the possibility of post-traumatic myelopathy by evaluating the spinal canal [4]. The C/V ratio can also be used to predict the occurrence of adjacent segment disease after cervical surgery. More relevant studies are needed to prove its clinical significance.

Conclusions

In summary, for old lower cervical fracture and dislocation, sufficient decompression and the sequence of the cervical spine are keys to treatment. There is no need to pursue anatomical reduction. Anterior partial corpectomy and titanium mesh bone graft and internal fixation has a sufficient and effective decompression of the spinal cord, recovery of sequence and physiological curvature of cervical vertebra, immediate and permanent stability, and promote the recovery of neurological function, conducive to early rehabilitation training. It should be the preferred choice for the treatment of old fracture and dislocation of the lower cervical spine. For cases with locked facet joints or posterior structures invading the vertebral canal, the combined anterior and posterior approaches should be performed in order to achieve better results when necessary.

Conflict of Interest

None.

References:

1. Samandouras G, Shafafy M, Hamlyn PJ: A new anterior cervical instrumentation system combining an intradiscal cage with an integrated plate: An early technical report. *Spine (Phila Pa 1976)*, 2001; 26(10): 1188–92
2. Gelalis ID, Christoforou G, Arnaoutoglou CM et al: Misdiagnosed bilateral C5–C6 dislocation causing cervical spine instability: A case report. *Cases J*, 2009; 2: 6149
3. Caruso R, Marrocco L, Piccione E, Wierzbicki VL: A blast of mistakes: Undiagnosed cervical spondylolisthesis following a bomb explosion. *Am J Case Rep*, 2017; 18: 320–23
4. Korres DS, Nikiforidis P, Babis GC et al: Old injuries of the lower cervical spine treated surgically. *J Spinal Disord*, 1995; 8(6): 509–15; discussion 499
5. Abumi K, Shono Y, Kotani Y, Kaneda K: Indirect posterior reduction and fusion of the traumatic herniated disc by using a cervical pedicle screw system. *J Neurosurg*, 2000; 92(1 Suppl.): 30–37
6. Ordonez BJ, Benzel EC, Naderi S, Weller SJ: Cervical facet dislocation: Techniques for ventral reduction and stabilization. *J Neurosurg*, 2000. 92(1 Suppl.): 18–23
7. Vaccaro AR, Cook CM, McCullen G, Garfin SR: Cervical trauma: Rationale for selecting the appropriate fusion technique. *Orthop Clin North Am*, 1998; 29(4): 745–54
8. Bartels RH, Donk R: Delayed management of traumatic bilateral cervical facet dislocation: Surgical strategy. Report of three cases. *J Neurosurg*, 2002; 97(3 Suppl.): 362–65
9. Jain AK, Dhammi IK, Singh AP, Mishra P: Neglected traumatic dislocation of the subaxial cervical spine. *J Bone Joint Surg Br*, 2010; 92(2): 246–49
10. Hassan MG: Treatment of old dislocations of the lower cervical spine. *Int Orthop*, 2002; 26(5): 263–67
11. Liu P, Zhao J, Liu F et al: A novel operative approach for the treatment of old distractive flexion injuries of subaxial cervical spine. *Spine (Phila Pa 1976)*, 2008; 33(13): 1459–64
12. Payer M: Immediate open anterior reduction and antero-posterior fixation/fusion for bilateral cervical locked facets. *Acta Neurochir (Wien)*, 2005; 147(5): 509–13; discussion 513–14
13. Shear P, Hugenholtz H, Richard MT et al: Multiple noncontiguous fractures of the cervical spine. *J Trauma*, 1988; 28(5): 655–59
14. Nakashima H, Yukawa Y, Ito K et al: Posterior approach for cervical fracture-dislocations with traumatic disc herniation. *Eur Spine J*, 2011; 20(3): 387–94
15. Mizuno J, Nakagawa H, Inoue T et al: Spinal instrumentation for interfacet locking injuries of the subaxial cervical spine. *J Clin Neurosci*, 2007; 14(1): 49–52
16. Jiang X, Cao Y, Yao Y et al: Surgical management of old lower cervical dislocations with locked facet. *Clin Spine Surg*, 2016; 29(6): E319–24
17. Zdeblick TA, Bohlman HH: Cervical kyphosis and myelopathy. Treatment by anterior corpectomy and strut-grafting. *J Bone Joint Surg Am*, 1989; 71(2): 170–82
18. Yan D, Wang Z, Deng S et al: Anterior corpectomy and reconstruction with titanium mesh cage and dynamic cervical plate for cervical spondylotic myelopathy in elderly osteoporosis patients. *Arch Orthop Trauma Surg*, 2011; 131(10): 1369–74
19. Aebli N, Rüegg TB, Wicki AG et al: Predicting the risk and severity of acute spinal cord injury after a minor trauma to the cervical spine. *Spine J*, 2013; 13(6): 597–604
20. Shimada T, Ohtori S, Inoue G et al: Delayed surgical treatment for a traumatic bilateral cervical facet joint dislocation using a posterior-anterior approach: A case report. *J Med Case Rep*, 2013; 7: 9
21. Lins CC, Prado DT, Joaquim AF: Surgical treatment of traumatic cervical facet dislocation: Anterior, posterior or combined approaches. *Arq Neuropsiquiatr*, 2016; 74(9): 745–49