

**Received:** 2010.09.26  
**Accepted:** 2011.01.10  
**Published:** 2011.06.01

## Pain during external dacryocystorhinostomy with local anesthesia

### Authors' Contribution:

- A** Study Design
- B** Data Collection
- C** Statistical Analysis
- D** Data Interpretation
- E** Manuscript Preparation
- F** Literature Search
- G** Funds Collection

**Miroslav M. Knežević<sup>ABCD</sup>, Milenko Ž. Stojković<sup>CD</sup>, Gordana P. Vljaković<sup>AB</sup>, Miloš B. Jovanović<sup>EF</sup>, Dejan M. Rašić<sup>EF</sup>**

University Eye Clinic, Clinical Center Of Serbia, Belgrade, Serbia

**Source of support:** There were no research contracts or any kind of financial support (grants) for this study

### Summary

|                          |  |
|--------------------------|--|
| <b>Background:</b>       | External dacryocystorhinostomy (DCR) is often performed under local anesthesia (LA) without adequate knowledge of the pain experienced by the patient.   |
| <b>Material/Methods:</b> | We subdivided our surgical technique into stages easily understood by the patients (introducing cotton tipped applicators, performing parabulbar injection, creating the incision, bone cracking (opening the ostium), manipulating the nose, intubating, closing the wound, and packing with gauze). A total of 50 patients ranging in age from 31 to 83 years of age ( $63.64 \pm 9.64$ ) underwent external DCR. Each patient was asked 30 minutes after surgery to indicate the intensity of pain experienced at each stage of the surgery and during intramuscular (IM) injection of an antibiotic using a visual analog scale (VAS). |
| <b>Results:</b>          | Analysis of the VAS-based pain scores indicated 3 statistically equal occurrences of pain coinciding with the opening of the ostium, and receiving both parabulbar anesthetic and IM antibiotic injections.  |
| <b>Conclusions:</b>      | The level of pain experienced during the most unpleasant stage of external DCR (ostium opening) was similar to the pain experienced from an IM injection. Patients can be informed that pain during external DCR with local anesthesia is comparable to receiving an IM gluteal injection.   |
| <b>key words:</b>        | <b>dacryocystorhinostomy • injection • local anesthesia • pain</b>   |

**Full-text PDF:** <http://www.medscimonit.com/fulltxt.php?ICID=881807>

**Word count:** 2496  
**Tables:** 4  
**Figures:** 1  
**References:** 14

**Author's address:** Miroslav Knežević, Pasterova 2, 11000 Belgrade, Serbia, e-mail: knelemik@gmail.com

## BACKGROUND

External dacryocystorhinostomy (DCR) was initially described by Toti in 1904 and further modified by Dupuy-Dutemps and Bourguet in 1921 [1]. Since its introduction, external DCR has been successfully performed with some modifications all over the world and remains the gold standard for lacrimal surgery [2,3]. External DCR can be completed under either local or general anesthesia (LA or GA) [2–5]. Current insight into how much pain is experienced while under LA is limited to results from a single study by Maheshwari [5]. To gain additional information on pain during DCR, the visual analog scale (VAS) was used to quantify pain experienced during the surgical procedure. These scores were then compared to pain scores following an intramuscular (IM) gluteal injection of prophylactic antibiotic administered at the beginning of surgery. Each patient experienced both procedures within a short time interval and was able to compare them. The results from this study can translate into patient education, thereby equating the pain associated with DCR under LA to the pain from a universal experience (IM gluteal injection).

## MATERIAL AND METHODS

The prospective study included 50 patients who underwent external DCR on 1 side with GA, followed 2 days later by external DCR on the opposite side with LA, between 2006 and 2008. The same surgeon, anesthesiologist, and scrub nurse were involved in every case. Furthermore, all surgeries were performed in the same operating room (OR) with the same set of instruments, using the same surgical technique.

The inclusion criterion for our study was bilateral dacryocystitis, and we selected 73 patients. Twenty-three patients were excluded from the study for 1 of the following reasons: 1) an unwillingness to participate in the research in 14 cases; 2) a history of midface trauma in 1 case; 3) poor candidacy for GA in 6 cases (American Society of Anesthesiology (ASA) status IV); 4) lacrimal sac asymmetry (1 was dilated); and 5) concurrent treatment with warfarin in 1 case.

Careful preoperative explanation of the proposed anesthesia, surgical procedure, and expectations during surgery, including both tactile and auditory sensations was provided to each patient.

Oxymetazoline 0.1% solution was sprayed into the nose of every patient 1 hour before surgery. At the same time, an IM gluteal injection of prophylactic antibiotic (cefuroxime 1.5 g) was administered. Direct injection of anesthetics into the nasal mucosa was not performed in any patient. A 22G cannula was introduced into the cubital vein to establish venous access, if needed. No intravenous sedation was administered. All patients were given intranasal oxygen at 4 L/min and subjected to constant monitoring of the electrocardiogram, blood pressure, and pulse oximetry throughout the procedure. BP (blood pressure), HR (heart beat rate) and oxygen saturation (OS) in the beginning of the procedure were noted. Minimal and maximal values and time (when it was reached during surgery) of BP, HR and OS were noted.

A fiberoptic coaxial headlight facilitated illumination for the DCR.

To monitor pain levels during DCR, we subdivided the surgical technique into stages easily understood by the patients:

### 1. Introduction of cotton tipped applicators

In the OR, 3 to 5 cotton tipped applicators (depending on nostril diameter), moisturized with oxymetazoline 0.1%, were introduced into the nostrils for 10–15 minutes. Conventional gauze packing was avoided due to the greater difficulty associated with insertion. Three minutes after installation of the applicators, 5 drops of tetracaine-hydrochloride 2% were instilled to anesthetize the nasal mucosa. Topical anesthetic drops (tetracaine hydrochloride 2%) were also instilled in both conjunctival sacs.

### 2. Injection of local anesthetic

Each patient received 3 1.5mL injections of 1:1 (v/v) mixture of lidocaine 2% epinephrine 1:200,000 and bupivacaine 0.75% via a 16mm 25G needle: 1) above the infraorbital foramen and immediately above the lower orbital floor periosteum, at the maximum depth needle length, 2) into the medial extraconal orbit and above the medial ligament, at the maximum depth permitted by the needle length, and 3) subcutaneously into the lacrimal sac region. After the 3 injections, 0.3 mL of mixture was used to moisturize the cotton tipped applicators previously introduced into the nose.

### 3. Surgical incision

A medial canthal incision was performed with blunt dissection of the orbicularis muscle carried down to the level of the medial canthal tendon. The medial canthal tendon and periosteum were incised and reflected with a periosteal elevator to expose the lacrimal fossa. Bleeding from the angular vessels was cauterized immediately by bipolar diathermy. Anterior and posterior flaps in the lacrimal sac were created.

### 4. Bone cracking (opening the ostium)

The nasal pack was removed. The thin lacrimal bone was fractured, and a 3mm tip Kerrison punch was used to create an osteotomy.

### 5. Manipulation of the nose (opening the nasal mucosa and suturing lower flaps)

Anterior and posterior flaps were created in the nasal mucosa. The 2 posterior flaps were then closed using a 6-0 Vicryl suture.

### 6. Intubation

Silicone stents were passed along the canalicular system and into the osteotomy site, exiting via the naris. Tubes were pulled, tied and knotted, and spontaneously retracted into the nose.

### 7. Wound closure (suturing upper flaps and tissue in layered fashion)

The anterior nasal mucosal flap was anastomosed to the anterior aspect of the lacrimal sac, and the incision was closed in a layered fashion using a 6-0 Vicryl suture.

**Table 1.** All measured patients data in our series grouped by gender.

|                                       | Female  |         |       | Male    |         |       | Statistics |
|---------------------------------------|---------|---------|-------|---------|---------|-------|------------|
|                                       | Range   | Average | SD    | Range   | Average | SD    | P          |
| Age                                   | 31–74   | 63.80   | 9.33  | 46–83   | 63.00   | 11.35 | 0.389      |
| Weight                                | 40–91   | 68.75   | 12.81 | 62–94   | 83.10   | 8.66  | 0.509      |
| High                                  | 151–181 | 162.83  | 7.45  | 162–192 | 173.10  | 9.01  | 0.080      |
| BP systolic beginning (mmHg)          | 108–190 | 153.45  | 17.13 | 132–184 | 148.10  | 15.28 | 0.449      |
| BP diastolic beginning (mmHg)         | 68–107  | 86.63   | 10.08 | 78–101  | 91.40   | 7.88  | 0.306      |
| BP average beginning (mmHg)           | 83–139  | 117.63  | 12.54 | 101–129 | 113.90  | 8.28  | 0.902      |
| Heart rate beginning (beats/min)      | 55–108  | 83.10   | 12.55 | 64–91   | 78.40   | 8.98  | 0.507      |
| Oxygen saturation beginning (%)       | 94–100  | 97.82   | 1.62  | 94–100  | 97.70   | 2.06  | 0.620      |
| BP systolic minimal (mmHg)            | 98–176  | 142.08  | 21.60 | 94–158  | 130.90  | 18.18 | 0.767      |
| BP diastolic minimal (mmHg)           | 64–111  | 84.23   | 12.62 | 67–90   | 83.60   | 6.72  | 0.308      |
| BP average minimal (mmHg)             | 78–138  | 108.60  | 14.20 | 75–113  | 102.90  | 10.89 | 0.628      |
| Heart rate minimal (beats/min)        | 51–107  | 79.83   | 15.67 | 61–95   | 73.10   | 10.67 | 0.364      |
| Oxygen saturation minimal (%)         | 95–100  | 98.35   | 1.58  | 96–100  | 97.90   | 1.37  | 0.197      |
| BP systolic maximal (mmHg)            | 128–211 | 166.50  | 23.40 | 140–187 | 164.70  | 14.86 | 0.492      |
| BP diastolic maximal (mmHg)           | 73–114  | 94.35   | 11.13 | 93–117  | 100.70  | 7.12  | 0.459      |
| BP average maximal (mmHg)             | 95–147  | 121.90  | 14.67 | 111–146 | 126.00  | 11.31 | 0.200      |
| Heart rate maximal (beats/min)        | 52–111  | 84.10   | 14.74 | 60–99   | 81.20   | 13.37 | 0.694      |
| Oxygen saturation maximal (%)         | 98–100  | 99.05   | 0.85  | 97–100  | 98.40   | 1.08  | 0.173      |
| Operating time (min)                  | 13–33   | 24.00   | 4.73  | 16–30   | 25.30   | 4.37  | 0.375      |
| Time till minimal BP (min)            | 7–25    | 16.75   | 4.50  | 6–24    | 12.80   | 6.48  | 0.190      |
| Time till maximal TA (min)            | 2–15    | 7.73    | 3.29  | 5–21    | 9.80    | 5.86  | 0.664      |
| Time from maximal to minimal BP (min) | 1–19    | 9.03    | 3.70  | 4–15    | 9.80    | 4.34  | 0.291      |

## 8. Packing with gauze (tamponade)

Gauze packing was inserted into the nose and removed the following day. The patients were asked to rest for 1–2 hours without applying ice packs following surgery and to avoid nose-blowing for 1 week.

All patients were asked 30 minutes after surgery to rate the intensity of pain experienced during the IM gluteal injection of prophylactic antibiotic and at each stage of the surgery using the VAS scale (0= the least amount of pain, and 10= the greatest amount of pain). To assimilate the pain data from all surgical stages, a single overall parameter of pain was utilized. Patients were also asked whether they would have the procedure repeated with LA. All patients were followed for 6 months.

Sample size for the study was calculated and 18 patients were sufficient to get reliable results. The Wilcoxon signed-rank test was used to assess the significance of the differences between VAS pain levels during different stages of surgery. Data were analyzed with the SPSS 12.0 software (SPSS Inc. 1989–2003) and a P value less than 0.05 was considered significant.

## RESULTS

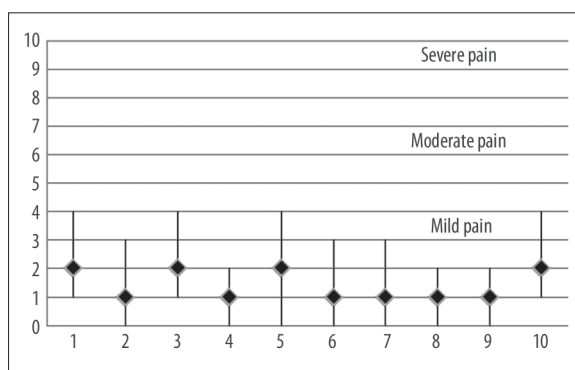
A total of 50 patients ranging in age from 31–83 years ( $63.64 \pm 9.64$ ) underwent external DCR. The group included 40 females between 31 and 74 ( $63.80 \pm 9.32$ ) years of age and 10 males between 46 and 83 years of age ( $63.00 \pm 11.35$ ). No statistically significant differences in pain levels, blood pressure and variations of BP during surgery, heart beat rate and HR variations and oxygen saturation and variations of OS during surgery existed between groups with respect to gender (for all  $P > 0.005$ ) (Table 1). Patients were divided in 3 groups based on their level of education (primary school, secondary school and college). There were no statistically significant differences between groups in pain levels during any stage of surgery and in overall level of pain.

Pain recorded at all stages of DCR was minor (Figure 1). Among these minor pain values, the lowest VAS pain level (median, 1) was present at multiple times: 1) at the introduction of the cotton tipped applicators; 2) at the beginning of the surgical procedure (skin incision and dissection of the lacrimal sac); 3) during nasal manipulation after bone

**Table 2.** Pain levels in our series.

| Stage/procedure                           | Range | Median | q1   | q2 |
|---|-------|--------|------|----|
| IM injection                              | 1–4   | 2      | 2    | 3  |
| 1. introducing cotton tipped applicators  | 0–3   | 1      | 1    | 2  |
| 2. injection                              | 1–4   | 2      | 2    | 3  |
| 3. incision (beginning of the procedure)  | 0–2   | 1      | 0.75 | 1  |
| 4. bone cracking (ostium opening)         | 0–4   | 2      | 2    | 3  |
| 5. nasal manipulation after bone cracking | 0–3   | 1      | 1    | 2  |
| 6. intubation                             | 0–3   | 1      | 1    | 2  |
| 7. wound closure                          | 0–2   | 1      | 0    | 1  |
| 8. gauze packing                          | 0–2   | 1      | 0.75 | 1  |
| 9. overall pain during procedure          | 1–4   | 2      | 2    | 3  |

q1 – the first quartile (25<sup>th</sup> percentile); q3 – the third quartile (75<sup>th</sup> percentile).



**Figure 1.** Pain levels in our series (numbers 1 to 10 represent stages of surgery). 1 – IM injection; 2 – introducing cotton tipped applicators; 3 – injection; 4 – incision (beginning of the procedure); 5 – bone cracking (ostium opening); 6 – nasal manipulation after bone cracking; 7 – intubation; 8 – wound closure; 9 – gauze packing; 10 – overall pain during procedure.

cracking (incision and suture of nasal mucosa); 4) during intubation; 5) during wound closure; and 6) during nasal packing at the end of the procedure. Medium levels of pain (median, 2) were noted during the IM gluteal injection of prophylactic antibiotic, the LA injection, and the ostium opening, and for overall pain (Table 2). No statistically significant differences in pain levels between IM gluteal injection, LA injection, and ostium opening were observed ( $P>0.05$ ).

None of the patients complained of pain during surgery. Consequently, none required conversion to GA or additional analgesics. LA injection did not result in hemorrhage, and none of the patients experienced uncontrolled intranasal bleeding during the procedure. No cases of postoperative epistaxis requiring nasal packing occurred, and no one experienced dislodged tubing. Success was confirmed with patent lacrimal passages on irrigation in 49 of 50 patients after 6 months. One patient (2%) complained of recurrence of profuse watering after the procedure and required further surgery.

Forty-seven of the 50 participants (94%) stated that they preferred the next procedure to be performed in the same way. The remaining 3 patients (6%) preferred GA; they did not complain of pain, and the VAS pain levels were not statistically different from the rest of the group ( $P>0.05$ ). In 2 cases, GA was selected because participants did not want to be consciously involved in the procedure (they preferred to be asleep and remain unaware). In the third case, the sound of bone cracking was unpleasant for the patient. We have not received another such a complaint in the 300+ procedures that we have performed using LA.

## DISCUSSION

Performing DCR under LA has been an accepted procedure for years, especially for elderly patients [6–8]. The specific risks of GA are, of course, avoided with LA. A much lower incidence of postoperative nausea and vomiting PONV after DCR was observed with LA compared with GA in a previous study. Anesthetics used for GA also act as vasodilators and enhance bleeding [2,4,8,9]. Based on these findings, the use of LA is often recommended to the patient. However, when patients inquire about pain experienced during surgery with LA, little scientific data exists to support claims that patients do not complain and that the procedure is not painful. Measuring pain levels during different stages of our surgical technique generated more precise data on when pain occurred. By comparing bone cracking to an IM injection, we tried to associate 2 painful events. Bone cracking showed the highest levels of pain experienced during surgery according to the VAS scores (range 0 to 4, median 2). The median value of pain experienced during ostium opening was the same as the median pain values during the administration of LA and IM injection (difference was not statistically significant). All manipulations involving the nasal structures (introducing cotton tipped applicators, forming nasal mucosa flaps, and intubation) induce similar levels of pain (median 1), and the differences among those procedures was not statistically significant. We did not perform syringing in the beginning of surgery in order to measure exact level of pain during syringing. The syringing procedure is similar to intubation, so we may presume that level

**Table 3.** Comparison of our series with Maheshwari's series [5].

| Stage                                  | Our series |        | Maheshwari [5]       |                   | Description |
|--|------------|--------|----------------------|-------------------|-------------|
|  | Range      | Median | Range                | Stage             |             |
| Overall pain during procedure          | 1–4        | 3      | Not measured         |                   |             |
| Introducing cotton tipped applicators  | 0–3        | 1      | Not measured         |                   |             |
| Injection                              | 1–4        | 2      | Not measured         |                   |             |
| Incision (beginning of the procedure)  | 0–2        | 1      | 0–2                  | Skin incision     | No pain     |
| Bone cracking                          | 0–4        | 2      | 3–4                  | Bony ostium       | Mild pain   |
| It's done as last part of incision     |            |        | 3–4                  | Sac flap          | Mild pain   |
| Nasal manipulation after bone cracking | 0–3        | 1      | 3–4                  | Nasal mucosa flap | Mild pain   |
| Intubation                             | 0–3        | 1      | Not performed at all |                   |             |
| Wound closure                          | 0–2        | 1      | 0–2                  | Wound closure     | No pain     |
| Gauze packing                          | 0–2        | 1      | Not measured         |                   |             |

**Table 4.** Comparison our series to Smith et al. [13].

| Pain level | Smith et al.'s series [13] |       | Our series |    |
|------------|----------------------------|-------|------------|----|
|            | No                         | %     | No         | %  |
| 0–2.5      | 46                         | 69.71 | 35         | 70 |
| 2.6–5      | 12                         | 18.18 | 15         | 30 |
| 5.1–7.5    | 5                          | 7.56  | 0          | 0  |
| 7.6–10     | 3                          | 4.55  | 0          | 0  |

of pain during manipulations involving nasal structures is similar to syringing.

Bone cracking (making ostium) produces sounds similar to tooth extraction. None of the 50 patients included in study needed any tooth removal so we could not make this comparison.

Maheshwari tried to measure the level of pain during DCR using a verbal rating scale (VRS) and concluded that LA was acceptable for patients [5]. We compared our VAS-based pain scores with Maheshwari's VRS scores (Table 3) and achieved similar results. Minor differences existed in the procedure itself, including opening the lacrimal sac at the beginning after elevating periosteum in our cases. The formation of the sac flap was recorded as being as painful as the creation of bone ostium in our series, and as painful as the creation of the nasal mucosa flap in Maheshwari's study. Patients may not have distinguished opening the lacrimal sac from creating the nasal mucosa flap because the procedures occurred right after each other in Maheshwari's study. The fact that recorded pain levels for both procedures is the same strongly suggests that patients put the 2 stages of Maheshwari's study together.

Few other studies have addressed pain during DCR, and all concluded that patients did not complain of pain [10–12]. The following sentences are direct quotes from these papers:

“All patients found the technique acceptable, and none stated afterwards that they would have preferred to have had a general anesthetic” [10].

“In our technique of LA, properly localized and sufficient nerve block effectively eliminates patient pain and provides hemostasis which ensures surgeon's comfort during DCR” [11].

“Patients in both groups reported that they were comfortable during and immediately after surgery” [12].

Kratky V et al. and Hurwitz JJ et al. reported procedures with LA but did not comment on the effectiveness of LA or the level of patient acceptance [6,7].

The lack of patient complaints does not necessarily correlate with an absence of pain. Pain was likely tolerable and not severe enough for the patient to complain of discomfort. Smith et al measured pain during injection of LA in the region of the lacrimal fossa using VAS [13]. The percentage of patients experiencing levels of pain lower than 2.6 were almost identical to our results (Table 4). One major difference was noted between the results of our study and Smith et al. If any of the patients respond during injection of LA that the pain was the worst imaginable (pain level 7, 6–10), anesthesia should be converted at that time to GA. Smith

et al performed all procedures under LA, and patients did not complain. Clearly, the pain threshold varies from patient to patient and may be related to cultural differences as well [14]. All of our patients were satisfied with the procedure, similar to previously published studies [6,7,10–13].

Distinguishing pain directly related to the operation site from discomfort associated with sensory clues (ie, unpleasant tastes, sights, or sounds) that patients record as pain is a limitation to this study. DCR can be associated with unpleasant sounds (bone cracking) and unpleasant tastes (blood in the throat). A comparison of DCR with tooth extraction (the only commonly performed procedure with LA that involves the sound of bone cracking) may provide useful information about this perceived pain.

## CONCLUSIONS

Based on the experience of these 50 patients, we can claim that pain experienced during external DCR under LA, if it is present, is low on the VAS scale. Furthermore, the most painful stage of external DCR under LA (bone cracking) was no more painful than the IM injection experienced at the beginning of the procedure. Other stages (opening nasal mucosa, intubation, and nose packing) induced even lower levels of pain on the VAS and can be compared to syringing.

Pain experienced under LA during external DCR can best be described to patients as similar to the pain experienced from an IM gluteal injection. Patients should also be informed before and during the procedure that there will be a sound of bone cracking, not unlike when a tooth is extracted, and that they may experience pain equal to or less than that associated with an IM injection.

## Acknowledgments

All surgical procedures were performed on University Eye Clinic Clinical Center of Serbia. Approval for this study was obtained from the Belgrade University School of Medicine Ethics Committee.

## Conflicts of interest

All authors have no conflicts of interest.

## REFERENCES:

1. Hughes SM: The History of Lacrimal Surgery. *Adv Ophthal Plastic & Reconstruct Surgery*, 1986; 5: 139–68
2. Caesar RH, Mc Nab AA: External dacryocystorhinostomy and local anesthesia. Technique to measure minimized blood loss. *Ophthal Plast Reconstr Surg*, 2004; 20: 57–59
3. Moore WMH, Bentley CR, Olver JM: Functional and anatomic results after two types of endoscopic endonasal dacryocystorhinostomy: surgical and holmium laser. *Ophthalmology*, 2002; 109: 1575–82
4. Jordan DR: Avoiding blood loss in outpatient DCR. *Ophthal Plast Reconstr Surg* 1991;7: 261–66
5. Maheshwari R: Single-prick infiltration anesthesia for external dacryocystorhinostomy. *Orbit*, 2008; 27(2): 79–82
6. Kratky V, Hurwitz JJ, Ananthanarayan C, Avram DR: Dacryocystorhinostomy in elderly patients: regional anesthesia without cocaine. *Can J Ophthalmol*. 1994; 29(1): 13–16
7. Hurwitz JJ, Merkur S, De Angelis D: Outcome of lacrimal surgery in the elderly. *Can J Ophthalmol*, 2000; 35: 18–22
8. Woog JJ, Kennedy RH, Custer PL et al: Endonasal dacryocystorhinostomy: a report by the American Academy of Ophthalmology. *Ophthalmology*, 2001; 108: 2369–77
9. Mailer CM, Webster AC: Controlled sedation, sphenopalatine and nasociliary blocks, and bloodless flap suturing in dacryocystorhinostomy. *Can J Ophthalmol*, 1982; 17(5): 189–93
10. McNab AA, Simmie RJ: Effectiveness of local anaesthesia for external dacryocystorhinostomy. *Clin Experiment Ophthalmol*, 2002; 30(4): 270–72
11. Ciftci F, Pocan S, Karadayi K, Gulecek O: Local versus general anesthesia for external dacryocystorhinostomy in young patients. *Ophthal Plast Reconstr Surg*, 2005; 21(3): 201–6
12. Meyer DR: Comparison of oxymetazoline and lidocaine versus cocaine for outpatient dacryocystorhinostomy. *Ophthal Plast Reconstr Surg*, 2000; 16(3): 201–5
13. Smith MG, Kong AS, Yung MW et al: Lacrimal fossa block: an audit of a minimally invasive regional anaesthetic technique for endoscopic dacryocystorhinostomy. *Clin Otolaryngol*, 2001; 26: 407–10
14. Rashid S, Dick BD: Factors associated with chronic noncancer pain in the Canadian population. *Pain Res Manag*, 2009; 14(6): 454–60