



TECHNICAL NOTE

Minimal invasive surgery for left colectomy adapted to the COVID-19 pandemic: laparoscopic intracorporeal resection and anastomosis, a 'don't touch the bowel' technique

Xavier Serra-Aracil | Laura Mora-Lopez | Irene Gomez-Torres | Anna Pallisera-Lloveras | Sheila Serra-Pla | Anna Serracant | Albert Garcia-Nalda | Oriol Pino-Perez | Salvador Navarro-Soto

Colorectal Surgery Unit, General and Digestive Surgery Department, Hospital Universitari Parc, Barcelona, Spain

Correspondence

Xavier Serra-Aracil, Coloproctology Unit, General and Digestive Surgery Service, Parc Tauli University Hospital, Sabadell, Parc Tauli s/n, 08208 Sabadell, Barcelona, Spain.
Email: xserraa@gmail.com

Abstract

Aim: The COVID-19 pandemic has forced surgeons to adapt their standard procedures. The modifications introduced are designed to favour minimally invasive surgery. The positive results obtained with intracorporeal resection and anastomosis in the right colon and rectum prompt us to adapt these procedures to the left colon. We describe a 'don't touch the bowel' technique and outline the benefits to patients of the use of less surgically aggressive techniques and also to surgeons in terms of the lower emission of aerosols that might transmit the COVID-19 infection.

Methods: This was an observational study of intracorporeal resection and anastomosis in left colectomy. We describe the technical details of intracorporeal resection, end-to-end stapled anastomosis and extraction of the specimen through mini-laparotomy in the ideal location.

Results: We present preliminary results of 17 patients with left-sided colonic pathologies, 15 neoplasia and two diverticular disease, who underwent four left hemicolectomies, six sigmoidectomies and seven high anterior resections. Median operating time was 186 min (range 120–280). No patient required conversion to extracorporeal laparoscopy or open surgery. Median hospital stay was 4.7 days (range 3–12 days). There was one case of anastomotic leak managed with conservative treatment.

Conclusion: Intracorporeal resection and end-to-end anastomosis with the possibility of extraction of the specimen by a mini-laparotomy in the ideal location may present benefits and also adapts well to the conditions imposed by the COVID-19 pandemic. Future comparative studies are needed to demonstrate these benefits with respect to extracorporeal anastomosis.

KEYWORDS

intracorporeal anastomosis, left intracorporeal anastomosis, minimally invasive left colon surgery, surgical measures against COVID-19, 'don't touch the bowel' technique

INTRODUCTION AND INDICATIONS

The SARS-CoV-2 virus (COVID-19) pandemic in 2020 has forced surgeons to adapt and modify many of their procedures. Although there is no clear consensus at present regarding the measures to adopt, a variety of modifications have been suggested in order to prevent the generation of aerosols and subsequent exposure. Among the measures proposed are the use of minimally invasive approaches such as laparoscopy, central negative pressure systems, smoke filters in cannulas, and balloon trocars, as well as minimizing the size of surgical incisions [1–3]. One of these recommendations is the performance of laparoscopic procedures [4] with minimal evacuation of gas and exteriorization of the specimen, and intracorporeal intestinal anastomoses.

Given the evidence of the benefits of intracorporeal resection and anastomosis in right hemicolectomy [5,6], and in view of our experience and that of other authors in transanal rectal and left colon surgery [7–9], we propose to adapt these procedures for use in the left colon. This minimally invasive ‘don’t touch the bowel’ technique decreases the level of surgical aggression and avoids contact with (or opening) the intestine. It may help to protect surgeons against the emission of aerosols that may transmit COVID-19 infection. The main objective of this study is to describe the surgical technique of intracorporeal resection and anastomosis in left colon surgery.

METHODS

The local Institutional Ethics Committee approved the use of the intracorporeal technique for the treatment of tumours and diverticular disease of the left colon, sigmoid and upper third of the rectum (LIEC 2020/679). Informed consent was obtained from the patients after an explanation of the risks and benefits of the procedure. Surgery was performed by our team of colorectal surgeons.

Surgical technique

Once the trocars are placed and pneumoperitoneum is created, tie of the inferior mesenteric vessels is performed and the splenic flexure is mobilized as necessary. The distal section is performed using an ECHELON FLEX™ ENDOPATH® stapler, 1.5 mm staple height and 60 mm blue reload.

Intracorporeal resection (Video S1)

Over the proximal mesocolon, the origin of the inferior mesenteric vessels is taken as a reference, and the mesocolon is marked and sectioned intracorporeally (Figure 1A). Next, we mark the

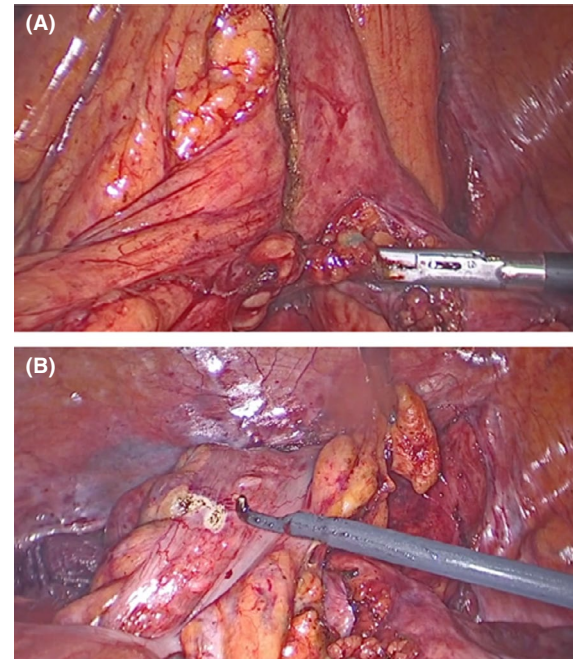


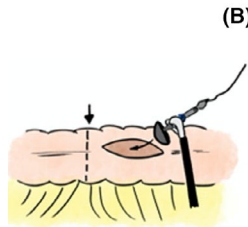
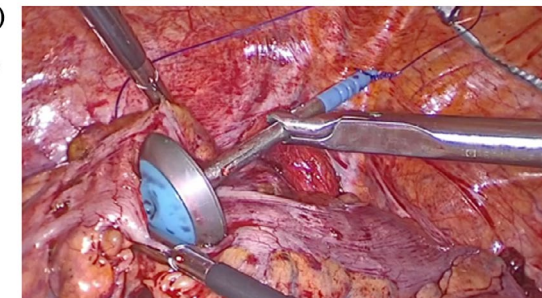
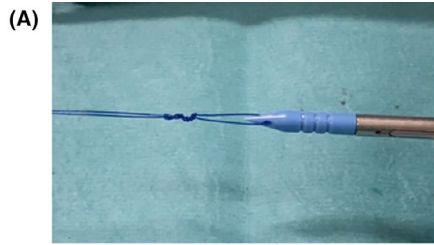
FIGURE 1 (A) Exposure of the mesocolon at the level of the resection area. The inferior mesenteric vessels are to the right of the image, and the area of the mesocolon section is marked. (B) After sectioning of the mesocolon, the area where the colon is to be sectioned is marked with the endostapler

area where the proximal section of the colon will be performed (Figure 1B).

Preparation of the anvil of the circular stapled suture and its insertion in the proximal colon (Video S1)

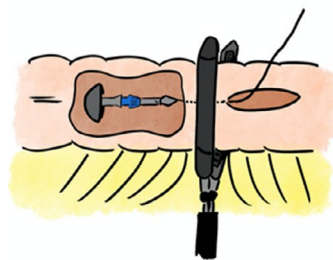
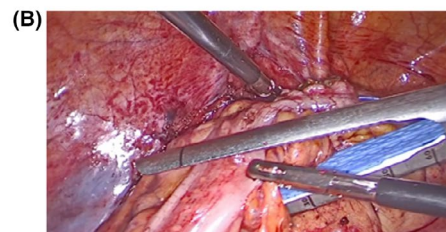
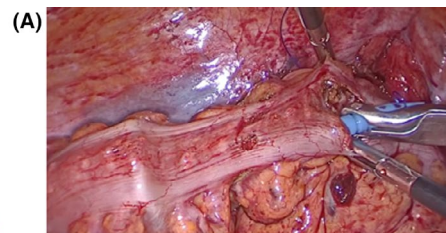
A 29 mm curved circular stapler (B. Braun, Melsungen, Germany) is used. The anvil-tip is mounted together with the anvil-head. On this device a 0 Prolene® monofilament suture is performed, with multiple knots to aid its manipulation (Figure 2A), of about 7–10 cm in length so that it can be pulled through the staple line of the section of the colon. In order to introduce the anvil and to remove the specimen afterwards, a mini transverse laparotomy 3.5–4 cm long is performed in the better site of the abdomen, preferably a mini Pfannenstiel, although in obese patients in the left upper quadrant.

To introduce the anvil in the proximal colon (Video S2), a colotomy is performed some 2–3 cm distal to the colon section mark. The anvil-head (Figure 2B) is inserted in its entirety inside the colon, allowing the monofilament to exit through the colotomy (Figure 3A). After the complete insertion of the anvil-head beyond the section mark, the ECHELON FLEX™ ENDOPATH®, 1.5 mm staple height and 60 mm blue reload, is applied again (Figure 3B) (Video S3).



(B)

FIGURE 2 (A) Preparation of the anvil-tip (removable plastic piece) with a 0 Prolene® monofilament suture, with multiple knots to facilitate its manipulation. (B) Insertion of the anvil-head together with the anvil-tip inside the colon



(A)

(B)

FIGURE 3 (A) The anvil-head inserted entirely inside the colon, allowing the monofilament to exit through the colotomy. (B) Anvil-head with anvil-tip inside the colon; once the anvil unit (head and tip) is beyond the section area, the endostapler is inserted here

Extraction of the anvil-head through the staple suture line section of the colon, extraction of the anvil-tip and preparation of the proximal end of the anastomosis (Video S4)

After sectioning the colon, the Prolene® suture remains in the middle of the staple line (Figure 4A1). The monofilament is sited among the stapled suture line. Then it is pulled by extracting the whole anvil (Figure 4A1,A2). The extraction of the anvil-tip from the anvil (Figure 4B) involves the introduction of a needle holder through a 5 mm trocar, which pulls from the multiple knots holding the anvil-tip in place (Figure 4B1,B2). The counter-traction exerted by the trocar on the anvil-head and the traction of the needle holder in the same direction makes the extraction of the anvil-tip straightforward (Figure 4B3,B4).

A purse-string is made around the orifice through which the anvil-head exits using a 2/0 Prolene® suture. This is done to secure the tissue around the anvil and includes any tissue possibly damaged by the trocar. A stapled end-to-end anastomosis is performed in accordance with the standard technique, checking the integrity of the anastomotic rings and the intra-operative air testing of the

anastomoses. The anastomosis is reinforced with 4–5 loose 3/0 silk stitches on the lateral and anterior surfaces. The specimen is extracted through a 3–5 cm mini-laparotomy adapted to the size of the tumour, inside a plastic bag (Applied Medical, Inzii 12/15 mm Retrieval System; Video S5) protected with a dual-ring retractor (Alexis O Wound Protector C8401). The mini-laparotomy can be performed anywhere in the abdominal wall.

RESULTS

Seventeen patients underwent intracorporeal surgery of the left colon. The results for the demographic and preoperative variables of the patients are presented in Table 1. The pathology location was splenic flexure (one), left colon (two), sigmoid (nine) and the rectosigmoid junction/upper rectum (five). Table 2 shows the operative and pathological patient variables. The technique used for intracorporeal resection and anastomosis was high anterior resection in seven, sigmoidectomy in six and left hemicolectomy in four. The mean surgical time was 186 ± 49 min (range 120–280). No patient required conversion to extracorporeal laparoscopy or open surgery. In two patients,

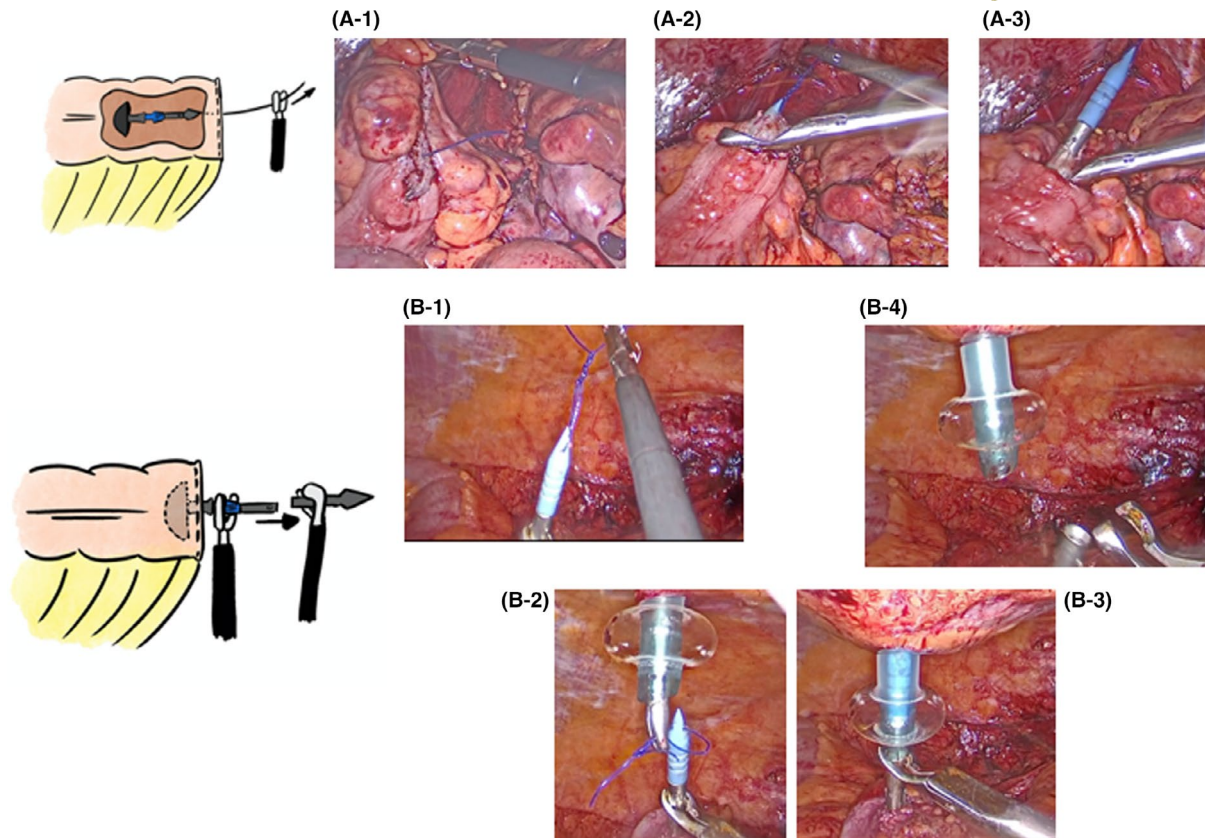


FIGURE 4 (A1) After the section of the colon with the endostapler, the monofilament remains in the middle of the section of staple line. (A2) Traction from the monofilament, with the exit of the anvil through the staple line. (A3) Exit of the anvil. (B1) Anvil-tip with multiple knots. (B2) Traction with a needle holder inserted through a 5 mm trocar on the multiple knots of the anvil-tip. (B3) Insertion of the anvil unit (head and tip) inside the 5 mm trocar. (B4) Traction from the needle holder, causing the anvil-tip to exit

elective sigmoid resection was performed for diverticular disease. As for the pathological variables among the tumours, there was one gastrointestinal stromal tumour and the rest were adenocarcinoma (14).

With regard to 30-day postoperative morbidity, there was only one complication due to anastomotic leak which settled with conservative management (Table 3). One patient was reoperated at 48 h for bleeding from the mesocolon section, with satisfactory recovery and discharge on the eighth postoperative day. Another patient returned to the emergency room on the ninth postoperative day with a urinary tract infection. Mean hospital stay was 4.7 ± 3 days (range 3–12). The mean Complication Comprehensive Index was 6.7 ± 10.7 (range 0–33.7). None of the patients undergoing surgery and none of the members of the surgical team were contaminated with SARS-CoV-2 (COVID-19).

DISCUSSION

Intracorporeal resection of the specimen and stapled colorectal anastomosis without the need for its extraction, a 'don't touch the bowel' technique, offers multiple advantages. These benefits

include the avoidance of excessive manipulation, less bleeding, and reduction of the tension of the mesocolon caused by its exteriorization. We believe that these manoeuvres avoid the traction of the colon, which may compromise the blood supply to the segment of the staple line anastomosis, and can help to reduce the rate of anastomotic leaks due to ischaemia. In the case of obese patients with a short mesocolon, the manoeuvres of exteriorization of the colon may be difficult and may damage the remaining colon; therefore, intracorporeal techniques represent a major improvement. Circular stapled end-to-end colorectal anastomoses in the left colon appear to be the safest; the rate of anastomotic leak is around 7.5% [10]. The end-to-end anastomosis that we describe avoids the suture line and is similar to the standard colo-colonic or colorectal anastomosis that we habitually perform; it does not require an extra length of colon, and mobilization of the splenic flexure is avoided.

An intracorporeal anastomosis in left colonic laparoscopic resections has already been described in an emergency colorectal surgery setting. In pre-COVID times this could easily be done via Pfannenstiel and extracorporeal insertion of the anvil, but with the currently described technique the anvil is inserted intracorporeally with its benefits [11,12]

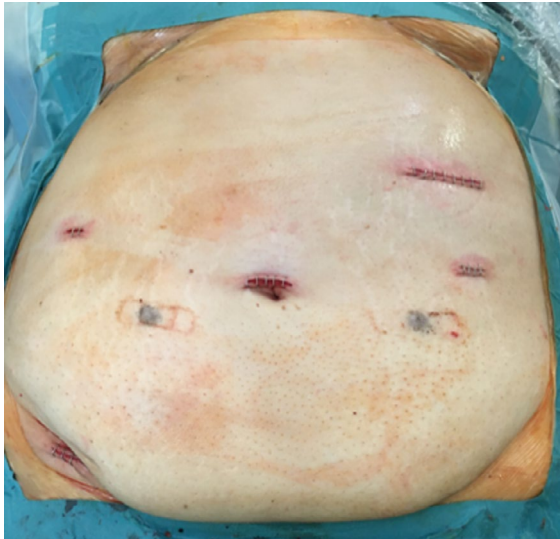


FIGURE 5 Patient with obese morbidity. Location of mini-laparotomy in the left upper quadrant

TABLE 1 Demographic and preoperative variables of the patients

Variables	Value
Age at surgery, years, mean \pm SD (range)	68 \pm 11.3 (47–84)
Gender	
Male	9 (53%)
Female	8 (47%)
BMI, kg/m ² , mean \pm SD (range)	27.8 \pm 4.2 (22.1–39.1)
ASA classification	
II	10 (58.8)
III	7 (41.2%)
Pathology	
Neoplasia	15 (88.2%)
Diverticular disease	2 (11.8%)
Pathology site	
Splenic flexure	1 (5.9%)
Left colon	2 (11.8%)
Sigmoid	9 (53%)
Upper rectum	5 (29.3%)

Abbreviations: ASA, American Society of Anesthesiologists; BMI, body mass index.

This technique with intracorporeal resection also enables the surgeon to choose which type of accessory incision to perform in order to extract the specimen. This is particularly advantageous in morbidly obese patients with a large infra-umbilical fat pad. The technique obviates the need for a Pfannenstiel incision and allows the performance of smaller incisions in the ideal location, as in one of the patients in our series (Figure 5). In patients of this type,

TABLE 2 Operative and pathological patient variables

Variables	Value
Surgical technique	
Left hemicolectomy	4 (23.5%)
Sigmoidectomy	6 (35.3%)
High anterior resection	7 (41.2%)
Operative time, min, mean \pm SD (range)	186 \pm 49 (120–280)
Estimated blood loss, ml, mean \pm SD (range)	30 \pm 11.8 (20–50)
Definitive pathology	
Diverticular disease	2
GIST	1
Adenocarcinoma	14
No. of retrieved lymph nodes in adenocarcinoma, mean \pm SD	15.8 \pm 4.3
Pathological stage in adenocarcinoma	
I	3
II	6
III	4
IV	1

Abbreviation: GIST, gastrointestinal stromal tumour.

TABLE 3 Hospital stay and postoperative complications

Variables	Value
Postoperative hospital stay, days, mean \pm SD (range)	4.7 \pm 3 (3–12)
Postoperative morbidity, Clavien–Dindo grade	6 (35.3%)
0	11 (64.7%)
I	2 (11.8%)
II	3 (17.6%)
IIIa	0
IIIb	1 (5.9%)
IVa	0
IVb	0
V	0
Complication Comprehensive Index, mean \pm SD (range)	6.7 \pm 10.7 (0–33.7)
Anastomotic leak (Clavien–Dindo grade) (%)	1 (II) (5.9%)

intracorporeal resection avoids the difficult extraction of the colon with its voluminous mesocolon through mini-laparotomy [13,14]. However, the possible risk of infection related to pneumoperitoneum leak through the incision is not avoided.

The procedure for intracorporeal resection and end-to-end anastomosis described in this study does not entail any greater technical difficulty. Surgical times in our series are within the normal range



[15], and from the oncological point of view the resection is performed in the same way as in standard laparoscopic surgery. In all the patients included in the study, more than 12 lymph nodes were resected [16].

The new situation caused by the COVID-19 pandemic has obliged us to modify our approach to left colon surgery. Intracorporeal resection and end-to-end anastomosis with the possibility of extraction of the specimen by a mini-laparotomy in the ideal location may present benefits and also adapts well to the conditions imposed by the COVID-19 pandemic. Also, adequate precautions must be adopted, using ultrafiltration (smoke evacuators and/or filters) during the procedure and monitoring smoke/gas evacuation and final exsufflation. Trocar incisions should be minimized, using trocars with balloon to avoid gas leakage around ports [17].

Future comparative studies are needed to demonstrate these benefits with respect to extracorporeal anastomosis.

ETHICS APPROVAL AND CONSENT TO PARTICIPATE

The study has been approved by the local ethics committee of our centre (CEIC 2020/679). All patients included in the study have been informed of the surgical technique used as well as its risks and possible complications. They signed a specific informed consent for the surgery performed.

ACKNOWLEDGEMENTS

We thank all the members of the Coloproctology Unit of the Department of General Surgery and the members of the Multidisciplinary Colorectal Cancer Team. We are grateful to Xus Badia for his help with the illustrations, the surgical nurses Marta Arizu and Merche Muñoz, and Michael Maudsley for his help with English.

CONFLICT OF INTERESTS

The authors have no conflicts of interest to declare.

AUTHOR CONTRIBUTIONS

XSA, LML, IGT wrote and edited the paper. All authors (XSA, LML, IGT, APL, SSP, AS, AGN, OPP, SNS) have reviewed the paper, revising it critically for intellectual content. Each author has participated sufficiently in the work of reviewing and approving the study as written..

ORCID

Xavier Serra-Aracil  <https://orcid.org/0000-0003-0291-1900>

Anna Pallisera-Lloveras  <https://orcid.org/0000-0001-6572-7356>

Albert Garcia-Nalda  <https://orcid.org/0000-0003-4060-8216>

REFERENCES

- Francis N, Dort J, Cho E, Feldman L, Keller D, Lim R, et al. SAGES and EAES recommendations for minimally invasive surgery during COVID-19 pandemic. *Surg Endosc.* 2020;34:2327-31. <https://doi.org/10.1007/s00464-020-07565-w>
- Vigneswaran Y, Prachand VN, Posner MC, Matthews JB, Hussain M. What is the appropriate use of laparoscopy over open procedures in the current COVID-19 climate? *J Gastrointest Surg.* 2020;24:1686-91. <https://doi.org/10.1007/s11605-020-04592-9>
- Wexner SD, Cortés-Guiral D, Gilshtein H, Kent I, Reymond MA. COVID-19: impact on colorectal surgery. *Colorectal Dis.* 2020;22:635-40. <https://doi.org/10.1111/codi.15112>
- Moletta L, Pierobon ES, Capovilla G, Costantini M, Salvador R, Merigliano S, et al. International guidelines and recommendations for surgery during COVID-19 pandemic: a systematic review. *Int J Surg.* 2020;79:180-8. <https://doi.org/10.1016/j.ijssu.2020.05.061>
- Martinek L, You K, Giuratrabocchetta S, Gachabayov M, Lee K, Bergamaschi R. Does laparoscopic intracorporeal ileo-colic anastomosis decrease surgical site infection rate? A propensity score-matched cohort study. *Int J Colorectal Dis.* 2018;33:291-8. <https://doi.org/10.1007/s00384-017-2957-7>
- Bollo J, Turrado V, Rabal A, Carrillo E, Gich I, Martínez MC, et al. Randomized clinical trial of intracorporeal versus extracorporeal anastomosis in laparoscopic right colectomy (IEA trial). *Br J Surg.* 2020;107:364-72. <https://doi.org/10.1002/bjs.11389>
- Serra-Aracil X, Mora-López L, Casalots A, Pericay C, Guerrero R, Navarro-Soto S. Hybrid-NOTES: TEO for transanal total mesorectal excision. Intracorporeal resection and anastomosis. *Surg Endosc.* 2016;30:346-54. <https://doi.org/10.1007/s00464-015-4170-5>
- Ceccarelli G, Biancafarina A, Patriiti A, Spaziani A, Bartoli A, Bellochi R, et al. Laparoscopic resection with intracorporeal anastomosis for colon carcinoma located in the splenic flexure. *Surg Endosc.* 2010;24:1784-8. <https://doi.org/10.1007/s00464-009-0853-0>
- Akamatsu H, Omori T, Oyama T, Tori M, Ueshima S, Nakahara M, et al. Totally laparoscopic sigmoid colectomy: a simple and safe technique for intracorporeal anastomosis. *Surg Endosc.* 2009;23:2605-9. <https://doi.org/10.1007/s00464-009-0406-6>
- Bakker IS, Grossmann I, Henneman D, Havenga K, Wiggers T. Risk factors for anastomotic leakage and leak-related mortality after colonic cancer surgery in a nationwide audit. *Br J Surg.* 2014;101(4):424-32. <https://doi.org/10.1002/bjs.9395>
- Di Saverio S, Birindelli A, Mandrioli M, Podda M, Binda GA. Intracorporeal anastomoses in emergency laparoscopic colorectal surgery from a series of 59 cases: where and how to do it—a technical note and video. *Colorectal Dis.* 2017;19:O103-O107. <https://doi.org/10.1111/codi.13642>
- Amore Bonapasta S, Lazzaro S, Passafiume F, Santoni S, Grassi GB, Longo G. Laparoscopic management of acute, severe colon ischaemia: demanding emergency extended left hemicolectomy with completely intracorporeal anastomosis—a video vignette. *Colorectal Dis.* 2019;21(12):1454-55. <https://doi.org/10.1111/codi.14812>
- Raftopoulos I, Courcoulas AP, Blumberg D. Should completely intracorporeal anastomosis be considered in obese patients who undergo laparoscopic colectomy for benign or malignant disease of the colon? *Surgery.* 2006;140:675-82. <https://doi.org/10.1016/j.surg.2006.07.013>
- Blumberg D. Laparoscopic colectomy performed using a completely intracorporeal technique is associated with similar outcome in obese and thin patients. *Surg Laparosc Endosc Per-cutan Tech.* 2009;19:57-61. <https://doi.org/10.1097/SLE.0b013e318193c780>
- Lacy AM, Garcia-Valdecasas JC, Delgado S, Castells A, Taurá P, Piqué JM, et al. Laparoscopy-assisted colectomy versus open colectomy for treatment of non-metastatic colon cancer: a randomised trial. *Lancet.* 2002;359(9325):2224-9. [https://doi.org/10.1016/S0140-6736\(02\)09290-5](https://doi.org/10.1016/S0140-6736(02)09290-5)
- National Comprehensive Cancer Network. Colon Cancer. Clinical Practice Guidelines in Oncology: National Comprehensive Cancer Network; version 4.2020 — June 15, 2020; <http://www.nccn.org>. Accessed 29 Jul 2020.

17. MIS Filtration Group. How to manage smoke evacuation and filter pneumoperitoneum during laparoscopy to minimize potential viral spread: different methods from SoMe—a video vignette. *Colorectal Dis.* 2020;22:644–5. <https://doi.org/10.1111/codi.15086>

SUPPORTING INFORMATION

Additional supporting information may be found online in the Supporting Information section.

How to cite this article: Serra-Aracil X, Mora-Lopez L, Gomez-Torres I, et al. Minimal invasive surgery for left colectomy adapted to the COVID-19 pandemic: laparoscopic intracorporeal resection and anastomosis, a 'don't touch the bowel' technique. *Colorectal Dis.* 2021;23:1562–1568. <https://doi.org/10.1111/codi.15562>