

[ CASE REPORT ]

## Successful Elimination of SARS-CoV-2 Following Vaccination with BNT162b2 after Prolonged Viral Infection in an Immunocompromised Lymphoma Patient

Masao Hagihara<sup>1</sup>, Yui Imai<sup>1</sup>, Tomoyuki Uchida<sup>1</sup>, Shin Ohara<sup>1</sup>, Morihiro Inoue<sup>1</sup>,  
Tomiyuki Sugi<sup>2</sup> and Keiko Mitamura<sup>3</sup>

### Abstract:

A 52-year-old man with mantle cell lymphoma treated with bendamustine and rituximab developed prolonged severe acute respiratory syndrome coronavirus 2 (SARS-CoV-2) infection. Despite elevated titers of anti-spike IgG antibody, protracted pancytopenia persisted for more than six months. Finally, the anti-SARS CoV-2 vaccine, BNT162b2, was administered, which improved his blood cell count and eliminated the virus. The increased anti-spike IgG titer and lymphocyte count after vaccination suggested that both humoral and cellular immunity acted in coordination to eliminate the virus.

**Key words:** SARS-CoV-2, bendamustine, prolonged infection, vaccine, anti-spike IgG, cellular immunity

(Intern Med 61: 2215-2219, 2022)

(DOI: 10.2169/internalmedicine.9513-22)

### Introduction

The coronavirus disease 2019 (COVID-19) pandemic has caused higher mortality in patients with hematological malignancies than in the general population (1). Patients with lymphoid malignancies, such as multiple myeloma or malignant lymphoma, have a high risk of developing severe COVID-19 infection and subsequent fatal complications (2). A major reason for this vulnerability is their suppressed immune function due to the nature of the hematological disorder and several immune-mediating anti-cancer agents. Rituximab, an anti-CD20 monoclonal antibody, is an anti-cancer agent that has been associated with the inefficient development of humoral immunity against severe acute respiratory syndrome coronavirus 2 (SARS-CoV-2) (3). In such cases, prolonged SARS-CoV-2 viral shedding is evident (4).

In the present case, a patient with malignant mantle cell lymphoma on a rituximab regimen presented prolonged infection with SARS-CoV-2, even after developing sufficient levels of SARS-CoV-2 anti-spike IgG antibody. The patient was vaccinated with BNT162b2, an mRNA COVID-19 vac-

cine, 197 days after testing positive for SARS-CoV-2. Subsequently, the virus was no longer detectable on day 246. This was accompanied by an increase in IgG titers and improvement of CD4<sup>+</sup> and CD8<sup>+</sup> T lymphopenia, which suggests a synergism between the effects of the humoral and cellular immune responses in eradicating the persistent viral load.

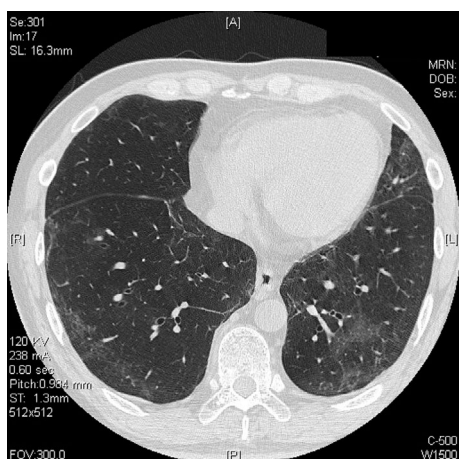
### Case Report

A 52-year-old man diagnosed with mantle cell lymphoma in June X-2 was prescribed combined chemotherapy with Hyper-CVAD (cyclophosphamide, vincristine, doxorubicin, and dexamethasone) and a rituximab regimen, followed by bendamustine and rituximab (BR) for 3 cycles. Approximately 1 month after the final cycle of BR (-44 days before the diagnosis of COVID-19), he complained of abnormal taste, and his blood cell count showed severe pancytopenia. One week later, he developed slight dyspnea and cough, and computed tomography (CT) revealed ground-glass opacity in his lungs bilaterally, which suggested SARS-CoV-2 infection (Fig. 1). Then, he was diagnosed with COVID-19-associated

<sup>1</sup>Department of Hematology, Eiju General Hospital, Japan, <sup>2</sup>Department of Pharmacy, Eiju General Hospital, Japan and <sup>3</sup>Department of Preventive Medicine, Eiju General Hospital, Japan

Received for publication February 8, 2022; Accepted for publication March 24, 2022

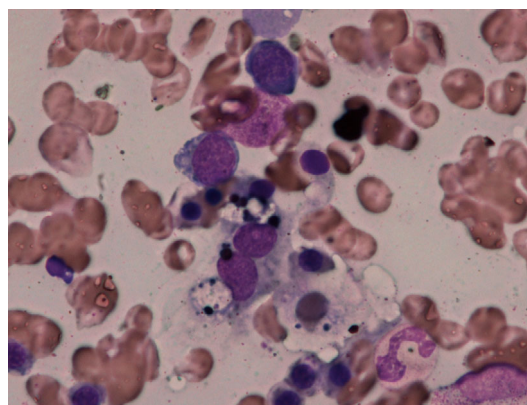
Correspondence to Dr. Masao Hagihara, hagihara@eijuhp.com



**Figure 1.** Computed tomography of the chest at the onset of COVID-19. A view of the bilateral lower lungs shows ground-glass opacity.

pneumonia based on positive results from antigen and polymerase chain reaction (PCR) tests for SARS-CoV-2, which were performed on samples obtained from nasopharyngeal specimens. He was immediately admitted to a central hospital for infection control and was administered remdesivir for 5 days. He was discharged on day 10, as all his symptoms had resolved. However, a negative PCR test result was not confirmed. Thereafter, laboratory findings showed a protracted pancytopenia, which required intermittent infusions of granulocyte colony-stimulating factor (G-CSF) and the transfusion of red blood cells and platelets. On 69 days from the onset of COVID-19, the patient again underwent PCR and antigen tests for SARS-CoV-2, both of which showed positive results. However, his SARS-CoV-2 anti-spike IgG titer was elevated as high as 10,156 AU/mL, as determined using a chemiluminescent microparticle immunoassay (SARS-CoV-2 IgG II Quant from Abbott Laboratories). On 96 days from the onset, bone marrow aspiration was conducted, which was normocellular with no infiltration of lymphoma cells. Occasionally, a proliferation of macrophages demonstrating phagocytosis of hematopoietic cells was evident (Fig. 2). Remdesivir was administered for 10 days starting from day 173 days. However, no significant improvement in peripheral blood count was evident, and he continued to show positive PCR and antigen test results.

On 197 days from the onset, he was administered his first dose of the BNT162b2 COVID-19 vaccine, to which he did not experience any severe adverse reactions. On 218 days from the onset, after receiving his second dose of the vaccine, his viral antigen test results were negative, and his cycle threshold (Ct) value increased from 21 to 34, showing a marked reduction in viral load. Approximately one month later (246 days from the onset), his PCR test result was finally negative (cut off value: 42), with an increased titer of SARS CoV-2 anti-spike IgG (20,392 AU/mL). During this clinical course, his blood cell count finally improved (Fig. 3a) together with a profound restoration of his CD4<sup>+</sup>

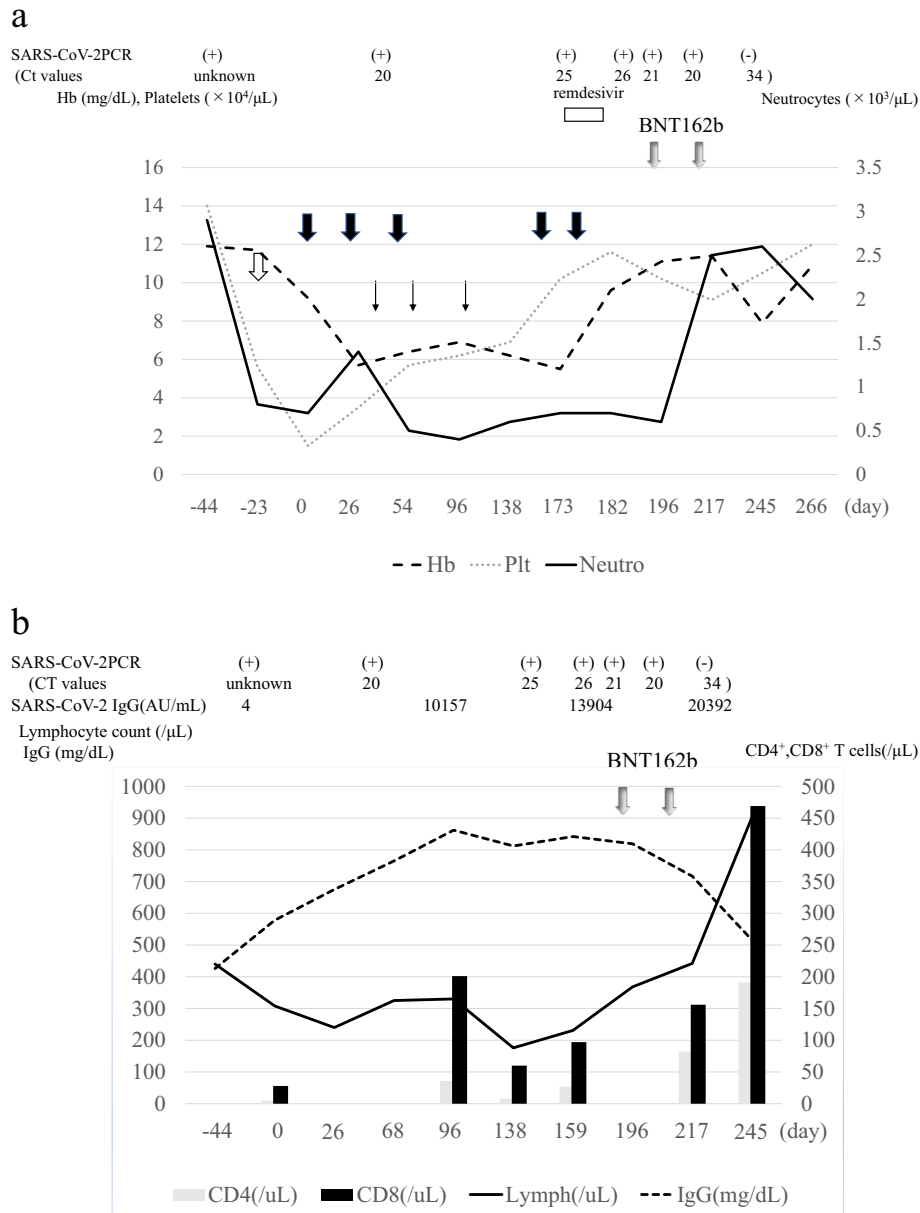


**Figure 2.** Bone marrow findings during cytopenia. The marked appearance of hemophagocytic macrophages is demonstrated.

and CD8<sup>+</sup> T cell counts after vaccination (Fig. 3b). The patient is now in remission, as confirmed via CT, and is scheduled to receive high-dose chemotherapy combined with autologous stem cell transplantation.

## Discussion

Several unusual cases of persistent SARS-CoV-2 infection in patients with cancer have been reported (4-11). In the present case, viral infection was detected up to day 246 following the initial positive test result, which is the longest duration of viral infection reported to date. Anti-CD20 monoclonal antibodies (mAb), such as rituximab or obinutuzumab, have been widely used to treat hematological cancers or autoimmune disorders, and are known to impair humoral immunity by depleting normal B-lymphocytes. Recovery of the B cell count requires 6-12 months after the completion of therapy (12). As a result, patients being treated with rituximab often develop diminished immunologic responses to various types of vaccinations, including vaccinations against influenza viruses and several pathogenic bacteria (13, 14). The development of anti-SARS-CoV-2 IgG antibodies after vaccination was reported to be diminished in patients who were recently treated with rituximab or obinutuzumab (15). Therefore, it can be concluded that patients who develop COVID-19 during or after anti-CD20 mAb treatment often do not show seropositivity, which could explain the prolonged SARS-CoV-2 infection. A major distinction from prior reports is that, in this case, the SARS-CoV-2 virus was not eliminated, even though the patient had developed relatively high levels of anti-SARS-CoV-2 IgG antibodies. When SARS-CoV-2 anti-spike IgG antibody titers were determined 69 days after the onset of COVID-19, the total IgG was at the lowest level of the normal range (765 mg/dL). Therefore, humoral antiviral immunity was considered to have effectively developed through continued stimulation by the virus. Although lower seroconversion rates have been observed in patients with hematological malignancies who develop COVID-19, over half of these patients who received



**Figure 3.** (a) Blood cell count during the clinical course. Thick black, white, and thin arrows indicate the infusion of red blood cells, platelets, and granulocyte-stimulating factor, respectively. (b) Immunological parameters during the clinical course. Day 0 indicates the diagnosed date of COVID-19.

anti-CD20 antibody therapy developed anti-SARS CoV-2 IgG antibodies (3, 16). A target antigen for the IgG antibody is the receptor-binding domain of the S1 subunit of the spike protein of SARS-CoV-2, which is associated with neutralization of the virus (17). Thus, it was considered that the IgG antibodies produced were inadequate to eliminate the large number of viral particles or that some host-specific genetic variation occurred that jeopardized the efficacy of the anti-virus IgG antibody (4).

We therefore administered remdesivir to harness its suppressive effect on viral proliferation (7). However, this strategy failed because of an excessively high viral load, which was evident from the Ct value of approximately 20. Next, the anti-SARS-CoV-2 vaccine, BNT162b2, was administered

and the remaining viral particles were successfully cleared out with a significant increase in the SARS-CoV-2 anti-spike IgG titer. Bendamustine can increase the risk of infection through profound CD4<sup>+</sup> T lymphopenia (18). It has been reported that the median CD4<sup>+</sup> T cell number significantly decreases and then recovers 7-9 months after the discontinuation of bendamustine treatment (19). It has also been reported that SARS-CoV-2-specific T cells can rapidly expand when extracted from convalescent patients and are useful in preventing infection in immunocompromised patients (20); CD8<sup>+</sup> T cells also contribute to the survival of patients with hematological cancers who develop COVID-19 (21, 22). The COVID-19 vaccine BNT162b1 could elicit robust SARS-CoV-2 spike protein-specific CD4<sup>+</sup> and CD8<sup>+</sup> T cell re-

sponses, which augment the antibody responses (23). In our case, both the CD4<sup>+</sup> and CD8<sup>+</sup> T cells expanded following vaccination. Thus, we hypothesize that the BNT162b2 vaccine stimulated both humoral and cellular immunity, probably anti-viral killer T cells, which may have acted synergistically to eliminate the virus in this case.

Our patient showed persistent pancytopenia for six months after initially testing positive for SARS-CoV-2, accompanied with a sustained high viral load. Bendamustine often induces prolonged bone marrow suppression, but this is unlikely in this case because the numbers of nuclear cells in the bone marrow were normalized. Lymphoma recurrence was also ruled out as morphologically abnormal lymphocytes were not observed in a bone marrow smear. After the eradication of the virus, the peripheral blood cell count, especially that of neutrophils and lymphocytes, prominently improved. One possible reason could be viral-induced hemophagocytosis, which has been reported, especially in severe COVID-19 (24). Besides, an antigenemia-assay ruled out any involvement of cytomegalovirus. The hemophagocytosis is triggered by the hypersecretion of several cytokines, which subsequently cause an impaired immunological function. In our case, elevated serum soluble interleukin-2 receptor (1,500-2,000 U/mL), even after the achievement of complete remission along with hyperferritinaemia (1,500-2,000 ng/dL), suggested the association of hemophagocytosis as an underlining etiology of cytopenia. Finally, the ferritin level significantly decreased (811 ng/mL) following vaccination.

Other than the hematological disturbances, several biomarkers, including lactate dehydrogenase and C-reactive proteins, remained slightly elevated (1-6 mg/dL and 211-318 U/L, respectively), while COVID-19-associated clinical manifestations were not observed after the resolution of pneumonia. We then speculated that either the virus in the present case had lost aggressiveness or the acquired anti-SARS-CoV-2 antibodies had restrained proliferation in the respiratory airways. Recently, several cases of COVID-19 after bendamustine and rituximab-treatment have been reported (25-28). In these reports, even with prolonged viral shedding, the clinical outcomes were not always unfavorable. The case with the longest (>8 months) viable viral persistence was reported by Sepulcri et al. (28), in which the recurrence of viremia with a relapse of symptomatic COVID-19 appeared even after anti-viral therapy with convalescent plasma infusion. One major difference with our patient is the failed acquisition of anti-SARS-CoV-2-specific antibodies, which have inhibitory effects as described above.

The COVID-19 pandemic has not yet subsided, and bendamustine, which has recently been approved, is now widely applied as a salvage treatment option for aggressive lymphoma in our country. Following the recommendations by expert panels worldwide, continued caution should be taken when attending patients on bendamustine and/or anti-CD20 mAb treatment in the COVID-19 era. It is essential to document the absence of SARS-CoV-2 virus at the time of release from quarantine in severely immunosuppressed cases.

#### Author's disclosure of potential Conflicts of Interest (COI).

Masao Hagihara: Honoraria, Chugai Pharmaceuticals and Janssen Pharmaceuticals.

#### References

- Pagano L, Salmanton-Garcia J, Marchesi F, et al. COVID-19 infection in adult patients with hematological malignancies: a European Hematology Association Survey (EPICOVIDEHA). *J Hematol Oncol* **14**: 168, 2021.
- Hagihara M, Ohara S, Uchida T, Inoue M. Practical management of patients with hematological diseases during the COVID-19 pandemic in Japan. *Int J Hematol* **114**: 709-718, 2021.
- Thakkar A, Pradhan K, Jindal S, et al. Patterns of seroconversion for SARS-CoV-2-IgG in patients with malignant disease and association with anticancer therapy. *Nat Cancer* **2**: 392-399, 2021.
- Avanzato VA, Matson MJ, Seifert SN, et al. Case study: prolonged infectious SARS-CoV-2 shedding from an asymptomatic immunocompromised individual with cancer. *Cell* **183**: 1901-1912 e9, 2020.
- Tepasse PR, Hafezi W, Lutz M, et al. Persisting SARS-CoV-2 viraemia after rituximab therapy: two cases with fatal outcome and a review of the literature. *Br J Haematol* **190**: 185-188, 2020.
- Koff AG, Laurent-Rolle M, Hsu JC, Malinis M. Prolonged incubation of severe acute respiratory syndrome coronavirus 2 (SARS-CoV-2) in a patient on rituximab therapy. *Infect Control Hosp Epidemiol* **42**: 1286-1288, 2021.
- Helleberg M, Niemann CU, Moestrup KS, et al. Persistent COVID-19 in an immunocompromised patient temporarily responsive to two courses of remdesivir therapy. *J Infect Dis* **222**: 1103-1107, 2020.
- Choi B, Choudhary MC, Regan J, et al. Persistence and evolution of SARS-CoV-2 in an immunocompromised host. *N Engl J Med* **383**: 2291-2293, 2020.
- Nakajima Y, Ogai A, Furukawa K, et al. Prolonged viral shedding of SARS-CoV-2 in an immunocompromised patient. *J Infect Chemother* **27**: 387-389, 2021.
- Aydillo T, Gonzalez-Reiche AS, Aslam S, et al. Shedding of viable SARS-CoV-2 after immunosuppressive therapy for cancer. *N Engl J Med* **383**: 2586-2588, 2020.
- Yasuda H, Tsukune Y, Watanabe N, et al. Persistent COVID-19 pneumonia and failure to develop anti-SARS-CoV-2 antibodies during rituximab maintenance therapy for follicular lymphoma. *Clin Lymphoma Myeloma Leuk* **20**: 774-776, 2020.
- Houot R, Levy R, Cartron G, Armand P. Could anti-CD20 therapy jeopardise the efficacy of a SARS-CoV-2 vaccine? *Eur J Cancer* **136**: 4-6, 2020.
- Eisenberg RA, Jawad AF, Boyer J, et al. Rituximab-treated patients have a poor response to influenza vaccination. *J Clin Immunol* **33**: 388-396, 2013.
- Nazi I, Kelton JG, Larche M, et al. The effect of rituximab on vaccine responses in patients with immune thrombocytopenia. *Blood* **122**: 1946-1953, 2013.
- Maneikis K, Sablauskas K, Ringeleviciute U, et al. Immunogenicity of the BNT162b2 COVID-19 mRNA vaccine and early clinical outcomes in patients with haematological malignancies in Lithuania: a national prospective cohort study. *Lancet Haematol* **8**: e583-e592, 2021.
- Levavi H, Lancman G, Gabrilove J. Impact of rituximab on COVID-19 outcomes. *Ann Hematol* **100**: 2805-2812, 2021.
- Yamayoshi S, Sakai-Tagawa Y, Koga M, et al. Comparison of rapid antigen tests for COVID-19. *Viruses* **12**: 1420, 2020.
- Fung M, Jacobsen E, Freedman A, et al. Increased risk of infectious complications in older patients with indolent non-Hodgkin lymphoma exposed to bendamustine. *Clin Infect Dis* **68**: 247-255,



- 2019.
19. Saito H, Maruyama D, Maeshima AM, et al. Prolonged lymphocytopenia after bendamustine therapy in patients with relapsed or refractory indolent B-cell and mantle cell lymphoma. *Blood Cancer J* **5**: e362, 2015.
  20. Keller MD, Harris KM, Jensen-Wachspress MA, et al. SARS-CoV-2-specific T cells are rapidly expanded for therapeutic use and target conserved regions of the membrane protein. *Blood* **136**: 2905-2917, 2020.
  21. Gallais F, Velay A, Nazon C, et al. Intrafamilial exposure to SARS-CoV-2 associated with cellular immune response without seroconversion, France. *Emerg Infect Dis* **27**: 113-121, 2021.
  22. Bange EM, Han NA, Wileyto P, et al. CD8<sup>+</sup> T cells contribute to survival in patients with COVID-19 and hematologic cancer. *Nat Med* **27**: 1280-1289, 2021.
  23. Sahin U, Muik A, Derhovanessian E, et al. COVID-19 vaccine BNT162b1 elicits human antibody and TH1 T cell responses. *Nature* **586**: 594-599, 2020.
  24. Soy M, Atagunduz P, Atagunduz I, Sucak GT. Hemophagocytic lymphohistiocytosis: a review inspired by the COVID-19 pandemic. *Rheumatol Int* **41**: 7-18, 2021.
  25. Sung A, Bailey AL, Stewart HB, et al. Isolation of SARS-CoV-2 in viral cell culture in immunocompromised patients with persistently positive RT-PCR results. *Front Cell Infect Microbiol* **12**: 804175, 2022.
  26. Arai T, Mukai S, Kazama R, et al. Persistent viral shedding of severe acute respiratory syndrome coronavirus 2 after treatment with bendamustine and rituximab: a case report. *J Infect Chemother.* Forthcoming.
  27. Regalado-Artamendi I, Jimenez-Ubieto A, Hernandez-Rivas JA, et al. Risk factors and mortality of COVID-19 in patients with lymphoma: a multicenter study. *Hemasphere* **5**: e538, 2021.
  28. Sepulcri C, Dentone C, Mikulska M, et al. The longest persistence of viable SARS-CoV-2 with recurrence of viremia and relapsing symptomatic COVID-19 in an immunocompromised patient - a case study. *Open Forum Infect Dis* **8**: ofab217, 2021.

The Internal Medicine is an Open Access journal distributed under the Creative Commons Attribution-NonCommercial-NoDerivatives 4.0 International License. To view the details of this license, please visit (<https://creativecommons.org/licenses/by-nc-nd/4.0/>).