

Available online at [www.sciencedirect.com](http://www.sciencedirect.com)

ScienceDirect

journal homepage: [www.elsevier.com/locate/radcr](http://www.elsevier.com/locate/radcr)

## Case Report

## A case of inguinal lymphogranuloma venereum imitating malignancy on CT imaging

Katherine Promer, MD<sup>a,\*</sup>, Allan Pillay, PhD<sup>b</sup>, Kai-Hua Chi, MS<sup>b</sup>, Noushin Vahdat, MD<sup>c</sup>, Samantha S. Katz, PhD<sup>b</sup>, Cheng Y. Chen, PhD<sup>b</sup>, Joshua Fierer, MD<sup>a,c</sup>

<sup>a</sup> UC San Diego Health, CA, USA

<sup>b</sup> Centers for Disease Control and Prevention (CDC), Atlanta, GA, USA

<sup>c</sup> VA San Diego Healthcare System, CA, USA

## ARTICLE INFO

## Article history:

Received 17 December 2018

Revised 13 February 2019

Accepted 14 February 2019

Available online 5 March 2019

## Keywords:

Lymphogranuloma venereum

Computed tomography

Chlamydia trachomatis

## ABSTRACT

Lymphogranuloma venereum is a sexually transmitted infection caused by serovars L1, L2, and L3 of *Chlamydia trachomatis*. We here report a case of Lymphogranuloma venereum, confirmed by PCR testing, which mimicked malignancy on CT imaging.

© 2019 The Authors. Published by Elsevier Inc. on behalf of University of Washington.

This is an open access article under the CC BY-NC-ND license.

(<http://creativecommons.org/licenses/by-nc-nd/4.0/>)

### Case description

A 63-year-old man who has sex with men with HIV (viral load < 20 copies/mL, CD4<sup>+</sup> 573/mL) and recurrent balanitis presented to an emergency department (ED) in San Diego, California with right groin pain and swelling. He first noted a penile lesion and right groin swelling 3 weeks prior. Syphilis serology and HSV lesion polymerase chain reaction (PCR) were negative, so symptoms were attributed to recurrent balanitis. The penile lesion diminished with fluconazole, but progressive right groin swelling and development of fever prompted a visit to the ED.

Physical exam revealed a 3 cm tender right inguinal mass and a 0.5 cm macule at the dorsal-proximal penile shaft with-

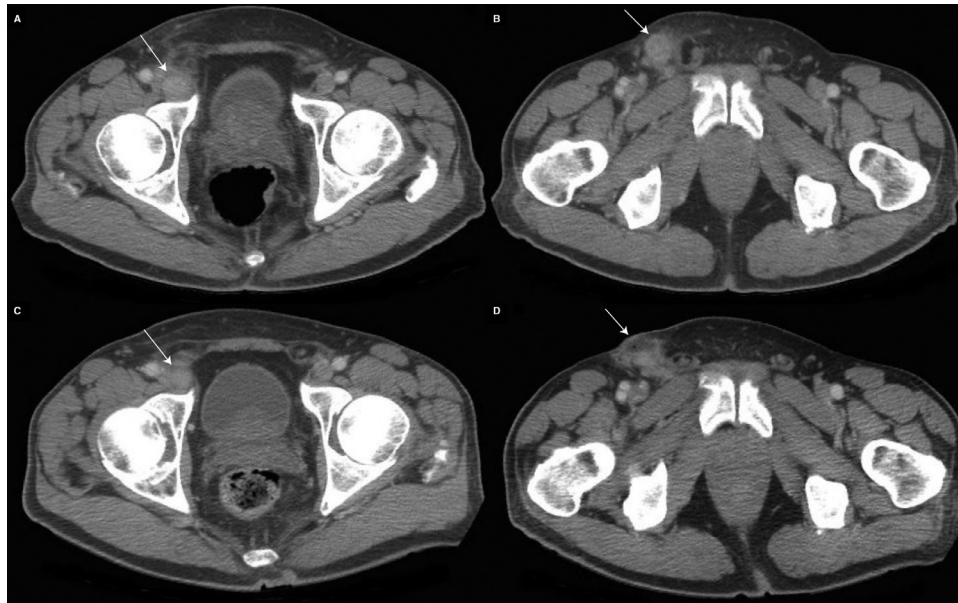
out evidence of active balanitis. CT (Fig. 1a and b) revealed multiple enhancing, enlarged right inguinal and external iliac lymph nodes, concerning for lymphoma or metastatic or inflammatory adenopathy, so the patient was admitted for further evaluation. The infectious diseases consultant considered lymphogranuloma venereum (LGV), syphilis, and chancroid as possible diagnoses, recommending empiric treatment with doxycycline 100 mg twice daily and one dose of 250 mg intramuscular ceftriaxone. Surgery performed an excisional biopsy leaving a drain in place. Grossly, the mass resembled a purulent lymph node, and histology revealed fibro-adipose tissue with marked acute and chronic inflammation but no visible nodal tissue. Neither Gram stain, Giemsa stain, nor bacterial cultures revealed a causative organism. The patient was discharged to complete 21 days of doxycycline for presumptive LGV treatment and advised to inform his most recent partners of this diagnosis. After he was discharged, the urine molecular test resulted as positive for Chlamydia (Cobas

\* Corresponding author.

E-mail address: [kpromer@ucsd.edu](mailto:kpromer@ucsd.edu) (K. Promer).

<https://doi.org/10.1016/j.radcr.2019.02.012>

1930-0433/© 2019 The Authors. Published by Elsevier Inc. on behalf of University of Washington. This is an open access article under the CC BY-NC-ND license. (<http://creativecommons.org/licenses/by-nc-nd/4.0/>)



**Fig. 1 – Contrast enhanced CT images of the abdomen and pelvis. (A) Axial slice of the initial CT demonstrating 2.1 cm enhancing right external iliac lymph node (arrow). (B) Axial slice of the initial CT demonstrating 2.7 cm enhancing right inguinal lymph node (arrow). (C) Axial slice of the follow-up CT demonstrating decrease in size of external iliac lymph node to 1.7 cm (arrow). (D) Axial slice of the follow-up CT demonstrating small anterior fluid collection at site of biopsy in right inguinal region attributed to post-surgical changes (arrow).**

4800 CT/NG test [Roche Molecular Diagnostics, Pleasanton, CA, USA]), further supporting the diagnosis.

Fever and groin pain improved, but on day 10 of doxycycline, he returned to the ED with diffuse abdominal pain. Repeat CT (Fig. 1c and d) demonstrated enhancing right inguinal lymph nodes, smaller but still concerning for lymphoma or metastatic disease. Abdominal pain resolved, and CT findings were attributed again to LGV. The patient was discharged and continued to improve on doxycycline treatment.

A formalin-fixed paraffin-embedded (FFPE) sample and 2 fresh tissue specimens, refrigerated for a week prior to freezing, were shipped on dry ice to the Centers for Disease Control and Prevention for LGV PCR and genotyping. Genomic DNA was extracted using the ChargeSwitch gDNA Mini Tissue Kit (Thermo Fisher Scientific, Waltham, MA, USA) and tested for LGV and non-LGV *C. trachomatis* using a real-time quadriplex PCR assay [1]. All 3 specimens tested positive for LGV. Nested PCR amplification of the *ompA* gene and sequencing of the amplicon using the BigDye Terminator v3.1 Cycle Sequencing Kit and an ABI 3130xl Genetic Analyzer (Applied Biosystems, Foster, CA, USA) [2] identified the L2b-variant.

## Discussion

Data on the incidence of LGV in San Diego County had been limited in the years preceding this 2017 case. The 9 reported cases in 2012 and the fewer than 5 reported cases per year between 2013 and 2016 likely underestimate true incidence. Most reported LGV cases in men who has sex with men

present as proctitis with rectal bleeding, tenesmus, and abdominal pain; a genital lesion with tender lymphadenopathy is less common [3].

Several testing options exist for the diagnosis of LGV. Genital, rectal, and lymph node specimens can be tested for *C. trachomatis* by culture, direct immunofluorescence, or nucleic acid amplification tests [4,5]. Commercial direct immunofluorescence kits using antimajor outer member protein antibodies are *C. trachomatis*-specific, while those with antilipopolsaccharide antibodies cross-react with nontrachomatis chlamydia, and nonchlamydial bacteria [6]. Serology may also support the diagnosis of LGV in the appropriate clinical context [4,5]. Lastly, PCR testing on unstained FFPE or fresh tissue can differentiate LGV strains from other serovars of *C. trachomatis* [1,7].

PCR has been used to detect LGV in rectal, bubo aspirate, penile lesion, urethral, and urine specimens [8–10]. An ideal specimen for PCR should be frozen immediately at  $-80^{\circ}\text{C}$  or stored only 1–2 hours at  $4^{\circ}\text{C}$  prior to freezing. In this case, genotyping revealed the L2b-variant, the major serovar implicated in the 2003 European LGV outbreak and subsequently in North America [11–13]. Genotyping can be used for molecular epidemiology to establish transmission chains [14]. A series of 5 atypical LGV cases presenting with painful, edematous genital ulceration caused by L2b suggests that this variant is more virulent than other genotypes [15].

Characterization of LGV imaging findings is limited to 3 case reports with CT images depicting cervical or rectal tissue involvement resembling cancer [16–18]. In our case, a correct clinical diagnosis was made by the infectious diseases consultant through history, physical exam, and appropriate

laboratory testing. The surgical biopsy and hospitalization may have all been avoided had management focused on an infectious etiology rather than pursuing further work-up of possible malignancy. This case, however, emphasizes that LGV should be included in the differential diagnosis of unilateral inguinal lymphadenopathy and provides the opportunity to demonstrate the CT appearance of inguinal LGV, which may imitate malignancy.

## Conclusion

Imaging is generally not required to diagnose LGV and, as this case illustrates, does not distinguish from lymphoma or metastatic adenopathy. Therefore, particularly in a patient with appropriate risk factors, LGV should be included in the differential diagnosis along with metastasis, lymphoma, and other infectious or inflammatory etiologies.

## Acknowledgments

We thank Kimberly Workowski from the Centers for Disease Control and Prevention and Wael Alshehri from UC San Diego Health for their helpful comments during the preparation of the manuscript and Ryan D. Murphy from the California Department of Public Health for providing statistics on case incidence of LGV in San Diego County.

## Disclaimer

The findings and conclusions in this paper are those of the authors and do not necessarily represent the views of the Centers for Disease Control and Prevention. The authors report no potential conflicts of interest.

## Funding

Katherine Promer is supported by a grant from the National Institutes of Health: T32 AI 007036

## REFERENCES

- [1] Chen CY, Chi KH, Alexander S, Ison CA, Ballard RC. A real-time quadriplex PCR assay for the diagnosis of rectal lymphogranuloma venereum and non-lymphogranuloma venereum Chlamydia trachomatis infections. *Sex Transm Infect* 2008;84(4):273–6.
- [2] Halse TA, Musser KA, Limberger RJ. A multiplexed real-time PCR assay for rapid detection of Chlamydia trachomatis and identification of serovar L-2, the major cause of Lymphogranuloma venereum in New York. *Mol Cell Probes* 2006;20(5):290–7.
- [3] Stoner BP, Cohen SE. Lymphogranuloma venereum 2015: clinical presentation, diagnosis, and treatment. *Clin Infect Dis* 2015;61(Suppl 8):S865–73.
- [4] Workowski KA, Bolan GA. Sexually transmitted diseases treatment guidelines, 2015. *MMWR Recomm Rep* 2015;64(Rr-03):1–137.
- [5] Mabey D, Peeling RW. Lymphogranuloma venereum. *Sex Transm Infect* 2002;78(2):90–2.
- [6] Johnson RE, Newhall WJ, Papp JR, Knapp JS, Black CM, Gift TL, et al. Screening tests to detect Chlamydia trachomatis and Neisseria gonorrhoeae infections—2002. *MMWR Recomm Rep* 2002;51(Rr-15):1–38 quiz CE1–4.
- [7] Kersh EN, Pillay A, de Voux A, Chen C. Laboratory processes for confirmation of lymphogranuloma venereum infection during a 2015 investigation of a cluster of cases in the United States. *Sex Transm Dis* 2017;44(11):691–4.
- [8] Markowicz M, Grilnberger E, Huber F, Leibl G, Abrahamian H, Gartner M, et al. Case report: lymphogranuloma venereum proctitis—from rapid screening to molecular confirmation of a masked sexually transmitted disease. *Diagn Microbiol Infect Dis* 2013;76(4):516–17.
- [9] Sethi G, Allason-Jones E, Richens J, Annan NT, Hawkins D, Ekbote A, et al. Lymphogranuloma venereum presenting as genital ulceration and inguinal syndrome in men who have sex with men in London, UK. *Sex Transm Infect* 2009;85(3):165–70.
- [10] Bauwens JE, Orlander H, Gomez MP, Lampe M, Morse S, Stamm WE, et al. Epidemic Lymphogranuloma venereum during epidemics of crack cocaine use and HIV infection in the Bahamas. *Sex Transm Dis* 2002;29(5):253–9.
- [11] Spaargaren J, Fennema HS, Morre SA, de Vries HJ, Coutinho RA. New lymphogranuloma venereum Chlamydia trachomatis variant, Amsterdam. *Emerg Infect Dis* 2005;11(7):1090–2.
- [12] Herida M, de Barbeyrac B, Sednaoui P, Scieux C, Lemarchand N, Kreplak G, et al. Rectal lymphogranuloma venereum surveillance in France 2004–2005. *Euro Surveill* 2006;11(9):155–6.
- [13] Kropp RY, Wong T, Canadian LGVWG. Emergence of lymphogranuloma venereum in Canada. *CMAJ* 2005;172(13):1674–6.
- [14] Kendall BA, Tardif KD, Schlaberg R. Chlamydia trachomatis L serovars and dominance of novel L2b ompA variants, U.S.A. *Sex Transm Infect* 2014;90(4):336.
- [15] Haber R, Maatouk I, de Barbeyrac B, Bagot M, Janier M, Fouere S. Lymphogranuloma Venereum-serovar l2b presenting with painful genital ulceration: an emerging clinical presentation? *Sex Transm Dis* 2017;44(5):310–12.
- [16] Berment H, Mehdaoui D, Koning E, Ramirez S, Lemoine F, Sabourin J. Pseudotumoral venereal lymphogranulomatosis: a case report. *J Radiol*. 2010;91(1 Pt 1):65–8.
- [17] Zweizig S, Schlaerth JB, Boswell WD Jr. Computed tomography of lymphogranuloma venereum mimicking cervical cancer. *Comput Med Imaging Graph* 1991;15(2):97–100.
- [18] Sullivan B, Glaab J, Gupta RT, et al. Lymphogranuloma venereum (LGV) proctocolitis mimicking rectal lymphoma. *Radiol Case Rep* 2018;13:1119–22.