Approach to malignant pleural effusions: Role of pleural manometry exemplified by case scenarios

Irfan Ismail Ayub

Department of Pulmonary Medicine, Sri Ramachandra Medical College and Research Institute, Chennai, Tamil Nadu, India

ABSTRACT

Issues related to the management of pleural effusion in India are unique. With high incidence of tuberculosis and malignancy, managing patients with pleural effusion may not be the same between patients. Decisions on intercostal chest drain insertion, volume of fluid to be removed during therapeutic thoracentesis, and further diagnostic imaging and investigations are often taken with difficulty in low-resource settings. Pleural manometry can help resolve these issues and help in the management of such patients. Pleural manometry has been advocated as a valuable tool to characterize underlying lung behavior during thoracentesis and has been proposed to be useful in diagnosing unexpandable lung, predicting the success of pleurodesis, and preventing the development of excessively negative pleural pressures which in turn may lead to the development of reexpansion pulmonary edema. There is very little literature on pleural manometry from India and other developing countries. In this article, the utility of pleural manometry in managing patients with malignant pleural effusion is discussed.

KEY WORDS: Malignant pleural effusion, pleural manometry, thoracic ultrasound

Address for correspondence: Dr. Irfan Ismail Ayub, Department of Pulmonary Medicine, First Floor Link, G Block, Sri Ramachandra Medical College and Research Institute, Porur, Chennai - 600 116, Tamil Nadu, India. E-mail: iia@rediffmail.com

INTRODUCTION

There are no estimates on the incidence rates of patients with pleural effusion in India. However, a significant percentage of our patients present with pleural effusion. There are specific problems with managing patients with pleural effusion in India. With tuberculosis still endemic in India and with an increase in the incidence of malignancy, managing patients with pleural effusion may not be the same between patients. In tubercular pleural effusion, one may insert an intercostal chest drain (ICD) to drain the pleural effusion following which ICD can be removed following complete lung expansion. However, in malignant pleural effusions, one must be overtly cautious before placing an ICD as this may be detrimental to patient care, especially in the setting of unexpandable lung. With an increase in patients presenting with malignant pleural effusion, it becomes difficult to decide on proper patient selection for ICD insertion. For patients in whom a decision is taken not to place an ICD, one must decide on how much fluid should be aspirated in a single sitting and also must deal with the resultant increasing influx of patients coming for review visits for therapeutic thoracentesis, thus increasing the load on an already overburdened health service. In patients with undiagnosed pleural effusion, a decision has to be taken on when to request for a computed tomogram (CT) scan of the chest. Costs to the patient do not permit repeat CT scans if the earlier CT scan was ordered in haste. Further, a decision has to be taken on which diagnostic tool to proceed with: bronchoscopy, medical thoracoscopy, or image-guided biopsy. Pleural manometry can help resolve these issues and help in the management of such patients.

Access this article online	
Quick Response Code:	Website: www.lungindia.com
	DOI: 10.4103/lungindia.lungindia_153_17

This is an open access journal, and articles are distributed under the terms of the Creative Commons Attribution-NonCommercial-ShareAlike 4.0 License, which allows others to remix, tweak, and build upon the work non-commercially, as long as appropriate credit is given and the new creations are licensed under the identical terms.

For reprints contact: reprints@medknow.com

How to cite this article: Ayub II. Approach to malignant pleural effusions: Role of pleural manometry exemplified by case scenarios. Lung India 2019;36:142-8.

© 2019 Indian Chest Society | Published by Wolters Kluwer - Medknow

ROLE OF PLEURAL MANOMETRY

Pleural manometry has been advocated as a valuable tool to characterize underlying lung behavior during thoracentesis.[1] It has been proposed to be useful in diagnosing unexpandable lung, predicting the success of pleurodesis, and preventing the development of excessively negative pleural pressures which in turn may lead to the development of reexpansion pulmonary edema.[2-4] It is a simple and relatively safe procedure to perform and can be incorporated as part of routine pleural fluid thoracentesis procedures. In addition to the above indications, pleural manometry may have increased utility in managing patients with malignant pleural effusion, especially in low-resource settings as described below:

To decide whether a chest drain insertion would provide symptomatic relief in a patient with malignant pleural effusion and underlying lung mass presenting with dyspnea

When a patient with an existing malignant lung mass and moderate asymptomatic pleural effusion develops acute dyspnea associated with a sudden increase in the size of the effusion, a decision has to be taken on whether a chest drain should be placed for the effusion, and this is probably determined by trying to understand the reason behind the "acute" increase in the volume of the effusion. A chest drain may alleviate dyspnea if the effusion had increased due to progressive malignant infiltration of the pleura. However, if the effusion had increased due to further growth of the underlying mass leading to an active collapse, then, insertion of a chest drain may lead to worsening symptoms [Figure 1a-e]. Pleural manometry can be utilized to determine which of the two "forces" dominate: negative pleural pressure due to the active collapse or positive pleural pressure secondary to the effusion. This way, a chest drain can be placed when the major determinant of pleural pressure is the direct involvement of the pleura rather than the active lung collapse. If a chest drain is inserted in the latter scenario, the pleural fluid will drain off creating a predominantly negative pleural pressure (contributed both by the active collapse and the drainage of the effusion). This effective negative pleural pressure will lead to either a pneumothorax or shift of the mediastinum to the same side. This may lead to V/Q mismatch in the normal lung in addition to reexpansion pulmonary edema in the diseased lung and lead to hypoxemia. Thus, a chest drain should be avoided in such cases.

To decrease the frequency of hospital visits for repeated therapeutic thoracentesis in patients with malignant pleural effusion and unexpandable lung

Immediate relief of dyspnea in patients with lung cancer and malignant pleural effusion can be achieved through a therapeutic thoracentesis. In the absence of pleural manometry, one will not have an indication on how much pleural fluid can safely be removed in a single sitting. In such a situation, to be cautious and avoid reexpansion pulmonary edema, not more than 1 L is usually removed in a single sitting [Figure 2a and b]. However, when the patient has rapidly reaccumulating pleural effusion, repeated sessions of "limited" volume thoracentesis will be required, leading to recurring costs and multiple hospital visits for the same. This can be avoided with the

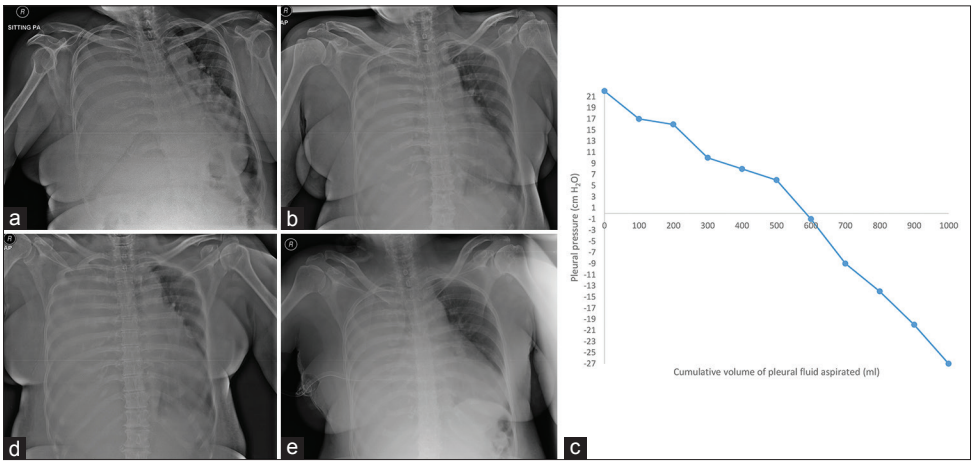

Figure 1: The "swinging mediastinum." (a, b, d, and e) Show chest X-ray anteroposterior view images of a 70-year-old female presenting with acute dyspnea. She was diagnosed with right upper lobe adenocarcinoma (computed tomogram-guided biopsy) with paramalignant pleural effusion a year ago and was on palliative care. At that time, she developed a hydropneumothorax following intercostal chest drain insertion. Intercostal chest drain was removed after a week. She required 2 hospital visits in the last year for therapeutic thoracentesis to relieve dyspnea. (a) Chest X-ray shows right massive pleural effusion with contralateral shift of mediastinum. (b) Mediastinum is at the center after aspirating 2100 ml of pleural fluid (final 1100 ml guided by pleural manometry). The patient's dyspnea had reduced. Right hemithorax appears radio-opaque due to residual effusion and underlying lung mass. (c) Pleural elastance curve shows pleural pressure of –27 cm H_2O after removing 2100 ml of fluid, which coincided with the development of chest pain. (d) Chest X-ray taken 2 days later showing increase in right pleural effusion with contralateral mediastinal shift. The patient started to develop worsening dyspnea. (e) Chest X-ray taken postemergency intercostal chest drain insertion 3 days after the earlier chest X-ray. Over 2 L of pleural fluid drained. The mediastinum has now shifted to the same side as the effusion. The patient became hypoxemic after intercostal chest drain insertion and was later intubated. She died a week later

use of tunneled indwelling pleural catheters. The latter is limited by high costs (both at the onset and recurring costs with respect to the vacuum jars) in our setting. In such a case, simple pleural manometry can enable larger volume of pleural fluid to be removed in a single sitting and thus increase the symptom-free interval between visits for therapeutic thoracentesis [Figures 2b, c, e and 3c, d].

To increase the likelihood of obtaining significant radiological information from a computed tomogram scan

In a patient with massive pleural effusion with or without a mediastinal shift to the contralateral side, and when repeated cytological examination of the pleural fluid is nondiagnostic, we may have to proceed with a CT scan of the chest. If the CT scan is taken without draining the pleural fluid effectively, the CT scan may end up adding no extra information to the chest X-ray (CXR) as the pleural effusion would lead to passive collapse of the underlying lung and any lesion in the lung may be missed [Figure 3a and b]. Performing a therapeutic thoracentesis guided by pleural manometry may aid in removing as much fluid as possible and thus increase the likelihood of obtaining significant radiological information from the CT scan [Figure 2a-f]. This can help avoid repeat CT scans.

To decide on whether bronchoscopy may be of diagnostic utility in patients with malignant pleural effusion

In a patient with massive malignant pleural effusion and "surprisingly" minimal mediastinal shift to the contralateral side, the pulmonologist has to deal with the dilemma on how to proceed with diagnostic investigations – whether to opt for bronchoscopy to look for an endobronchial growth or to proceed with a medical thoracoscopy. The latter is likely to yield when the pleural fluid shows positive malignant cytology. However, this is offset by the possibility of the lung not expanding following thoracoscopy if there is an endobronchial growth. This will in turn prolong hospital stay and further increase costs if the patient has to be discharged finally on an indwelling pleural catheter. One might argue that a bronchoscopy can be done in all patients before thoracoscopy to avoid such a scenario, but this will also add to patient's costs in addition to increasing discomfort, when one intervention alone would have probably sufficed in achieving a diagnostic sample.

Pleural manometry may be of use in such situations. In massive malignant pleural effusion, pleural pressure is expected to be positive at the onset, and as we drain the

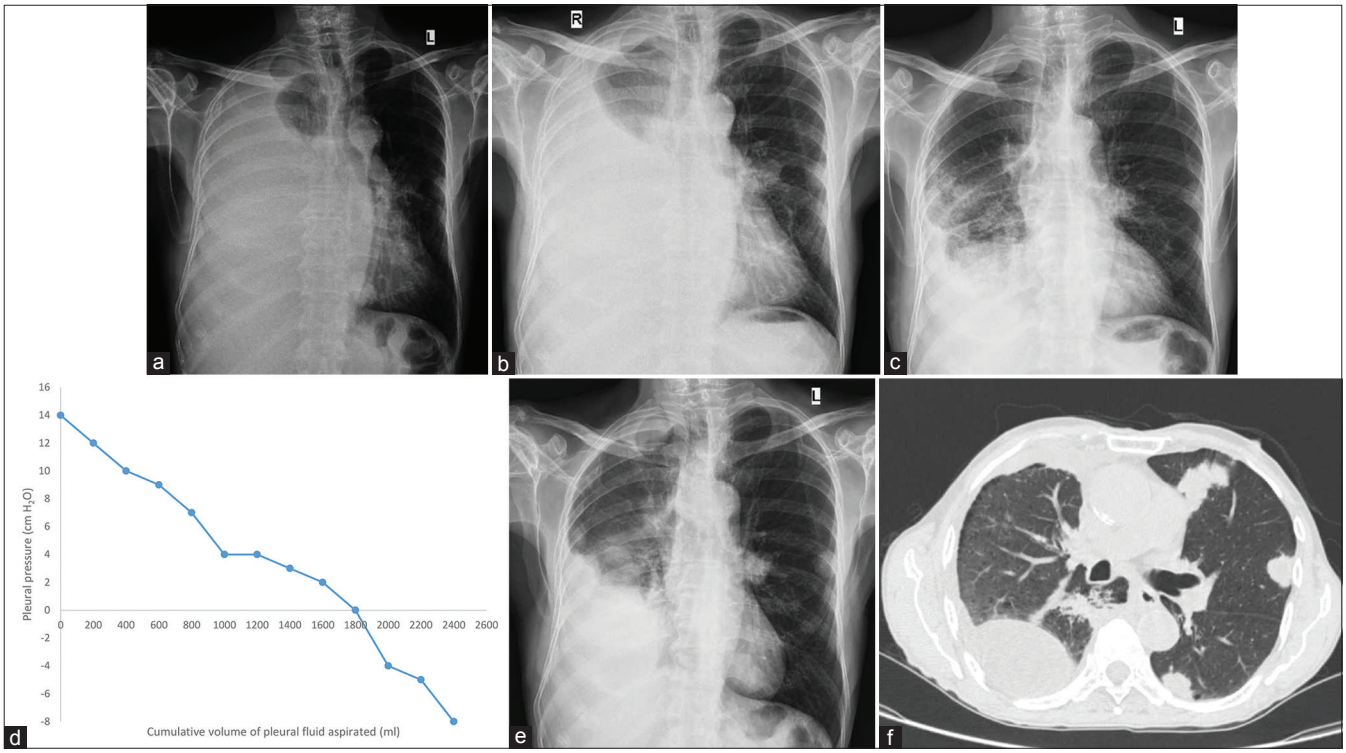

Figure 2: (a-f) Show images from a 64-year-old male who was earlier diagnosed with squamous cell carcinoma of the buccal mucosa and has undergone surgical excision and radiotherapy for the same 2 years ago. He presented now with acute onset dyspnea of 2-week duration. (a) Chest X-ray shows right massive pleural effusion with contralateral mediastinal shift. (b) Chest X-ray taken after therapeutic thoracentesis of 1 L in the absence of pleural manometry. There appears to be no significant change in the size of the effusion. (c) Chest X-ray taken the same day after aspirating 2400 ml of pleural fluid under pleural manometry. Nodular lesions are seen in the underlying right lung now. Interestingly, a nodule is also seen peripherally in the left mid zone which was not noticeable in the earlier chest X-ray. (d) Pleural elastance curve showing a pleural pressure of −8 cm H_2O after the removal of 2400 ml of fluid. The procedure was stopped as the patient complained of chest pain. (e) Chest X-ray taken 4 days later shows no significant reaccumulation of effusion. (f) Computed tomogram chest at the level of left secondary carina shows bilateral lung nodules. Biopsy of the large right pleural based nodule showed metastatic malignancy whereas pleural fluid did not show malignant cytology. He was started on chemotherapy and has not required further therapeutic thoracentesis since 5 months

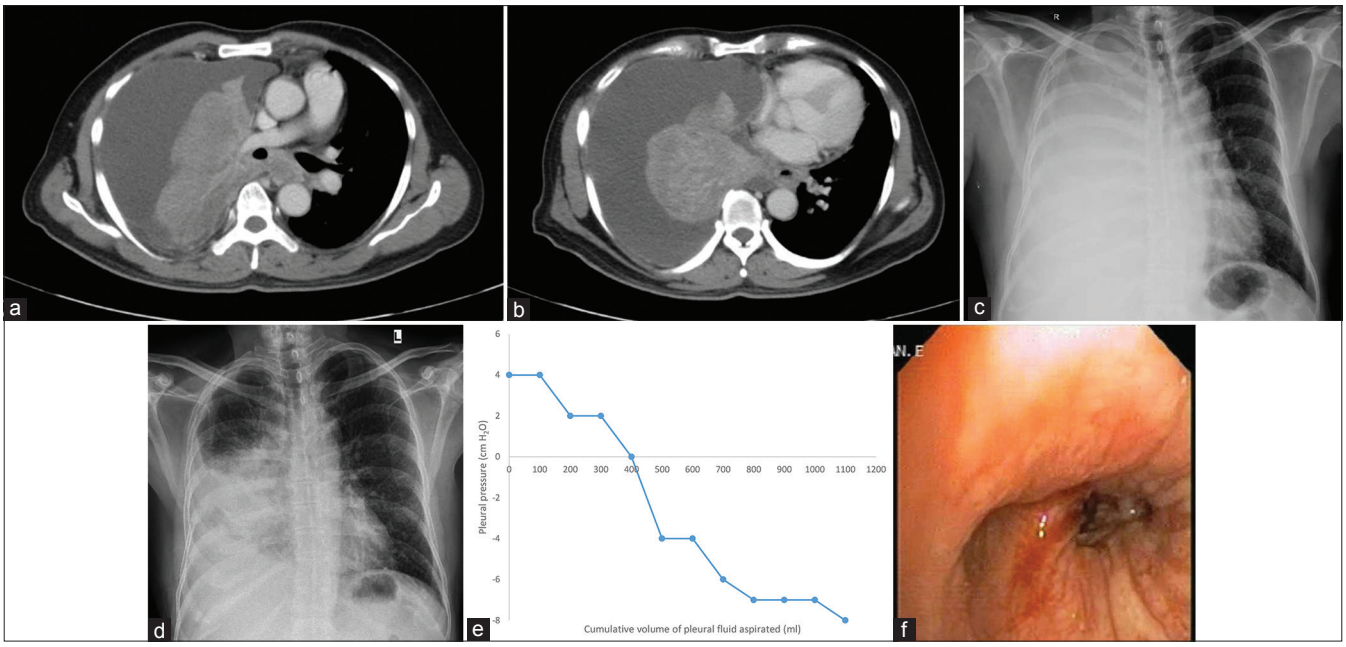

Figure 3: (a-f) Show images from a 57-year-old male who presented with progressive dyspnea of 15-day duration. He was diagnosed with right pleural effusion on chest X-ray by a general practitioner, and 900 ml of hemorrhagic pleural fluid was aspirated in the absence of pleural manometry, cytological examination of which revealed atypical cells. (a and b) Contrast-enhanced computed tomogram scan of the chest at levels of left secondary carina and left ventricular outflow tract show massive right pleural effusion with contralateral mediastinal shift and subcarinal lymphadenopathy. There is passive collapse of the underlying lung with no obvious lung abnormality on radiology. (c and d) Chest X-ray taken before and posttherapeutic thoracentesis guided by pleural manometry. Postaspiration, the mediastinum is at the center. (e) Pleural elastance curve shows pleural pressure of −8 cm H_2O after aspirating 1100 ml of effusion. The patient developed chest pain and the procedure was terminated. (f) Right intermedius bronchus showing mucosal nodularity during flexible video bronchoscopy with the lumen of the middle lobe (left) and right lower lobe (right) seen. Right upper lobe was completely occluded by extrinsic compression. Mucosal biopsy from intermedius bronchus and transbronchial needle aspiration from subcarinal station showed adenocarcinoma. The patient chose not to proceed with chemotherapy and was discharged. He died 45 days later at home without requirement for repeat therapeutic thoracentesis

fluid, the pressures are expected to decrease. If the pleural pressure falls below −19 mm H_2O, it suggests that there is, in addition to active malignant pleural involvement, an unexpandable lung. Thus, in such a case, one may consider performing a bronchoscopy to look for any endobronchial pathology [Figure 3a-f].

To perform ultrasound-guided biopsy of lung mass in the presence of a large pleural effusion

In patients with large pleural effusion and underlying lung mass and no obvious endobronchial involvement, a CT-guided biopsy is the preferred technique to achieve a histopathological diagnosis. This is usually costlier than performing an ultrasound-guided biopsy of the lung mass in addition to increasing radiation exposure. When there is a large pleural effusion, getting diagnostic tissue by ultrasound guidance may be difficult. Insertion of a chest drain to drain off some of the effusion may lead to the replacement of the effusion with air in the pleural space, especially if there is coexisting unexpandable lung. Air in the pleural space will make it technically more challenging to proceed with an ultrasound-guided biopsy. Pleural manometry can be of use in such situations. Pleural pressure guided therapeutic thoracentesis will enable large volume of pleural fluid to be removed and eventually lead to lesser volume of pleural fluid interface lying in between the ultrasound transducer and the underlying lung mass, hence making ultrasound guided biopsy easier to perform [Figure 4a-f].

DISCUSSION

Very little literature has been published on the usage of pleural manometry from India. The reason may be that many pulmonologists may not understand the physiological basis for performing pleural manometry.[5] Lack of pleural subspecialty training or fellowship programs and the absence of pleural subspecialty clinics may also contribute to the former.[6] Furthermore, performing pleural manometry has not been shown to have an effect on better patient outcomes.

The normal pleural space contains approximately 10–20 ml of pleural fluid, and normal pleural pressures vary from −5 cm H_2O at the end of expiration to −10 cm H_2O at the end of inspiration. With the presence of pleural effusion, the pleural pressures will become positive. As pleural fluid is drained, the pleural pressure will start to fall. Plotting the pleural pressure recordings against cumulative pleural fluid removed gives us the pleural elastance curves which gives information regarding the underlying lung and its ability to expand following thoracentesis. In normal underlying lung with pleural effusion, opening pleural pressure is

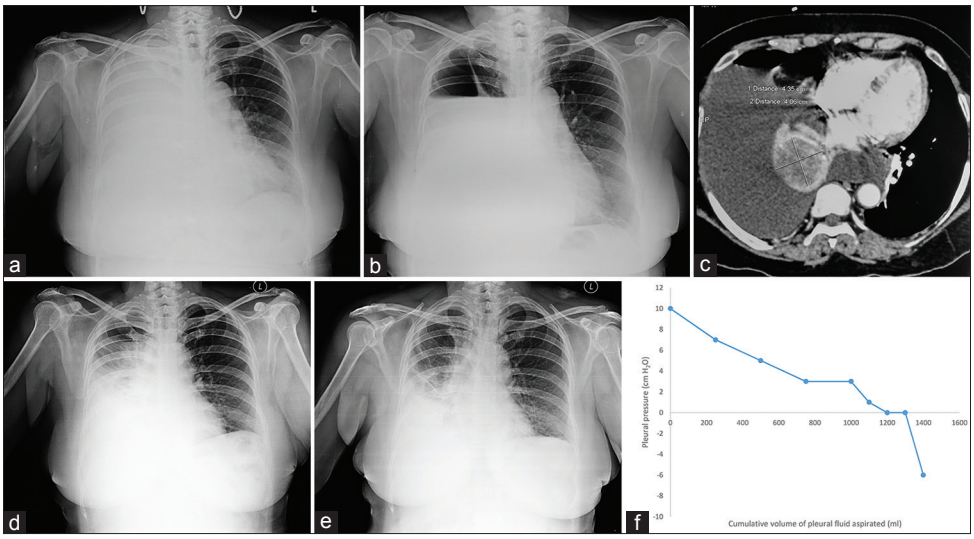

Figure 4: Performing pleural manometry to assist ultrasound-guided biopsy of lung mass. (a-e) Shows images from a 61-year-old female who presented with dyspnea of 2-week duration. She had earlier presented elsewhere where chest X-ray posteroanterior view (a) showed right massive pleural effusion with mediastinal shift to the contralateral side. (b) Chest X-ray taken after attempted aspiration of 1.5 L of pleural effusion in the absence of pleural manometry shows right hydropneumothorax. (c) Contrast-enhanced computed tomogram chest at the level of ventricular chambers shows right hydropneumothorax with underlying lung mass and subcarinal lymphadenopathy. (d) Chest X-ray taken a week later when she presented to me. The air pocket in the pleural space had apparently got absorbed. (e) Chest X-ray taken after draining 1400 ml of pleural fluid under pleural pressure monitoring. The medial margin of the right lower lung mass is well defined. (f) Pleural elastance curve on the removal of 1400 ml of pleural effusion. Pleural pressure dropped suddenly to −6 cm H_2O and the patient developed chest pain and the procedure was stopped. Following which, the lung mass was visualized nearer to the chest wall on ultrasound and biopsy was performed under ultrasound guidance. Histopathology revealed adenocarcinoma and pleural fluid cytology revealed atypical cells

positive and starts to fall but remains positive with the removal of the fluid. In lung entrapment, opening pleural pressure is positive and starts to fall and reaches negative values with fluid removal. However, the pleural pressure recording does not reach values < -19 cm H_2O. In trapped lung, opening pleural pressure is negative at the onset and reaches further negative values to below -19 cm H_2O with progressive fluid removal.[2,3]

Inability of the underlying lung to expand following therapeutic thoracentesis has earlier been referred to either trapped lung or lung entrapment. In the former, there is no active pleural inflammation or disease. The trapped lung is unable to expand commonly due to a thick visceral pleural peel, and the pleural fluid biochemistry will suggest transudative pathology. In lung entrapment, there is active pleural involvement by inflammation or malignancy. Pleural fluid is exudative in nature. The lung, in this case, has the potential to expand with the management of the underlying disease.[2,3,7] However, with progressive disease or as in the case of malignancy, lung entrapment may progress to trapped lung.

Now, to remove confusion, authors suggest using the term "unexpandable lung" to refer to both the above entities.[5] I agree with this concept, and this cannot be more clearly explained than to look at the example of the patient in Figure 1. This patient had active malignant infiltration of the pleura as portrayed by pleural fluid cytological examination. However, the terminal part of the pleural elastance curve demonstrated "trapped" physiology rather than "entrapment" physiology. This is usually the case when a patient has a malignant pleural effusion associated with an underlying lung malignant mass with some extent of endobronchial involvement or extrinsic bronchial compression leading to inability of the lung to expand. As this discussion deals with the use of pleural manometry predominantly in this patient group, the term "unexpandable lung" is preferable to describe the physiology of the underlying lung in these patients. In the patient with unexpandable lung, insertion of an ICD may do more harm to the patient [Figure 1]. In such patients, avoiding ICD placement would eventually lead to an increase in patients' visits for repeat therapeutic thoracentesis. This burden to the health-care services can be decreased by the use of pleural manometry as in the patients described in Figures 2 and 3. In both examples, the patients did not require repeat thoracentesis. However, this is not the rule, as in the example in Figure 1, where the effusion reaccumulated within 3 days.

With health-care costs directly borne by the patient in developing countries, investigations such as CT scan and bronchoscopy should only be considered if they are likely to provide diagnostic information for patient care. CT scan taken without adequate pleural drainage may not contribute any additional information compared to CXR [Figure 3a and b]. A simple drainage of 1 L may not suffice in such cases either [Figure 2a and b]. Pleural manometry can aid in the removal of large volume of pleural fluid before performing a CT scan and increase the likelihood of obtaining useful radiological information

from the CT scan. In patients with pleural fluid showing malignant cellularity, before performing thoracoscopy, we must ensure that in all probability, the lung will expand after the procedure as this will permit ICD removal and early discharge from the hospital. Pleural manometry can help determine if there is unexpandable lung. If the pleural pressures remain positive throughout, one can proceed to thoracoscopy without performing a bronchoscopy. This will avoid additional costs to the patient. On the contrary, if pleural pressures become negative during thoracentesis, there is in all likelihood unexpandable lung. A bronchoscopy should then be performed to look for endobronchial pathology. It must be stressed that the presence of unexpandable lung does not imply endobronchial pathology. A lung mass that causes extrinsic compression of a bronchus can also lead to unexpandable lung.

CT-guided biopsy of lung mass is generally preferred in the setting of coexisting large pleural effusions. Ultrasound-guided biopsy is an option in these patients as it will reduce costs as well as avoid exposure to ionizing radiation. However, the large effusion may make it difficult to gauge distance and accommodate respiratory variations. If there is coexisting unexpandable lung, insertion of ICD may result in a pneumothorax and make ultrasound redundant. There is a role for pleural manometry in such cases – large quantity of fluid can be removed, thus decreasing the depth of fluid interface lying in between the ultrasound probe and the lung mass thus permitting biopsy to be performed easily [Figure 4]. With the availability of point-of-care ultrasound, the utility of pleural manometry in such cases cannot be overemphasized.

Studies have looked at various patient outcomes when performing pleural manometry. The volume of pleural fluid drained did not correlate with patient symptoms such as chest pain and cough.[8] In the examples above, it can be seen that chest pain developed in all the patients described above albeit at different cumulative volume of fluid drained, and aspiration was stopped immediately. The development of chest pain, rather than cough, has been found to be associated with lower closing pleural pressures and should be considered an indicator to stop further thoracentesis.[8] Such chest pain can be very severe[5] and as in the patient described in Figure 1, and may be associated with dyspnea and hypoxemia leading to respiratory failure. Reexpansion pulmonary edema may have also contributed to the sudden worsening of respiratory status in this patient. Interestingly, a retrospective study did not find any significant difference in the number of patients who developed chest discomfort or dyspnea following therapeutic thoracentesis between the group that underwent the procedure with manometry and the group that underwent thoracentesis without manometry.[9]

The development of pneumothorax following thoracentesis [Figure 4] may indicate the presence of unexpandable lung, with the development of the pneumothorax due to excessive negative pleural pressures following thoracentesis (pneumothorax ex vacuo). However, such pneumothorax has been found to occur even in the absence of detectable excessively negative pleural pressure, hence questioning the role of pleural manometry in preventing pneumothorax postthoracentesis. In the patient described in Figure 4, when thoracentesis was done with pleural manometry, the pneumothorax did not recur. On the contrary, in the patient described in Figure 1, insertion of ICD did not lead to a pneumothorax. Rather, the mediastinum shifted to the affected side. In the same patient, though, there was a history of the development of pneumothorax after insertion of ICD a year ago. Variability in the development of pneumothorax ex vacuo between patients and within the same patient at different time intervals can probably be explained by the presence of pleuroparenchymal air leaks that open up when the lung contour adapts to the removal of the effusion.[10] Perhaps, it is the rapidity by which the effusion is drained that determines the development of such air leaks and subsequent pneumothoraces. Of note, pneumothorax ex vacuo rarely requires treatment, as in the patient described in Figure 4.[10]

Finally, with respect to the intended audience of this paper, it may be imperative to summarize on how one can perform pleural manometry in low-resource settings. Pleural pressure recording can be done during thoracentesis by connecting the aspiration catheter and attached syringe to an undamped U-manometer, an overdamped U-manometer (with the interposition of a resistor to restrict the respiratory swings in order to obtain more accurate recordings), or a digital handheld pleural manometer.[2,5] The overdamped water U-manometer is as accurate as the digital handheld pressure transducer devices.[2] There are no studies that have directly compared the accuracy of readings obtained between the undamped and overdamped water manometers. As such, in low-resource settings, especially when pleural manometry itself is being performed to avoid additional recurring costs of further investigations and procedures, one can perform the procedure with the relatively easier and less costlier undamped water U manometer. I perform pleural manometry in such clinical settings with (1) 16 G IV cannula catheter, (2) two 3-way adapters, (3) two 100 cm small bore infusion lines, (4) 20 ml syringe, (5) 100 cm inch tape taped to an IV stand, and (6) a drainage collection bottle. I identify the most dependent portion of the pleural effusion (usually one intercostal space above the diaphragm) as visualized by ultrasound. After local infiltration of puncture site with 2% lignocaine, the IV cannula is advanced till fluid is aspirated. Then, the needle is withdrawn and the catheter is fixed to the 20 ml syringe through two 3-way adapters fixed in series placed in between. The side ports of the 3-way adapters are connected to the infusion lines with one draining into the drainage collection bottle and the other preflushed with normal saline hanging down till 40 cm below the puncture site and then rising up (forming a "U") with the ascending

arm taped to the IV stand. The stopcocks of the adapters are rotated such that fluid is initially aspirated and drained into the drainage bottle. At fixed intervals (after every 100–200 ml of fluid drained during the 1st L and at 100 ml intervals after that), the stopcocks are rotated such that the manometer is in series with the aspiration catheter whereas the syringe as well as the draining infusion line are no longer in continuity. The pressure recording is taken when the meniscus steadies between two values consistently (5 s) following which the lower value is recorded.

CONCLUSION

Pleural manometry can be useful in the management of patients with malignant pleural effusion in low-resource settings. Proper patient selection and a thorough understanding of pleural physiology during pleural fluid thoracentesis are necessary before performing pleural manometry.

Financial support and sponsorship
Nil.

Conflicts of interest
There are no conflicts of interest.

REFERENCES

1. Bhatnagar R, Corcoran JP, Maldonado F, Feller-Kopman D, Janssen J, Astoul P, *et al*. Advanced medical interventions in pleural disease. Eur Respir Rev 2016;25:199-213.
2. Doelken P, Huggins JT, Pastis NJ, Sahn SA. Pleural manometry: Technique and clinical implications. Chest 2004;126:1764-9.
3. Huggins JT, Doelken P. Pleural manometry. Clin Chest Med 2006;27:229-40.
4. Huggins JT, Doelken P, Sahn SA. The unexpandable lung. F1000 Med Rep 2010;2:77.
5. Maldonado F, Feller-Kopman D. Should manometry be routinely used during thoracentesis? Yes, but not without some basic physiologic understanding! Expert Rev Respir Med 2016;10:1035-7.
6. Chawla RK, Madan A, Chawla A. Pleural manometry: Relevance in today's practice. Lung India 2016;33:468-70.
7. Huggins JT, Sahn SA, Heidecker J, Ravenel JG, Doelken P. Characteristics of trapped lung: Pleural fluid analysis, manometry, and air-contrast chest CT. Chest 2007;131:206-13.
8. Feller-Kopman D, Walkey A, Berkowitz D, Ernst A. The relationship of pleural pressure to symptom development during therapeutic thoracentesis. Chest 2006;129:1556-60.
9. Pannu J, DePew ZS, Mullon JJ, Daniels CE, Hagen CE, Maldonado F, *et al*. Impact of pleural manometry on the development of chest discomfort during thoracentesis: A symptom-based study. J Bronchology Interv Pulmonol 2014;21:306-13.
10. Heidecker J, Huggins JT, Sahn SA, Doelken P. Pathophysiology of pneumothorax following ultrasound-guided thoracentesis. Chest 2006;130:1173-84.