

Gossypiboma (retained surgical sponge) induces septic shock after previous breast surgery: A case report

SAGE Open Medical Case Reports
Volume 7: 1–3
© The Author(s) 2019
Article reuse guidelines:
sagepub.com/journals-permissions
DOI: 10.1177/2050313X19830474
journals.sagepub.com/home/sco



Pin-Keng Shih^{1,2,3} 

Abstract

Foreign body granuloma caused by retained surgical sponge is also called gossypiboma or textiloma, is mostly described in the abdominal cavity, with only a very few cases of retained surgical sponges located in breasts. A 48-year-old female came to our emergency department due to shortness of breath with consciousness disturbance. Sixteen years previously, she had gone through modified radical mastectomy. Eight years later, she received breast reconstruction. At emergency department, her hemodynamic status was unstable. Besides, there was one mass lesion with abscess in the right axillary region, and percutaneous abscess drainage was performed. She was sent to the medical intensive care unit for further care of septic shock. Because her symptoms and signs did not improve, we decided to perform fasciectomy and surprisingly found one retained surgical sponge in her breast. After the operation, she recovered well and the wound was stable. Due to limited literature available, we present a case of gossypiboma in the breast with a clinical manifestation of septic shock.

Keywords

Gossypiboma, retained surgical sponge

Date received: 29 August 2018; accepted: 22 January 2019

Introduction

Foreign body granuloma due to retained surgical sponge is also called gossypiboma or textiloma. The condition is usually in the field of thoracic or abdominal surgery.¹ Reports on superficial sites, such as the extremities, the neck or as in our case, the breasts, are extremely rare. To our knowledge, only two cases of breast gossypiboma have been reported including the description of the mammographic and sonographic appearance.² Gossypiboma usually presents as a palpable mass in the breast, but we encountered a physically non-detectable gossypiboma in the breast and the patient had a clinical manifestation of septic shock.

Case report

The 48-year-old woman came to our emergency department (ED) because of shortness of breath associated with consciousness disturbance. Sixteen years ago, she had undergone modified radical mastectomy (MRM), chemotherapy, and radiotherapy due to right breast cancer. Eight years later, she received breast reconstruction. Before she came to ED, she had had a motorcycle accident and hurt her right arm

3 days previously. At home, she had experienced dizziness, cold sweating, and shortness of breath. Also, she complained about worsening of right anterior chest pain. At ED, her consciousness was disturbed and her initial vital signs were measured as follows: blood pressure: 74/46 mmHg, heart rate: 72/min, respiratory rate: 22/min, and body temperature: 36.7°. Her laboratory data were reported as follows: white blood cell count: 17,100/ μ L and percentage of neutrophilic segments: 92.6%, and blood gas: pH: 7.41, pCO₂: 38 mmHg, pO₂: 62 mmHg, and HCO₃⁻: 24.1 mmol/L. Abdomen- and chest-computed tomography (CT) showed a 57 mm mass lesion with abscess in the right axillary region (Figure 1), and percutaneous abscess drainage (PAD) was

¹Division of Plastic & Reconstructive Surgery, China Medical University Hospital

²China Medical University, Taichung

³Department of Cosmetics and Health Care, Chung-Jen Junior College of Nursing, Health Sciences and Management

Corresponding Author:

Pin-Keng Shih, Division of Plastic & Reconstructive Surgery, China Medical University Hospital, 2 Yuh Der Road, Taichung City, 404.

Email: pinking.shih@gmail.com



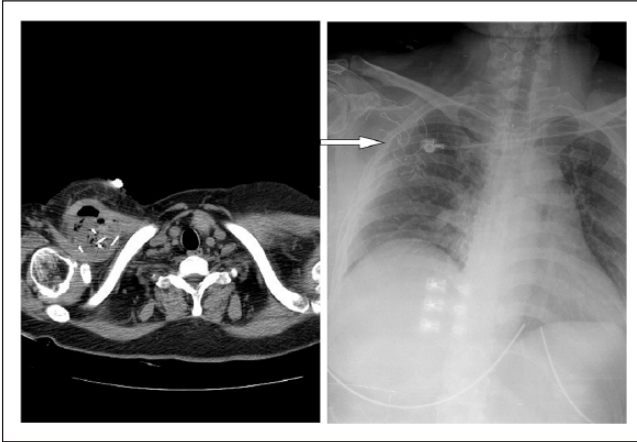


Figure 1. CT (left picture) showed a mass lesion with abscess in the right axillary region, and this was compared with plain radiograph. An incorporated radiopaque marker could be found (right picture, arrow).

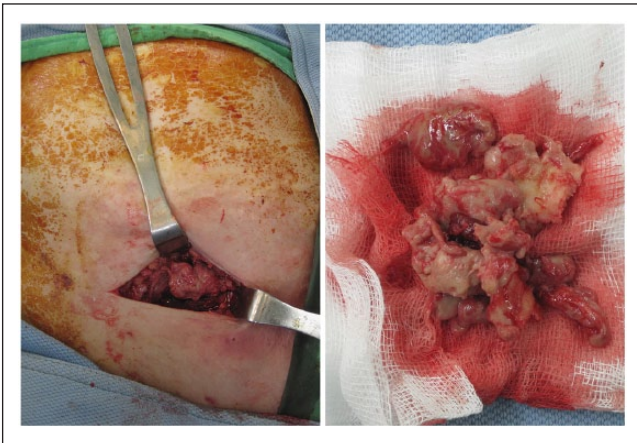


Figure 2. Left picture: foreign body granuloma-like retained surgical sponge was noted in the operation. Right picture: Gauze removed from the wound.

performed at ED. Because of the low blood pressure, the diagnosis of septic shock was considered. After resuscitation, she was sent to the medical intensive care unit (MICU) for further care. While there, she still had a fever. The report of bacterial culture and PAD culture was oxacillin-sensitive *Staphylococcus aureus* (OSSA). Oxacillin was used, and PAD was still turbid. In the upper-outer quadrant of her right breast was seen redness and swelling. Nine days later, we were consulted and then performed the fasciectomy and debridement for her right breast. We found a subcutaneous abscess over the right chest wall near the axillary, and a large amount of pus with granulation tissue material and a foreign body was suspected (Figure 2). After the operation, the wound received daily wet dressing for 14 days. When her wound had improved, we performed debridement and local flap for the defect reconstruction. Postoperative course

was uneventful. After a 2-month follow-up, the appearance was acceptable.

Discussion

The retention of a postoperative foreign body, of which surgical sponges are the most common, is a rare condition. A foreign body granuloma caused by a retained surgical sponge is called a gossypiboma, cottonballoma, textiloma, or gauzeoma. This condition is often in the field of thoracic or abdominal surgery. Reports on superficial sites such as the extremities, the neck or as is in our case, the breast, is extremely rare. To our knowledge, only two cases of gossypiboma of the breast have been reported.²

The clinical presentation of gossypiboma is variable and depends on the location of the sponge and the time elapsed between operation and detection. Symptoms may appear in the postoperative period or even after weeks, months, or years. Common symptoms and signs of gossypiboma are pain, a palpable mass, abscess formation, and fistula formation.³ In our case, the symptoms were septic shock.

Two types of foreign body reactions occur in patients with retained sponges. The first type is an inflammatory reaction with the formation of an abscess that usually leads to early detection. The second type is an aseptic reaction to cotton material and development of a granuloma, which can lead to long asymptomatic periods.⁴

The diagnosis of gossypiboma is difficult to make definitively because the clinical symptoms are nonspecific and the imaging findings are often inconclusive. Plain radiographs suggest the diagnosis if the surgical sponge is calcified or when a characteristic “whorl-like” pattern is present. Ultrasonography (US) images can be classified into two groups: solid and cystic. The most frequently described image is an echogenic area with an intense, sharply delineated posterior acoustic shadow due to the highly reflective fiber texture of the surgical sponge. A less frequent finding is a well-delineated cystic mass with a hyperechoic spongiform internal structure.⁵ CT may show air trapped between surgical sponge fibers, or calcification of cavity walls and contrast-enhanced rims, which may not be distinguishable from other tumors or abscesses.⁶ Magnetic resonance imaging (MRI) is not recommended because the radiopaque markers on surgical gauze are not magnetic or paramagnetic and are therefore not visible.

In our case, the patient underwent previous breast surgery and a surgical sponge was retained at that time. This retained sponge created an aseptic reaction causing adhesion and encapsulation, as well as granuloma formation, which led to a long asymptomatic period. Eight years later, she was involved in a traffic accident and had right chest contusion. This attack caused the aseptic encapsulation of granuloma of the right axillary region rupture and become inflamed. Cytokines were released from neighboring cells and drew large numbers of white blood cells to the area. Pus formed

due to the infectious process; therefore, she presented a clinical manifestation of septic shock.

A local abscess with infection was first suspected based on the patient's symptoms. PAD was performed for treatment. As the patient's condition did not improve, a gossypiboma would have been considered subsequently when we reviewed her radiograph and CT. A characteristic radiopaque marker of a "whorl-like" pattern was seen from the patient's plain radiograph and CT. Besides, CT also showed air trapped between surgical sponge fibers.

Conclusion

Gossypibomas are uncommon, mostly asymptomatic, and difficult to diagnose. Gossypiboma should be included in the differential diagnosis of a mass in the breast and in patients with previous history of breast surgery. Besides, systemic symptoms like septic shock may occur. More importantly, when abnormal findings are noted on previous radiographs, more attention should be drawn to the phenomenon to assist the interpretation.

Declaration of conflicting interests

The author(s) declared no potential conflicts of interest with respect to the research, authorship, and/or publication of this article.

Ethical approval

Our institution does not require ethical approval for reporting individual cases or case series.

Funding

The author(s) received no financial support for the research, authorship, and/or publication of this article.

Informed consent

The patient described herein had given consent to the use of de-identified patient data for use in research and education.

ORCID iD

Pin-Keng Shih  <https://orcid.org/0000-0003-2385-2065>

References

1. Cima RR, Kollengode A, Garnatz J, et al. Incidence and characteristics of potential and actual retained foreign object events in surgical patients. *J Am Coll Surg* 2008; 207: 80–87.
2. El Khoury M, Mignon F, Tardivon A, et al. Retained surgical sponge or gossypiboma of the breast. *Eur J Radiol* 2002; 42: 58–61.
3. McIntyre LK, Jurkovich GJ, Gunn ML, et al. Gossypiboma: tales of lost sponges and lessons learned. *Arch Surg* 2010; 145: 770–775.
4. Zantvoord Y, van der Weiden RM and van Hooff MH. Transmural migration of retained surgical sponges: a systematic review. *Obstet Gynecol Surv* 2008; 63: 465–471.
5. Yamato M, Ido K, Izutsu M, et al. CT and ultrasound findings of surgically retained sponges and towels. *J Comput Assist Tomogr* 1987; 11: 1003–1006.
6. Liessi G, Semisa M, Sandini F, et al. Retained surgical gauzes: acute and chronic CT and US findings. *Eur J Radiol* 1989; 9: 182–186.