

# Prenatal sonographic characteristics and postnatal outcomes of umbilical-portal-systemic venous shunts under the new in-utero classification

## A retrospective study

Haifang Wu, MD<sup>a</sup>, Guowei Tao, MD<sup>a,\*</sup>, Xiang Cong, MD<sup>a</sup>, Qi Li, MD<sup>a,b</sup>, Jing Zhang, MD<sup>a,b</sup>, Zhe Ma, MD<sup>a</sup>, Zhonglu Zhang, MD<sup>c</sup>

### Abstract

An in-utero re-classification of umbilical-portal-systemic venous shunt (UPSVS) has recently been proposed. We retrospectively reviewed the sonograms of a large cohort of fetuses, identified and analyzed UPSVS cases, and presented the prenatal sonographic characteristics, birth outcomes, and follow-up results following the new classification system.

Sonograms and clinical data of all participants who visited our departments from April 2016 to July 2018 were retrospectively reviewed. Identified cases of UPSVS were analyzed according to the new classification: Type I: umbilical-systemic shunt (USS); Type II: ductus venosus-systemic shunt (DVSS); Type IIIa: intrahepatic portal-systemic shunt (IHPSS) and Type IIIb: extrahepatic portal-systemic shunt (EHPSS). Postnatal follow-ups ranged from 3 months to 1 year.

A total of 10 UPSVS cases were identified in 61,082 fetuses: 4 with Type I, 3 with Type II and 3 with Type IIIa. All 4 cases of USS had complete agenesis of the portal venous system, and had the umbilical vein drained into the inferior vena cava. Two USS cases also had trisomy 21. Pregnancy was terminated in all cases with a Type I shunt. Two fetuses with DVSS had normal portal venous system and were born full term. The pregnancy of 1 DVSS case was terminated due to the detection of trisomy 21. Three cases were IHPSS with full-term birth. One had chromosomal abnormality and 1 had surgery to repair the shunt 12-days post birth. In the 2 cases that did not receive repair surgery, sonographic examination revealed the portal-hepatic venous shunt was not closed at the 6-month follow-up period. However, the 1 case that had repair surgery appeared healthy at the 3-month follow-up period.

UPSVS is extremely rare. Type I shunts have the poorest prognosis, and the presence of the intrahepatic portal venous system is key to live birth in UPSVS regardless of types. Chromosomal abnormalities and other organ anomalies can occur in any types of UPSVS. Therefore, karyotyping and examination of other organs should be performed once UPSVS is detected.

**Abbreviations:** DV = ductus venosus, DVSS = ductus venosus-systemic shunt, EHPSS = extrahepatic portal-systemic shunt, IHPSS = intrahepatic portal-systemic shunt, IVC = inferior vena cava, PV = portal vein, UPSVS = umbilical-portal-systemic venous shunt, USS = umbilical-systemic shunt, UV = umbilical vein.

**Keywords:** chromosome abnormality, prenatal, ultrasonography examination, umbilical-portal-systemic venous shunt

Editor: Milan Perovic.

This study was supported by the Provincial Key Research and Development Fund of Shandong Province, China (Grant #: 2015GSF118081 and 2016GSF201141).

The authors have no conflict of interest to declare.

<sup>a</sup> Department of Ultrasound, Qilu Hospital of Shandong University, Jinan,

<sup>b</sup> Medical School of Shandong University, Jinan, <sup>c</sup> Department of Ultrasound, the Affiliated Hospital of Jining Medical University, Jining, Shandong Province, China.

\* Correspondence: Guowei Tao, Department of Ultrasound, Qilu Hospital of Shandong University, 107 Wenhua West Road, Jinan 250012, China (e-mail: taoguowei@yahoo.com).

Copyright © 2019 the Author(s). Published by Wolters Kluwer Health, Inc.

This is an open access article distributed under the terms of the Creative Commons Attribution-Non Commercial-No Derivatives License 4.0 (CCBY-NC-ND), where it is permissible to download and share the work provided it is properly cited. The work cannot be changed in any way or used commercially without permission from the journal.

Medicine (2019) 98:2(e14125)

Received: 11 May 2018 / Received in final form: 29 November 2018 / Accepted: 20 December 2018

<http://dx.doi.org/10.1097/MD.00000000000014125>

## 1. Introduction

The abnormal course of the umbilical vein (UV), and the absence and displacement of the portal vein (PV) or the ductus venosus (DV) in the fetus can cause shunting into the systemic veins.<sup>[1]</sup> This rare anomaly has recently been re-classified under the term ‘umbilical-portal-systemic venous shunts’ (UPSVS).<sup>[2]</sup> Based on the anatomical origin of the shunt (umbilical, portal, or ductal), UPSVS is classified into 3 types: Type I, umbilical-systemic shunt (USS); Type II, ductus venosus-systemic shunt (DVSS); and Type III, portal-systemic shunt which is further divided into 2 subtypes: Type IIIa, intrahepatic portal-systemic shunt (IHPSS) and Type IIIb, extrahepatic portal-systemic shunt (EHPSS).<sup>[2]</sup> Distinct from previously used postnatal dichotomous classification, that is, intra- and extrahepatic shunts,<sup>[3–8]</sup> the new classification takes into account the unique anatomy of the fetus, that is, the umbilical, portal and DV form a functionally inseparable system, in which each component (UV, PV, or DV) can produce a shunt with systemic veins. Therefore, the new classification system is believed to be more suitable for prenatal analysis of the clinical and prognostic characteristics of UPSVS.<sup>[2]</sup> According to the new

**Table 1****Characteristics, birth outcomes and follow-up results of all cases of UPSVS.**

Case	GA	UPSVS	DV	Other abnormalities	Karyotyping	Outcomes	FU
1	28w	Type I	—	Bilateral CPC	trisomy 21	PT	NA
2	28w	Type I	—	Multiple IHC and increased CTR	ND	PT	NA
3	22w	Type I	—	VSD and nasal bone agenesis	trisomy 21	PT	NA
4	25w	Type I	—	None	ND	PT	NA
5	30w	Type II	+	None	ND	FTB	Healthy at 1-year FU
6	33w	Type II	+	PLSVC	ND	C-section at 37w	Healthy at 4-month FU
7	18w	Type II	+	nasal bone agenesis	trisomy 21	PT	NA
8	36w	Type IIIa	—	None	ND	FTB	Shunt not closed at 6-month FU
9	32w	Type IIIa	—	increased CTR	46, XY, inv (9) (p12q13)	FTB	Shunt not closed at 6-month FU
10	28w	Type IIIa	+	None	ND	FTB	Healthy at 3-month FU

Follow-up ultrasound examination was declined in cases 5 and 6. CPC=choroid plexus cysts, CTR=cardiothoracic ratio, DV=ductus venosus, FTB=full-term birth, FU=follow-up, GA=gestational age (weeks) at diagnosis, IHC=intrahepatic calcifications, NA=not applicable, ND=not determined, PLSVC=persistent left superior vena cava, PT=pregnancy terminated, UPSVS=umbilical-portal-systemic venous shunt, VSD=ventricular septal defect.

classification, the absence of a normal DV does not stand alone as a pathology,<sup>[2]</sup> although a number of studies have described prenatal diagnosis of DV agenesis.<sup>[9–16]</sup>

To date, there has been scarce documentation about prenatal diagnosis of UPSVS, warranting further studies to expand our knowledge to improve perinatal outcome prediction and management.<sup>[1,2]</sup> There are few case reports that have focused on the prenatal analysis of UPSVS but have used the postnatal dichotomous classification.<sup>[17,18]</sup> Since its establishment, the new classification has not been applied to the prenatal analysis of UPSVS. Here, we retrospectively analyzed UPSVS cases identified from a large cohort of fetuses (>60,000) and presented the prenatal sonographic characteristics, birth outcomes, and follow-up results of UPSVS following the new classification system.

## 2. Methods

This study was approved by the Research Ethics Committee of Qilu Hospital of Shandong University, and the Medical Research Ethics Committee of the Affiliated Hospital of Jining Medical University with the waiver of the requirement for obtaining informed consent due to the nature of the retrospective study. Fetal sonograms taken from April 2016 to July 2018 at the Department of Ultrasound, Qilu Hospital of Shandong University and the Department of Ultrasound, the Affiliated Hospital of Jining Medical University were retrospectively reviewed. Additionally, clinical data and follow-up results of those with UPSVS were analyzed.

Pregnant women undergoing regular ultrasound monitoring received the standard 2D procedure using the Philips iU22 ultrasound system with a 3.5 to 5.0 MHz transducer. This included transabdominal scanning to examine the fetus, the placenta and amniotic fluid, and sagittal scanning to visualize the ductus venosus. In the case of suspected anomaly, a further 3-plane scan of the fetal venous system was carried out as described by Yagel et al<sup>[19]</sup>:

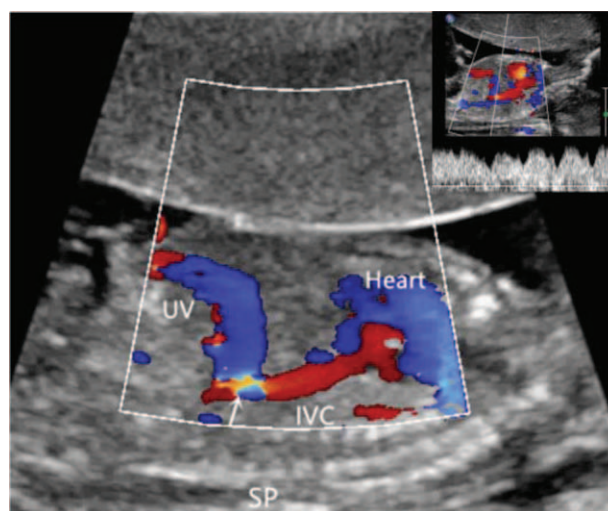
1. a transverse abdominal plane scan was done at the level of left portal sinus to examine the umbilical vein (UV), left portal vein, portal sinus, anterior right portal vein, posterior right portal vein, main portal vein, and splenic vein and artery;
2. moving the transducer cephalad, a ventral or lateral transverse plane was used to image the right, middle and left hepatic veins and inferior vena cava (IVC);

3. longitudinal anteroposterior plane scanning was performed to image the UV, ductus venosus, IVC and left hepatic vein. Pulsed-wave Doppler imaging of a given target vessel was performed in all cases of UPSVS. Postnatal follow-ups were conducted up to 1 year.

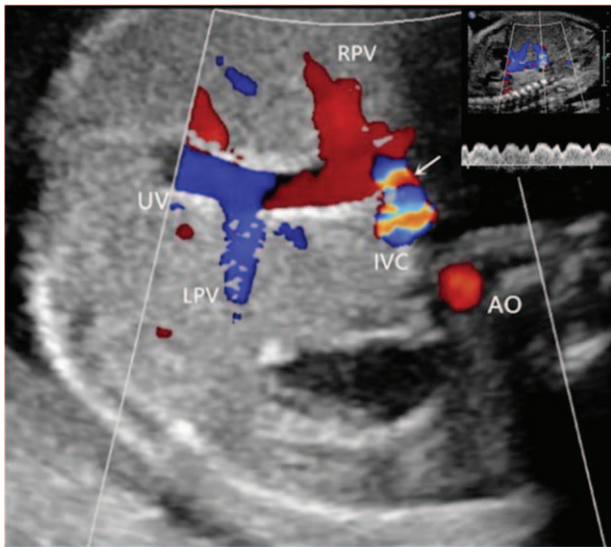
## 3. Results

A total of 61,082 fetal sonograms were retrospectively reviewed. Ten cases of UPSVS were identified, which included 4 cases of USS (cases 1–4); 3 cases of DVSS (case 5–7) and 3 cases of IHPSS (cases 8–10). Cases 8 and 9 were referred to our department for a suspected UPSVS. Post-birth follow-ups ranged from 3 to 12 months. Characteristics and outcomes of all cases are shown in Table 1.

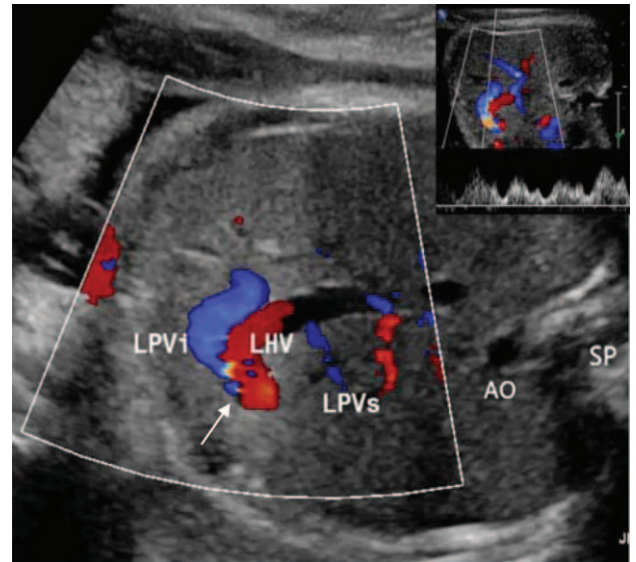
The UV was found to drain into the IVC in all Type I UPSVS cases, and there was complete absence of DV and intrahepatic portal venous system, shown in the sonogram of case 2 in Figure 1. Two cases of USS had trisomy 21. Displacement of the



**Figure 1.** A representative sonogram of case 2. Shown here is a sagittal scan of the Type I shunt. The UV was seen to connect the IVC, and triphasic waveforms at the site of shunt were detected (inserted at the right-upper corner). Arrow indicates the shunt site. IVC=inferior vena cava, SP=spine, UV=umbilical vein.



**Figure 2.** A representative sonogram of case 5. Shown here is a transverse scan to demonstrate the Type 2 shunt. The structure of UV, portal veins (LPV and RPV) and the DV (arrow) appeared intact with the DV draining into the hepatic segment of the IVC. DV type velocity waveforms were detected at the shunt site (inserted at the right-upper corner). AO=aorta, IVC=inferior vena cava, LPV=left portal vein, RPV=right portal vein, UV=umbilical vein.



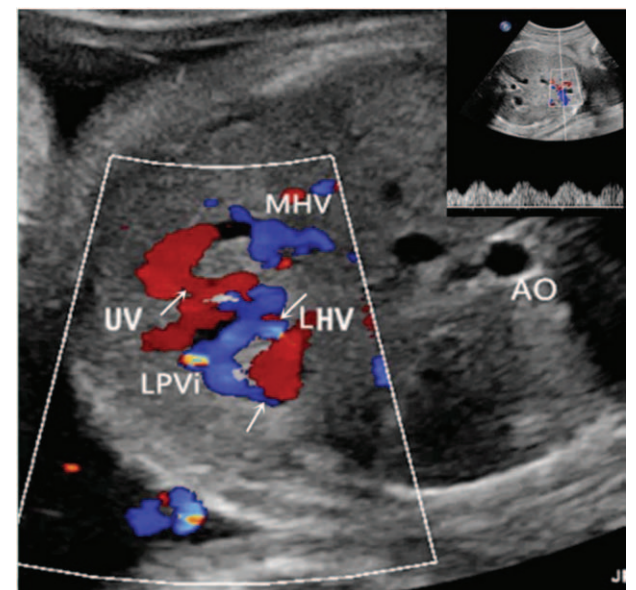
**Figure 3.** A representative sonogram of case 8. A transverse scan shows a shunt (arrow) between the LPV1 and LHV. LHV was enlarged and triphasic waveforms were detected at the shunt site (inserted at the right-upper corner). AO=aorta, LHV=the left hepatic vein, LPV1=inferior branch of the left portal vein, LPVs=superior branch of the left portal vein, SP=spine.

splenic vein and the superior mesenteric vein were detected in cases 1 and 2, respectively, which resulted in drainage into the UV. Pulsed-wave Doppler examinations showed triphasic waveforms at the shunt site in all 4 cases of USS (Fig. 1, inserted). Pregnancy was terminated in all Type I shunt cases.

In the new classification system, the Type II shunt is defined as a short DV connecting to the IVC below the pre-diaphragmatic infundibulum or a short DV draining into the hepatic vein with an intact UV-PV-DV structure.<sup>[2]</sup> In case 5, the UV, PV, and DV were seen; however, the DV was found to connect to the hepatic fragment of the IVC (Fig. 2), and DV type velocity waveforms were detected at the shunt site (Fig. 2, inserted). The PV and its branches were visible and appeared normal, indicating an intact intrahepatic portal venous system (images not shown). Full-term birth took place in case 5 and no abnormalities up to 1-year postnatal follow-up were observed. Case 6 had persistent left superior vena cava and C-section was performed at 37 weeks; the infant was healthy at 4-month follow-up. Ultrasound examination was declined in cases 5 and 6 during follow-ups. One case of DVSS had trisomy 21 and the pregnancy was terminated as requested by the family (Table 1).

A shunt between the inferior branch of the left portal vein and the left hepatic vein was detected in Case 8 (Fig. 3). Additionally, turbulent blood flow and an enlarged left hepatic vein were detected at the shunt site (Fig. 3). The baby was born full term with hypoglycemia that disappeared 1 month after birth. Case 9 had multiple left/middle hepatic/portal vein shunts (Fig. 4) with a karyotype of 46, XY, inv (9) (p12q13); the baby was born full term with jaundice and abnormal liver function. The baby was hospitalized for 1 month and recovered. Typical triphasic waveforms were detected at the shunt site of the left portal vein of cases 8 and 9 (Figs. 3 and 4, inserted, respectively). Case 10 had a shunt between the inferior branch of the left portal vein and middle hepatic vein, the baby was born full term and surgery was performed 12-days post birth to repair the shunt. Intrauterine

growth restriction was observed in all cases of Type IIIa UPSVS. The portal-hepatic venous shunt in cases 8 and 9 was not closed at the 6-month follow-up as shown by sonography examination. The 3-month follow-up of case 10 showed that the infant was healthy.



**Figure 4.** A representative sonogram of case 9. A transverse scan shows multiple shunts (arrows) between the left portal vein and the left hepatic vein/middle hepatic vein. Triphasic waveforms were detected at the shunt site (inserted at the right-upper corner). AO=aorta, LHV=the left hepatic vein, LPV1=inferior branch of the left portal vein, MHV=middle hepatic vein, UV=umbilical vein.

#### 4. Discussion

Prenatal studies of UPSVS in large series have rarely been reported, and the prevalence of fetal UPSVS remains unknown. We identified 10 cases of UPSVS in 61,082 fetuses, representing a prevalence rate of 1.64 per 10,000 fetuses. Considering that cases 8 and 9 were referred to our department, the UPSVS prevalence could be even lower. Ono et al screened 293,416 neonates and found that 8 had intrahepatic portal-systemic shunts and 3 extrahepatic portal-systemic shunts.<sup>[20]</sup> This postnatal finding, together with our results, suggest that UPSVS is rare.

Following the new classification, we discovered that fetuses with Type I shunts had the poorest prognosis, that is, pregnancy termination in all 4 cases. The worst outcome for USS, that is, lowest rates of live birth and postnatal survival, was also observed in a previous study.<sup>[21]</sup> In all Type I cases we examined, complete absence of intrahepatic portal venous system was noted, which is the determining factor for the termination of pregnancy. Additionally, we found that 2 Type I, 1 Type II and 1 Type IIIa UPSVS cases had abnormal karyotypes (Table 1). Volpe et al also revealed chromosomal abnormality (1/3) in Type I shunts (UV connection to the iliac vein).<sup>[21]</sup> In contrast, Achiron and Kivilevitch revealed no chromosomal abnormalities in Type I (0/7) or Type III (0/16) shunts, but in Type 2 shunts (4/19).<sup>[21]</sup> Weissmann–Brenner and Zalel karyotyped 5 of 6 fetuses with UV drainage into the IVC and reported that 4 had chromosomal abnormalities, including trisomy 21, trisomy 13, etc.<sup>[22]</sup> These authors did not provide information about the PV and hepatic veins, but reported DV agenesis in all 5 cases, indicating the shunts are not Type II. Chromosomal abnormalities in DV agenesis (non-Type II) cases were reported at a prevalence of 20.2% (24/119).<sup>[15]</sup> Taken together, we concluded that chromosomal abnormalities could occur in any of the 3 types of shunts. We also observed choroid plexus cysts in case 1, cardiomegaly in case 2, and ventricular septal defect and nasal bone agenesis in case 3. These results are in agreement with previous reports showing that USS is associated with a high occurrence of other organ anomalies.<sup>[2,21]</sup>

Case 5 had a satisfying outcome, mainly due to the presence of the intrahepatic portal venous system. A high incidence of chromosomal abnormalities among Type II shunts was reported.<sup>[2]</sup> We found 1 case of Type II with trisomy 21 (case 7). It has been shown that fetuses with IHPSS have the highest rate of live birth compared with those with other types of shunts.<sup>[21]</sup> In our series, full-term birth took place in all cases of IHPSS. A common postnatal problem associated with IHPSS is the abnormal liver function<sup>[21]</sup> that was observed in case 9. Han et al conducted a follow-up study of 6 neonates with intrahepatic portosystemic venous shunts and found 5 who spontaneously closed at approximately 1 year.<sup>[23]</sup> Cases 8 and 9 did not display shunt closure at 6 months post birth, probably due to the short follow-up time. No EHPSS cases were identified in this study. Of note, the presence of intrahepatic portal venous system in EHPSS is of paramount importance for the best outcome.<sup>[2]</sup> UPSVS is rare, and from over 60,000 sonograms, we only identified 10 cases of UPSVS. This small sample size is a limitation of this study. Nevertheless, the information gathered from these cases under the new classification of UPSVS is valuable, for example, chromosomal abnormalities, and other organ anomalies were observed in all 3 types of UPSVS, which can be used to predict fetal outcomes and direct perinatal management.

#### 5. Conclusion

UPSVS is extremely rare. Fetuses with Type I shunts have the poorest prognosis and the presence of the intrahepatic portal venous system is key to live birth regardless of UPSVS types. Chromosomal abnormalities and other organ anomalies can occur in any types of UPSVS. Therefore, karyotyping and examinations of other organs should be performed once UPSVS is detected. To our knowledge, this is the first study to apply the new UPSVS classification, since its establishment, to investigate the clinical and prognostic characteristics of UPSVS. Our results suggest prenatal analysis with the new classification system is helpful in predicting the fetal outcomes and directing perinatal management.

#### Acknowledgment

We sincerely thank Mr. Anthony Cannavici from the University of Toronto for help in English editing.

#### Author contributions

**Conceptualization:** Guowei Tao.

**Data curation:** Haifang Wu and Zhonglu Zhang.

**Formal analysis:** Haifang Wu and Zhonglu Zhang.

**Funding acquisition:** Guowei Tao and Zhe Ma.

**Investigation:** Haifang Wu, Guowei Tao, Qi Li, and Zhonglu Zhang.

**Methodology:** Guowei Tao.

**Project administration:** Zhe Ma.

**Software:** Qi Li.

**Supervision:** Xiang Cong and Jing Zhang.

**Validation:** Xiang Cong.

**Visualization:** Haifang Wu, Guowei Tao, Jing Zhang, and Zhonglu Zhang.

**Writing – original draft:** Haifang Wu.

**Writing – review & editing:** Guowei Tao.

#### References

- Yagel S, Kivilevitch Z, Cohen SM, et al. The fetal venous system, Part II: ultrasound evaluation of the fetus with congenital venous system malformation or developing circulatory compromise. *Ultrasound Obstet Gynecol* 2010;36:93–111.
- Achiron R, Kivilevitch Z. Fetal umbilical-portal-systemic venous shunt: in-utero classification and clinical significance. *Ultrasound Obstet Gynecol* 2016;47:739–47.
- Sokollik C, Bandsama RHJ, Gana JC, et al. Congenital portosystemic shunt: characterization of a multisystem disease. *J Pediatr Gastroenterol Nutr* 2013;56:675–81.
- Bernard O, Franchi-Abella S, Branchereau S, et al. Congenital portosystemic shunts in children: recognition, evaluation and management. *Semin Liver Dis* 2012;32:273–87.
- Lautz TB, Tantemsapya N, Rowell E, et al. Management and classification of type II congenital portosystemic shunts. *J Pediatr Surg* 2011;46:308–14.
- Franchi-Abella S, Branchereau S, Lambert V, et al. Complications of portosystemic shunts in children: therapeutic options and outcomes. *J Pediatr Gastroenterol Nutr* 2010;51:322–30.
- Stringer MD. The clinical anatomy of congenital portosystemic venous shunts. *Clin Anat* 2008;21:147–57.
- Sokollik C, Bandsma RH, Gana JC, et al. Congenital portosystemic shunt: characterization of a multisystem disease. *J Pediatr Gastroenterol Nutr* 2013;56:675–81.
- Hofstaetter C, Plath H, Hansmann M. Prenatal diagnosis of abnormalities of the fetal venous system. *Ultrasound Obstet Gynecol* 2000;15:231–41.
- Jaeggi ET, Fouron JC, Hornberger LK, et al. Agenesis of the ductus venosus that is associated with extrahepatic umbilical vein drainage:

- prenatal features and clinical outcome. *Am J Obstet Gynecol* 2002;187:1031–7.
- [11] Perles Z, Nir A, Nadjari M, et al. Absent ductus venosus in the fetus: review of the literature and first report of direct umbilical venous drainage to the coronary sinus. *Fetal Diagn Ther* 2003;18:247–51.
- [12] Berg C, Kamil D, Geipel A, et al. Absence of ductus venosus-importance of umbilical venous drainage site. *Ultrasound Obstet Gynecol* 2006;28:275–81.
- [13] Acherman RJ, Evans WN, Galindo A, et al. Diagnosis of absent ductus venosus in a population referred for fetal echocardiography: association with a persistent portosystemic shunt requiring postnatal device occlusion. *J Ultrasound Med* 2007;26:1077–82.
- [14] Shen O, Valsky DV, Messing B, et al. Shunt diameter in agenesis of the ductus venosus with extrahepatic portosystemic shunt impacts on prognosis. *Ultrasound Obstet Gynecol* 2011;37:184–90.
- [15] Strizek B, Zamprakou A, Gottschalk I, et al. Prenatal diagnosis of agenesis of ductus venosus: a retrospective study of anatomic variants, associated anomalies and impact on postnatal outcome. *Ultraschall Med* 2017;doi: 10.1055/s-0043-115109.
- [16] Thomas JT, Petersen S, Cincotta R, et al. Absent ductus venosus-outcomes and implications from a tertiary centre. *Prenat Diagn* 2012;32:686–91.
- [17] Gorincour G, Droulle P, Guibaud L. Prenatal diagnosis of umbilico-portosystemic shunts: report of 11 cases and review of the literature. *AJR Am J Roentgenol* 2005;184:163–8.
- [18] Delle Chiaie L, Neuberger P, Von Kalle T. Congenital intrahepatic portosystemic shunt: prenatal diagnosis and possible influence on fetal growth. *Ultrasound Obstet Gynecol* 2008;32:233–5.
- [19] Yagel S, Cohen SM, Valsky DV, et al. Systematic examination of the fetal abdominal precordial veins: a cohort study. *Ultrasound Obstet Gynecol* 2015;45:578–83.
- [20] Ono H, Mawatari H, Mizoguchi N, et al. Clinical features and outcome of eight infants with intrahepatic porto-venous shunts detected in neonatal screening for galactosaemia. *Acta Paediatr* 1998;87:631–4.
- [21] Volpe P, Marasini M, Caruso G, et al. Prenatal diagnosis of ductus venosus agenesis and its association with cytogenetic/congenital anomalies. *Prenat Diagn* 2002;22:995–1000.
- [22] Weissmann-Brenner A, Zalel Y. Umbilical vein insertion into the inferior vena cava: an ominous sign of chromosomal abnormalities? *J Ultrasound Med* 2014;33:2207–10.
- [23] Han BH, Park SB, Song MJ, et al. Congenital portosystemic shunts: prenatal manifestations with postnatal confirmation and follow-up. *J Ultrasound Med* 2013;32:45–52.