

Abnormal vortex formation in the right pulmonary artery after the arterial switch operation

Evangeline G. Warmerdam ^{1*}, Hans C. van Assen ², Julio Sotelo ^{3,4,5}, and Heynric B. Grotenhuis¹

¹University Medical Center Utrecht, Heidelberglaan 100, 3584 CX Utrecht, the Netherlands; ²Leiden University Medical Center, Albinusdreef 2, 2333 ZA Leiden, the Netherlands; ³School of Biomedical Engineering, Universidad de Valparaíso, Av. Gran Bretaña 1091, Valparaíso, Chile; ⁴Biomedical Imaging Center, Pontificia Universidad Católica de Chile, Av Libertador Bernardo O'Higgins 340 Santiago, Chile; and ⁵Millennium Nucleus for Cardiovascular Magnetic Resonance, Campus San Joaquín, Vicuña Mackenna 4860, Santiago, Chile

Received 3 November 2020; first decision 24 November 2020; accepted 8 December 2020

Transposition of the great arteries (TGAs) is a common cyanotic congenital heart defect, accounting for 5–8% of all congenital heart defects.¹ Currently, the arterial switch operation (ASO) combined with the LeCompte manoeuvre is the most used surgical procedure to correct TGA. Although pulmonary artery (PA) stenosis is the most common late complication after ASO,² flow disturbances such as vortex formation can also be observed in patients without obvious PA stenosis. Energy loss (EL) may then be a good marker of an inefficient circulation.

We present a 20-year-old male with TGA who underwent an ASO and ventricular septal defect closure at the age of 7 days. The patient had no complaints and underwent echocardiography, cardiac magnetic resonance (CMR), and exercise testing for research purposes. Echocardiography showed diastolic flattening of the intraventricular septum, indicative of mild right ventricular pressure overload. Pulmonary arteries could not be visualized. The exercise test revealed a decreased exercise capacity with a VO_2/kg at 75% of predicted. Cardiac magnetic resonance showed preserved biventricular function, normal flow distribution between the branch PAs, and a right PA diameter of 27×16 mm. Four-dimensional flow CMR revealed a significant vortex flow in the right PA (Figure 1). To assess haemodynamic impact of this flow disturbance, peak-systolic EL was calculated and visualized (Figure 2) for the PAs. Energy loss in the right PA at peak-systole was

4.33 mW—38% of total EL measured in the PAs—which may be associated with the reduced exercise capacity of this TGA patient.

This case highlights the value of four-dimensional flow CMR, allowing for visualization of flow and quantification of haemodynamic parameters in the cardiovascular system. Since TGA patients require life-long follow-up, a non-invasive imaging modality that allows for improved understanding of the often complex haemodynamics in these patients may prove of important value.

Consent: The authors confirm that written consent for submission and publication of this case report including images and associated text has been obtained from the patient in line with COPE guidance.

Conflict of interest: none declared.

Funding: this work was supported by Stichting Hartekind [grant number 3570].

References

1. Brickner ME, Hillis LD, Lange RA. Congenital heart disease in adults. Second of two parts. *N Engl J Med* 2000;**342**:334–342.
2. Ruys TPE, Van der Bosch AE, Cuyper JAAE, Witsenburg M, Helbing WA, Bogers AJJC et al. Long term outcome and quality of life after arterial switch operation: a prospective study with a historical comparison. *Congenit Heart Dis* 2013;**8**: 203–210.

* Corresponding author. Tel: +31-(0) 88-7574327, Fax: +31-(0)88-7574328, Email: e.g.warmerdam@umcutrecht.nl

Handling Editor: Konstantinos Stathogiannis

Peer-reviewers: Domenico Filomena and Maria Boutsikou

© The Author(s) 2021. Published by Oxford University Press on behalf of the European Society of Cardiology.

This is an Open Access article distributed under the terms of the Creative Commons Attribution Non-Commercial License (<http://creativecommons.org/licenses/by-nc/4.0/>), which permits non-commercial re-use, distribution, and reproduction in any medium, provided the original work is properly cited. For commercial re-use, please contact journals.permissions@oup.com

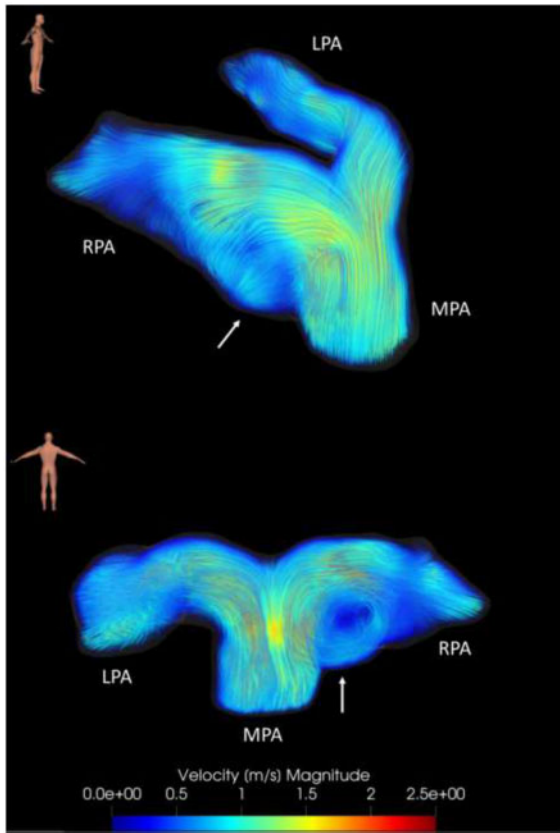


Figure 1 Visualization of blood flow in the pulmonary arteries at peak-systole with colour-coded streamlines obtained from a four-dimensional flow cardiac magnetic resonance scan. Four-dimensional flow cardiac magnetic resonance is the term used for time-resolved phase-contrast cardiac magnetic resonance with flow-encoding in all three spatial directions. Using four-dimensional-flow cardiac magnetic resonance, qualification and quantification of flow over an entire volume can be obtained. This figure shows vortex flow in the right pulmonary artery, indicated by the arrow. LPA, left pulmonary artery; MPA, main pulmonary artery; RPA, right pulmonary artery. This four-dimensional flow cardiac magnetic resonance was acquired a 3.0T scanner (Ingenia R5.6.1, Philips Healthcare, Best, the Netherlands), with the following scan parameters: spatial resolution $2.5 \times 2.5 \times 2.5 \text{ mm}^3$, FOV $350 \times 350 \text{ mm}^2$, temporal resolution 65.5 ms, echo time 2.44 ms, repetition time 4.28 ms, flip angle 10° , venc 200 cm/s, and TFE factor 3.

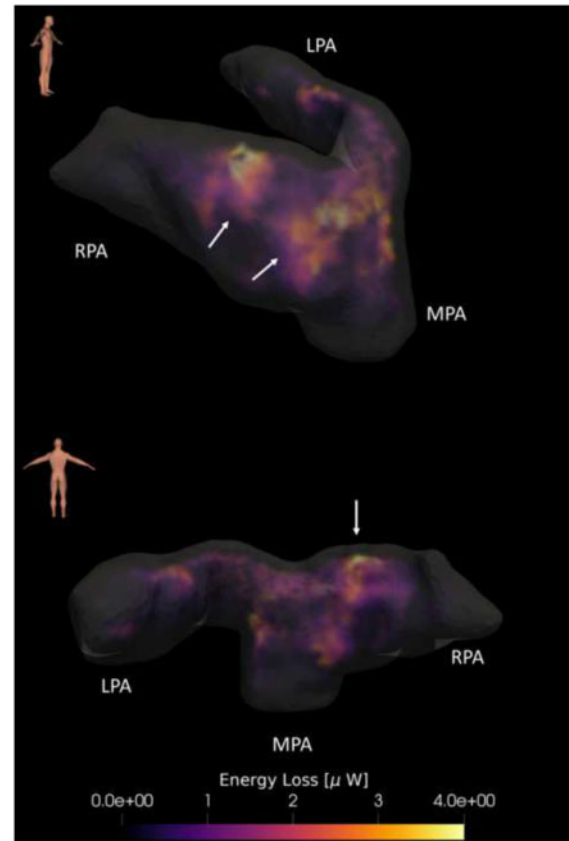


Figure 2 Visualization of energy loss in the pulmonary arteries at peak-systole. Energy loss is a quantitative measure of the mechanical kinetic energy irreversibly lost to thermal energy, due to friction forces between viscous fluids and the adjacent wall. Minimal energy loss is required for an optimal cardiovascular circulation. Therefore, loss may be a good marker of an inefficient circulation. Increased values of energy loss can be seen at the location of the vortex flow, indicated by the arrow. LPA, left pulmonary artery; MPA, main pulmonary artery; RPA, right pulmonary artery.