

## ARTICLE

# Effect of Crohn's Disease on Villous Length and CYP3A4 Expression in the Pediatric Small Intestine

Carrie A Vyhlidal<sup>1,2,\*</sup>, Brian D. Chapron<sup>1</sup>, Atif Ahmed<sup>2,3</sup>, Vivekanand Singh<sup>4</sup>, Rebecca Casini<sup>5</sup> and Valentina Shakhnovich<sup>1,2,6</sup>

Changes in absorptive capacity and first-pass metabolism in the small intestine affect oral drug bioavailability. Characterization of such changes as a consequence of inflammation is important for developing physiologically-based pharmacokinetic (PBPK) models for inflammatory bowel disease. We sought to elucidate the impact of small intestinal Crohn's disease (CD) on villous length and CYP3A4 expression in children. Freshly frozen duodenal and terminal ileum (TI) biopsies from 107 children (1–19 years) with and without CD were evaluated for active inflammation. Villous length and CYP3A4 mRNA/protein expression were compared among regions of active and inactive inflammation in CD and controls. A twofold reduction in villous length was observed in inflamed duodena and ilia of children with CD, but in the absence of regional inflammation, villi in CD were comparable in length to controls. Expression of *CYP3A4* mRNA correlated significantly with villous length in the TI ( $P = 0.0003$ ), with a trend observed in the duodenum that did not reach statistical significance. In the presence of active inflammation, a significant decrease in CYP3A protein expression was confirmed in the duodenum, where protein expression also correlated significantly with villous length across diagnoses ( $P < 0.0001$ ). Our findings suggest that previous observations of decreased CYP3A4 expression and function in inflamed intestine may not be due solely to downregulation by inflammatory cytokines, but also to villous blunting and subsequent loss of surface area for protein expression. This information is relevant for PBPK model development and could aid with dose adjustment decisions for oral CYP3A4 substrates administered during CD flare (e.g., budesonide).

## Study Highlights

### WHAT IS THE CURRENT KNOWLEDGE ON THE TOPIC?

Small intestinal inflammation associated with Crohn's disease (CD) has the potential to alter the absorption and first-pass metabolism of orally administered drugs metabolized by CYP3A4, the major P450 isoform in the small intestine. However, there is currently little information available in pediatric populations, where such information is critical for the development of physiologically-based pharmacokinetic (PBPK) models that could aid with appropriate drug dose selection of oral CYP3A4 substrates during disease flare vs. remission.

### WHAT QUESTION DID THIS STUDY ADDRESS?

This study investigates the relationships of inflammation, villous length, and the expression of CYP3A4 and related genes in the small intestine of children with and without CD.

### WHAT DOES THIS STUDY ADD TO OUR KNOWLEDGE?

Active regional inflammation in CD was associated with both villous length blunting and decreased mRNA/protein expression of CYP3A4 in the small intestine.

### HOW MIGHT THIS CHANGE CLINICAL PHARMACOLOGY OR TRANSLATIONAL SCIENCE?

CYP3A4 expression and villous length data presented in this study can contribute to future PBPK model development.

Crohn's disease (CD) is a chronic autoimmune condition characterized by recurrent and remitting episodes of inflammation in the gastrointestinal tract. Active upper tract CD is associated with inflammation in the small intestine that results in histopathological changes to the intestinal absorptive epithelium, including villous blunting in the affected intestinal regions.<sup>1,2</sup> Because healthy villi play a critical role

in making the small intestine the major site of absorption for most orally administered drugs, the structural changes frequently observed in active CD have the potential to alter oral drug bioavailability. In light of the fact that treatment of CD frequently necessitates patients take multiple oral medications on a lifelong basis,<sup>3</sup> it is important to characterize the factors governing small intestinal drug disposition in CD.

<sup>1</sup> Division of Clinical Pharmacology, Toxicology and Therapeutic Innovation, Children's Mercy Kansas City, Kansas City, Missouri USA; <sup>2</sup> Department of Pediatrics, University of Missouri - Kansas City School of Medicine, Kansas City, Missouri USA; <sup>3</sup> Division of Pathology, Children's Mercy Kansas City, Kansas City, Missouri USA; <sup>4</sup> Division of Pathology, UT Southwestern Medical Center, Dallas, Texas USA; <sup>5</sup> NorthShore University Health System, Skokie, Illinois USA; <sup>6</sup> Division of Pediatric Gastroenterology, Hepatology and Nutrition, Children's Mercy Kansas City, Kansas City, Missouri USA. Correspondence: Carrie A. Vyhlidal (cvyhlidal@cmh.edu)

Cytochrome P450 3A4 (CYP3A4)-mediated metabolism is the primary route of clearance for over a quarter of the most commonly prescribed drugs.<sup>4</sup> In addition to high hepatic expression, CYP3A4 is the most abundant cytochrome P450 isoform in the small intestine and is capable of extensively metabolizing many orally absorbed drugs during first-pass metabolism.<sup>5,6</sup> Much is known about the regulation of CYP3A4 expression in the healthy adult intestine, including its transcriptional regulation by specific nuclear receptors such as PXR and FXR.<sup>7–9</sup> However, there is currently a paucity of published literature regarding alterations in CYP3A4 expression in CD, with a critical information gap for pediatric patients.

Notable among the existing published data are results from an *in vivo* pharmacokinetic study in adults with CD that attempted to estimate the fraction of a CYP3A4 substrate, midazolam, metabolized in the intestine during first-pass.<sup>10</sup> The authors of the study estimated an average fivefold lower intestinal extraction ratio of midazolam in adults with CD than previously reported for healthy subjects.<sup>10</sup> One major limitation of the study design was that the independent contributions of the fraction absorbed ( $F_a$ ) and the fraction escaping intestinal first-pass metabolism ( $F_g$ ) could not be differentiated. This separation of  $F_a$  and  $F_g$  is critical because some histological pathologies that occur in CD (e.g., villous blunting and reductions in tight junction integrity) may independently alter drug access to the portal venous supply,<sup>2,11</sup> thereby altering the  $F_a$  and potentially confounding the estimation of changes in  $F_g$  and CYP3A4-mediated intestinal first-pass metabolism.

Direct assessment of CYP3A4 expression in small intestinal biopsies provides a way to circumvent the issue of conflating changes in the diffusion and partitioning of drugs across the epithelial barrier with changes in the intrinsic catalytic activity of CYP3A4 in the small intestinal enterocytes. Using archived formalin fixed, paraffin embedded duodenal and ileal biopsies from children with CD, we previously demonstrated decreased mRNA expression of CYP3A4 and NR1I2 (the gene encoding for PXR) in inflamed vs. noninflamed small intestine from the same individuals.<sup>12</sup> These observations mirrored similar findings of reduced intestinal CYP3A4 mRNA expression in celiac disease,<sup>13</sup> another inflammatory disorder that, similarly to CD, results in intestinal villous blunting.<sup>2</sup> Collectively, these findings raise the question of whether villous blunting and the subsequent reduction in intestinal surface area, or inflammation/disease *per se*, modulate intestinal CYP3A4 expression, and, if so, to what extent. Such mechanistic insights are relevant for the development of physiologically-based pharmacokinetic (PBPK) models of drug disposition in the intestine, particularly for conditions characterized by recurrent and remittent bouts of intestinal pathology where drug dose adjustments may be warranted based on variability in local intestinal drug metabolism during active vs. inactive phases of disease. Thus, our primary objective in this study was to investigate the relationships of inflammation, villous length, and CYP3A4 expression in the small intestine of children with and without CD.

Given the putatively “synergistic” nature of the concerted actions of CYP3A4 and the active apical efflux transporter P-gp in the small intestine,<sup>14</sup> genes encoding for P-gp (ABCB1), PXR (NR1I2) and FXR (NR1H4), two nuclear receptors known to regulate CYP3A4 and ABCB1

gene expression, were also evaluated.<sup>15,16</sup> Additionally, the expression of the gene encoding for IL8 (CXCL8), an inflammatory chemokine that is elevated in CD, was also assessed as an added means of quantifying intestinal inflammation.<sup>17</sup> VIL1 expression was determined as a marker of enterocyte content of the biopsies as well.

## METHODS

### Collection of samples

In addition to standard-of-medical-care clinical and histopathology review, fresh flash-frozen duodenal and terminal ileum (TI) mucosal biopsies from 39 children with CD (1–19 years of age) who were treatment-naïve (i.e., no steroids, immunomodulators, or biologics), and 68 age and sex-matched children without inflammatory bowel disease (IBD) were assessed for villous length and mRNA expression. Standard-of-care endoscopy with biopsy was routinely performed after at least 8 hours of fasting. Biopsies from children without CD (i.e., controls) were collected from children undergoing standard-of-medical-care upper and lower endoscopies to rule out organic causes of common gastrointestinal (GI) complaints (e.g., abdominal pain). All routinely biopsied sites (i.e., esophagus, stomach, and small and large intestine) were reviewed by two independent pathologists to confirm that inflammation and/or any other organic pathology was absent. Ultimately, these children were diagnosed with functional or psychosomatic complaints, but healthy GI tracts with no evidence of GI pathology. Children without IBD were overenrolled in order to assess variability in intestinal villous length across the pediatric age spectrum. For all samples, the extent of inflammation was assessed by two independent, experienced pediatric pathologists. The villous length was measured using Infinity Analyze Software (Teledyne Lumenera, Ottawa, Canada) with built-in morphometric capabilities. A line was drawn from the villous tip to the base where it curves to blend with the crypt and its length was measured in micrometers. This study was approved by the Children’s Mercy Pediatric Institutional Review Board. Descriptive statistics for the study population are provided in **Table 1**.

### Gene expression

Using the Allprep DNA/RNA/miRNA extraction kit (Qiagen, Valencia, CA) according to manufacturer’s recommendations, RNA was extracted from intestinal mucosal biopsy samples obtained during standard-of-care endoscopy. RNA quantity was determined with a NanoDrop ND-1000 spectrophotometer (ThermoFisher Scientific, Waltham, MA) and quality with an Experion automated electrophoresis system (BioRad, Hercules, CA). Total RNA (200 ng) was reverse transcribed using the High-Capacity RNA-to-cDNA Kit (Applied Biosystems, Foster City, CA). Eight duodena and eight TI samples (3 from children with CD, and 5 without CD) were excluded from gene expression analyses due to lack of sufficient material for RNA extraction. An additional four duodenal (4 from children with CD) and three TI (1 from a child with CD, and 2 without CD) RNA samples were excluded from gene expression analyses due to GAPDH mRNA values below the limits of quantification for the assay. For all other samples, expression of NR1I2 (Hs00243666\_m1), NR1H4 (Hs01026590\_m1), CXCL8 (Hs99999034\_m1),

**Table 1** Descriptive statistics of the study population

	Control-all	Control-no meds	CD-all	CD subgroups			
				CD-Duo	CD-TI	CD-both	CD-remission
Number of participants	68 duo 61 TI	21 duo 21 TI	39 duo 37 TI	5 duo 5 TI	15 duo 14 TI	11 duo 11 TI	8 duo 7 TI
Age, years [range]	13.4 ± 3.8 [2.0–18.1]	12.7 ± 4.2 [2.0–18.1]	12.7 ± 3.5 [1.3–19.3]	14.7 ± 3.7 [10.2–19.3]	13.6 ± 2.6 [7.5–17]	13.0 ± 2.3 [8.6–16.6]	9.5 ± 4.7 [1.3–13.6]
Female (%)	35 (51)	9 (43)	13 (33)	1 (20)	4 (27)	4 (36)	4 (50)
Duodenum villous length, μm <sup>b</sup>	471 ± 72	441 ± 70	396 ± 150 <sup>a</sup>	279 ± 138 <sup>a</sup>	483 ± 81	262 ± 130 <sup>a</sup>	492 ± 98
TI villous length, μm <sup>b</sup>	509 ± 74	500 ± 64	268 ± 184 <sup>a</sup>	471 ± 50	205 ± 150 <sup>a</sup>	179 ± 166 <sup>a</sup>	389 ± 176 <sup>a</sup>

CD, Crohn's disease; Duo, duodenum, TI, terminal ileum.

<sup>a</sup>Indicates statistically significant difference in villous length from "Control-all" group for the corresponding tissue.

<sup>b</sup>Villous length is reported as average ± SD.

*CYP3A4* (Hs00604506\_m1), *VIL1* (Hs\_00200229\_m1), *ABCB1* (Hs00184500\_m1), and *GAPDH* (4333764) was determined via real-time polymerase chain reaction using PerfeCTa FastMix (Quanta Biosciences, Beverly, MA). Each gene expression assay was performed in triplicate for each sample and results were normalized to the expression of *GAPDH*. In this study, we considered the expression of *VIL1* as an independent marker of villous length, therefore, *GAPDH* was used to normalize gene expression rather than *VIL1*, commonly used in other gene expression studies in the small intestine. Similar differences in gene expression were observed between groups when *VIL1* was used to normalize gene expression in this dataset.

### Immunohistochemistry

On the basis of tissue availability, a subset of duodenal biopsy samples including 35 non-IBD controls and 34 patients with CD (15 with active duodenal inflammation and 19 CD without duodenal inflammation) were subjected to immunohistochemistry (IHC) staining for CYP3A4 protein expression. Briefly, a polyclonal antibody for CYP3A4 (ThermoFisher Scientific, Rockford, IL) was used at a dilution of 1:1000. After antigen retrieval, automated IHC was performed in a Leica BOND-MAX instrument (Leica Biosystems, Wetzlar, Germany), using standard protocols that included primary antibody, a secondary antibody, a polymer conjugate, and a coloring reagent. Staining in the top of mucosal villi was evaluated in the study samples and compared with staining pattern in normal pediatric mucosa, which served as an internal positive control. Postnatal liver tissue, known to abundantly express CYP3A4, served as an external positive control. The intensity of the staining was defined *a priori* according to the following scoring system: (0) negative or complete absence of any staining; (1) weak staining or marked loss of normal staining; (2) patchy interrupted staining or decreased intensity of normal staining; or (3) normal staining, with staining intensity similar to normal mucosa. During sample analysis, scores 0 and 1 were binned together, as consensus could not be reached between the rating pathologists for several samples with low/no staining for CYP3A4. Because the TI is generally less relevant than the duodenum in oral drug absorption, IHC staining was not performed on TI biopsies.

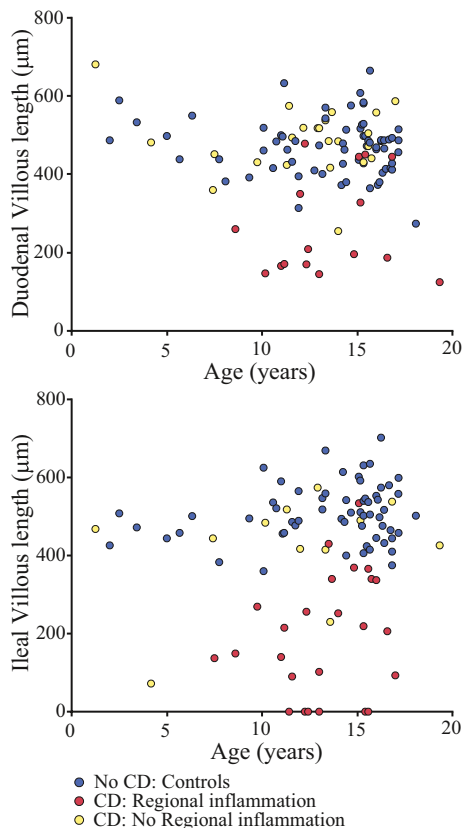
### Statistical analysis

Villous length and log-transformed normalized gene expression levels were compared in controls without IBD and children with CD (with and without active regional inflammation in the intestine on histopathology). Statistical analyses were performed using JMP 14.2.0 (SAS Institute, Cary, NC). One-way analysis of variance (ANOVA) was conducted on expression data for all six genes of interest or villous length measurements within a given intestinal region (duodena and TI) across the three conditions: non-IBD controls, CD with inflammation in the region of interest (duodena or TI), and CD without inflammation in the region of interest. Comparison of villous length was also stratified by IHC staining grade. A Pearson  $\chi^2$  test of independence was performed to examine the relationship between staining grade of CYP3A4 and CD disease/inflammation state. *Post hoc* pairwise comparisons were conducted on all data with significant results using Tukey's Honest Significant Difference.

## RESULTS

### Villous length

There was no observable trend between age and villous length in the duodenum or TI across the study population ( $n = 107$  duodenum and  $n = 98$  TI, age 1–19 years), regardless of disease or inflammation status (**Figure 1**). Concomitant medication use at the time of endoscopy (e.g., acid suppression drugs and antihistamines) did not appear to influence villous length (control-no meds vs. control-all; **Table 1**). A statistically significant, approximately twofold reduction in villous length was observed in both the duodenum and TI in the presence of active inflammation associated with CD, compared with CD without active regional inflammation on histopathology, or in controls without IBD ( $P < 0.0001$ ; **Figure 2**). Villous length in the duodenum did not differ significantly between controls and children with CD without active regional inflammation ( $486 \pm 85 \mu\text{m}$  vs.  $471 \pm 72 \mu\text{m}$  duodenum;  $P = 0.7$ ). In contrast, villous length in the terminal ileum was statistically significantly lower in children with CD without active regional inflammation relative to controls ( $509 \pm 74 \mu\text{m}$  controls vs.  $423 \pm 140 \mu\text{m}$  CD without active inflammation;  $P = 0.04$ ).



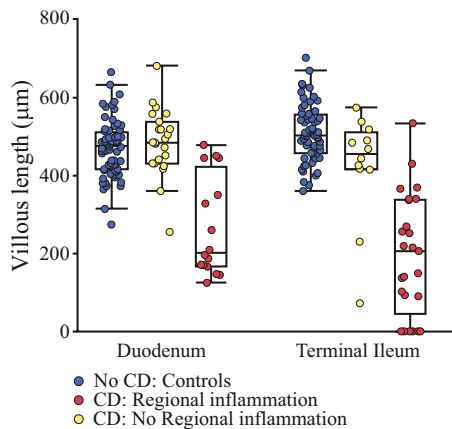
**Figure 1** Ontogeny of small intestinal villous length in the presence and absence of Crohn's disease (CD)-associated inflammation. There was no apparent association between age and villous length across the age range studied (1–19 years) in either the duodenum or terminal ileum regardless of disease or inflammation status.

**Gene expression**

**Disease-specific differences**

Statistically significant differences in *CYP3A4* mRNA expression were noted in the TI determined by one-way ANOVA ( $F(2,93) = 3.89, P = 0.024$ ; **Figure 3**). Specifically, *CYP3A4* gene expression was reduced in ileal tissue of children with CD and active ileal inflammation compared with children without CD ( $P = 0.021$ ). *CYP3A4* expression in the TI was not significantly different between children with CD without active inflammation and controls ( $P = 0.98$ ). Decreased *CYP3A4* gene expression in inflamed duodenal tissue of children with CD was also noted, but did not reach statistical significance (one-way ANOVA  $F(2,92) = 1.88, P = 0.16$ ). No significant differences or trends in expression of other *CYP3A4*-related genes or *VIL1* were noted across study groups.

Statistically significant differences in expression were also observed in both the duodenum and TI for *CXCL8*, which encodes IL-8, a marker of inflammation (one-way ANOVA  $F(2,92) = 4.25, P = 0.02$ , duodenum; and  $F(2,93) = 20.61, P < 0.0001$ , TI). In the duodenum, *CXCL8* expression was higher in children with CD with active inflammation relative to controls (**Figure 3**,  $P = 0.02$ ). In the terminal ileum, *CXCL8* expression was significantly higher in children with



**Figure 2** Effect of Crohn's disease (CD)-associated regional inflammation on villous length. Both mean duodenal ( $289 \pm 140 \mu\text{m}$ ) and ileal ( $194 \pm 154 \mu\text{m}$ ) villous length was significantly reduced in children with active CD and regional inflammation, compared with children with CD without active regional inflammation ( $503 \pm 69 \mu\text{m}$  duodenum and  $423 \pm 140 \mu\text{m}$  ileum) or controls ( $495 \pm 67 \mu\text{m}$  duodenum and  $509 \pm 74 \mu\text{m}$  ileum;  $P < 0.0001$ ).

CD, both with and without active TI inflammation on histopathology, compared with controls ( $P < 0.0001$  and  $P = 0.007$ , respectively).

Adding gender as a covariate did not affect the above results.

**Regional differences**

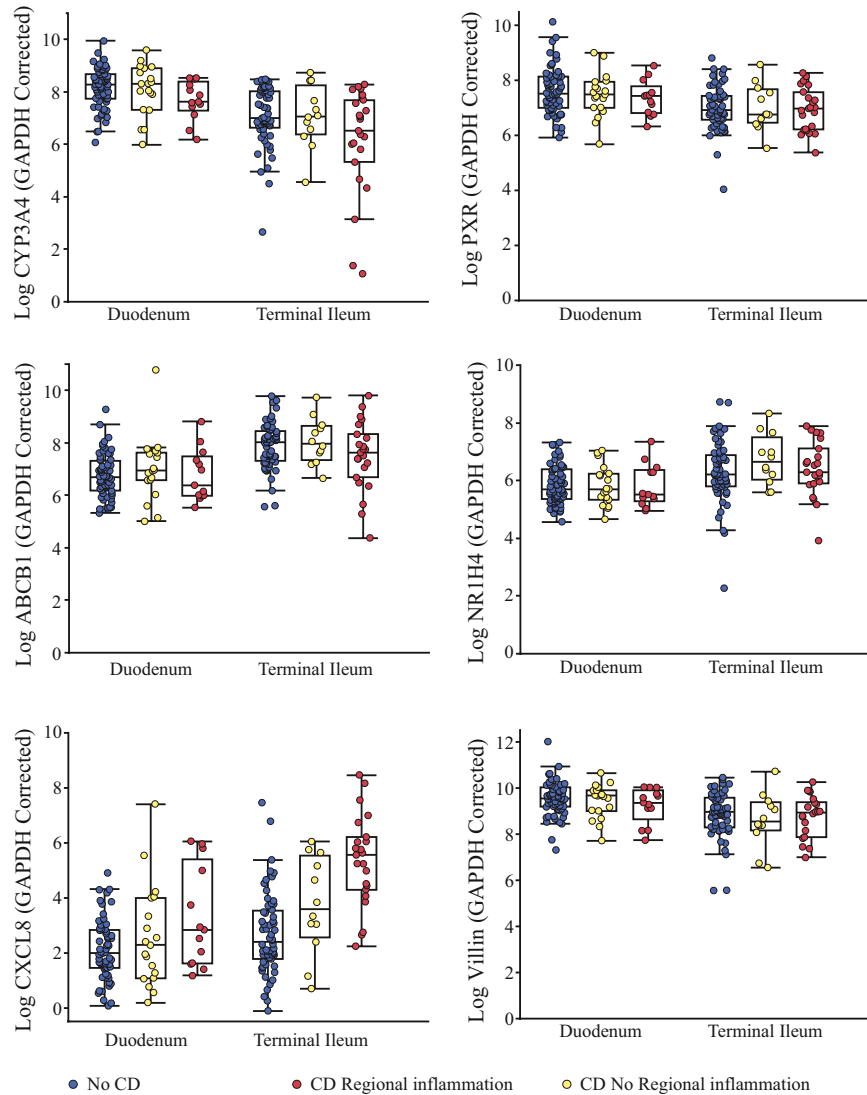
In controls without IBD, gene expression of *CYP3A4*, *VIL1*, and *NR1I2* was significantly greater in the duodenum than the TI ( $P < 0.0001$ ). This gradient in *NR1I2* gene expression was lost in samples from patients with CD (corrected  $P > 0.05$ ), whereas it was maintained for *CYP3A4* and *VIL1*. Conversely, expression of *ABCB1* and *NR1H4* was significantly greater in the TI than the duodenum in both controls ( $P < 0.0001$ ) and children with CD ( $P = 0.02$  and  $P = 0.006$ , respectively). Expression of *CXCL8* was also significantly greater in the TI than the duodenum, but only in children with CD (both with and without active inflammation on histopathology (**Figure 3**).

**mRNA correlations with villous length**

Overall, mRNA expression did not correlate with villous length, except for *CYP3A4* in the TI across the entire study population, independent of disease status ( $r = 0.38, P = 0.0003$ ). Expression of *CXCL8* mRNA was inversely correlated with villous length ( $r = -0.55, P < 0.0001$ ), as well as expression of *CYP3A4* in the TI ( $r = -0.42, P < 0.0001$ ).

**Immunohistochemistry of CYP3A4**

Similar to observations in adults,<sup>18</sup> expression of *CYP3A4* protein in pediatric controls was restricted mostly to the villous tips and was enriched along the apical border of the duodenal enterocytes. The pattern for *CYP3A4* IHC staining was weaker, more diffuse, and patchier in the inflamed duodenum of children with CD than in the uninflamed duodenum of children with CD or in controls. Approximately 47%, 33%, and 20%



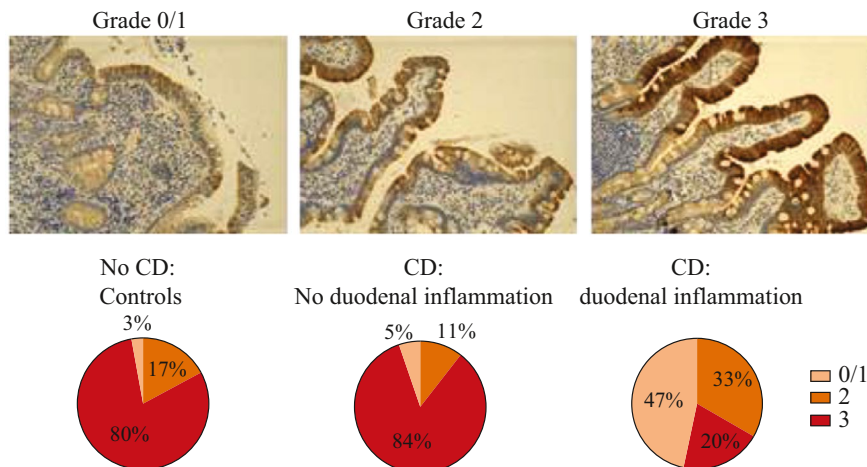
**Figure 3** Small intestinal mRNA expression levels for CYP3A4 and related genes in the presence and absence of Crohn's disease (CD)-associated inflammation. Gene expression of CYP3A4 was significantly reduced in the terminal ileum (TI) of children with CD when active regional (i.e., ileal) inflammation was present. A similar trend was observed in the duodenum; however, it did not reach statistical significance. Expression of CXCL8 was increased in CD in the TI in CD in the presence and absence of active regional (i.e., TI) inflammation. The expression of CYP3A4, ABCB1, NR1H4, and Villin was significantly different between duodenum and TI only in controls without CD, and expression of CXCL8 differed significantly between the duodenum and TI only in CD with active inflammation in one region but not the other.

of patients with CD and active duodenal inflammation scored 0/1, 2, and 3, respectively, on IHC staining, compared with 5%, 11%, and 84% of patients with CD but without duodenal inflammation and 3%, 17%, and 80% of controls without IBD (Figure 4). A  $\chi^2$  test of independence found a statistically significant relationship between CD disease/inflammation status and CYP3A4 staining grade (Pearson  $\chi^2 = 25.6$ ,  $P < 0.0001$ ). Higher staining grades were significantly associated with longer mean villous length (one-way ANOVA  $F(2,66) = 69.3$ ,  $P < 0.0001$ ). Post hoc analysis confirmed differences among all three possible pairings of IHC staining grades ( $P < 0.0001$ ). When stratified by disease and inflammation state, visual inspection of the relationship between CYP3A4 IHC staining grade and villous length generally suggests that, although relatively lower duodenal CYP3A4 protein expression is more

common in CD with active duodenal inflammation, villous length appears similar within a given staining grade irrespective of underlying disease or inflammation status (Figure 5).

## DISCUSSION

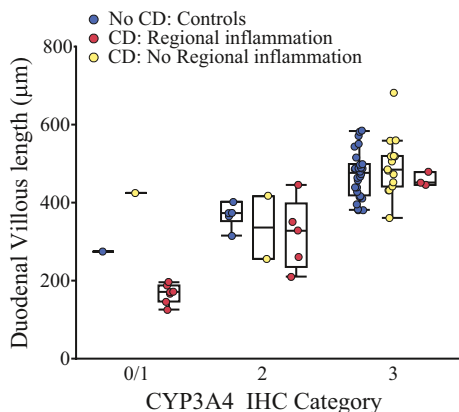
CD is an inflammatory illness that often manifests in histopathological changes along the GI tract.<sup>1,2</sup> Small intestinal involvement in CD has the potential to alter the absorption and first-pass metabolism of orally administered drugs. However, there is currently little published information on the intestinal disposition of drugs in children with CD. In this study, we sought to elucidate the effects of CD, both during active small intestinal inflammation and remission, on the relationship between enterocytic CYP3A4 expression and



**Figure 4** Prevalence of duodenal CYP3A4 protein expression patterns in presence and absence of Crohn’s disease (CD)-associated duodenal inflammation. Representative images of staining grades are displayed in the upper panels. Prevalence of staining grades by disease and duodenal inflammation status are displayed below. Grade 3 staining (i.e., normal apical pattern) was comparable between controls without CD and children with CD but without active duodenal inflammation. Lower staining grades (0/1 and 2) were more prevalent in biopsies from children with CD and active duodenal inflammation.

villous length. Using duodenal and TI tissue collected from individuals with CD and healthy controls during routine biopsy, we evaluated villous length, CYP3A4 mRNA expression, and protein expression. Because the mass of tissue collected during routine biopsies in children is especially small, currently available targeted proteomic approaches are insufficiently sensitive to measure CYP3A4 content in a quantitative manner. As such, we opted to evaluate CYP3A4 protein expression qualitatively via IHC staining. Although the interpretation of the IHC-derived enzyme expression data has some limitations, it does demonstrate that there are important differences in CYP3A4 expression occurring during CD-associated regional inflammation.

Specifically, we observed that active regional inflammation in CD was associated with both villous length blunting



**Figure 5** Association between villous length and CYP3A4 protein expression. CYP3A4 immunohistochemistry (IHC) staining category (ordinal variable) correlated with villous length in the duodenum where higher protein staining was noted in samples with longer villi, independent of disease or inflammation. CD, Crohn’s disease.

and decreased mRNA/protein expression of CYP3A4 in the small intestine. Although the trend toward decreased CYP3A4 mRNA expression in the inflamed duodenum of children with CD did not reach statistical significance, as it did in the TI, significant reduction in CYP3A4 protein expression was confirmed by IHC staining in the presence of duodenal inflammation (Figure 4). IHC staining grade also correlated with villous length across all samples (Figure 5). Observation of lower IHC staining in the duodena of controls with shorter villi, in the absence of increased tissue CXCL8 expression or inflammation on histopathology, suggests that villous length may exert an independent effect on CYP3A4 expression in the gut. This could suggest that previous observations of reduced intestinal CYP3A4 activity in CD<sup>10</sup> may not be solely the result of the direct action of CD-associated inflammatory cytokines on CYP3A4 transcriptional regulation. Rather, reduced CYP3A4 expression may also be secondary to loss of enterocyte surface area along the shorter duodenal villi caused by intestinal inflammation. However, we acknowledge that the relationship between villous length and protein expression is complex and mechanistic studies are beyond the scope of this report.

If altered, CYP3A4 expression is associated with villous blunting and/or active disease in the duodenum, as our data suggest, dose adjustments for oral CYP3A4 substrates may be necessary during times of CD flare vs. remission. This is particularly relevant for oral CYP3A4 substrates budesonide and midazolam, as budesonide is commonly prescribed for IBD flare, in an attempt to limit systemic corticosteroid exposure, and midazolam is used as an anxiolytic before endoscopy. Although changes in ileal CYP3A4 expression may also contribute to the disposition of these drugs, CYP3A4 expression decreases from proximal to distal small intestine,<sup>19–21</sup> as supported by our mRNA data. Thus, the relative contribution of CYP3A4 changes in the TI is expected to be lower than changes in the duodenum. For this reason, IHC staining in the TI

was not performed, especially as additional tissue was not always available for staining.

Our data also provide a basis for further investigations into the utility of orally administered CYP3A4 drug probes and their metabolism as noninvasive surrogate markers of intestinal epithelial health and inflammation. This biomarker approach has been previously evaluated with some promise in celiac disease<sup>22</sup> but not yet in CD, where it could offer a convenient alternative to endoscopy, particularly as the focus of therapeutic end points shifts from symptom relief to mucosal healing for CD.<sup>23</sup>

In addition to CYP3A4 expression, we also evaluated gene expression for *ABCB1* (gene encoding for P-gp), an active efflux transporter localized in the apical brush border of the small intestine that is capable of independently reducing the fraction of drug absorbed in the small intestinal epithelium.<sup>24</sup> P-gp and CYP3A4 are believed to be coregulated by a number of the same nuclear receptors in the gut (e.g., PXR).<sup>15,25</sup> In our study, no significant differences were noted in *ABCB1* or *NR1I2* (gene encoding for PXR) in inflamed vs. noninflamed small bowel. However, the typical proximodistal gradient for *NR1I2* observed in controls, was absent in children with CD, suggesting that this gene is also modulated by disease, consistent with our previous findings.<sup>12</sup>

Four children without active TI inflammation on histopathology were noted to have granulomas present. Whereas only present in a subset of patients, granulomas are considered markers of CD and have been suggested to indicate a more aggressive disease phenotype<sup>26</sup>; although this is somewhat controversial. Based on the absence of active inflammation on histopathology, samples from these children were grouped with other children with CD without active inflammation. However, both villous length and the expression of the inflammatory cytokine, *CXCL8*, was highly variable in these biopsies suggesting that the disease may not be in complete remission for all of these children. Variability in disease phenotype in the TI (e.g., granulomas) may also help explain our observation of reduced villous length and increased *CXCL8* expression in the TI, but not the duodenum, of children with CD without active inflammation, when compared with controls.

Understanding the contribution of intestinal inflammation to variability in the expression and function of drug metabolizing enzymes and transporters in the intestine is important for the development of PBPK models. Our characterization of age-related and disease-related changes in intestinal villous length is equally important for the development of maturation functions for scaling effective absorptive surface area for pediatric PBPK models. In our study, we confirm previous observations of stability in intestinal villous length after 1 year of age,<sup>27</sup> in the absence of intestinal disease. We also demonstrate that villous length is reduced twofold in the presence of small bowel inflammation from CD, and as such could contribute significantly to reduction in surface area for oral drug absorption. Although the observations from our study alone are insufficient to generate a bottom-up PBPK model of pediatric CD, we believe PBPK modeling is ideally suited for pediatric patients with this diagnosis.

First, pediatric patients represent a minority of the patient population,<sup>28</sup> which makes enrollment of children in adequately powered trials challenging. Second, the pediatric disease phenotype is distinct and generally more aggressive than adult-onset disease<sup>29</sup>; therefore, it may be inappropriate to extrapolate adult pharmacology data to children without accounting for both ontogeny and disease severity in the intestine. In addition, few data exist regarding the expression of drug metabolizing enzymes and transporters in adults with CD. For example, Wilson *et al.* reported lower ileal CYP3A4 expression and reduced colonic expression of P-gp in adults with CD.<sup>30</sup> There are no studies that have investigated alterations of gene expression in the duodenum of adults with CD. Last, the remitting and relapsing nature of CD, if captured effectively in the small intestine compartment of a PBPK model, could aid with appropriate dose adjustments of orally administered drugs during disease remission and flare. Our hope is that the CYP3A4 expression and villous length data presented herein can inform future PBPK model development.

In summary, our data suggest that expression of CYP3A4, one of the most abundant CYP isoforms in the small intestine,<sup>5,6</sup> increases with increasing villous length, which is significantly blunted in active CD due to regional intestinal inflammation. Villous blunting, in addition to modulation by inflammatory cytokines, may contribute to previous observations of reduced CYP3A4 expression and activity in the small intestines of children with CD. Villous blunting may also account for decreased total absorptive capacity in the small intestine, which may influence the relative bioavailability of orally administered drugs during disease flare vs. remission. Future studies could test this hypothesis through PBPK simulation, followed by confirmation *in vivo*. Ideally, future translational studies to support further PBPK model development would use more advanced technologies, such as the rapidly evolving field of targeted proteomics, to obtain measurements of enzyme expression that are not currently possible due to constraints of routine mucosal biopsy size (i.e., ~ 1 mg). Such quantitative data would be crucial for the informed development of disease-specific PBPK models capable of providing tailored dosing for pediatric patients with CD, and potentially other conditions affecting the small intestine (e.g., celiac disease).

**Acknowledgment.** The authors gratefully acknowledge Emily and Todd Novicoff for their generous philanthropic support of our ongoing work.

**Funding.** This work was funded, in part, by a philanthropic gift from Emily and Todd Novicoff to the Children's Mercy Kansas City. This publication was made possible by a Eunice Kennedy Shriver National Institute of Child Health and Human Development (NICHD)-funded postdoctoral fellowship to B.D.C. (T32-HD069038). Its contents are solely the responsibility of the authors and do not necessarily represent the official views of the NICHD or National Institutes of Health (NIH).

**Conflict of Interest.** All authors declared no competing interests for this work.

**Disclaimer.** As an Associate Editor of *Clinical and Translational Science*, Valentina Shakhnovich was not involved in the review or decision process for this paper.

**Author Contributions.** C.A.V., B.D.C., A.A., Vi.S., R.C., and Va.S. wrote the manuscript. C.A.V., B.D.C., Vi.S., A.A., and Va.S. designed the research. C.A.V., B.D.C., A.A., and Va.S. performed the research. C.A.V., B.D.C., and Va.S. analyzed the data. Va.S. and A.A. contributed new reagents/analytical tools.

- Culliford, A., Markowitz, D., Rotterdam, H. & Green, P.H. Scalloping of duodenal mucosa in Crohn's disease. *Inflamm. Bowel Dis.* **10**, 270–273 (2004).
- Effinger, A., O'Driscoll, C.M., McAllister, M. & Fotaki, N. Impact of gastrointestinal disease states on oral drug absorption – implications for formulation design – a PEARL review. *J. Pharm. Pharmacol.* **71**, 674–698 (2019).
- Love, B.L. Report: pharmacotherapy for moderate to severe inflammatory bowel disease: evolving strategies. *Am. J. Manag. Care* **22**, s39–s50 (2016).
- Wienkers, L.C. & Heath, T.G. Predicting in vivo drug interactions from in vitro drug discovery data. *Nat. Rev. Drug Discov.* **4**, 825–833 (2005).
- Couto, N. et al. Quantitative proteomics of clinically relevant drug-metabolizing enzymes and drug transporters and their intercorrelations in the human small intestine. *Drug Metab. Dispos.* **48**, 245–254 (2020).
- Paine, M.F. et al. The human intestinal cytochrome P450 "pie". *Drug Metab. Dispos.* **34**, 880–886 (2006).
- Dürr, D. et al. St John's Wort induces intestinal P-glycoprotein/MDR1 and intestinal and hepatic CYP3A4. *Clin. Pharmacol. Ther.* **68**, 598–604 (2000).
- Glaeser, H., Drescher, S., Eichelbaum, M. & Fromm, M.F. Influence of rifampicin on the expression and function of human intestinal cytochrome P450 enzymes. *Br. J. Clin. Pharmacol.* **59**, 199–206 (2005).
- Khan, A.A. et al. Comparison of effects of VDR versus PXR, FXR and GR ligands on the regulation of CYP3A isozymes in rat and human intestine and liver. *Eur. J. Pharm. Sci.* **37**, 115–125 (2009).
- Wilson, A., Tirona, R.G. & Kim, R.B. CYP3A4 activity is markedly lower in patients with Crohn's disease. *Inflamm. Bowel Dis.* **23**, 804–813 (2017).
- Landy, J. et al. Tight junctions in inflammatory bowel diseases and inflammatory bowel disease associated colorectal cancer. *World J. Gastroenterol.* **22**, 3117–3126 (2016).
- Shakhnovich, V. et al. Decreased pregnane X receptor expression in children with active Crohn's disease. *Drug Metab. Dispos.* **44**, 1066–1069 (2016).
- Bragde, H., Jansson, U., Jarlsfelt, I. & Soderman, J. Gene expression profiling of duodenal biopsies discriminates celiac disease mucosa from normal mucosa. *Pediatr. Res.* **69**, 530–537 (2011).
- van Waterschoot, R.A. & Schinkel, A.H. A critical analysis of the interplay between cytochrome P450 3A and P-glycoprotein: recent insights from knockout and transgenic mice. *Pharmacol. Rev.* **63**, 390–410 (2011).
- Lutz, J.D. et al. Cytochrome P450 3A induction predicts P-glycoprotein induction; part 1: establishing induction relationships using ascending dose rifampin. *Clin. Pharmacol. Ther.* **104**, 1182–1190 (2018).
- Martin, P., Riley, R., Back, D.J. & Owen, A. Comparison of the induction profile for drug disposition proteins by typical nuclear receptor activators in human hepatic and intestinal cells. *Br. J. Pharmacol.* **153**, 805–819 (2008).
- Daig, R. et al. Increased interleukin 8 expression in the colon mucosa of patients with inflammatory bowel disease. *Gut* **38**, 216–222 (1996).
- Fakhoury, M. et al. Localization and mRNA expression of CYP3A and P-glycoprotein in human duodenum as a function of age. *Drug Metab. Dispos.* **33**, 1603–1607 (2005).
- de Waziers, I., Cugnenc, P.H., Yang, C.S., Leroux, J.P. & Beaune, P.H. Cytochrome P 450 isoenzymes, epoxide hydrolase and glutathione transferases in rat and human hepatic and extrahepatic tissues. *J. Pharmacol. Exp. Ther.* **253**, 387–394 (1990).
- Paine, M.F. et al. Characterization of interintestinal and intrainestinal variations in human CYP3A-dependent metabolism. *J. Pharmacol. Exp. Ther.* **283**, 1552–1562 (1997).
- Zhang, Q.Y. et al. Characterization of human small intestinal cytochromes P-450. *Drug Metab. Dispos.* **27**, 804–809 (1999).
- Morón, B. et al. CYP3A4-catalyzed simvastatin metabolism as a non-invasive marker of small intestinal health in celiac disease. *Am. J. Gastroenterol.* **108**, 1344–1351 (2013).
- Pineton de Chambrun, G., Peyrin-Biroulet, L., Lemann, M. & Colombel, J.F. Clinical implications of mucosal healing for the management of IBD. *Nat. Rev. Gastroenterol. Hepatol.* **7**, 15–29 (2010).
- Akamine, Y., Yasui-Furukori, N. & Uno, T. Drug-drug interactions of P-gp substrates unrelated to CYP metabolism. *Curr. Drug Metab.* **20**, 124–129 (2019).
- Fan, J. et al. Up-regulation of transporters and enzymes by the vitamin D receptor ligands, 1 $\alpha$ ,25-dihydroxyvitamin D3 and vitamin D analogs, in the Caco-2 cell monolayer. *J. Pharmacol. Exp. Ther.* **330**, 389–402 (2009).
- Molnar, T., Tiszlavicz, L., Gyulai, C., Nagy, F. & Lonovics, J. Clinical significance of granuloma in Crohn's disease. *World J. Gastroenterol.* **11**, 3118–3121 (2005).
- Cummins, A.G. et al. Crypt fission peaks early during infancy and crypt hyperplasia broadly peaks during infancy and childhood in the small intestine of humans. *J. Pediatr. Gastroenterol. Nutr.* **47**, 153–157 (2008).
- Rosen, M.J., Dhawan, A. & Saeed, S.A. Inflammatory bowel disease in children and adolescents. *JAMA Pediatr.* **169**, 1053–1060 (2015).
- Dubinsky, M.C. et al. Serum immune responses predict rapid disease progression among children with Crohn's disease: immune responses predict disease progression. *Am. J. Gastroenterol.* **101**, 360–367 (2006).
- Wilson, A. et al. Crohn's disease is associated with decreased CYP3A4 and P-glycoprotein protein expression. *Mol. Pharm.* **16**, 4059–4064 (2019).

© 2020 The Authors. *Clinical and Translational Science* published by Wiley Periodicals LLC on behalf of the American Society for Clinical Pharmacology and Therapeutics. This is an open access article under the terms of the Creative Commons Attribution-Non-Commercial-NoDerivs License, which permits use and distribution in any medium, provided the original work is properly cited, the use is non-commercial and no modifications or adaptations are made.