

An Arthroscopic Modification of Coracoclavicular Ligament Reconstruction and Distal Clavicle Fracture Fixation in the Lateral Position



James M. Paci, M.D., and Shrey M. Kanjiya, M.D.

Abstract: Distal clavicle fractures and acromioclavicular injuries are common shoulder injuries. Despite the frequency of these injuries, there is no gold standard for treatment. Recent suspensory fixation techniques have minimized the amount of hardware required for surgical treatment of both acromioclavicular separations and distal clavicle fractures. Advantages include reconstruction of ligamentous anatomy, minimal hardware irritation, earlier return to activity, and decreased need for hardware removal. These reconstructions are classically done in the beach chair position in an open fashion. Our preferred technique for treatment of unstable distal clavicle fractures and acromioclavicular injuries is arthroscopy-assisted coracoclavicular ligament reconstruction with or without distal clavicle fixation in the lateral decubitus position.

Distal clavicle fractures and acromioclavicular (AC) injuries comprise a large portion of shoulder injuries. The mechanism of injury is usually a direct fall onto the shoulder with the arm adducted, a fall onto an outstretched arm, or direct impact to the shoulder.¹

AC joint stability relies on several static and dynamic stabilizers. The static stabilizers include the AC ligament, coracoclavicular (CC) ligaments, and joint capsule. The AC ligament provides anterior and posterior translational stability, while the CC ligaments provide superior and inferior translational stability. The CC ligaments, the trapezoid and conoid, insert 3 and 4.5 cm from the end of the clavicle, respectively. The dynamic stabilizers include the deltoid and trapezius.¹

AC injuries are classified by the Rockwood classification. It is well established that grade I and II injuries can be treated conservatively, while grades IV to VI require operative fixation. Grade III injuries remain controversial. The Neer classification describes lateral clavicle fractures. Types I, III, and IV are considered stable and can be treated nonoperatively with good outcomes. Type IIA, IIB, and V are considered unstable and require operative fixation to prevent nonunion or malunion.¹

Currently there is no gold standard for fixation of AC separations. The current operative options for AC injuries include fixation with a hook plate, Kirschner wire fixation, screw fixation of the coracoid to the clavicle, the Weaver-Dunn procedure, CC ligament reconstruction, and suture-based suspensory fixation. Traditional plating techniques often require a second procedure for hardware removal and a larger incision. Several techniques have been described to reconstruct the CC ligaments to maintain reduction of the AC joint without the need for plate-based fixation.²⁻⁵ Banffy et al.² found that a single-tunnel technique can adequately maintain reduction in AC separations while achieving high return to work and play rates. A biomechanical study by Beitzel et al.³ showed similar load to failure and translational stability of single- and double-tunnel techniques without biological augmentation. In addition, a second bone tunnel may increase the risk of postoperative fracture.⁴

Distal clavicle fractures can be treated with precontoured clavicle locking plates paired with CC reconstruction or hook plates. Hook plates achieve good

From The Orlin & Cohen Orthopedic Group at Northwell Health (J.M.P.), Woodbury; and Department of Orthopaedics, Stony Brook University School of Medicine (S.M.K.), Stony Brook, New York, U.S.A.

The authors report the following potential conflicts of interest or sources of funding: J.M.P. receives support from Arthrex and Zimmer-Biomet. Full ICMJE author disclosure forms are available for this article online, as supplementary material.

Received May 27, 2018; accepted August 16, 2018.

Address correspondence to James M. Paci, M.D., The Orlin & Cohen Orthopedic Group, 45 Crossways Park Dr., Woodbury, NY 11797, U.S.A. E-mail: James_Paci@Yahoo.com

© 2018 by the Arthroscopy Association of North America. Published by Elsevier. This is an open access article under the CC BY-NC-ND license (<http://creativecommons.org/licenses/by-nc-nd/4.0/>).

2212-6287/18651

<https://doi.org/10.1016/j.eats.2018.08.023>

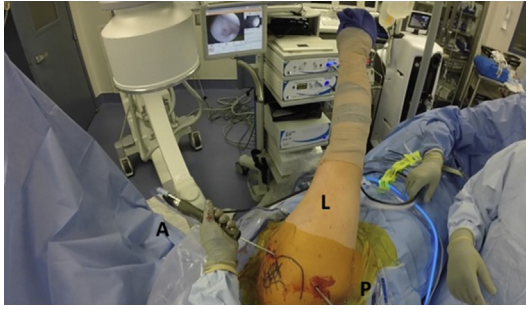


Fig 1. The patient is positioned in the lateral decubitus position, and the right arm is placed in inline traction. A standard posterior portal is established, and an anterior portal is established through the rotator interval under direct visualization. (A, anterior; L, lateral; P, posterior.)

results in treatment of distal clavicle fractures with high union rates and return to work.⁶ However, hook plates require eventual hardware removal. Newer techniques have described reconstructing the CC ligaments to secondarily reduce and maintain fractures. Cisneros and Reiriz⁵ demonstrated comparable clinical and radiographic outcomes between plate-based fixation and CC ligament reconstruction with fracture cerclage.

Traditionally, CC ligament reconstruction has been described as an open technique in the beach chair position.⁷ We propose and describe an arthroscopy-assisted CC ligament reconstruction technique in the lateral position for treatment of both unstable AC separations and distal clavicle fractures. Using an arthroscopic approach allows us to address associated intra-articular pathology, provide direct visualization of the

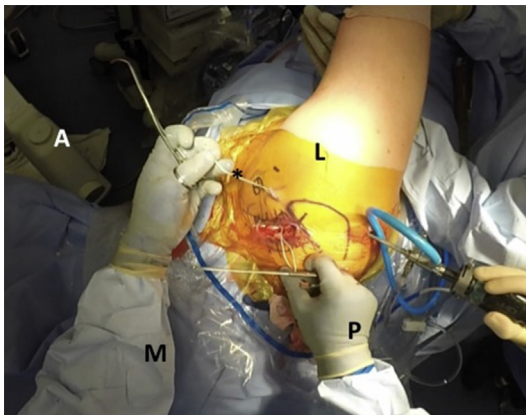


Fig 2. Patient is in the lateral decubitus position with the right arm in inline traction. An approximately 6 cm incision is made over the distal clavicle and acromion. A Satinsky clamp or coracoid passer is used to pass FiberLink or SutureTape (asterisk) beneath the coracoid from medial to lateral. Using the arthroscope and arthroscopic grasper, the stitch is grasped at the anterior portal site. The suture is then retrieved through the superior incision, lateral to the coracoid with a grasper or clamp. (A, anterior; L, lateral; M, medial; P, posterior.)

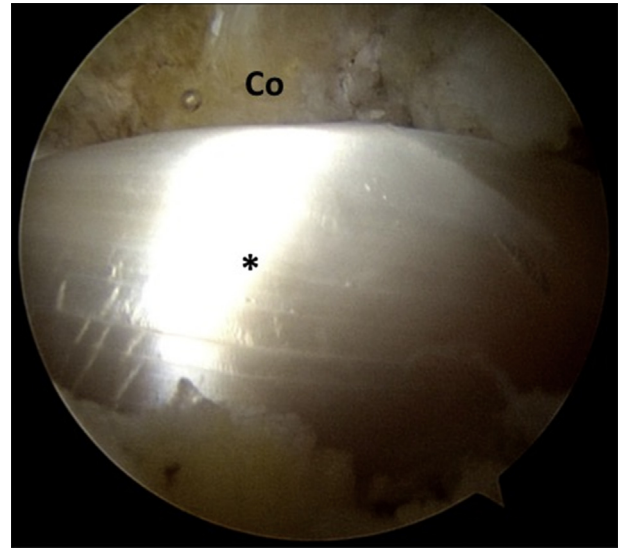


Fig 3. Direct arthroscopic visualization from the standard posterior portal of the right shoulder demonstrates the allograft (asterisk) shuttled beneath the coracoid (Co).

undersurface of the coracoid, and graft or suture passage around the coracoid. The benefits of lateral position have been extensively described, including decreased risk of bradycardia and hypotension, improved cerebral perfusion, availability of traction and joint space distraction, and surgeon comfort with the lateral position.⁸ Additionally, we have found improved surgical exposure of the distal clavicle without interference from the patient's head and neck, as well as improved access for fluoroscopic imaging.

Surgical Technique

Indications and Preoperative Planning

Primary indications for this technique include high-grade AC injuries and distal clavicle fractures. High-grade AC separations include grades IV to VI. Grade III

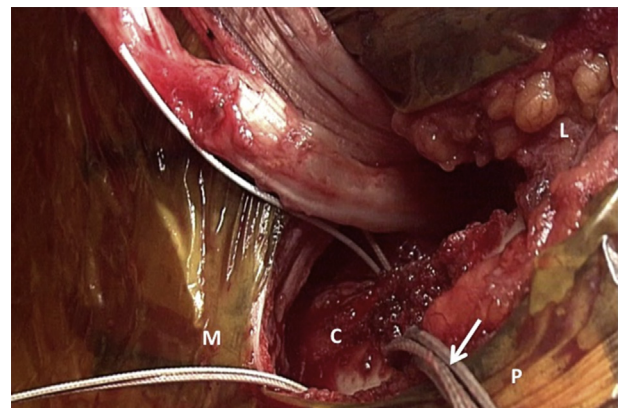


Fig 4. Superior view of the right distal clavicle that demonstrates the 4 tails of FiberTape suture (arrow) passing through the clavicle. Anterior to the clavicle are the 2 limbs of the graft (asterisk). (C, clavicle; L, lateral; M, medial; P, posterior.)

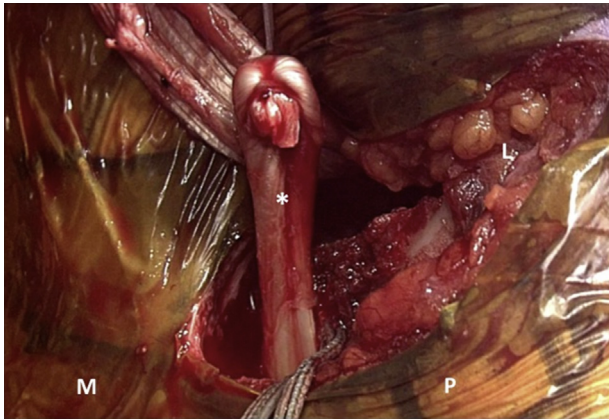


Fig 5. Superior view of the right distal clavicle demonstrating the graft (asterisk) passed around the clavicle. One limb is posteromedial to the clavicle, leaving the other limb anterolateral to the clavicle (L, lateral; M, medial; P, posterior.)

AC separations remain controversial and can be treated conservatively in nonathletes or low-demand patients. However, grade III AC separations should be surgically stabilized in elite and overhead athletes. Preoperative anterior-posterior and lateral radiographs of the clavicle are evaluated. In addition, a cross arm AC joint radiograph can help determine AC joint stability. Advanced imaging is usually not required, but a computed tomography scan can be obtained if there is question regarding fracture morphology.

Patient Positioning and Arthroscopy

Our surgical technique is demonstrated in [Video 1](#). The patient is positioned in the lateral decubitus position with all bony prominences well padded. An axillary roll is placed under the nonoperative axilla, and a beanbag is used to support the patient. The operative extremity is placed in inline suspension ([Fig 1](#)). The patient is prepped and draped in the usual sterile

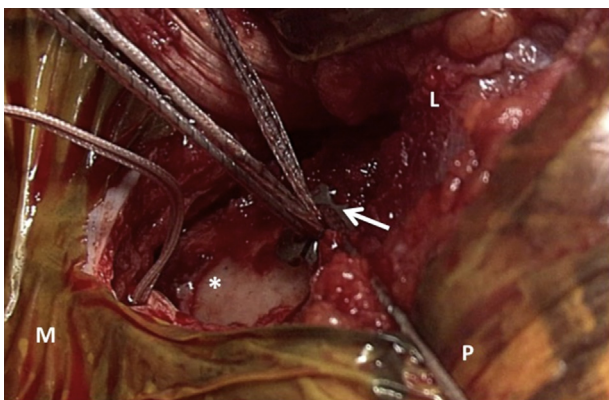


Fig 6. Superior view of the right distal clavicle (asterisk) demonstrating a suture button (Dog Bone; arrow) placed on the superior clavicle capturing the 4 limbs of the FiberTape sutures. (L, lateral; M, medial; P, posterior.)

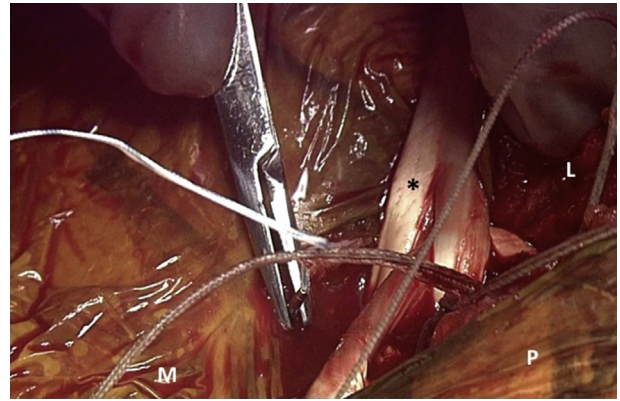


Fig 7. Superior view of the right distal clavicle demonstrating the allograft (asterisk) Pulvertaft woven to itself and secured to itself using SutureTape suture, leaving a long tail from the posterior medial limb. (L, lateral; M, medial; P, posterior.)

fashion. The glenohumeral joint is insufflated with normal saline from a posterior arthroscopic portal position. A standard posterior portal is then established. An anterior portal is established through the rotator interval using spinal needle localization ([Fig 1](#)). After addressing any associated pathology, the rotator interval is debrided and a 70° arthroscope is used to safely debride and expose the undersurface of the coracoid. Once the coracoid is exposed, attention is turned to the open incision.

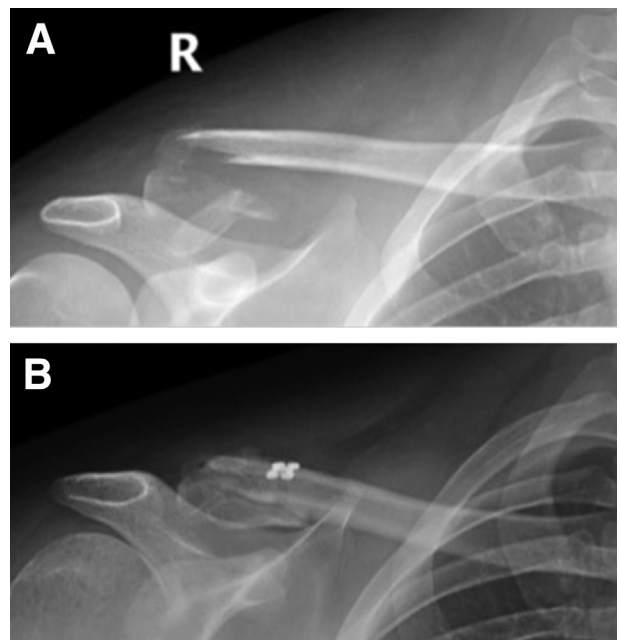


Fig 8. Radiograph A is an anteroposterior (AP) radiograph of the right (R) clavicle demonstrating a distal third clavicle fracture with superior displacement of the proximal fragment. Radiograph B is an AP radiograph of the right clavicle status post—arthroscopic assisted open reduction and coracoclavicular ligament reconstruction.

Table 1. Pearls and Pitfalls

Pearls	Pitfalls
Consider preoperative computed tomography scan to define distal clavicle fracture morphology.	Failure to address AC joint capsule may lead to loss of reduction or inadequate reduction.
The C-arm should be positioned in the anterior to posterior direction.	When addressing AC instability, the drill hole should be made 3.5 cm from the end of the clavicle.
Use the Statinsky clamp from medial to lateral direction to minimize the risk of brachial plexus injury.	When addressing distal clavicle fractures, the drill hole should be made 1 cm medial to the fracture to avoid cutout.
A 70° lens will enhance visualization of the coracoid. Clear all soft tissue beneath the coracoid.	Limit early activity to avoid loss of reduction.
The AC joint capsule should be addressed to avoid loss of reduction or inadequate reduction.	Failure to address anterior-posterior instability with allograft tissue in the posteromedial to anterolateral direction may lead to early failure.
SutureTape cerclage can aid in reduction of fracture comminution.	
Allograft placement from posteromedial to anterolateral over the clavicle will add anterior-posterior stability.	

AC, acromioclavicular.

AC Joint Exposure

An approximately 6 to 7 cm incision is made from the distal clavicle over the acromion. The distal clavicle and AC joint are exposed. In the case of a distal clavicle fracture, the fracture site is addressed to allow for provisional reduction. In the case of AC separation, provisional reduction is attempted. If the reduction is blocked, then the intra-articular disk of the AC joint is excised and reduction is attempted. If this fails, distal clavicle excision is performed and reduction is attempted. This may be required in chronic separations.

Allograft Preparation

A Satinsky clamp or coracoid passer is used to pass a FiberLink or SutureTapeLink (Arthrex, Naples, FL) beneath the coracoid from medial to lateral. The superior coracoid is palpated, and care is taken to remain in contact with the coracoid to avoid nerve injury. Visualizing with the arthroscope, the suture is grasped at the anterior portal site. The suture is then retrieved through the superior incision, lateral to the coracoid. This achieves control of the subcoracoid space (Fig 2). A soft tissue allograft tendon is prepared with loop and tack fixation at each end with no. 2 FiberLoop (Arthrex). With direct arthroscopic visualization, 2 FiberTape sutures (Arthrex) and the allograft are shuttled beneath the coracoid (Fig 3).

Allograft and Suture Fixation

A cannulated 3 mm drill bit is passed approximately 3.5 cm from the distal end of the clavicle centrally within the clavicle. A passing stitch is passed with a FiberStick suture (Arthrex). This is then traded out for FiberLink. Alternatively, a 2 mm drill bit and Hewson suture passer may be used. The 4 tails of FiberTape sutures are then passed through the clavicle (Fig 4). The graft is then passed, shuttling 1 limb posteromedial to the clavicle, leaving the other limb anterolateral to the clavicle (Fig 5). The superiorly displaced clavicle is then reduced manually. A suture button (Dog Bone; Arthrex) is placed on the superior clavicle capturing the FiberTape sutures. The tape sutures are tied, securing the reduction (Fig 6). During distal clavicle repair, the fracture is cerclaged with SutureTape (Arthrex) to contain comminution and provide secondary support. In cases with larger fragments, interfragmentary screws may be used. The allograft is then Pulvertaft woven and secured using SutureTape suture, leaving a long tail from the posterior medial limb (Fig 7). The excess graft is then placed over the superior clavicle to the posterosuperior edge of the acromion, over the AC joint and secured into the capsular tissues and periosteum with SutureTape. Reduction is verified on C-arm fluoroscope (Fig 8).

Table 2. Advantages and Disadvantages

Advantages	Disadvantages
Lateral patient positioning improves access to distal clavicle.	Technically demanding.
Arthroscopic technique allows the surgeon to address any associated intra-articular pathology.	Inline arm suspension can make the reduction more difficult.
Arthroscopic assistance aids in suture and graft passage around the coracoid.	Positioning obese patients may be difficult.
Minimal hardware irritation, decreasing the risk for a second surgical procedure to remove hardware.	Lateral position may be more difficult or unfamiliar for some surgeons.
Single drill hole in the clavicle and lack of holes in the coracoid decreases risk of iatrogenic fracture.	Potential risk for neurovascular injury when passing suture or graft around the coracoid.
Use of FiberTape reduces risk of Giggly saw-type injury to the coracoid.	

Closure

A pants-over-vest imbrication of the overlying deep soft tissue structures is performed using a combination of the SutureTape suture and 0 Vicryl suture for additional security. The superficial tissues and skin are closed with 2-0 Vicryl and a running 3-0 Prolene. The portal sites are closed with 3-0 nylon, and sterile dressings are placed. The arm is secured in a shoulder abduction sling.

Rehabilitation

Radiographs are obtained every 2 weeks for the first 6 weeks for both AC separations and distal clavicle fractures. Radiographs are taken as needed until there is evidence of fracture union for distal clavicle fractures. The patient will remain non-weight bearing on the operative extremity for 2 weeks in a sling. From weeks 2 to 4 the patient will be allowed passive flexion to 90°, glenohumeral abduction as tolerated, internal and external rotation beginning at 45°, and advancing as tolerated. Pendulum exercises are encouraged as tolerated. The patient will also begin isometric internal rotation, external rotation, bicep, and triceps strengthening. Weeks 4 to 8 entail gradual return to full range of motion and initiation of light resistance exercises. Forward flexion resistance will begin on week 6. The patient will progress to weeks 8 to 16 if they demonstrate full and nonpainful range of motion, as well as radiographic signs of union or stable AC joint. At this point advanced range of motion, strengthening, and neuromuscular control are initiated. From week 16 the patient is gradually returned to full activity with an interval return to sports program.

Discussion

AC joint injuries and distal clavicle fractures are common shoulder injuries. Left untreated, these injuries cause chronic pain, instability, and disability. However, there is no gold standard for the operative treatment of these injuries. Plating techniques require a larger incision and hardware removal due to soft tissue irritation. We propose an arthroscopy-assisted reconstruction of the CC ligaments with FiberTape coracoid cerclage fixed to the clavicle through a single tunnel with a suture button with allograft augmentation in the lateral decubitus position. Surgical pearls and pitfalls of this technique are described in Table 1. Yagnik et al.⁷ described a similar open technique in a modified beach chair position through a transverse incision over the AC joint. We have found that our arthroscopic modification in the lateral position has several advantages (Table 2). This technique allows for a smaller incision over the AC joint and direct visualization of graft and suture passage around the coracoid. Additionally, we are able to simultaneously address any

intra-articular pathology. The lateral decubitus position minimizes the risks associated with the beach chair position.⁸ The disadvantages of this technique are noted in Table 2. This technique is limited by its relative technical difficulty. The surgeon must be comfortable with the lateral decubitus position. For obese patients, positioning and exposure may be difficult. There are specific risks associated with this procedure. The brachial plexus can be injured if one diverges too far medial from the coracoid while passing the graft or sutures. There is also a risk of iatrogenic clavicle or coracoid fracture. However, using only 1 small drill hole in the clavicle reduces the risk of clavicle fracture, while the use of FiberTape broadens the footprint across the coracoid, decreasing the risk of a Giggly saw-type injury to the coracoid.

In conclusion, our arthroscopy-assisted CC reconstruction in the lateral position allows for treatment of unstable AC injuries and distal clavicle fractures. This treatment decreases incision size and soft tissue disruption, allows for direct visualization beneath the coracoid, and allows us to arthroscopically address associated shoulder pathology.

References

1. Simovitch R, Sanders B, Ozbaydar M, Lavery K, Warner JJ. Acromioclavicular joint injuries: Diagnosis and management. *J Am Acad Orthop Surg* 2009;17:207-219.
2. Banffy MB, van Eck CF, ElAttrache NS. Clinical outcomes of a single-tunnel technique for coracoclavicular and acromioclavicular ligament reconstruction. *J Shoulder Elbow Surg* 2018;27:S70-75.
3. Beitzel K, Obopilwe E, Chowanec DM, et al. Biomechanical comparison of arthroscopic repairs for acromioclavicular joint instability: Suture button systems without biological augmentation. *Am J Sports Med* 2011;39:2218-2225.
4. Dumont GD, Russell RD, Knight JR, et al. Impact of tunnels and tenodesis screws on clavicle fracture: A biomechanical study of varying coracoclavicular ligament reconstruction techniques. *Arthroscopy* 2013;29:1604-1607.
5. Cisneros LN, Reiriz JS. Management of unstable distal third clavicle fractures: Clinical and radiological outcomes of the arthroscopy-assisted conoid ligament reconstruction and fracture cerclage with sutures. *Eur J Orthop Surg Traumatol* 2017;27:373-380.
6. Zhang C, Huang J, Luo Y, Sun H. Comparison of the efficacy of a distal clavicular locking plate versus a clavicular hook plate in the treatment of unstable distal clavicle fractures and a systematic literature review. *Int Orthop* 2014;38:1461-1468.
7. Yagnik GP, Porter DA, Jordan CJ. Distal clavicle fracture repair using cortical button fixation with coracoclavicular ligament reconstruction. *Arthrosc Tech* 2018;7:411-415.
8. Peruto CM, Ciccotti MG, Cohen SB. Shoulder arthroscopy positioning: Lateral decubitus versus beach chair. *Arthroscopy* 2009;25:891-896.