

# Measurement of the nerve root of the lower lumbar region using digital images

Xin Zhao, MD, Jie Zhao, MD, Jie Guan, MM, Junkai Zeng, MM, Chen Han, MM, Yuzhou He, MM, Tangjun Zhou, MM, Chen Chen, MM, Youzhuan Xie, MD\*

## Abstract

The purpose of this study was to evaluate the relationship between the nerve root of lower lumbar and the surrounding structures using three-dimensional computed tomography (3D CT).

Twenty-three consecutive patients with thoracolumbar fractures without obvious radiological degeneration were retrospectively studied at the spinal surgery department of the hospital. The parameters of the relationship between the nerve root of the lower lumbar and the surrounding structures were measured using 3D CT in the work station of the picture archiving and communication system.

The size of the dorsal root ganglion (DRG) of the L4 was  $5.5 \pm 0.4$  mm on the right side and  $5.8 \pm 0.3$  mm on the left side. The size of the DRG of the L5 was  $6.1 \pm 0.5$  mm on the right side and  $5.7 \pm 0.4$  mm on the left side. The value of the preganglionic nerve root of the L4 was  $11.2 \pm 0.6$  mm on the right side and  $12.3 \pm 0.8$  mm on the left side, and the value of the preganglionic nerve root of the L5 was  $15.1 \pm 1.1$  mm on the right side and  $14.9 \pm 0.9$  mm on the left side.

Using 3D CT imaging constructed in the picture archiving and communication system is a practical and convenient method for evaluating the relationship between the nerve root and the surrounding structures in the routine clinical work of a spinal surgeon. The data obtained through 3D CT imaging will be helpful for surgeons, allowing them to become more familiar with correlating anatomical knowledge of individual patient.

**Abbreviations:** 3D CT = three-dimensional computed tomography, CT = computed tomography, DRG = dorsal root ganglion, PACS = picture archiving and communication system, PELD = percutaneous endoscopic lumbar discectomy, PS = pedicle screw.

**Keywords:** dorsal root ganglion, evaluate, spinal surgery, the nerve root of lower lumbar region, thoracolumbar fractures, three-dimensional computed tomography

## 1. Introduction

Minimally invasive surgery has the advantage of tissue preservation, reduction of unnecessary damage to healthy areas, acceleration of healing, and a reduction in the duration of treatment. Therefore, percutaneous endoscopic lumbar discectomy (PELD) has gained popularity for use in the treatment of lumbar disease. Among the surgical approaches of PELD, the lumbar intervertebral foramen is a main passageway to execute the operative procedure. In the foramen, the “triangular safety zone” is considered to be a safe area for accessing the intervertebral discs of the lumbar spine. This zone was first

defined by Mirkovic et al.<sup>[1]</sup> The triangular safety zone has a lateral limit at the dura mater, a lower limit at the upper vertebral plateau, and the hypotenuse at the lumbar nerve root.

The lumbar nerve roots leave the dural sac and enter the nerve root sheath before they exit through the corresponding intervertebral foramina. This entrance point (axilla point) differs for each root and depends on the lumbar spine level.<sup>[2]</sup> Close to the junction between the dorsal and ventral roots, the dorsal root presents an enlargement known as the dorsal root ganglion (DRG), which consists of a grouping of cell bodies of sensory fibers. The DRGs are located in the intervertebral foramina, except for the sacral DRGs, which are located inside the vertebral canal, and the coccygeal DRGs, which are intradural.<sup>[3]</sup> The DRG differs from the nerve roots in that it is sensitive to mechanical pressure even in the absence of chemical irritation. This is because it contains several nociceptors that have an increased mechanical sensitivity. Moreover, it may have a greater chance of causing neuropathic pain if it is injured.<sup>[4]</sup> These neural structures cannot always be viewed in one field of vision during PELD, and their position can only be estimated. For this reason, an exact anatomical knowledge of the nerve root and its relationship with the surrounding structures, especially with the herniated disc, is paramount for spinal surgeons.

Several publications have described anatomical knowledge of this area using the anatomical dissection method.<sup>[2,5]</sup> However, few studies of these anatomical areas have been performed using the computed tomography (CT) imaging method. The limitation of studies that rely on the anatomical dissection method is that they are always composed of a small sample size due to the scarcity of cadavers. Studies using the anatomical dissection

Editor: Anish Thachangattuthodi.

The authors have no conflicts of interest to disclose.

Shanghai Key Laboratory of Orthopedic Implant, Department of Orthopaedic Surgery, Shanghai Ninth People's Hospital, Shanghai Jiaotong University School of Medicine, Shanghai, PR of China.

\* Correspondence: Youzhuan Xie, Shanghai Key Laboratory of Orthopedic Implant, Department of Orthopaedic Surgery, Shanghai Ninth People's Hospital, Shanghai Jiaotong University School of Medicine, Zhizaoju Road, No. 639, Shanghai, China (e-mail: phoque711@163.com).

Copyright © 2018 the Author(s). Published by Wolters Kluwer Health, Inc. This is an open access article distributed under the terms of the Creative Commons Attribution-Non Commercial License 4.0 (CCBY-NC), where it is permissible to download, share, remix, transform, and build up the work provided it is properly cited. The work cannot be used commercially without permission from the journal.

Medicine (2018) 97:8(e9848)

Received: 11 November 2017 / Received in final form: 17 January 2018 /

Accepted: 19 January 2018

<http://dx.doi.org/10.1097/MD.00000000000009848>

method have been published with a sample size of fewer than 20 cadavers.<sup>[6–8]</sup> The benefit of using the CT imaging method to study anatomical features is that it is possible to record from a large sample size. More importantly, anatomical features of the individual patient can be studied, which is crucial for the preoperative scheme. Using the CT imaging method, the spinal surgeon can assess the relationship between the nerve root and the herniated disc of the patient.

Digital imaging is becoming increasingly popular because of the picture archiving and communication system (PACS) that is generally installed in surgical departments. Using the PACS, a surgeon can reconstruct a 3D model for the lumbar region within the department. Preoperative measurement of 3D CT is possible and convenient. The purpose of this study was to evaluate the relationship between the nerve root of the lower lumbar with the surrounding structures using the 3D CT imaging method.

## 2. Method

Our study consisted of 2 parts. First, we assessed the relationship between the nerve root of lower lumbar and the surrounding structures using 3D CT in 23 patients without lumbar radiological degeneration. Secondly, the relationship between the nerve root and the disc was demonstrated using 3D CT in a patient with lumbar disc herniation.

### 2.1. Study part one

From May 2016 to January 2017, 23 consecutive patients presenting with thoracolumbar fractures were enrolled in the spinal surgery department of Shanghai Ninth People's Hospital. This sample consisted of 8 females and 15 males between 25 and 50 years of age. The inclusion criteria were: the patients were adult without obvious lumbar radiological degenerative change, and the patients needed a lumbar operation with pedicle screw (PS) fixation. The exclusion criteria were: the patients had lumbar scoliosis or spine deformity and the patients had received a lumbar operation. The study was approved by the ethics committee of the hospital.

All patients had preoperative and postoperative CT scans (SOMATOM Definition Flash, Siemens, Germany). The postoperative CT scan was used for reconstructing a 3D model of the lumbar using the PACS (GE Healthcare Centricity PACS, General Electric Company, NY).

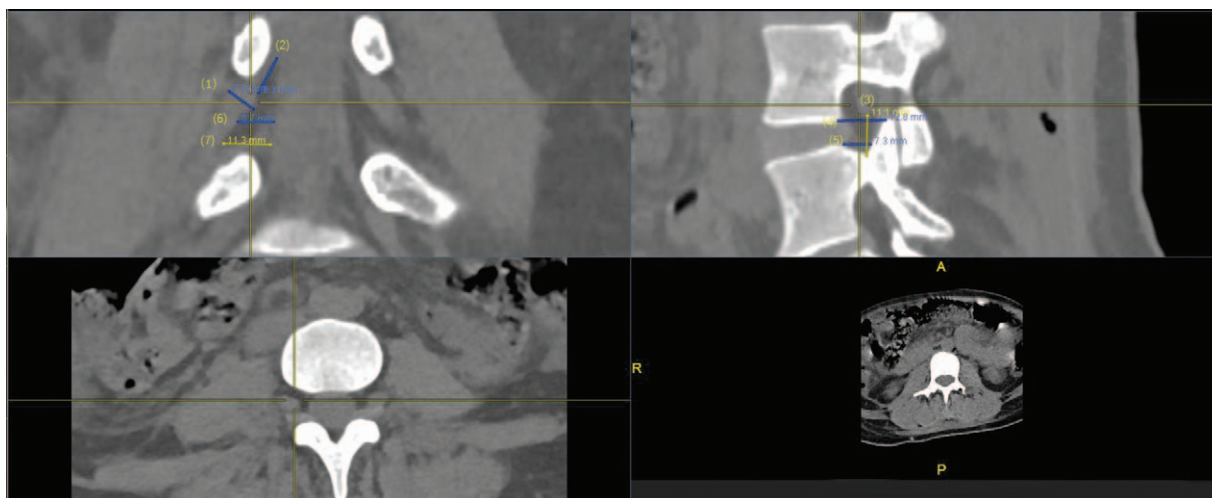
All measurements were performed in the postoperative CT by an independent spinal surgeon. The surgeon performing the measurements had 2 years of spine surgery experience. Before the measurement, a 3D CT image of the lumbar was constructed on the workstation screen with the software provided in the PACS, and 3 images of the lumbar region were formed: a sagittal plane image, a cross-sectional plane image, and a coronal plane image.

By removing the mouse symbol on 1 plane image of the 3D image of the lumbar region, the corresponding points on the other plane images were removed. The parameters of the study were measured in the following images: first, in the cross-sectional plane image the mouse symbol was used to focus on the DRG of the targeted nerve root. Second, the mouse symbol was adjusted in the coronal plane image for the whole nerve root to be demonstrated. Finally, the mouse symbol was removed and the sagittal plane image provided the mid-sagittal plane of pedicle.

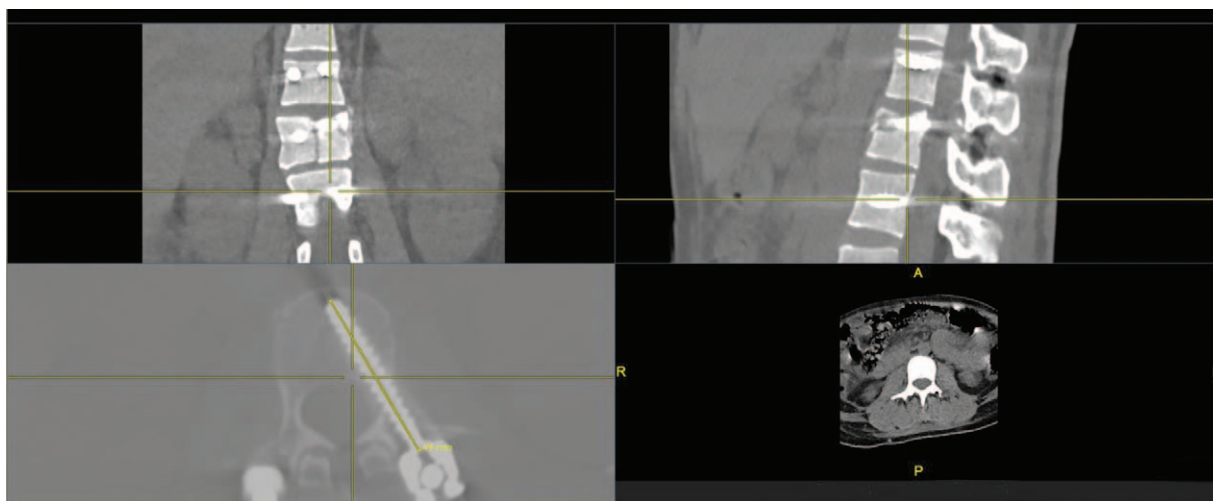
In summary, the following data were collected from the nerve roots of L4 and L5 during the study: the diameter of the DRG measured in the coronal image plane; the value of the preganglionic nerve root, which is the distance between the axilla of the root and the start of the dorsal root ganglion measured in the coronal plane; the distance between the inferior edge of the root and the superior edge of the pedicle measured in the sagittal image plane; at the level of the superior and inferior edge of the disc, the width of the targeted foramina measured in the sagittal image plane; and at the level of the superior and inferior edge of the disc, the distance between the nerve root and the dural sac measured in the coronal image plane (Fig. 1).

### 2.2. The study of magnification

Because all of the studied patients received PS fixation owing to thoracolumbar fractures, the actual lengths of the PS were known from the operative records. In order to determine the



**Figure 1.** The parameters of the relationship between the nerve root of the lower lumbar and the surrounding structures in patients without radiological degeneration: (1) the diameter of the DRG measured in the coronal image plane; (2) the value of the preganglionic nerve root measured in the coronal plane; (3) the distance between the inferior edge of the root and the superior edge of the pedicle measured in the sagittal image plane; (4) and (5) at the level of the superior and inferior edge of the disc, the width of the targeted foramina measured in the sagittal image plane; (6) and (7) at the level of the superior and inferior edge of the disc, the distance between the nerve root and the dural sac measured in the coronal image plane. DRG=dorsal root ganglion.



**Figure 2.** A cross-sectional plane image of postoperative digital images was selected in which the whole pedicle screw was demonstrated. Then, the longitudinal length of pedicle screw was measured in cross-sectional plane image.

magnification of the digital images, the magnification was calculated as the ratio of the pedicle screw length measured through analysis of the postoperative digital image relative to the actual pedicle screw length (Fig. 2). The average magnification obtained was applied in the study to measure the parameters.

### 2.3. The study of agreement

To assess the intraobserver agreement of the measurements, the value of the preganglionic nerve root measured in the coronal plane was evaluated repeatedly by the spinal surgeon. To assess the interobserver agreement of measurements, the value of the preganglionic nerve root measured in the coronal plane was evaluated repeatedly by an independent radiologist.

### 2.4. Statistical analysis

The data are presented as mean  $\pm$  standard deviation. One-sample *t* tests were used to compare the values of the preganglionic nerve root that were measured repeatedly. A difference of less than 2 mm was considered to be nonsignificant. All statistical analyses were performed using SPSS software. *P* values of less than 0.05 were considered significant.

### 2.5. Study part two

We enrolled a patient with lumbar disc herniation of the L4/5 level who had received PELD in our department in 2017. A preoperative 3D CT was constructed at the work station. The 3 images planes, which were mentioned previously (in the study part one section), were chosen by removing the mouse symbol. The difference was the choice of coronal plane image. In the part two, the coronal plane image was chosen in which the whole nerve root of L4 and the disc herniated of L4/5 can be demonstrated. Then, at the level of the superior and inferior edge of the disc, the width of the targeted foramina was measured in the sagittal image plane. At the level of the superior and inferior edge of the disc, the distance between the nerve root and the disc herniated was measured in the coronal image plane (Fig. 3).

## 3. Results

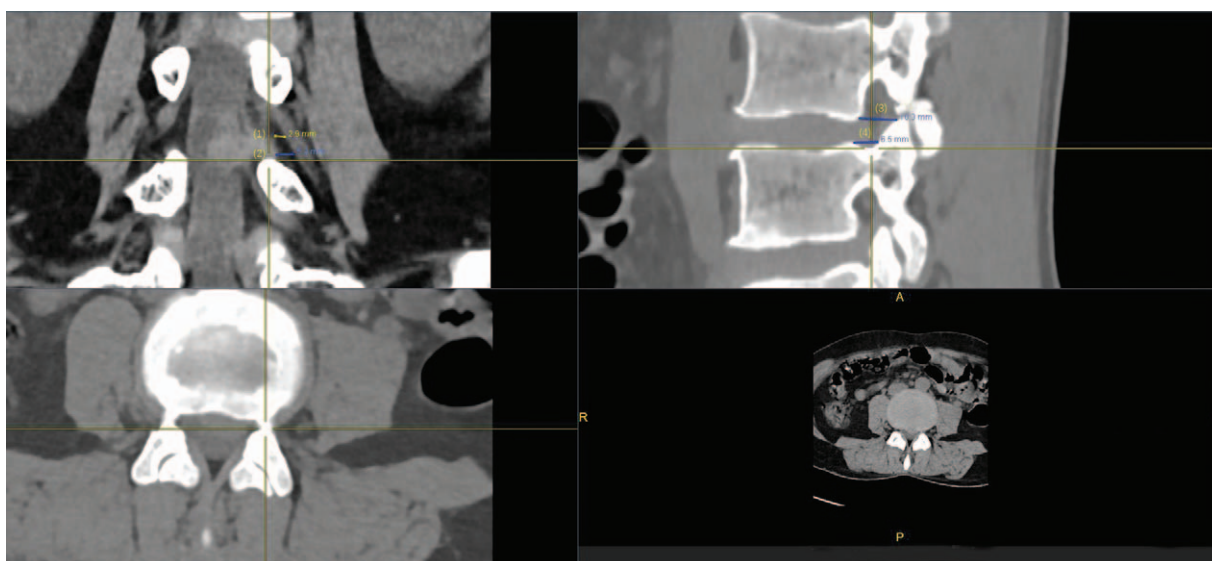
In part one of the study, the magnification was 1.037. To assess the intraobserver agreement of the measurements, we measured the difference in the value of the preganglionic nerve root measured in coronal plane repeatedly by the same doctor. The intraobserver difference was  $1.35 \pm 0.6$  mm. To assess the interobserver agreement of the measurements, we measured the value of the preganglionic nerve root measured in the coronal plane repeatedly by independent doctors. The interobserver difference was  $1.57 \pm 0.8$  mm. No significant difference was reported between the value of the preganglionic nerve root that were assessed for intraobserver agreement of the measurements and interobserver agreement of the measurements ( $P > .05$ ).

The findings of all measurements are shown in Table 1. The size of the DRG of the L4 was  $5.5 \pm 0.4$  mm on the right side and  $5.8 \pm 0.3$  mm on the left side. The size of the DRG of the L5 was  $6.1 \pm 0.5$  mm on the right side and  $5.7 \pm 0.4$  mm on the left side. The value of the preganglionic nerve root measured of the L4 was  $11.2 \pm 0.6$  mm on the right side and  $12.3 \pm 0.8$  mm on the left side. The value of preganglionic nerve root of the L5 was  $15.1 \pm 1.1$  mm on the right side and  $14.9 \pm 0.9$  mm on the left side. The distance between the inferior edge of the root and the superior edge of the pedicle of L4/5 measured in the sagittal image plane was  $10.2 \pm 0.8$  mm on the right side and  $9.8 \pm 0.9$  mm on the left side. The distance between the inferior edge of the root and the superior edge of the pedicle of L5/S1 measured in the sagittal image plane was  $10.3 \pm 0.7$  mm on the right side and  $10.5 \pm 1.0$  mm on the left side.

In part two of the study, at the level of the superior and inferior edge of the disc, the distance between the nerve root and the herniated disc was 2.9 mm and 5.2 mm in the coronal image plane.

## 4. Discussion

In the present study, attention was paid to the relationship between the nerve root of the L4 and L5 and the surrounding structures. This was because disc herniation most frequently occurs in the lower lumbar region, at the L4/5 and L5/S1 level. PELD was performed through the intervertebral foramen at the



**Figure 3.** The parameters of the relationship between the nerve root of the lower lumbar and the surrounding structures in patients with disc herniation. (1) and (2) at the level of the superior and inferior edge of the disc, the distance between the nerve root and the disc herniated were measured in the coronal image plane. (3) and (4) at the level of the superior and inferior edge of the disc, the width of the targeted foramina in the sagittal image plane were measured.

L4/5 and L5/S1 level. The patients enrolled in the current study did not experience radiology degeneration of the lower lumbar region. Therefore, in these patients, the anatomy of the lower lumbar region can be considered to be similar to that of a healthy population.

These results demonstrate that the size of the DRG is similar to the size measured in other studies that have used the MRI method<sup>[9]</sup> and the anatomical dissection method.<sup>[8]</sup> The value of the preganglionic nerve root measured at the L4 was  $11.2 \pm 0.6$  mm on the right side and  $12.3 \pm 0.8$  mm on the left side, and the value of preganglionic nerve root of the L5 was  $15.1 \pm 1.1$  mm on the right side and  $14.9 \pm 0.9$  mm on the left side. Due to the different nerves measured, the mean value of the L3 and the L4 nerve root was 7.95 mm in an article that used the anatomical dissection method in cadavers. However, the results of the present study are similar to that of another study that recorded measurements in fresh human cadavers, in which the value of the preganglionic nerve root of the L4 was  $12.30 \pm 4.24$  mm on the right side and  $11.40 \pm 2.70$  mm on the left side, and the value of the preganglionic nerve root of the L5 was  $16.0 \pm 3.39$  mm on the right side and  $16.50 \pm 3.58$  mm on the left side. Moreover, the study also conclude that the value of the preganglionic nerve root of the L5 is longer than that of the L4.

Most herniated discs are located at the same level of the intervertebral space. Therefore, at the level of the superior and inferior edge of the disc, the width of the targeted foramina, as measured in the sagittal image plane, and the distance between the nerve root and the dural sac, as measured in coronal image plane, constitute the space which is the main work area of the cannulae during PELD. This space allows for the introduction of the cannulae for posterolateral percutaneous procedures in the lumbar region. If the space is smaller than the cannulae, a larger foraminotomy may be necessary and a partial facetectomy may be needed to enlarge the space. Our results demonstrate that the space was always sufficient for cannulae insertion.

Although the height of the intervertebral foramen has been reported in many articles,<sup>[6,7]</sup> the distance between the inferior edge of the root and the superior edge of the pedicle, as measured in the sagittal image plane, was the effective height for PELD. The value of the L4/5 was  $10.2 \pm 0.8$  mm on the right side and  $9.8 \pm 0.9$  mm on the left side. The value of the L5/S1 was  $10.3 \pm 0.7$  mm on the right side and  $10.5 \pm 1.0$  mm on the left side.

Due to the different conditions between cadavers and living human beings, the use of the CT imaging method to describe the anatomy of the nerve roots in living humans is advantageous. Formalin fixed cadavers can display altered anatomic relation-

**Table 1**

**The results of the parameters measured using three dimensional computed tomography (3D CT).**

		The results of parameters measured on 3D CT							
		1	2	3	4	5	6	7	
L4	Right		$5.5 \pm 0.4$	$11.2 \pm 0.6$	$10.2 \pm 0.8$	$10.3 \pm 1.1$	$6.1 \pm 0.5$	$7.2 \pm 0.6$	$10.2 \pm 1.0$
	Left		$5.8 \pm 0.3$	$12.3 \pm 0.8$	$9.8 \pm 0.9$	$10.6 \pm 0.9$	$6.5 \pm 0.4$	$6.8 \pm 0.5$	$11.2 \pm 0.9$
L5	Right		$6.1 \pm 0.5$	$15.1 \pm 1.1$	$10.3 \pm 0.7$	$10.1 \pm 0.9$	$7.1 \pm 0.3$	$6.9 \pm 0.7$	$12.5 \pm 1.1$
	Left		$5.7 \pm 0.4$	$14.9 \pm 0.9$	$10.5 \pm 1.0$	$9.8 \pm 0.8$	$6.9 \pm 0.6$	$7.4 \pm 0.5$	$10.6 \pm 0.8$

3D CT = three-dimensional computed tomography.

(1) the diameter of the DRG (millimeter) (2) the distance of the axilla of the root to the start of the dorsal ganglion (millimeter) (3) the distance between the inferior edge of the root and superior edge of the pedicle (millimeter) (4) and (5) at the level of the superior and inferior edge of the disc, the width of the targeted foramina (millimeter) (6) and (7) at the level of the superior and inferior edge of the disc, the distance between the nerve root and the dural sac (millimeter)

ships due to the decreased tension within the tissues. In the present study, we researched the anatomical features using CT imaging instead of MRI, because 3D CT images can be constructed conveniently using the PACS. The 3D CT imaging method that was used in the present study is practical and convenient for use in the routine clinical work of spinal surgeons. This CT imaging method can be used to formulate the operation scheme for individual patients. Careful evaluation of the preoperative 3D CT findings provides the spatial relationships between the nerve root and the surrounding structures. In part two of the study we found that, at the level of the superior and inferior edge of the disc, the distance between the nerve root and the herniated disc can be evaluated in the coronal image plane, which can aid the spinal surgeon in further spatial assessment.

The weakness of this study is that the software that is provided in the PACS cannot rotate the image at all angles. Due to the lumbar lordosis, the nerve root lies obliquely at some degrees in the sagittal plane. In these cases, the measurement of the nerve root in relation to the surrounding structures has some error in the coronal plane.

In conclusion, the data regarding the relationship between the nerve root and the surrounding structures that were measured using the 3D CT imaging method were similar to those previously reported in published articles. Thus, the 3D CT imaging method provides a practical and convenient method that can be used in the routine clinical work of a spinal surgeon. The data obtained from the 3D CT imaging method will be helpful for surgeons in the future, allowing them to become more familiar with

correlating anatomical knowledge, especially for individual patients. Additionally, these findings may contribute to an increased success rate in spinal operations.

## References

- [1] Mirkovic SR, Schwartz DG, Glazier KD. Anatomic considerations in lumbar posterolateral percutaneous procedures. *Spine (Phila Pa 1976)* 1995;20:1965–71.
- [2] Teske W, Boudelal R, Zirke S, et al. Anatomical study of preganglionic spinal nerve and disc relation at different lumbar levels: special aspect for microscopic spine surgery. *Technol Health Care* 2015;23:343–50.
- [3] Hasegawa T, Mikawa Y, Watanabe R, et al. Morphometric analysis of the lumbosacral nerve roots and dorsal root ganglia by magnetic resonance imaging. *Spine (Phila Pa 1976)* 1996;21:1005–9.
- [4] Cohen MS, Wall EJ, Brown RA, et al. 1990 AcroMed Award in basic science. Cauda equina anatomy. II: Extrathecal nerve roots and dorsal root ganglia. *Spine (Phila Pa 1976)* 1990;15:1248–51.
- [5] Vialle E, Vialle LR, Contreras W, et al. Anatomical study on the relationship between the dorsal root ganglion and the intervertebral disc in the lumbar spine. *Rev Bras Ortop* 2015;50:450–4.
- [6] Torun F, Dolgun H, Tuna H, et al. Morphometric analysis of the roots and neural foramina of the lumbar vertebrae. *Surg Neurol* 2006;66: 148–51.
- [7] Arslan M, Comert A, Acar HI, et al. Nerve root to lumbar disc relationships at the intervertebral foramen from a surgical viewpoint: An anatomical study. *Clin Anat* 2012;25:218–23.
- [8] Silverstein MP, Romrell LJ, Benzel EC, et al. Lumbar dorsal root Ganglia location: an anatomic and MRI assessment. *Int J Spine Surg* 2015;9.
- [9] Shen J, Wang HY, Chen JY, et al. Morphologic analysis of normal human lumbar dorsal root ganglion by 3D MR imaging. *AJNR Am J Neuroradiol* 2006;27:2098–103.