

Received: 2018.12.14  
Accepted: 2019.03.29  
Published: 2019.07.19

# Clinical Effectiveness of Endoscopic Stent Placement in Treatment of Acute Intestinal Obstruction Caused by Colorectal Cancer

Authors' Contribution:  
Study Design A  
Data Collection B  
Statistical Analysis C  
Data Interpretation D  
Manuscript Preparation E  
Literature Search F  
Funds Collection G

ABCDE 1 **Yinghao Cao\***  
F 1 **Shenghe Deng\***  
B 1 **Junnan Gu\***  
A 1 **Jiang Li**  
B 1 **Ke Wu**  
C 2 **Hai Zheng**  
D 2 **Ping Cheng**  
F 2 **Jingxiang Zhang**  
F 2 **Gang Zhao**  
D 1 **Kaixiong Tao**  
F 1 **Guobing Wang**  
AEFG 1 **Kailin Cai**

1 Department of Gastrointestinal Surgery, Union Hospital, Tongji Medical College, Huazhong University of Science and Technology, Wuhan, Hubei, P.R. China  
2 Department of Emergency and Trauma Surgery, Union Hospital, Tongji Medical College, Huazhong University of Science and Technology, Wuhan, Hubei, P.R. China

**Corresponding Author:**  
**Source of support:**

\* Yinghao Cao, Shenghe Deng, and Junnan Gu contributed equally to this work and are considered co-first authors

Kailin Cai, e-mail: [caikailin@hust.edu.cn](mailto:caikailin@hust.edu.cn)

The Science and Technology Department of Hubei Province (No. 2018CFC884), Wu Jieping Medical Foundation of China (No. 320.2710.1843), and the Clinical Research Physician Program of Tongji Medical College, HUST

**Background:** Emergency endoscopic intestinal stenting has been applied with increasing frequency in colorectal cancer patients with acute intestinal obstruction. However, its clinical effectiveness as compared to emergency surgery remains controversial.





**Material/Methods:** The clinical data of 96 patients with acute intestinal obstruction caused by colorectal cancer from April 2012 to April 2018 were retrospectively collected. Statistical technique success rate, clinical success rate, operative time, average indwelling time of stent, complications, transition time to second-stage surgery, postoperative hospital stay, sputum rate, and postoperative infection rate were studied.

**Results:** Endoscopic colonoscopy was successfully performed in 94 patients. The success rate of stent placement was 97.9%, and the average operative time was 35 minutes (range, 25–85 minutes). Forty-two patients underwent stage I colectomy after relief of the obstruction. The average stent retention time was 7 days (range, 5–15 days). Two patients suffered from anastomotic infection. Their intestinal preparation time, hospital stay, fistula rate, and infection rate were lower than those of patients undergoing emergency operation for colon cancer intestinal obstruction. A total of 52 patients with colon cancer underwent palliative stent placement. Three patients had complications, including 1 case of stent displacement in the palliative care group and 2 cases with perforation in the bridge surgery group.

**Conclusions:** Emergency endoscopic placement of an intestinal stent is safe and effective in the treatment of patients with acute intestinal obstruction caused by colorectal cancer. It is also a safe and simple procedure for patients receiving advanced palliative treatment, which greatly improves their quality of life and is easy for patients' families to accept.

**MeSH Keywords:** **Endoscopy • Intestinal Obstruction • Palliative Care • Stents**

**Full-text PDF:** <https://www.medscimonit.com/abstract/index/idArt/914623>

 2522  2  3  17



## Background

Acute intestinal obstruction can result from conditions such as malignancy, adhesions, strangulated hernia, volvulus, inflammatory bowel disease, and phytobezoars, and cases arising from colorectal cancer occur in a considerable proportion of patients, accounting for clinical manifestations in 7–29% of cases [1–3]. In fact, intestinal obstruction due to colorectal cancer is a clinical emergency, which can quickly lead to progression of the disease. If left untreated, the mortality rate can reach as high as 30% [4–6]. Therefore, the key to alleviating the crisis is to quickly and effectively eliminate the intestinal obstruction.

The traditional treatment methods include one-stage resection plus fistula for obstructive patients, and permanent fistula palliative treatment for patients with unresectable tumors. With the development of endoscopy and minimally invasive technology, one-stage radical resection or conservative treatment after intestinal stent implantation has been increasingly used in the treatment of colorectal cancer patients presenting with acute intestinal obstruction. As a prelude to one-stage surgical resection or conservative treatment, placement of a self-expanding metal stent (SEMS) can effectively relieve obstruction in the case of acute obstruction [7] and can change the emergency operation to a limited operation to reduce the rate of fistula. Because of the improvement in body condition and increase in the intestinal anastomosis rate, it can reduce the mortality rate and the incidence of overall complications [8]. However, its clinical effectiveness as compared to emergency surgery remains debatable.

In this retrospective study, we assessed the clinical effectiveness of endoscopic colon stenting in the treatment of patients with acute intestinal obstruction arising from colorectal cancer.

## Material and Methods

### Patients

This study was approved by the Ethics Committee of Tongji Medical College, Huazhong University of Science and Technology (No. 2018-S377, dated 11 July 2018) and all patients signed an informed consent to participate. Data for 96 patients with acute intestinal obstruction caused by colorectal cancer between April 2012 and April 2018 were retrospectively collected and reviewed, and of these patients, 94 underwent endoscopic colon stenting. The inclusion criteria used in this study were as follows: (1) abdominal CT imaging revealed irregular thickening of the intestinal wall, dilatation of proximal lumen, and unusual air/gas; (2) colonoscopy was not able to pass through the narrow segment; (3) at least 3 symptoms, including pain,

vomiting, and distention, were present; and (4) willingness to sign an informed consent form. Patients with the following conditions were excluded from the study: (1) psychiatric disorders; (2) severe cardiovascular and cerebrovascular diseases; (3) bowel obstruction with perforation; (4) high risk factors for undergoing colonoscopy; and (5) unwillingness to sign the informed consent form.

Among the 94 patients, 42 cases were selected for surgery after obstructive symptoms gradually resolved, and 52 cases were treated conservatively. Thus, the patients with intestinal obstruction due to colon cancer were divided into 2 groups: a bridge to surgery group and a palliative treatment group. The bridge to surgery group included 42 cases in which colonic stenting was used as transitional therapy, and stage I resection of colon cancer was subsequently performed after removal of the obstruction. The 52 patients in the palliative care group were not scheduled for radical operation due to organ dysfunction or multiple metastases, but colonic stenting was used as palliative treatment to relieve obstruction and improve quality of life.

Another group of 67 patients who underwent emergency surgery during the same period consisted of cases with intestinal obstruction due to colorectal cancer. In this group, 41 males and 26 females, aged 27–87 years, with an average age of 58.4 years, were treated with radical operation within the same period. All patients were admitted to the hospital with cessation of defecation and venting before surgery, and emergency CT showed proximal intestinal dilatation and limited intestinal space.

### Instruments and materials

The guide wire was from Boston Scientific (Hydra Jagwire, diameter 0.035 in, length 450 cm), the stent was from Wilson Cook (Nanjing Minimally Invasive Company), and the colonoscopy was an Olympus PCF-Q260AI.

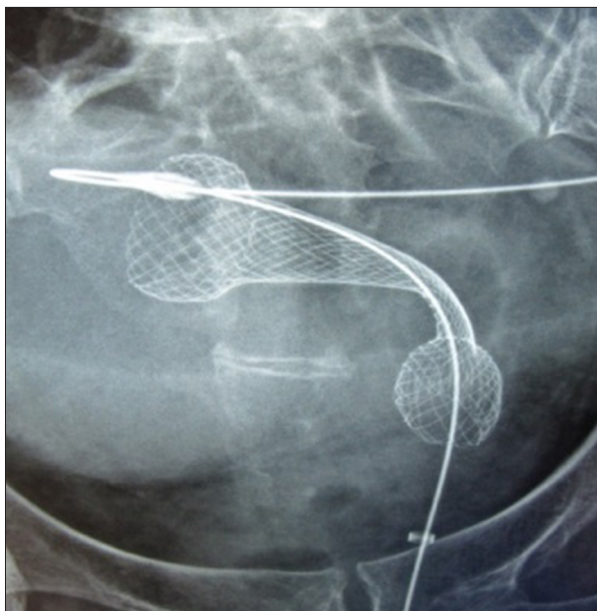
### Colonoscopic stenting procedure

#### Preoperative preparation

Before the operation, patients were treated with fasting, gastrointestinal decompression, rehydration to correct water and electrolyte disorders and to improve the general condition of patients, as well as a glycerin enema or saline to clean enema.

#### Surgical procedures

The patient was placed in supine position, monitored by electrocardiography (ECG), monitored for oxygen saturation, and routinely inhaled. A self-expanding nickel titanium alloy stent

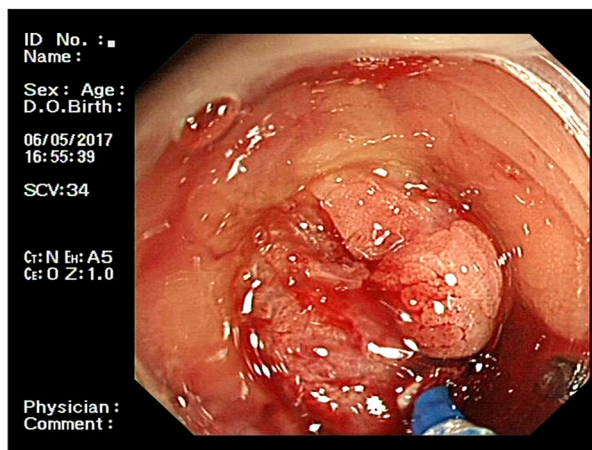

**Figure 1.** Fluoroscopic image of implantation of self-expanding metal stent for acute intestinal obstruction caused by colorectal cancer. A self-expanding metal stent was guided to the narrowing segment and implanted in the colon, as visualized under fluoroscopy.

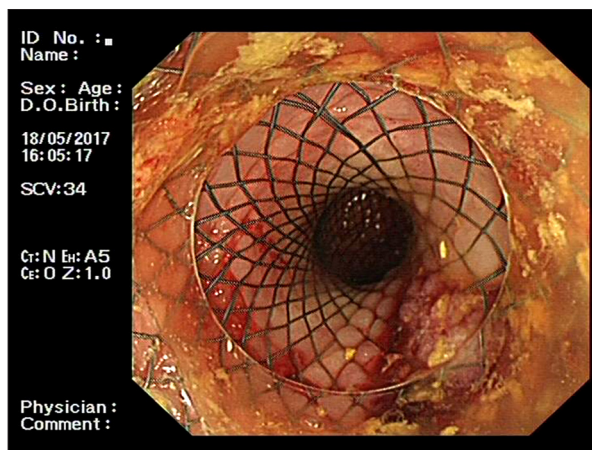was used. Both ends were horn openings; the middle section was cylindrical, 18–30 mm in diameter; and the length was at least 2.0 cm longer than the 2 ends of the lesion. Stent placement was performed by an experienced endoscopist, and a titanium clip was placed over the distal stenosis as a marker under colonoscopy at first. The guide wire was inserted along the colonoscope, and the catheter was inserted through the guide wire through the narrow part under X-ray surveillance. After the stenosis was injected with contrast agent (80–100 mL), the length of the narrow segment was observed under fluoroscopy (Figure 1). The contrast catheter was removed, and a stent pusher was inserted through the guide wire under X-ray monitoring, so that the front end of the stent was more than 2 cm beyond the proximal end of the obstruction. The position of the stent was adjusted according to the metal marking under the X-ray. As shown in Figures 2 and 3, a representative case with accurate intestinal obstruction caused by colorectal cancer was treated with the self-expanding metal stent placement. The implanted stent was expanded and remained in place in the colon. During the operation, special attention was given to the patient's vital signs and bloating to avoid intestinal perforation or intestinal bleeding.

#### Postoperative management

Abdominal X-ray examination was performed 24 h after the operation to confirm stent placement and the expansion. After the obstruction was relieved, the gastrointestinal decompression tube



**Figure 2.** Endoscopic view of the intestinal obstruction caused by colorectal cancer. Endoscopic examination revealed intestinal obstruction due to colorectal cancer.



**Figure 3.** Endoscopic view of a stent placed for the treatment of acute intestinal obstruction due to colorectal cancer. The implanted metal stent was expanded and remained in place in the colon.

could be removed, and a liquid diet was given before semi-liquid food could be gradually introduced. Patients who needed radical surgery could be temporarily discharged from the hospital. After 5–15 days, the patient was then admitted to the hospital for surgical treatment. Patients who were identified as unsuitable for surgery were followed up regularly by abdominal plain film, barium enema, or colonoscopy. In addition, the period of follow-up after the stent placement ranged from 6 to 60 months in the study patients, with averages follow-ups of 36 months in the bridge surgery group, 16 months in the palliative care group, and 30 months in the emergency operation group.

#### Statistical analysis

All data were analyzed using the statistical package SPSS version 23.0. All measurement data were represented as  $(\bar{x} \pm s)$ .

**Table 1.** Evaluation of colon stent effectiveness.

Group	Cases (n)	Success rate (n=%)	Complication (n=%)	
			Perforation	Displacement
Palliative care group	54	52 (96.3)	2 (3.7)	0 (0)
Bridge to surgery group	42	42 (100)	0 (0)	1 (2.4)
Total	96	94 (97.9)	3 (3.1)	

**Table 2.** Comparison of different treatments for intestinal obstruction.

Group	Cases (n)	Postoperative hospital stay ( $\bar{x} \pm s.d$ )	Stoma rate (n=%)	Postoperative infection rate (n=%)
Bridge to surgery group	42	12.5±2.3	9 (21.4)	2 (4.8)
Emergency operation group	67	15.9±4.6	37 (55.2)	8 (11.9)
P		P<0.01	P<0.01	P<0.01

The paired *t* test was used in the group, and analysis of variance (ANOVA) was used in the group. The count data were expressed in percentage (%), the data were processed by chi-square test, and *P* <0.05 was considered statistically significant.

## Results

### Demographic and clinical characteristics of the study patients

A total of 94 patients with acute intestinal obstruction due to colorectal cancer underwent endoscopic colon stenting during the study period, including 48 males and 46 females. The age of the study patients ranged from 30 to 83 years. Obstruction occurred in the transverse colon (n=7, 7.4%), descending colon (n=21, 22.3%), sigmoid colon (n=25, 26.6%), rectum (n=20, 21.3%), ascending colon (n=7, 7.4%), hepatic flexure (n=7, 7.4%), and splenic flexure (n=7, 7.4%).

### Assessment of clinical effectiveness of endoscopic colonic stenting

Of the patients who were scheduled for endoscopic colon stenting, the technical success rate was 97.9% (94/96). Stent implantation could not be completed in 2 cases due to poor bowel preparation, resulting in inability of the colonoscope to reach the obstruction site during the operation. The releaser failed in 1 patient during the first attempt at stent implantation, but technical success was achieved after the releaser was replaced. The average operation time was 35 min (range, 25–85 min) under single colonoscopy.

### Analysis of post-procedure complications

The 94 patients in whom a stent was successfully placed achieved clinical resolution of the obstruction-related symptoms following the procedure. The stent-associated complications were reported as follows: two patients who underwent stent implantation had not flatus or defecated for 3 days following the procedure, and abdominal pain was aggravated. The abdominal plain film indicated that there was subdiaphragm free air; therefore, an emergency operation was performed. Stent displacement happened in one patient 5 days after the the endoscopic procedure, and the other patients had good stent expansion and excreted a large amount of feces. The abdominal pain and distension of the patients were considerably relieved, and they began to take water on the next day after the procedure. Except for two cases of colon perforation and one case of displacement, no other complications such as gastrointestinal bleeding or abdominal pain were observed. As shown in Table 1, a total of 42 patients were selected for radical surgery after relief of obstruction symptoms, while the other 52 patients received conservative treatment. The patients with colon perforation after stent implantation, was treated with two-stage radical surgery.

We compared outcomes of different treatments for intestinal obstruction due to colorectal cancer. As shown in Table 2, the postoperative infection rate was 4.8% in the bridge surgery group, which was significantly lower than the rate of 11.9% in the emergency operation group (*P*<0.01). The duration of postoperative hospitalization was significantly shorter in the bridge surgery group than in the emergency operation group (12.5 vs. 15.9 days, *P*<0.01). The stoma rate was 21.4% in the

bridge surgery group, which was significantly lower than the 55.2% in the emergency operation group ( $P < 0.01$ ).

## Discussion

Colorectal cancer is a common malignancy in China and many other countries around the world, with older age and lifestyle factors largely contributing to the etiology. With the change in dietary structure, the growing prevalence of obesity, and smoking, the incidence of colorectal cancer continues to rise. Colorectal cancer is commonly accompanied by acute intestinal obstruction, and the overall condition is poor in patients with acute intestinal obstruction. These patients can experience conditions such as dehydration, anemia, metabolic disorders, malnutrition, and acid-base imbalance. Selective primary resection is the treatment of choice for non-obstructive colon cancer, and emergency surgery for acute colonic obstruction has high morbidity and mortality rates [9]. Moreover, when there is acute intestinal obstruction secondary to colon cancer, it is difficult for the quality of the operation to meet the standards for a normal operation. For example, the total number of lymph nodes dissected was significantly less than that in a limited operation, possibly due to difficulties in the emergency surgery resulting from severe distention in the intestinal tract and surrounding areas, in combination with abnormal coagulation function in patients with acute intestinal obstruction. To reduce the risk of anastomotic leakage, temporary diversion of feces, such as with a temporary ostomy, can be used during the operation. The rate of permanent colostomy significantly increases because a lot of factors could impair the returning of the colostomy. These problems have greatly reduced the quality of life and increased the cost of colon cancer. Many studies have demonstrated the safety and efficacy of SEMS placement in the treatment of malignant obstruction caused by colorectal cancer as a transitional procedure and palliative treatment [10,11].

Regarding the success rate of stent placement, Ho et al. indicated that surgeon familiarity with stent deployment systems is critical to technical success [12,13]. In our study, the success rate of stent placement was 97.3%, and the clinical success rate was 94.3%, which is similar to those in other studies [14]. We believe that familiarity with the stent is an important factor in improving the success rate of the technique, but the surgeon's skill and operational experience in placing the stent may be more important. Guidelines from the European Society of Gastroenteroscopy recommend that colon stent placement for malignant colonic obstruction should be performed or supervised directly by an experienced professional technician who has performed at least 20 colon stent placement operations [15]. In China, where there are many patients with colon cancer and obstruction, the endoscopist in this study has

performed more than 25 colon stent placements per year before the first case enrolled.

The optimal time for surgery after stent placement is still controversial [13,15]. Sahebally et al. performed selective surgery at an average of  $79.6 \pm 64.3$  days after SEMS insertion [16]. Ho et al. reported that a 2-week interval can completely decompress and resolve tissue edema. In our study, we started surgery 5–15 days after insertion of the stent. At that time, only mild edema of the intestine was found during the operation, and the excessive expansion of the intestine was not found, which ensured clear vision in the surgical field and facilitated performance of the operation. Of the 42 patients who underwent selective surgery, 32 underwent total laparoscopic tumor resection, 8 underwent laparotomy, and 2 underwent open surgery. Overall, 33 patients underwent primary anastomosis, and 9 patients underwent colectomy with anastomosis and protective ileostomy. Of the 67 patients who underwent emergency surgery in the same period, 30 patients underwent primary anastomosis, 37 patients underwent protective ileostomy, and 8 patients developed postoperative anastomotic leakage, bleeding, and other related complications. For the patients without colon perforation in this study, at an average of 7 days (range, 5–15 days) following the stent placement, we performed the second operation. On the basis of our findings, a minimum of 1 week after the stent placement is recommended regarding the timing of the operation after the stenting.

In addition, 52 patients in this study received a colonic stent as palliative care along with radiotherapy, chemotherapy, or supportive care. Relevant studies showed that the long-term survival rate with palliative treatment with colon stenting was similar to that achieved by surgical treatment, with a shorter median hospital stay, fewer complications, less trauma and pain, avoidance of enterostomy, improvement of quality of life, and easy acceptance by patients [17].

Although the clinical advantage of stenting compared with emergency surgery are obvious, the complications are still high, including perforation, displacement, re-obstruction, etc.; colon perforation is the most worrisome. Once a large amount of intestinal content leaks into the abdominal cavity, it will usually result in severe peritonitis. The signs of peritonitis may be less obvious in patients with small perforation inside the stented section of the colon, but the patient may have toxic shock when the perforation occurred at the upward side of the stent which can lead to death. Two patients had perforation in 3 days after stent implantation, and an emergency operation was performed. Stent reobstruction occurred in 1 patient due to migration, on day 19 and the patient underwent a successful second stenting with relief of bowel obstruction.

## Conclusions

Our results demonstrate that emergency endoscopic placement of intestinal stents for acute intestinal obstruction caused by colorectal cancer is safe and effective. The advantages include a good curative effect, minimal trauma, a simple procedure, and few adverse effects. In addition, this treatment can significantly reduce the mortality and the risk of stoma. It is also

a safe and simple treatment for patients receiving advanced palliative treatment, which greatly improves their quality of life and is easily accepted by both patients and their families.

## Conflict of interest

None.

## References:

1. Lee HJ, Hong SP, Cheon JH et al: Long-term outcome of palliative therapy for malignant colorectal obstruction in patients with unresectable metastatic colorectal cancers: endoscopic stenting versus surgery. *Gastrointest Endosc*, 2011; 73: 535–42
2. Ahn HJ, Kim SW, Lee SW et al: Long-term outcomes of palliation for unresectable colorectal cancer obstruction in patients with good performance status: Endoscopic stent versus surgery. *Surg Endosc*, 2016; 30: 4765–75
3. Işık A, Firat AD, Peker K et al: How could such a wide piece of tree root pass through the narrow pyloric orifice? An extremely rare case. *Am J Case Rep*, 2014, 15: 284–87
4. Deans GT, Krukowski ZH, Irwin ST: Malignant obstruction of the left colon. *Br J Surg*, 1994; 81(9): 1270–76
5. Waldron RP, Donovan IA, Drumm J et al: Emergency presentation and mortality from colorectal cancer in the elderly. *Br J Surg*, 1986; 73(3): 214–16
6. Kyllönen LE: Obstruction and perforation complicating colorectal carcinoma. An epidemiologic and clinical study with special reference to incidence and survival. *Acta Chir Scand*, 1987; 153(10): 607–14
7. van Hooft JE, Fockens P, Marinelli AW et al: Early closure of a multicenter randomized clinical trial of endoscopic stenting versus surgery for stage IV left-sided colorectal cancer. *Endoscopy*, 2008; 40: 184–91
8. Khot UP, Lang AW, Murali K, Parker MC: Systematic review of the efficacy and safety of colorectal stents. *Br J Surg*, 2002; 89: 1096–102
9. Datye A, Hersh J: Colonic perforation after stent placement for malignant colorectal obstruction – causes and contributing factors. *Minim Invasive Ther Allied Technol*, 2011; 20: 133–40
10. Watt AM, Faragher IG, Griffin TT et al: Self-expanding metallic stents for relieving malignant colorectal obstruction: A systematic review. *Ann Surg*, 2007; 246: 24–30
11. Zhang Y, Shi J, Shi B et al: Self-expanding metallic stent as a bridge to surgery versus emergency surgery for obstructive colorectal cancer: A meta-analysis. *Surg Endosc*, 2012; 26: 110–19
12. Datye A1, Hersh J: Colonic perforation after stent placement for malignant colorectal obstruction – causes and contributing factors. *Minim Invasive Ther Allied Technol*, 2011; 20: 133–40
13. Ho KM, Chan KM, Kwok SY et al: Colonic self-expanding metal stent (SEMS) as a bridge to surgery in left-sided malignant colonic obstruction: An 8-year review. *Surg Endosc*, 2017; 31(5): 2255–62
14. Watt AM, Faragher IG, Griffin TT et al: Self-expanding metallic stents for relieving malignant colorectal obstruction: A systematic review. *Ann Surg*, 2007; 246(1): 24–30
15. van Hooft JE, van Halsema EE, Vanbiervliet G et al: Self-expandable metal stents for obstructing colonic and extracolonic cancer: European Society of Gastrointestinal Endoscopy (ESGE) Clinical Guideline. *Endoscopy*, 2014; 46(11): 990–1053
16. Sahebally SM, Sarwar A, Cooke F: Short-term outcomes following the use of self-expanding metallic stents in acute malignant colonic obstruction – a single-centre experience. *Int J Surg*, 2014; 12(11): 1198–202
17. Faragher IG, Chaitowitz IM, Stupart DA: Long-term results of palliative stenting or surgery for incurable obstructing colon cancer. *Colorectal Dis*, 2008; 10(7): 668–72