

# Successful treatment of thyroid storm presenting as recurrent cardiac arrest and subsequent multiorgan failure by continuous renal replacement therapy

Han Soo Park<sup>1</sup>, Su Kyoung Kwon<sup>1</sup> and Ye Na Kim<sup>2</sup>

<sup>1</sup>Department of Internal Medicine, Division of Endocrinology and Metabolism, and <sup>2</sup>Division of Nephrology, Kosin University College of Medicine, Busan, Republic of Korea

Correspondence should be addressed to S K Kwon  
**Email**  
mir316@naver.com

## Summary

Thyroid storm is a rare and potentially life-threatening medical emergency. We experienced a case of thyroid storm associated with sepsis caused by pneumonia, which had a catastrophic course including recurrent cardiac arrest and subsequent multiple organ failure (MOF). A 22-year-old female patient with a 10-year history of Graves' disease was transferred to our emergency department (ED). She had a cardiac arrest at her home and a second cardiac arrest at the ED. Her heart recovered after 20 min of cardiac resuscitation. She was diagnosed with thyroid storm associated with hyperthyroidism complicated by pneumonia and sepsis. Although full conventional medical treatment was given, she had progressive MOF and hemodynamic instability consisting of hyperthermia, tachycardia and hypotension. Because of hepatic and renal failure with refractory hypotension, we reduced the patient's dose of beta-blocker and antithyroid drug, and she was started on continuous veno-venous renal replacement therapy (CRRT) with intravenous albumin and plasma supplementation. Subsequently, her body temperature and pulse rate began to stabilize within 1 h, and her blood pressure reached 120/60 mmHg after 6 h. We discontinued antithyroid drug 3 days after admission because of aggravated hyperbilirubinemia. The patient exhibited progressive improvement in thyroid function even after cessation of antithyroid drug, and she successfully recovered from thyroid storm and MOF. This is the first case of thyroid storm successfully treated by CRRT in a patient considered unfit for antithyroid drug treatment.

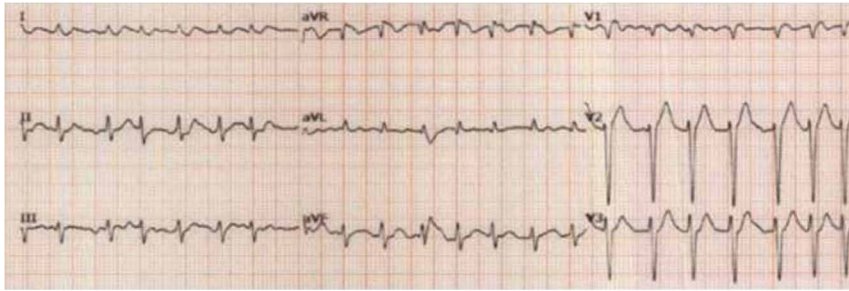
## Learning points:

- The presenting manifestations of thyroid storm vary and can include cardiac arrest with multiorgan failure in rare cases.
- In some patients with thyroid storm, especially those with severe complications, conventional medical treatment may be ineffective or inappropriate.
- During thyroid storm, the initiation of CRRT can immediately lower body temperature and subsequently stabilize vital signs.
- Early initiation of CRRT can be life-saving in patients with thyroid storm complicated by MOF, even when used in combination with suboptimal medical treatment.

## Background

Thyroid storm is a rare and potentially life-threatening medical emergency. The presenting manifestations of thyroid storm are varied, and some cases may go

unrecognized at first. Therefore, prompt recognition and proper treatment of thyroid storm is fundamental to saving patients with condition (1). In this report,



**Figure 1**  
Electrocardiogram (ECG). ECG showing atrial fibrillation with rapid ventricular response immediately after cardiac resuscitation.

we describe our experience with a rare case of thyroid storm that presented as recurrent cardiac arrest with subsequent multiple organ failure (MOF) and was successfully treated with continuous veno-venous renal replacement therapy (CRRT).

### Case presentation

A 22-year-old female patient was transferred to our hospital for a cardiac arrest after a history of several days of dyspnea. The patient had a cardiac arrest at her home just after the arrival of emergency medical technicians and recovered after cardiac resuscitation. She had a second cardiac arrest immediately after arriving at the emergency department (ED) and recovered again after 20min of cardiac resuscitation. Her husband indicated

she had a 10-year history of hyperthyroidism and irregular adherence to medication, and she suffered from symptoms of cough, fever and anorexia about 1 week and dyspnea for 2 days.

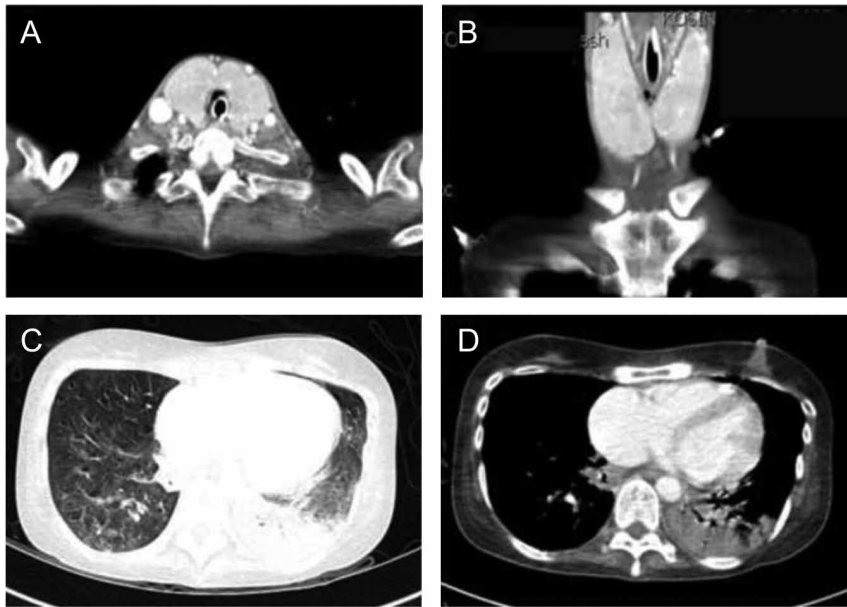
### Investigation

On initial assessment after cardiac resuscitation, her body temperature was 38.5°C, heart rate was 180beats/min (Fig. 1) and blood pressure was 80/40mmHg. Findings on physical examination revealed anterior neck swelling and rales in the area of the left lower lung.

Initial biochemical tests showed neutrophilia with thrombocytopenia, elevated total bilirubin, aspartate aminotransferase (AST), alanine aminotransferase (ALT) and evidence of coagulopathy. Blood tests

**Table 1** Summary of laboratory results.

Laboratory test	Reference value	At arrival	Day 1	Day 2
Urea (mg/dL)	5–23	24	21	18
Creatinine (mg/dL)	0.5–1.1	0.88	0.65	0.35
Sodium (mEq/L)	136–150	133	138	132
Potassium (mEq/L)	3.5–5.3	4.0	3.8	5.0
Albumin (g/dL)	3.5–5.0	2.1	2.5	3.1
Bilirubin (mg/dL)	0.2–1.2	3.61	7.9	11.8
Aspartate aminotransferase (U/L)	5–40	390	493	180
Alanine aminotransferase (U/L)	5–40	315	192	123
Alkaline phosphatase (U/L)	25–100	205		
Lactate dehydrogenase (U/L)	200–450	1932		
Prothrombin time (s)	11–15	27.1	33.5	35.5
Activated partial thromboplastin time (s)	27–45	43.2	50.3	180
International normalized ratio (INR)	0.8–1.2	2.57	3.39	2.86
pH	7.35–7.45	7.24	7.377	7.311
Bicarbonate (mmol/L)	20–29	21.9	31.8	26.9
pCO <sub>2</sub> (mmHg)	35–45	51	55.4	52.1
White blood cells (×10 <sup>9</sup> /L)	43–9.4	2.57	3.09	1.36
Hemoglobin (g/dL)	12–14	13.1	11.7	7.9
Platelet count (×10 <sup>9</sup> /L)		188	80	34
Culture				
Sputum		Streptococcus agalactiae, Candida albicans		
Urine		Escherichia coli		
Blood		Streptococcus agalactiae		

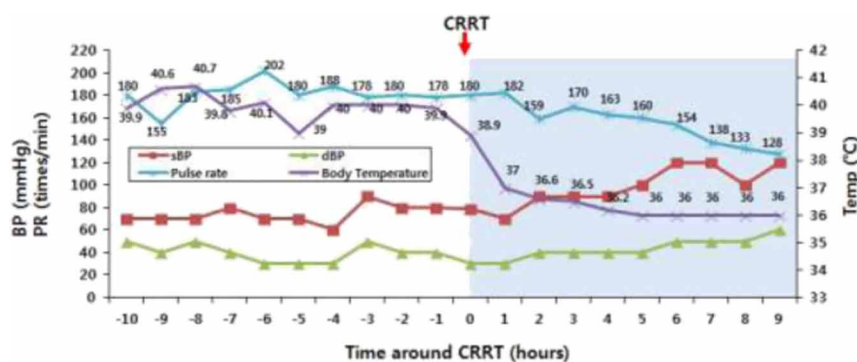


**Figure 2**  
Computed tomography (CT) scan of the neck and chest. Neck CT scan showing diffuse enlargement of the thyroid gland (A and B). Chest CT scan showing diffuse ground glass opacities (C) and dense peribronchial consolidation (D) mainly involving the left lobe of the lung.

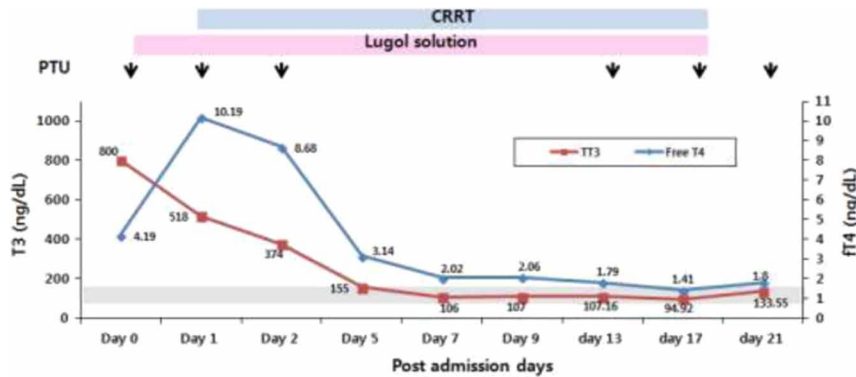
for thyroid function were as follows: free thyroxine (FT4): 4.19 ng/dL (reference value: 0.78–1.54 ng/dL), triiodothyronine (T3) >800 ng/dL (reference value: 65–150 ng/dL) and thyroid-stimulating hormone (TSH): 0.007  $\mu$ U/mL (reference value: 0.55–4.78  $\mu$ U/mL). Detailed laboratory data were presented as a table (Table 1). She had no history of alcohol intake, drug abuse, blood transfusion or exposure to hepatitis A, B or C. Extrahepatic obstruction was ruled out with an abdominal computed tomography (CT) scan. Chest CT scan revealed peribronchial consolidation of the left lung and diffuse enlargement of the thyroid (Fig. 2). Echocardiography revealed normal-sized cardiac chambers and preserved left ventricular systolic function with moderate pulmonary hypertension. The patient had a Burch and Wartofsky score of 110/140, which is highly suggestive of thyroid storm (2) and was finally diagnosed with thyroid storm complicated by pneumonia and sepsis.

## Treatment

The patient was provided with prompt and full conventional medical treatment for thyroid storm (oral propylthiouracil, Lugol solution, intravenous beta-blocker and steroids) after emergent cardiac resuscitation and was given general supportive management (intravenous propacetamol, hydration, antibiotics and dopamine and norepinephrine); however, the patient had sustained tachycardia, hyperpyrexia and progressive multiorgan dysfunction including acute liver failure, coagulopathy, heart failure and rapid deterioration of renal function. Because of progressive hepatic dysfunction and refractory hypotension below 70/40 mmHg, we reduced the patient's dose of beta-blocker and propylthiouracil and prepared her for therapeutic plasma exchange (TPE) for rapid direct removal of thyroid hormones (1). However, prior to initiating TPE, we started her on veno-venous CRRT with intravenous albumin and plasma supplementation for treatment of sepsis and acute renal failure as defined by urine output criteria of anuria over 6 h (3). After initiation of



**Figure 3**  
Vital signs before and after continuous renal replacement treatment (CRRT). The blue shadow represents the period after initiation of CRRT. Body temperature began to decrease abruptly after CRRT. Two hours after starting CRRT, systolic and diastolic pressure increased, pulse rates decreased progressively and body temperature stabilized.



**Figure 4**  
Changes in free T4 and total T3 profiles during the acute treatment period. The gray shadow represents the normal range. The black arrows indicate the days when antithyroid drug was administered. The pink and blue shadows indicate when Lugol solution and CRRT were administered respectively. Antithyroid drug (PTU) was stopped 4 days after initiation because of progressive elevation of bilirubin levels. During the days without antithyroid drug therapy, free T4 and total T3 levels were successfully controlled by CRRT combined with Lugol solution.

CRRT, her body temperature and pulse rate began to stabilize within 1 h, and her blood pressure increased to 100/60 mmHg 2 h later and 120/60 mmHg within 6 h (Fig. 3). Serum levels of triiodothyronine (T3) and alanine aminotransferase examined the following day showed moderate improvement, but her serum bilirubin level and aspartate aminotransferase (AST) remained elevated. In response, we reduced oral propylthiouracil from 200 mg every 6 h to 100 mg every 8 h on post-admission day 2 and stopped this treatment 3 days after admission because of aggravated hyperbilirubinemia and concerns regarding hepatic dysfunction. The patient exhibited progressive improvement of thyroid function even after cessation of propylthiouracil and successfully recovered from hyperthyroxinemia and hepatic dysfunction without TPE (Figs 4 and 5). We restarted antithyroid drug 13 days after admission.

### Outcome and follow-up

The patient was discharged from the hospital with alert mental status and normal renal and liver function tests and coagulation parameters 1 month after admission.

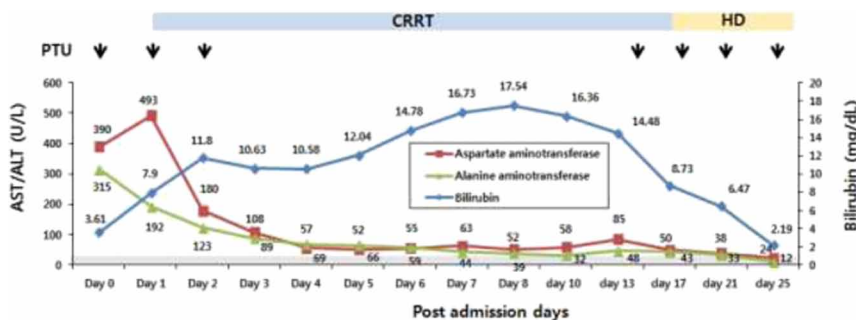
### Discussion

Thyroid storm is a potentially fatal disease with a reported hospital mortality rate of 10–75% (1). The laboratory

results for thyroid function during thyroid storm are not significantly different from those associated with thyrotoxicosis. Therefore, the diagnosis of thyroid storm is predominantly based on clinical manifestations including fever, cardiovascular dysfunction, gastrointestinal dysfunction and change in mental status, and clinical suspicion is essential for the diagnosis (2).

There have been several reports of unusual presentations of thyroid storm, including status epilepticus, complete heart block, rhabdomyolysis, stroke and MOF (4). In this case, the patient presented with recurrent cardiac arrest and subsequent MOF in the background of sepsis associated with pneumonia, which is an extremely rare presentation.

The patient in our case had refractory hyperthermia, tachycardia and other clinical deteriorations despite appropriate medical care for several hours. Plasmapheresis and TPE are alternative therapies for direct removal of free and protein-bound thyroid hormones, cytokines and autoantibodies used for severe cases of thyroid storm that are not effectively treated with antithyroid drugs alone or in patients unable to take antithyroid drugs because of hepatic dysfunction or medication side effects (5). Dialysis is generally regarded as ineffective for the removal of thyroid hormones because thyroid hormones are bound to plasma proteins; however, peritoneal dialysis (6), hemoperfusion through a resin (7) or charcoal



**Figure 5**  
Changes in liver function profile during treatment. The gray shadow represents the normal range. The black arrows indicate the days when antithyroid drug was administered. The blue and orange shadows indicate when CRRT and hemodialysis (HD) were administered respectively. Progressive elevation of bilirubin levels was observed.





column (8) and albumin dialysis (9) have shown some clinical benefits.

There have been no clinical reports describing improvement of thyroid storm with CRRT when it was not combined with TPE in patients unfit for antithyroid drug treatment. In the present case, we initiated CRRT before TPE because of the onset of acute kidney injury. Compared to intermittent hemodialysis, CRRT involves continuous dialysis and filtration over 24 h to facilitate slower removal of fluid and solute, which is better tolerated and results in fewer metabolic changes with improved removal of solute and immunomodulatory substances in critically ill patients. Therefore, CRRT is preferred to renal replacement therapy for hemodynamically unstable patients (10).

Prior to CRRT, the patient was treated with IV propacetamol and external cooling with an ice blanket and repeated alcohol swabs for several hours; however, her body temperature did not respond and remained between 39°C and 40°C for 10 h after admission. The most striking change after initiation of CRRT was rapid control of body temperature, which was accompanied by a slowed pulse rate and elevation of blood pressure (Fig. 3). The exact mechanism for the clinical improvement achieved by CRRT in this case is unclear; however, two possible mechanisms can be suggested. First, CRRT utilizes large volumes room-temperature fluids comprising dialysate and replacement fluids, and their administration can cause hypothermia. This well-known adverse effect of large volumes room-temperature fluids may have been useful for treating the patient's hyperthermia. Second, intravenous infusion of albumin and plasma in CRRT can increase the ability of proteins to bind free thyroid hormone (5). Given these possibilities, further investigation regarding the effects and prompt initiation of CRRT in hemodynamically unstable thyrotoxicosis is needed.

In conclusion, this is the first case of thyroid storm successfully treated by CRRT not combined with TPE in a patient unfit for full dosing with antithyroid drug without surgery. Furthermore, our patient had a rare and severe presentation of thyroid storm involving repeated cardiac arrest and subsequent multiorgan dysfunction that was treated successfully. Our experience suggests that prompt recognition of thyroid storm and early initiation of CRRT combined with conventional medical treatment may be a useful approach when

treating patients with thyroid storm associated with hemodynamically unstable MOF.

#### Declaration of interest

The authors declare that there is no conflict of interest that could be perceived as prejudicing the impartiality of the research reported.

#### Funding

This research did not receive any specific grant from any funding agency in the public, commercial or not-for-profit sector.

#### Patient consent

Written informed consent has been obtained from the patient for publication of the submitted article and accompanying images.

## References

- 1 Klubo-Gwiedzinska J & Wartofsky L 2012 Thyroid emergencies. *Medical Clinics of North America* **96** 385–403. (doi:10.1016/j.mcna.2012.01.015)
- 2 Burch HB & Wartofsky L 1993 Life-threatening thyrotoxicosis. Thyroid storm. *Endocrinology and Metabolism Clinics of North America* **22** 263–277.
- 3 Mehta RL, Kellum JA, Shah SV, Molitoris BA, Ronco C, Warnock DG & Levin A 2007 Acute Kidney Injury Network: report of an initiative to improve outcomes in acute kidney injury. *Critical Care* **11** R31. (doi:10.1186/cc5713)
- 4 Chong HW, See KC & Phua J 2010 Thyroid storm with multiorgan failure. *Thyroid* **20** 333–336. (doi:10.1089/thy.2009.0181)
- 5 Schwartz J, Winters JL, Padmanabhan A, Balogun RA, Delaney M, Linenberger ML, Szczepiokowski ZM, Williams ME, Wu Y & Shaz BH 2013 Guidelines on the use of therapeutic apheresis in clinical practice—evidence-based approach from the Writing Committee of the American Society for apheresis: the sixth special issue. *Journal of Clinical Apheresis* **28** 145–284. (doi:10.1002/jca.21276)
- 6 Herrmann J, Schmidt HJ & KrHerrmann HL 1973 Thyroxine elimination by peritoneal dialysis in experimental thyrotoxicosis. *Hormone and Metabolic Research* **5** 180–183. (doi:10.1055/s-0028-1093968)
- 7 Burman KD, Yeager HC, Briggs WA, Earll JM & Wartofsky L 1976 Resin hemoperfusion: a method of removing circulating thyroid hormones. *Journal of Clinical Endocrinology and Metabolism* **42** 70–76. (doi:10.1210/jcem-42-1-70)
- 8 Candrina R, DiStefano O, Spandrio S & Giustina G 1989 Treatment of thyrotoxic storm by charcoal plasmapheresis. *Journal of Endocrinological Investigation* **12** 133–134. (doi:10.1007/BF03349943)
- 9 Koball S, Hickstein H, Gloger M, Hinz M, Henschel J, Stange J & Mitzner S 2010 Treatment of thyrotoxic crisis with plasmapheresis and single pass albumin dialysis: a case report. *Artificial Organs* **34** E55–E58. (doi:10.1111/j.1525-1594.2009.00924.x)
- 10 Goldstein SL 2011 Continuous renal replacement therapy: mechanism of clearance, fluid removal, indications and outcomes. *Current Opinion in Pediatrics* **23** 181–185. (doi:10.1097/MOP.0b013e328342fe67)

Received in final form 20 January 2017

Accepted 8 February 2017