



Contents lists available at ScienceDirect

International Journal of Surgery Case Reports

journal homepage: www.casereports.com

Hemangiopericytoma/solitary fibrous tumor of the greater omentum: A case report and review of the literature



Rami Archid^{a,*}, Carl Christoph Schneider^a, Patrick Adam^b, Ahmed Othman^c,
Derek Zieker^a, Alfred Königsrainer^a

^a Department of General, Visceral and Transplant Surgery, Eberhard-Karls-University Hospital Tuebingen, Germany

^b Institute of Pathology, Eberhard-Karls-University Hospital Tuebingen, Germany

^c Department of Diagnostic and Interventional Radiology, Eberhard-Karls-University Hospital Tuebingen, Germany

ARTICLE INFO

Article history:

Received 22 January 2016

Received in revised form 14 April 2016

Accepted 14 April 2016

Available online 21 April 2016

Keywords:

Hemangioma pericytoma

Mesenchymal tumor

Greater omentum

ABSTRACT

INTRODUCTION: Hemangiopericytoma (HPC) has been first described in 1942 by Stout as a tumor originating from the capillary surrounding pericytes. It is known to occur in any anatomical site, especially the extremities and retroperitoneum.

PRESENTATION OF CASE: We describe a case of a 24 year old patient presenting with lower abdominal pain due to a tumor of the greater omentum, the patient was treated by conventional laparotomy with tumor resection and the histological evaluation confirmed the diagnosis Hemangiopericytoma/Solitary fibrous tumor (HPC/SFT). The patient has regularly followed-up with periodic imaging for the last 4 years, with no recurrences.

DISCUSSION AND CONCLUSION: According to our knowledge, HPC rarely develops in the greater omentum, only 20 cases were described in the literature. Primary surgical resection is the treatment of choice. There is no benefit of radiation or systemic chemotherapy. Angiogenic inhibitors represent promising systemic therapeutic concepts.

© 2016 The Authors. Published by Elsevier Ltd. on behalf of IJS Publishing Group Ltd. This is an open access article under the CC BY-NC-ND license (<http://creativecommons.org/licenses/by-nc-nd/4.0/>).

1. Introduction

Hemangiopericytoma (HPC) is a tumor first described in 1942 by Stout as a tumor originating from the capillary-surrounding pericytes [1]. It is known to occur in any anatomical site, especially the skeletal muscles, subcutaneous tissue of the lower limbs and retroperitoneum [2]. HPC is most commonly prevalent amongst individuals between 20 and 70 years, with the median age in the 40s [2]. HPC of the greater omentum is a rare condition, according to our knowledge; only 20 cases have been published till the current date (PubMed, National Library of Medicine, Bethesda MD, USA). This following article describes a case of HPC/SFT of the greater omentum with discussion of the literature and the value of different therapeutic options.

2. Presentation of case

A 25-year-old male patient presenting with lower abdominal pain was referred to our surgical department. The patient had no

nausea or vomiting, no complaints of irregular bowel movements or blood in stool. The patient reported no previous abdominal complaints or interventions, apart from lower leg procedures as a result of an injury seven years ago. Abdominal examination revealed a slightly hyper-peristaltic bowel, with a soft consistency and a palpable moveable mass in the upper abdomen, though no sign of peritonitis. Ultrasound showed a solid intra-abdominal tumor lying above the bladder. Abdominal CT-scan showed a hypervascularized solid centrally inhomogeneous tumor measuring 5.7 × 8.3 × 6.8 cm in the left lower quadrant lateral to the bladder, with an emphasized vascular supply originating from the left gastroepiploic vessels (Fig. 1). Thorax CT-scan revealed no tumor. The patient was considered for surgical laparotomy and tumor resection, which was carried out successfully.

Intraoperative findings showed a tumor within the greater omentum, mainly supplied by the left gastroepiploic vessels (Fig. 2). No peritoneal or organ metastasis were seen. The tumor was removed en bloc with an omental root containing the supplying vessels and was sent for histological evaluation, which showed alternating hypocellular and hypercellular areas and a focal myxoid change (Fig. 3). The round to spindle-shaped nuclei had little cytoplasm and dispersed chromatin. The tumor was rich in partly hyalinised branching vessels. Mitotic counts reached 7 mitoses per 10 high-power fields. In the immunohistochemical analysis,

* Corresponding author at: University Hospital of Tuebingen, Dep. of General, Visceral and Transplant Surgery, Hoppe-Seyler-Str. 3, 72076 Tuebingen, Germany.
E-mail address: rami.archid@med.uni-tuebingen.de (R. Archid).

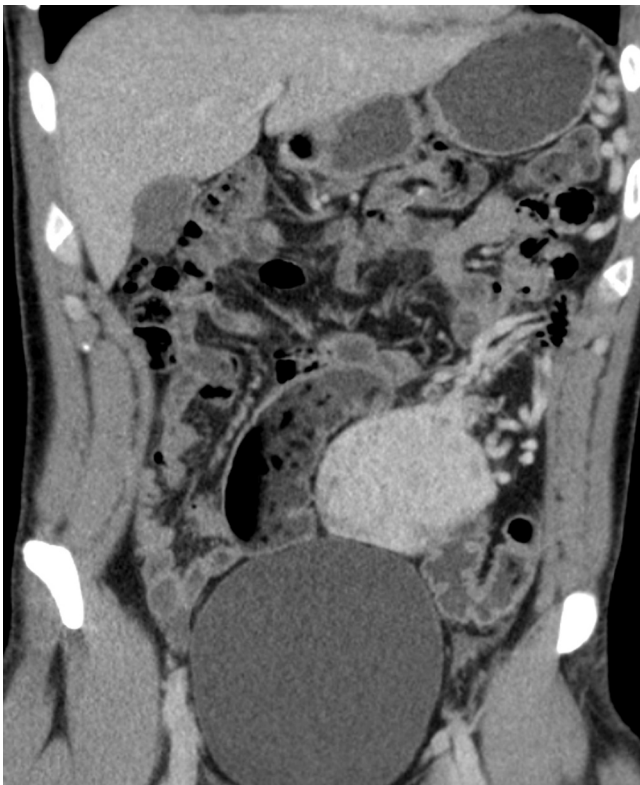


Fig. 1. Abdominal CT-scan showing a hypervascularized solid centrally inhomogeneous tumor measuring 5.7 × 8.3 × 6.8 cm in the left lower quadrant with an emphasized vascular supply originating from the left gastroepiploic vessels.

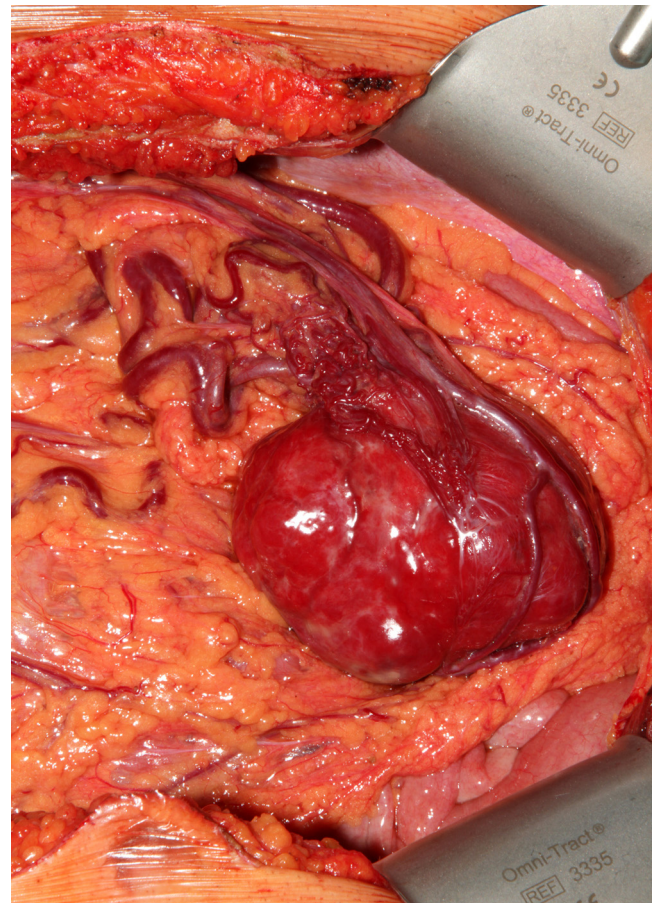


Fig. 2. Intraoperative image showing the tumor within the greater omentum, mainly supplied by the left gastroepiploic vessels.

the tumor showed a consistent positivity for CD34 and CD99 with negativity for AE1/3, Desmin, CD31, CD117, DOG1 and S100. Proliferation rate assessed by MIB1 staining was 5%. These findings confirm hemangiopericytoma as a diagnosis and the resection margin was free of tumor. The patient recovered with no complications and was discharged on the seventh postoperative day. The patient has regularly followed-up with periodic imaging for the last 4 years, with no recurrences.

3. Discussion and conclusion

Stout described several histological features of HPC in which the perivascular cells had different appearances [1]. Stout originally acknowledged the fact that the term Haemangiopericytoma was given in reference to Zimmermann's pericytes, which became questioned due to the scientific basis of the assumption [3]. Furthermore, studies have shown that only up to one third of HPCs show specific ultrastructural [4,5] or immunohistochemical features of pericytic origin [6,7]. As a consequence, the term solitary fibrous tumor SFT is being frequently utilized to embrace all HPC-like lesions [8].

According to the literature, HPC/SFT has a favorable long-term outcome after primary surgical resection [2,9]. HPC of the greater omentum has shown to recur at local or distant sites in several cases in the literature [10]. Enzinger and Smith suggested HPC malignancy criteria to be large tumor size (>5 cm), increased mitotic rate (≥4 mitotic figures/10HPF), high cellularity, presence of pleomorphic tumor cells and presence of haemorrhage and necrosis [2]. Still, the behavior of lesions lacking the mentioned criteria cannot be predicted [8]. Kaneko et al. concluded that a tumor size of more than 20 cm is an unfavorable prognostic factor of greater omen-

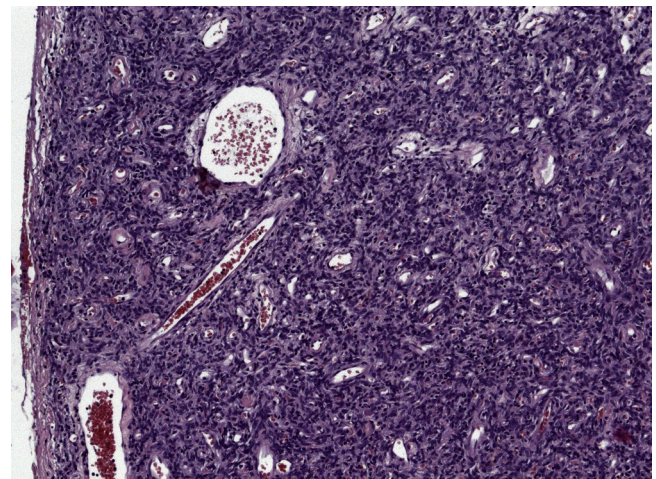


Fig. 3. Microscopic examination demonstrating numerous partly hyalinised branching vessels (stag-horn appearance) in the high population of spindle-shaped tumor cells. H&E, × 100.

tal HPC [10], though due to the limited number of cases on which the conclusion was made as well as the different possible entities of HPC/SFT, we believe that prognostic factors of omental HPC/SFT are to be seen as those of other regions.

Primary surgical resection is the treatment of choice, whenever possible [9,11]. Literature reports showed no significant benefit of radiation [12] or systemic chemotherapy [13,14], although a few responses have been reported. Due to the rich vascular charac-

teristics of these tumors, angiogenic inhibitors have emerged as promising systemic therapeutic concepts [15].

Conflicts of interest

The authors declare that there are no conflicts of interest.

Funding

We report no involvement of sponsors.

Ethical approval

The case report was approved by the local ethic committee at the university of Tuebingen. IEC-Project-number: 737/2015A.

Consent

Written informed consent was obtained from the patient and is available upon request. No patient identifying material was used in this manuscript.

Author contributions

Data collection: Rami Archid, Carl Christoph Schneider, Patrick Adam, Ahmed Othman, Derek Zieker; data analysis: Rami Archid, Patrick Adam, Ahmed Othman, Alfred Königsrainer; writing and revising of the final version of the manuscript: Rami Archid, Carl Christoph Schneider, Patrick Adam, Ahmed Othman, Derek Zieker, Alfred Königsrainer.

Guarantor

MD Rami Archid, University Hospital Tuebingen, Germany, Hoppe-Seyler-Str. 3, 72076-Tuebingen, Germany.

Acknowledgments

The work has been reported in line with the CARE criteria.

References

- [1] A.P. Stout, M.R. Murray, Hemangiopericytoma: a vascular tumor featuring Zimmermann's pericytes, *Ann. Surg.* 116 (1) (1942) 26–33.
- [2] F.M. Enzinger, B.H. Smith, Hemangiopericytoma. an analysis of 106 cases, *Hum. Pathol.* 7 (1) (1976) 61–82.
- [3] A.P. Stout, Hemangiopericytoma; a study of 25 cases, *Cancer* 2 (6) (1949) 1027–1054, illust.
- [4] I. Dardick, S.P. Hammar, B.W. Scheithauer, Ultrastructural spectrum of hemangiopericytoma: a comparative study of fetal, adult, and neoplastic pericytes, *Ultrastruct. Pathol.* 13 (2–3) (1989) 111–154.
- [5] H. Battifora, Hemangiopericytoma: ultrastructural study of five cases, *Cancer* 31 (6) (1973) 1418–1432.
- [6] W. Schurch, O. Skalli, R. Lagace, T.A. Seemayer, G. Gabbiani, Intermediate filament proteins and actin isoforms as markers for soft-tissue tumor differentiation and origin.III. Hemangiopericytomas and glomus tumors, *Am. J. Pathol.* 136 (4) (1990) 771–786.
- [7] P.L. Porter, S.A. Bigler, M. McNutt, A.M. Gown, The immunophenotype of hemangiopericytomas and glomus tumors, with special reference to muscle protein expression: an immunohistochemical study and review of the literature, *Mod. Pathol.* 4 (1) (1991) 46–52.
- [8] C. Gengler, L. Guillou, Solitary fibrous tumour and haemangiopericytoma: evolution of a concept, *Histopathology* 48 (1) (2006) 63–74.
- [9] F.R. Spitz, M. Bouvet, P.W. Pisters, R.E. Pollock, B.W. Feig, Hemangiopericytoma: a 20-year single-institution experience, *Ann. Surg. Oncol.* 5 (4) (1998) 350–355.
- [10] K. Kaneko, Y. Shirai, T. Wakai, G. Hasegawa, I. Kaneko, K. Hatakeyama, Hemangiopericytoma arising in the greater omentum: report of a case, *Surg. Today* 33 (9) (2003) 722–724.
- [11] N.J. Espat, J.J. Lewis, D. Leung, J.M. Woodruff, C.R. Antonescu, J. Shia, et al., Conventional hemangiopericytoma: modern analysis of outcome, *Cancer* 95 (8) (2002) 1746–1751.
- [12] E. Galanis, J.C. Buckner, B.W. Scheithauer, D.W. Kimmel, P.J. Schomberg, D.G. Piepgras, Management of recurrent meningeal hemangiopericytoma, *Cancer* 82 (10) (1998) 1915–1920.
- [13] G.F. Beadle, B.L. Hillcoat, Treatment of advanced malignant hemangiopericytoma with combination adriamycin and DTIC: a report of four cases, *J. Surg. Oncol.* 22 (3) (1983) 167–170.
- [14] M.C. Chamberlain, M.J. Glantz, Sequential salvage chemotherapy for recurrent intracranial hemangiopericytoma, *Neurosurgery* 63 (4) (2008) 720–726.
- [15] M.S. Park, D.M. Araujo, New insights into the hemangiopericytoma/solitary fibrous tumor spectrum of tumors, *Curr. Opin. Oncol.* 21 (4) (2009) 327–331.

Open Access

This article is published Open Access at sciedirect.com. It is distributed under the [IJSCR Supplemental terms and conditions](#), which permits unrestricted non commercial use, distribution, and reproduction in any medium, provided the original authors and source are credited.